Application of ASTLOF Scoring System in the Treatment of Acute Symptomatic Thoracolumbar Compression Fractures

Qing-Da Li
Honghui Hospital Affiliated to Xian Jiaotong University
Jun-Song Yang
Honghui Hospital Affiliated to Xian jiaotong University
Chao Jiang
Xi'an Jiaotong University Medical College First Affiliated Hospital
Yi-Fan Ma
Xi'an Jiaotong University Medical College First Affiliated Hospital
Xin Tian
Honghui Hospital Affiliated to Xian Jiaotong University
Ming-Yi Yang
Honghui Hospital Affiliated to Xian Jiaotong University
Wang-Li Huang
Honghui Hospital Affiliated to Xian Jiaotong University
Yuan Tuo
Honghui Hospital Affiliated to Xian Jiaotong University
Ding-Jun Hao (dingjun-hao@qq.com)
Honghui Hospital Affiliated to Xi'an Jiaotong University, Xi'an, 710054, China https://orcid.org/0000-0001-5162-8701

Research article

Keywords: tuberculosis, spinal tuberculosis, kyphotic deformity, related factors, surgery

Posted Date: October 6th, 2020

DOI: https://doi.org/10.21203/rs.3.rs-77485/v1

Abstract

Background: Osteoporotic vertebral compression fracture (OVCF) is a common injury in the elderly, often caused by low-energy injuries. Improper treatment will not only affect the stability and balance of the spine, but in severe cases will lead to neurological damage and increase the risk of death. This retrospective study aims to explore the principles of treatment of patients with the assessment system of thoracolumbar osteoporotic fracture (ASTLOF) in acute symptomatic thoracolumbar compression fractures when the ASTLOF score = 4 points.

Methods: The clinical data of patients with acute symptomatic thoracolumbar compression fractures admitted from February 2018 to February 2020 were retrospectively analyzed. Each patient was evaluated according to the ASTLOF scoring system, and patients with ASTLOF score = 4 were selected, a total of 108 patients. According to different treatment methods, they were divided into 32 cases in the non-surgical treatment (NST) group and 76 cases in the surgical treatment (ST)group. The visual analog score (VAS), Oswestry disability index (ODI), the recovery of injured vertebral body height, and the incidence of adjacent segment fractures were used for comprehensive evaluation.

Results: During the follow-up, the VAS score and ODI score showed that the early pain relief and functional improvement of the surgical treatment group were better than those of the conservative treatment group ($P<0.05$); the Cobb angle of the surgical treatment group was 3 months and 6 months after the operation, and the vertebral body was injured. The degree of improvement of margin height was better than that of the conservative treatment group (all $P<0.05$); in the surgical treatment group, 6 cases of adjacent vertebral fractures occurred after surgery, accounting for 7.89%, and 2 cases of the conservative treatment group had adjacent vertebral fractures, accounting for 6.25% There was no statistically significant difference between the two groups ($P>0.05$).

Conclusions: When the ASTLOF scoring system is used in the treatment of acute symptomatic thoracolumbar compression fractures, patients with ASTLOF score =4 should be treated with surgery in time, which can relieve pain early and quickly, perform functional exercises as soon as possible, and reduce complications related to long-term bed rest. Whether it increases the risk of adjacent vertebral fractures requires long-term follow-up studies in a large number of cases.

Background

Osteoporosis is a group of systemic skeletal diseases characterized by bone loss and destruction of bone microstructure, which leads to the decrease of bone strength, bone fragility, and increased risk of fracture[1]. The main complication of osteoporosis is osteoporotic vertebral compression fracture (OVCF)[2]. At present, there are more than 8.9 million osteoporotic fractures in the world every year, among which OVCF accounts for about 40% of all osteoporotic fractures[3, 4]. At the same time, OVCF is also an important cause of morbidity and mortality in patients with osteoporosis. The traditional treatment strategy for hospitalized OVCF is non-surgical management (NSM), that is, bed rest, external brace fixation, analgesia, and oral anti-osteoporosis drugs have achieved certain clinical effects[5].

However, the majority of OVCF patients are elderly patients and postmenopausal women. The patients' systemic function is decreased, and the traditional NSH fracture healing is slow, so they need to stay in bed for a long

time, which can easily lead to infection, bedsore, pulmonary thrombosis, and progressive decalcification and other related complications. Therefore, for the treatment of OVCF, the traditional treatment based on NSM gradually tends to be surgical treatment. Percutaneous vertebroplasty (PVP) or percutaneous kyphoplasty (PKP) that is, injection of medical bone cement or polymethylmethacrylate (PMMA) into the fractured vertebrae has been widely accepted as an effective pain relief method, and has become the conventional treatment for OVCF[6-9]. However, other studies have shown that PVP / PKP is similar to NSM in the conventional treatment of acute or subacute OVCFs patients, and does not show better clinical advantages. Therefore, how to evaluate the choice of conservative treatment or surgical treatment is a problem worthy of study[10-12]. After the ASTLOF was proposed and is widely used in clinical practice[13]. For osteoporotic vertebral compression fractures, the ASTLOF score of most patients was 4. According to the ASTLOF score system, surgery or conservative treatment can be selected, which makes clinicians have different opinions in treatment decisions. The clinical data of 108 patients with acute symptomatic OVCF who were admitted to our hospital from February 2018 to February 2020 were retrospectively analyzed to explore the treatment principles of patients with ASTLOF score = 4.

Methods

Inclusion and Exclusion Criteria

Inclusion criteria: ▯Meet the WHO criteria for diagnosing osteoporosis, -3.5SD< T value ≤-2.5SD [14]; ▯Low back pain (pain induced by changes in body position), VAS>5; ▯After imaging examination (X, CT or MRI) was diagnosed as OVCFs; ▯No symptoms and signs of the spinal cord and nerve root damage; ▯Single-segment vertebral compression fracture; ▯Age>55 years; ▯The course of disease ≤6 weeks.

Exclusion criteria: ▯ Osteoporosis caused by drugs or medical diseases; ▯ Burst fractures caused by severe violence; ▯ History of allergy to acrylic and bisphosphonate drugs; ▯ Pathological fractures. ▯Bone mineral density(BMD): T value ≤ -3.5SD or T value> -2.5SD; ▯ those with coagulation dysfunction; ▯ those with infection all over the body or at the puncture site.

General Materials

There were 108 cases (21 males and 87 females) with an average age of (71.62 ± 8.43) years (range, 55-92 years). There were 58 cases with slight trauma history, 14 cases with severe trauma history, and 36 cases without obvious trauma history. The main symptoms included low back pain, limited movement, and difficulty in turning over. The time from symptom onset to admission was 1-42 days, with an average of (6.85 ± 2.36) days. Among them, there were 5 cases of T6-T10, 14 cases of T11, 20 cases of T12, 32 cases of L1, 18 cases of L2, 6 cases of L3, 9 cases of L4, and 4 cases of L5**(Table1)**. There was no significant difference in age, sex ratio, BMD, and the vertebral segment between the two groups (P > 0.05). Before the start of the study, patients or their families were informed and signed an agreement. This study was reviewed and approved by the ethics committee of Honghui Hospital Affiliated to Xi'an Jiaotong University.

ASTLOF *Scoring Method and Application*

The ASTLOF score is based on the morphological changes of the injured vertebrae, MRI manifestations of the injured vertebrae, bone mineral density, and clinical manifestations (pain/neurological symptoms). The maximum total score is 8 points. See **Table 2** for details. The total score can be used as the basis for selecting

the treatment plan: total score ≤ 3 points, non-surgical treatment: total score = 4 points, according to the patient's vital signs to tolerate surgery, combined with the patient's desire for surgery and the quality of life requirements, Use non-surgical treatment or PKP/PVP; total score ≥ 5, use PKP/PVP, or open surgery that is fracture reduction and internal fixation + injured vertebra PKP/PVP.

Therapeutic Technique

Non-operative treatment: Taking analgesics (celecoxib), rest in bed, wearing a brace to move down the ground after 4-6 weeks; cooperating with anti-osteoporosis drug treatment (calcium + vitamin D + calcitonin / zoledronic acid); preventing bed-related complications; starting rehabilitation treatment in the rehabilitation department of our hospital one week later (including hyperthermia treatment of injured vertebrae, interference current therapy or ultrasonic therapy); according to the patients with OVCFs Patients with pain tolerance, the back fascia extension, abdominal and hip extensors isometric contraction exercise rehabilitation exercise.

Surgical treatment: PKP / PVP treatment.

Evaluation index and Follow-up

The 108 patients with acute symptomatic osteoporotic vertebral compression fractures included in the study were collected with complete clinical and imaging data (X, CT, and MRI), and divided into non-surgical treatment group (n1=32) and surgical treatment group according to different treatment methods (n2=76). Follow-ups were performed at 1 week, 1 month, 3 months, 6 months, and 1 year after surgery. According to the visual analog score (VAS), the Oswestry disability index (ODI), the height recovery of the injured vertebral body, and the incidence of adjacent segment fractures, the efficacy evaluation criteria were used.

Statistical analysis

Statistical software SPSS 22.0 (IBM, Armonk, NY, USA) was used to analyze the data. The count data were expressed as a percentage and the chi-square test was used. The measurement data were expressed as mean ± standard deviation . Analysis of variance (ANOVA) was used for preoperative and postoperative comparison within groups, and the t-test of independent samples was used for intergroup comparison. The difference was statistically significant ($P < 0.05$).

Results

VAS and ODI Scores

All patients were followed up. This group was followed up for 12.00 to 18.00 months, with an average of (13.42±4.11) months. There was no significant difference in VAS score and ODI score between the two groups before surgery ($P>0.05$), but the VAS score and ODI score in the surgical treatment group were significantly lower than the conservative treatment group at different time points after treatment, and the difference between the two groups was statistically significant ($P<0.05$), but at the last follow-up, there was no significant difference between the groups ($P>0.05$). **Table 3** shows the results of VAS scores of patients with different treatments, and **Table 4** shows the results of ODI scores. The decreasing trend of VAS score after treatment of patients with different treatment methods is shown in **Figure 1**, and the decreasing trend of the ODI score is shown in **Figure 2**. The VAS scores of patients with different treatment methods after treatment decreased compared with those

before treatment, but the rate of decrease in VAS of the surgical treatment group was significantly higher than that of the conservative treatment group one week after treatment, the difference was statistically significant [(55.48±8.36)% vs (14.53±) 1.95)%, P<0.05]. Similarly, the rate of ODI reduction in the surgical treatment group was significantly faster than that in the conservative treatment group, and the difference was statistically significant [(36.22±1.57)% vs (4.96±0.15)%, P<0.05]. It indicates that the early and rapid pain relief effect of surgical treatment is significantly better than that of conservative treatment. The image of typical cases of surgical treatment is shown in **Figure 3**.

Cobb and Vertebral Height

There was no significant difference in the Cobb angle of kyphosis and anterior height ratio of the injured vertebral body between the two groups (P > 0.05). At 3 months and 6 months after the operation, the Cobb angle and anterior height of the injured vertebral body in the surgical treatment group were significantly improved compared with those before the operation, but there was no significant improvement in the non-surgical treatment group. The differences between the two groups were statistically significant (P < 0.05, **Table 5**).

Incidence of Adjacent Vertebral Fractures

The incidence of adjacent vertebral fractures in the two groups was followed up. There were 2 cases of adjacent vertebral fractures in the non-surgical treatment group, accounting for 6.25%, and 6 cases in the surgical treatment group, accounting for 7.89%. There was no significant difference between the two groups (P > 0.05, **Table 6**)

Discussion

OVCF is more common in elderly and menopausal women[15]. With the aging of the population, the mobility and the balance of ability decrease, resulting in a significant increase in the incidence rate[16]. According to statistics, about a quarter of postmenopausal women will have OVCF at least once in their life[17], and one-third of women and one-fifth of men over the age of 50 will have a vertebral fracture in the rest of their lives[18]. OVCF is mainly caused by the low-energy injury. Bone formation and callus maturation are delayed due to the lack of bone mass, which is prone to delayed union or nonunion. When OVCF occurs, it will not only cause pain, deformity, dyskinesia, and other symptoms, but also lead to the decline of lung function and gastrointestinal problems, and increase the mortality rate[19].

Currently, the clinical classification of OVCF mainly includes the semi-quantitative method proposed by Genant in 1993[20], the Heini classification proposed by Heini in 2004[21], and the classification of compression fractures and burst fractures proposed by the Orthopedic Branch of the Chinese Medical Association in 2008. These classifications are still based on the morphological characteristics of fractures and spinal stability in imaging, and the evaluation indexes are single. Clinical symptoms, BMD, and MRI findings are not included in the evaluation criteria. The severity of OVCF can not be evaluated and no corresponding treatment measures are available. Therefore, it is bound to affect the prognosis and clinical treatment of OVCF[22]. How to evaluate whether patients choose the non-surgical treatment or surgical treatment? If Denis classification, AO classification, or TLICS spinal injury score system are used, these classifications are mainly for high-energy spinal injury, which is difficult to adapt to OVCF characterized by low-energy injury and osteoporosis[23, 24]. Hao Dingjun et al.[25] proposed the assessment system of thoracolumbar osteoporotic fracture (ASTLOF). The

scoring system consists of four parts: clinical manifestations of patients, morphological changes of injured vertebrae, MRI results, and bone mineral density. The classification combines imaging and clinical symptoms, provides a quantitative index for the treatment of OVCF and recommends the corresponding treatment scheme according to different scores. If the total score of ASTLOF is less than or equal to 3 points, conservative treatment is recommended; if the total score of ASTLOF is 4 points, both non-surgical treatment and surgical treatment are acceptable; if the total score of ASTLOF is more than 5 points, surgical treatment is recommended. Many scholars have verified that the scoring system has high feasibility and repeatability, and can effectively guide the clinical treatment of thoracolumbar OVCF. According to the ASTLOF scoring system, in 2019, the orthopedics branch of the Chinese Medical Association proposed the clinical guidelines for vertebral augmentation for acute symptomatic osteoporotic thoracolumbar vertebral compression fractures, which provides evidence-based medical evidence for the application of vertebral augmentation in OVCF treatment. In patients with acute symptomatic thoracolumbar compression fractures, most of the patients had low back pain (1 point). For such patients, the morphological changes of injured vertebrae were mostly compression fractures (1 point), MRI showed long T1 long T2 signal changes or fat suppression image showed high signal (1 point), and-3.5 < T value ≤ - 2.5 (1 point), which was the ASTLOF evaluation Four points. According to the ASTLOF scoring system and OVCF clinical guidelines, 4 points can choose the non-surgical treatment or surgical treatment. The uncertainty of the treatment choice makes clinicians confused in the treatment decision-making.

The author followed up the data of 108 patients with acute symptomatic thoracolumbar compression fractures with an ASTLOF score of 4 in our hospital. The results showed that the symptoms of low back pain and days activity of all patients in the non-surgical and surgical treatment groups gradually improved during different follow-up periods, and the VAS And ODI scores decreased gradually, and the difference was statistically significant compared with that at admission ($P<0.05$). However, the pain and functional recovery of the surgical treatment group were significantly better than those of the conservative treatment group ($P<0.05$). At the last follow-up, the overall VAS and ODI of the surgical group were significantly lower than those of the non-surgical group, indicating that the treatment options of the non-surgical and surgical groups were effective, but the surgery The treatment effect of the group is generally better than that of the non-surgical group, that is, PKP/PVP has the advantages of relieving pain and improving dysfunction in a short time. It shows that the selection of surgical treatment is reasonable and effective according to the ASTLOF score = 4 points. According to the cascade relationship of spinal fractures[26], patients with at least one minor vertebral fracture have a four-fold higher risk of subsequent vertebral fractures than those without fractures, which increases sharply with the number and severity of previous vertebral fractures[27]. Therefore, the patients with OVCF whose ASTLOF score is 4 points should be treated with surgery in time, which can relieve the pain quickly and recover the functional exercise as soon as possible, to reduce the incidence of complications such as falling pneumonia, urinary tract infection, muscle atrophy and weakness, bedsore and further loss of bone mass caused by long-term bed rest.

It has been reported that the risk of mortality associated with OVCF may be associated with spinal deformity, with a 1.14-fold increase in the kyphosis angle of age-adjusted SD[28]. Therefore, early correction of vertebral height and kyphosis Cobb angle is helpful to maintain the sagittal balance of the spine, reduce the incidence of lumbago, and reduce the risk of death associated with OVCF. When bone cement is injected into the injured vertebrae, the fracture site can not only regain mechanical stability, but also maintain the reduction state after hardening, and the height and Cobb angle of the injured vertebral body can be partially restored. At present, it is uncertain whether PKP / PVP increases the risk of vertebral fractures, especially adjacent vertebral bodies[29]. It

has been reported in previous literature that the strength of the vertebral body and the physiological invagination of endplate are aggravated by injecting bone cement into injured vertebrae, which increases the pressure of the intervertebral disc, transfers the load to adjacent vertebrae, and increases the risk of fracture of the adjacent vertebral body[30-32]. In this study, the incidence of adjacent vertebral fractures in the surgical treatment group was 7.89%, which was not significantly different from that in the conservative treatment group (6.25%) ($P > 0.05$). However, due to the small number of cases in this study and the limited follow-up time, it is not clear whether the occurrence of vertebral fractures is the result of the natural course of osteoporosis or PKP / PVP surgery.

Conclusion

For patients with acute symptomatic OVCF whose ASTLOF score is 4, early surgical treatment should be given in time. It can not only relieve the pain quickly and perform the functional exercise as soon as possible but also effectively restore the height of the injured vertebrae and correct Cobb angle, which is conducive to reduce the incidence of related complications caused by long-term bed rest. However, whether it increases the risk of adjacent vertebral fractures still needs a large number of long-term follow-up studies. This study is a single-center retrospective study, the sample size is limited and multicenter, larger sample size and data statistics are needed.

Abbreviations

ASTLOF: Assessment system of thoracolumbar osteoporotic fracture; OVCF: Osteoporotic vertebral compression fracture; NST: Non-surgical treatment; ST: Surgical treatment; VAS: Visual analog score; ODI: Oswestry disability index; PVP: Percutaneous vertebroplasty; PKP: Percutaneous kyphoplasty; PMMA: Polymethylmethacrylate; Pre: pre-treatment; Post-1w: post-treatment 1 week; Post-3m: post-treatment 3 month; Post-6m: post-treatment 6 month; SD: Standard deviations; BMD: Bone mineral density; CT: Computer Tomography; MRI: Magnetic resonance imaging;

Declarations

Ethics approval and consent to participate

The study was approved by the ethics committee of the Honghui Hospital Affiliated to Xi'an Jiaotong University, and all subjects obtained written informed consent.

Consent for publication

The subjects gave consent for any form of information about themselves to be published in the Journal of Orthopaedic Surgery and Research.

Availability of data and material

The dataset(s) supporting the conclusions of this article is included in the article.

Competing interests

The authors declare that they have no competing interests.

Funding

National Natural Science Foundation of China (81830077 81772357).

Authors' contributions

HDJ was responsible for the experimental design; LQD was responsible for writing the article; YJS was responsible for critical review of the intellectual content of the article. TY was responsible for the implementation of the experiment; JC, MYF, YMY, TX, and HWL were responsible for data collection and statistical analysis;

Acknowledgments

None.

Author Details

1 Honghui Hospital Affiliated to Xi'an Jiaotong University, Xi'an, 710054, China

2 The First Affiliated Hospital of Xi'an Jiaotong University, Xi'an, 710054, China

References

1. Barr JD, Barr MS, Lemley TJ, McCann RM: **Percutaneous vertebroplasty for pain relief and spinal stabilization**. *Spine (Phila Pa 1976)* 2000, **25**(8):923-928.
2. Lane JM, Russell L, Khan SN: **Osteoporosis**. *Clin Orthop Relat Res* 2000(372):139-150.
3. Shuler FD, Scott K, Wilson-Byrne T, Morgan L, Olajide OB: **Improving Rural Bone Health and Minimizing Fracture Risk in West Virginia: Validation of the World Health Organization FRAX Assessment Tool as a Phone Survey for Osteoporosis Detection**. *W V Med J* 2016, **112**(3):84-88.
4. Si L, Winzenberg TM, Jiang Q, Chen M, Palmer AJ: **Projection of osteoporosis-related fractures and costs in China: 2010-2050**. *Osteoporos Int* 2015, **26**(7):1929-1937.
5. Yokoyama K, Kawanishi M, Yamada M, Tanaka H, Ito Y, Kuroiwa T: **Long-term therapeutic effects of vertebroplasty for painful vertebral compression fracture: a retrospective comparative study**. *Br J Neurosurg* 2017, **31**(2):184-188.
6. Cohen JE, Lylyk P, Ceratto R, Kaplan L, Umanskyt F, Gomori JM: **Percutaneous vertebroplasty: technique and results in 192 procedures**. *Neurol Res* 2004, **26**(1):41-49.
7. Peh WC, Gilula LA, Peck DD: **Percutaneous vertebroplasty for severe osteoporotic vertebral body compression fractures**. *Radiology* 2002, **223**(1):121-126.
8. Wardlaw D, Cummings SR, Van Meirhaeghe J, Bastian L, Tillman JB, Ranstam J, Eastell R, Shabe P, Talmadge K, Boonen S: **Efficacy and safety of balloon kyphoplasty compared with non-surgical care for vertebral compression fracture (FREE): a randomised controlled trial**. *Lancet* 2009, **373**(9668):1016-1024.
9. Kobayashi K, Shimoyama K, Nakamura K, Murata K: **Percutaneous vertebroplasty immediately relieves pain of osteoporotic vertebral compression fractures and prevents prolonged immobilization of patients**. *Eur*

Radiol 2005, **15**(2):360-367.

10. Boszczyk B: **Percutaneous vertebroplasty does not reduce pain and disability from osteoporotic vertebral compression fracture**. *Evid Based Med* 2015, **20**(5):181.
11. Buchbinder R, Johnston RV, Rischin KJ, Homik J, Jones CA, Golmohammadi K, Kallmes DF: **Percutaneous vertebroplasty for osteoporotic vertebral compression fracture**. *Cochrane Database Syst Rev* 2018, **4**(4):Cd006349.
12. Macías-Hernández SI, Chávez-Arias DD, Miranda-Duarte A, Coronado-Zarco R, Diez-García MP: **Percutaneous Vertebroplasty Versus Conservative Treatment and Rehabilitation in Women with Vertebral Fractures due to Osteoporosis: A Prospective Comparative Study**. *Rev Invest Clin* 2015, **67**(2):98-103.
13. Xu Z, Hao D, He L, Guo H, He B, Liu T, Zheng Y, Wang D: **An assessment system for evaluating the severity of thoracolumbar osteoporotic fracture and its clinical application: A retrospective study of 381 cases**. *Clin Neurol Neurosurg* 2015, **139**:70-75.
14. Akkawi I, Zmerly H: **Osteoporosis: Current Concepts**. *Joints* 2018, **6**(2):122-127.
15. Meunier PJ, Roux C, Seeman E, Ortolani S, Badurski JE, Spector TD, Cannata J, Balogh A, Lemmel EM, Pors-Nielsen S *et al*: **The effects of strontium ranelate on the risk of vertebral fracture in women with postmenopausal osteoporosis**. *N Engl J Med* 2004, **350**(5):459-468.
16. Xie L, Zhao ZG, Zhang SJ, Hu YB: **Percutaneous vertebroplasty versus conservative treatment for osteoporotic vertebral compression fractures: An updated meta-analysis of prospective randomized controlled trials**. *Int J Surg* 2017, **47**:25-32.
17. Kim DG, Navalgund AR, Tee BC, Noble GJ, Hart RT, Lee HR: **Increased variability of bone tissue mineral density resulting from estrogen deficiency influences creep behavior in a rat vertebral body**. *Bone* 2012, **51**(5):868-875.
18. Oberkircher L, Ruchholtz S, Rommens PM, Hofmann A, Bücking B, Krüger A: **Osteoporotic Pelvic Fractures**. *Dtsch Arztebl Int* 2018, **115**(5):70-80.
19. Liu T, Li Z, Su Q, Hai Y: **Cement leakage in osteoporotic vertebral compression fractures with cortical defect using high-viscosity bone cement during unilateral percutaneous kyphoplasty surgery**. *Medicine (Baltimore)* 2017, **96**(25):e7216.
20. Genant HK, Wu CY, van Kuijk C, Nevitt MC: **Vertebral fracture assessment using a semiquantitative technique**. *J Bone Miner Res* 1993, **8**(9):1137-1148.
21. Heini PF, Orler R: **Kyphoplasty for treatment of osteoporotic vertebral fractures**. *Eur Spine J* 2004, **13**(3):184-192.
22. Oei L, Koromani F, Breda SJ, Schousboe JT, Clark EM, van Meurs JB, Ikram MA, Waarsing JH, van Rooij FJ, Zillikens MC *et al*: **Osteoporotic Vertebral Fracture Prevalence Varies Widely Between Qualitative and Quantitative Radiological Assessment Methods: The Rotterdam Study**. *J Bone Miner Res* 2018, **33**(4):560-568.
23. Vaccaro AR, Lehman RA, Jr., Hurlbert RJ, Anderson PA, Harris M, Hedlund R, Harrop J, Dvorak M, Wood K, Fehlings MG *et al*: **A new classification of thoracolumbar injuries: the importance of injury morphology, the integrity of the posterior ligamentous complex, and neurologic status**. *Spine (Phila Pa 1976)* 2005, **30**(20):2325-2333.

24. Schnake KJ, Blattert TR, Hahn P, Franck A, Hartmann F, Ullrich B, Verheyden A, Mörk S, Zimmermann V, Gonschorek O *et al*: **Classification of Osteoporotic Thoracolumbar Spine Fractures: Recommendations of the Spine Section of the German Society for Orthopaedics and Trauma (DGOU)**. *Global Spine J* 2018, **8**(2 Suppl):46s-49s.
25. Du JP, Liu JJ, Fan Y, Zhang JN, Huang YS, Zhang J, Hao DJ: **Surgery for Multisegment Thoracolumbar Mild Osteoporotic Fractures: Revised Assessment System of Thoracolumbar Osteoporotic Fracture**. *World Neurosurg* 2018, **114**:e969-e975.
26. Briggs AM, Greig AM, Wark JD: **The vertebral fracture cascade in osteoporosis: a review of aetiopathogenesis**. *Osteoporos Int* 2007, **18**(5):575-584.
27. Wegrzyn J, Roux JP, Arlot ME, Boutroy S, Vilayphiou N, Guyen O, Delmas PD, Chapurlat R, Bouxsein ML: **Determinants of the mechanical behavior of human lumbar vertebrae after simulated mild fracture**. *J Bone Miner Res* 2011, **26**(4):739-746.
28. Svedbom A, Alvares L, Cooper C, Marsh D, Ström O: **Balloon kyphoplasty compared to vertebroplasty and nonsurgical management in patients hospitalised with acute osteoporotic vertebral compression fracture: a UK cost-effectiveness analysis**. *Osteoporos Int* 2013, **24**(1):355-367.
29. Miller FG, Kallmes DF, Buchbinder R: **Vertebroplasty and the placebo response**. *Radiology* 2011, **259**(3):621-625.
30. Takahara K, Kamimura M, Moriya H, Ashizawa R, Koike T, Hidai Y, Ikegami S, Nakamura Y, Kato H: **Risk factors of adjacent vertebral collapse after percutaneous vertebroplasty for osteoporotic vertebral fracture in postmenopausal women**. *BMC Musculoskelet Disord* 2016, **17**:12.
31. Borensztein M, Camino Willhuber GO, Posadas Martinez ML, Gruenberg M, Sola CA, Velan O: **Analysis of Risk Factors for New Vertebral Fracture After Percutaneous Vertebroplasty**. *Global Spine J* 2018, **8**(5):446-452.
32. Zhang H, Xu C, Zhang T, Gao Z, Zhang T: **Does Percutaneous Vertebroplasty or Balloon Kyphoplasty for Osteoporotic Vertebral Compression Fractures Increase the Incidence of New Vertebral Fractures? A Meta-Analysis**. *Pain Physician* 2017, **20**(1):E13-e28.

Tables

Table 1 Patients demographic data

Parameter	Value
Number of patients	108
Male	21(19.4%)
Female	87(80.6%)
Age (years)	71.62±8.43
History of trauma	
Slight	58(53.7%)
Serious	14(13.0%)
No	36(33.3%)
Hospital stay(day)	6.85±2.36
Segments	
T6~T10	5
T11	14
T12	20
L1	32
L2	18
L3	6
L4	9
L5	4

Table 2 The assessment system of thoracolumbar osteoporotic fracture (ASTLOF).

Project	Score
Morphological changes	
Normal	0
Compression (single concave change / double concave change / wedge change)	1
Burst (involving fracture of central column)	2
MRI	
Normal	0
Long T1, long T2 signal changes or STIR high signal	1
Vacuum phenomenon or hydrops sign in the vertebral body	2
Bone mineral density□SD□	
T >−2.5 SD	0
-3.5SD< T ≤-2.5SD	1
T ≤-3.5SD	2
Clinical manifestation	
No obvious pain	0
Low back pain (pain caused by posture changes)	1
Persistent significant pain/nerve damage	2
Total score	0-8

Table 3 Comparison of VAS score results in different treatments and time points (x ± s)

Treatment	Pre	Post-1w	Post-3m	Post-6m	Follow-up	T-value	P-value
NST	7.48±1.62	6.42±1.71	5.27±1.53	3.25±1.48	2.40±1.36	342.483	□0.001
ST	7.56±1.70	3.45±1.04	2.14±0.62	1.98±0.53	1.81±0.43	276.538	□0.001
T-value	48.135	86.573	71.357	53.184	7.568		
P-value	0.071	□0.001	□0.001	0.046	0.078		

Pre: pre-treatment; Post-1w: post-treatment 1 week; Post-3m: post-treatment 3 months; Post-6m: post-treatment 6 months; NST: Non-surgical treatment; ST: Surgical treatment;

Table 4 Comparison of ODI score results in different treatments and time points (x ± s)

Treatment	Pre	Post-1w	Post-3m	Post-6m	Follow-up	T-value	P-value
NST	70.26±11.57	65.74±12.08	58.26±10.74	45.64±9.25	40.85±5.91	159.980	0.001
ST	72.85±13.46	45.83±10.25	35.30±8.63	26.52±7.10	28.91±4.67	148.723	0.001
T-value	21.573	63.725	58.282	48.264	13.857		
P-value	0.065	0.001	0.001	0.001	0.072		

Pre: pre-treatment; Post-1w: post-treatment 1 week; Post-3m: post-treatment 3 months; Post-6m: post-treatment 6 months; NST: Non-surgical treatment; ST: Surgical treatment;

Table 5 Comparison of Cobb angle and vertebral body height recovery in different treatments and time points (x ± s)

Parameter	NST	ST	T-value	P-value
Cobb°				
Pre	21.36±2.47	21.93±2.86	0.095	0.936
Post-3m	22.38±2.16	18.32±3.85	3.094	0.05
Post-6m	22.45±1.72	17.53±2.97	4.683	0.05
Injured vertebral height ratio (%)				
Pre	62.86±7.42	64.57±6.72	0.086	0.387
Post-3m	65.48±7.62	75.38±8.64	3.442	0.05
Post-6m	65.24±7.38	76.61±8.58	4.653	0.05

Pre: pre-treatment; Post-3m: post-treatment 3 months; Post-6m: post-treatment 6 month s; NST: Non-surgical treatment; ST: Surgical treatment;

Table 6 Comparison of the incidence of adjacent vertebral fractures in different treatments

Group	Fracture	Not fractured	Number	Incidence of adjacent vertebral fractures (%)
NST	2	30	32	6.25%
ST	6	70	76	7.89%
c2–value	0.09			
P-value	0.766			

NST: Non-surgical treatment; ST: Surgical treatment;

Figures

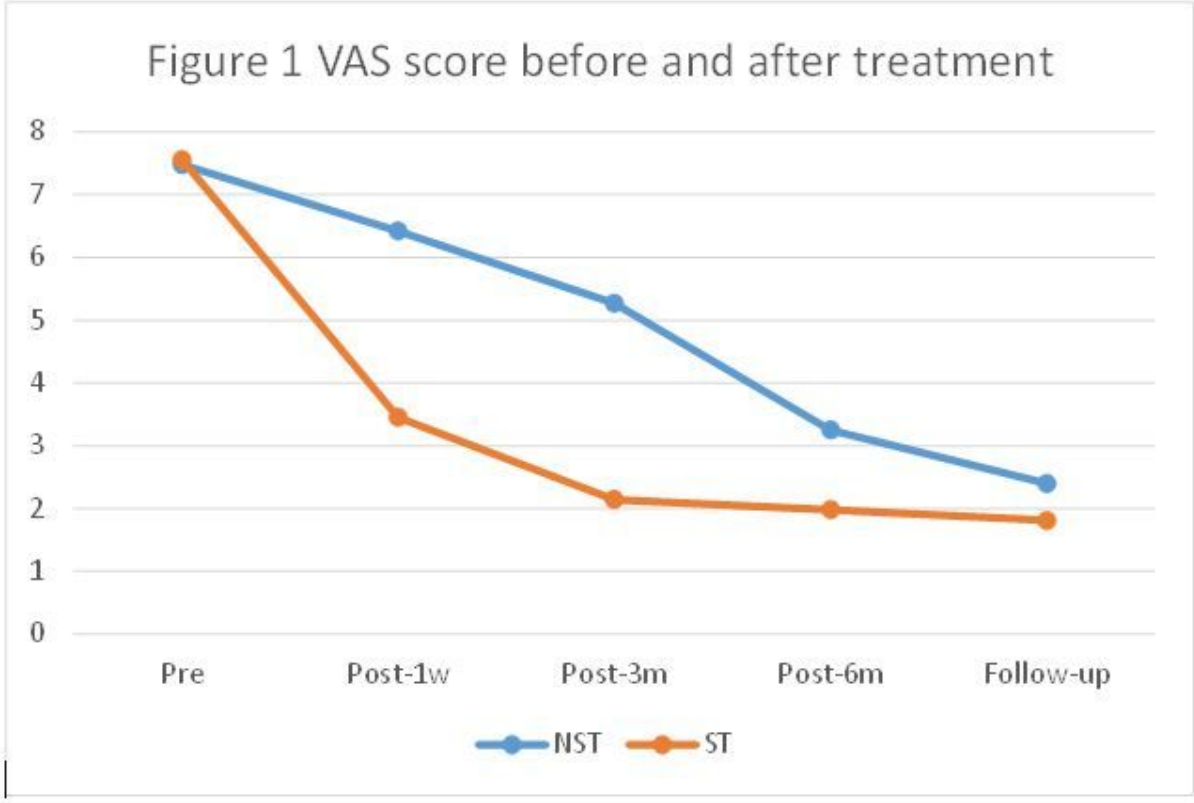

Figure 1

VAS Score before and after treatment

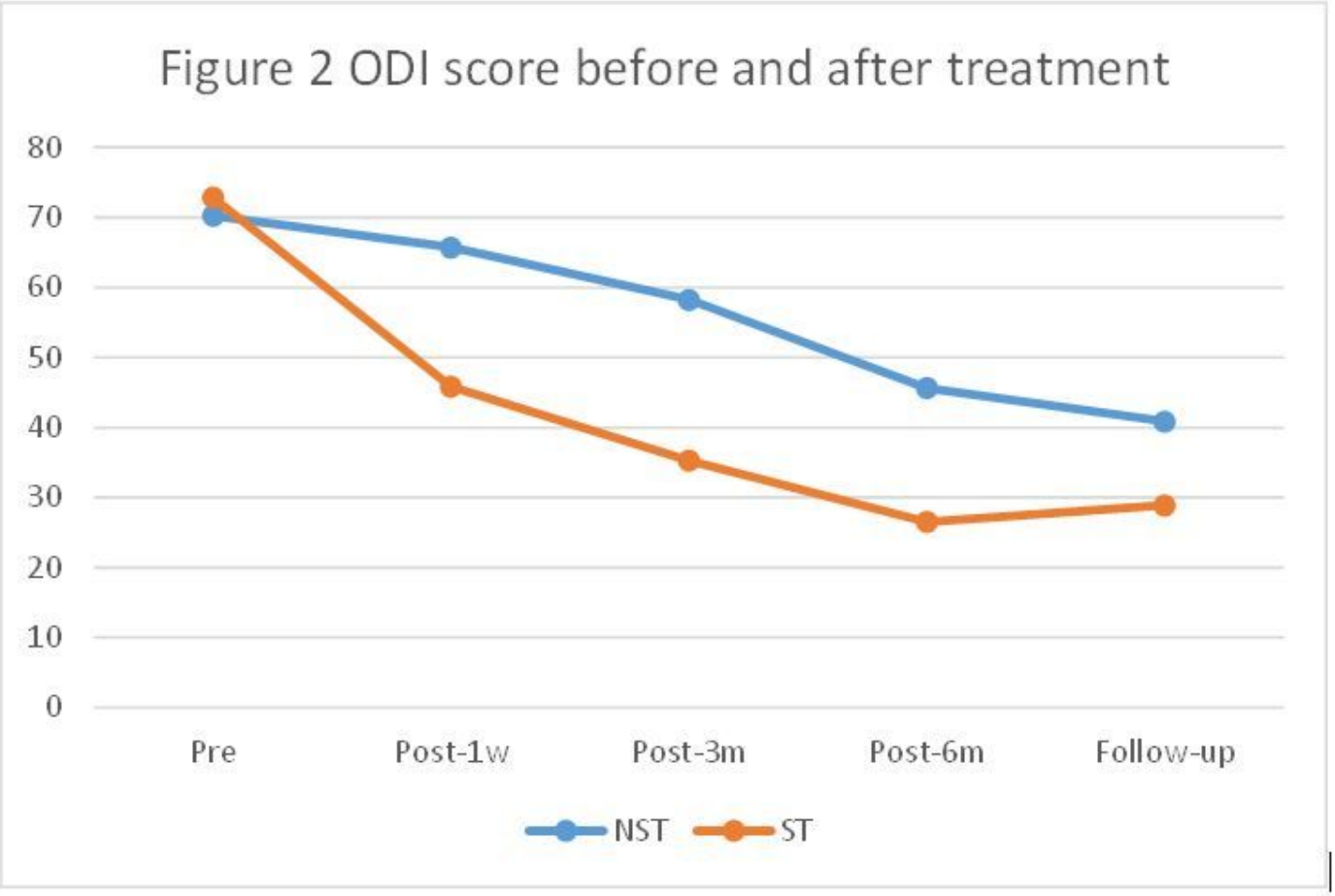

Figure 2

ODI score before and after treatment

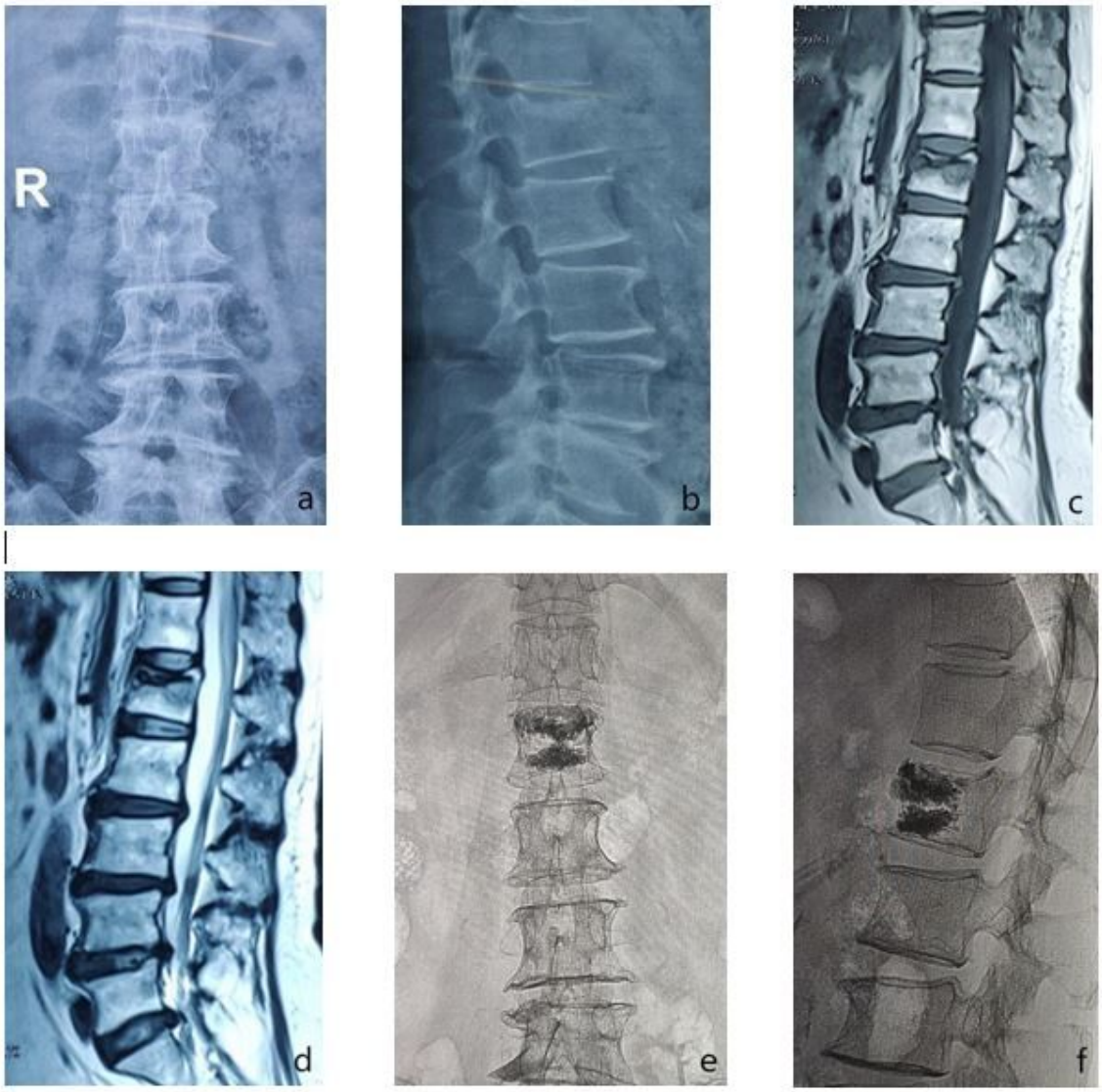

Figure 3

Patient, female, 65 years old, L1 osteoporotic vertebral compression fracture, ASTLOF score 4 points, PVP treatment. a, b X-rays of the front and back of the lumbar spine showed compression wedge deformation before treatment. c, d: Before treatment, MRI showed a low signal on T1WI and high signal on T2WI. e, f: After PVP of the injured vertebrae, X-ray film showed that the fracture was well reduced and the bone cement was filled well.