Prediction and applications of lymph nodes posterior to the right recurrent laryngeal nerve metastasis in patients with papillary thyroid carcinoma

Hai-Long Tan
Xiangya Hospital Central South University
Rooh-Afza Khushbu
Xiangya Hospital Central South University
Zheng-Tai Yuan
Hunan University of Chinese Medicine
Chen-Zhe Feng
Xiangya Hospital Central South University
Ya-Xin Zhao
Xiangya Hospital Central South University
Pei Chen
Xiangya Hospital Central South University
Hui-Yu Hu
Xiangya Hospital Central South University
Mian Liu
Xiangya Hospital Central South University
Deng-Jie Ou-Yang
Xiangya Hospital Central South University
Zi-en Qin
Xiangya Hospital Central South University
Peng Huang (xiangyahp@csu.edu.cn)
Xiangya Hospital Central South University https://orcid.org/0000-0003-3011-3359
Shi Chang
Xiangya Hospital Central South University

Research Article

Keywords: papillary thyroid carcinoma, LN-prRLN, central lymph node dissection, lymph node metastasis, risk factors

Posted Date: August 6th, 2021

DOI: https://doi.org/10.21203/rs.3.rs-784990/v1

Abstract

Purpose

Residues from the LN-prRLN are one of the main reasons for persistence or recurrence in patients with papillary thyroid carcinoma (PTC). However, the methods for preoperative assessment of LN-prRLN status, as well as the correlation with other clinicopathological features remains unclear.

Methods

Clinicopathological feature of 493 patients with PTC were retrospectively reviewed. Univariate and multivariate analyses were performed to identify the independent risk factors of LN-prRLN metastasis. The implications of positive LN-prRLN on right lateral lymph node and contralateral central lymph node metastasis were also investigated.

Results

Among the 493 patients, 343 (69.6%) was women and the average age was 39.06 ± 10.63 years old. Male sex, tumor size > 10 mm, extrathyroidal extension, the number of lymph nodes anterior to the right recurrent laryngeal nerve (LN-arRLN) metastasis ≥ 1, and right lateral lymph node metastasis (right-LLNM) were found as the independent risk factors of LN-prRLN metastasis in PTC. The prediction model based on those five factors performed better than the other forecast models. Moreover, positive LN-prRLN, male sex, microcalcifications, and tumor size > 10 mm significantly increases the risk of right-LLNM. Meanwhile, positive LN-prRLNand male sex will significantly increase the risk of con-CLNM.

Conclusions

LN-prRLN dissection should be recommended in patients with male sex, tumor size > 10 mm, extrathyroidal extension, the number of LN-arRLN metastasis ≥ 1, and present right-LLNM. Furthermore, when LN-arRLN metastasis has occurred, surgeons should be more alert to the possibility of right lateral lymph node and contralateral central lymph node metastasis.

Introduction

Thyroid carcinoma (TC) is one of the most rapidly increasing malignancies during the past 40 years worldwide, and the estimated incidence rate increased from 4.56 to 14.42 per 100,000 person-years between 1974–1977 and 2010–2013[1, 2]. Papillary thyroid carcinoma (PTC) is the most common pathological type of TC, which accounts for approximately 80%-90%[3]. Thyroidectomy with lymph nodes dissection (LND) is the main treatment of choice for PTC, but the correct management of nodal excision remains controversial[4]. Although PTC shows a favorable prognosis, and with an average 10-years

overall survival (OS) rate of around 90%, however, central lymph node metastasis (CLNM) has been proved to exist in 21–82% of PTC patients during the first treatment[5–7]. In addition, residual positive lymph nodes by negative lymph node dissection will increase the risk of recurrence and distant metastasis, which greatly affects the quality of life after surgery and increases the cost of retreatment again[8, 9]. Thus, complete lymph node dissection (LND) during the initial operation will help to improve the prognosis of patients with PTC.

Based on the physiological characteristics of specific anatomy of neck, central compartment is different between the left and right. According to American Thyroid Association (ATA), lymph nodes in central compartment consist of Delphian, pretracheal and paratrachea-esophageal lymph nodes[10]. Since the right recurrent laryngeal nerve is located in lymph nodes and fibrofatty tissues, the lymph nodes in the right central compartment are divided into two parts and labeled separately based on American Head and Neck Society (AHNS), including lymph nodes posterior to the right recurrent laryngeal nerve (LN-prRLN) and lymph nodes anterior to the right recurrent laryngeal nerve (LN-arRLN)[11], which is different from the left central compartment. Nowadays, it is controversial whether to dissect the LN-prRLN, as relatively lower prevalence of LN-prRLN metastasis and higher morbidities such as recurrent laryngeal nerve injury has been observed during the operation[12–15]. Accurate preoperative and intraoperative evaluation of LN-prRLN metastasis will definitely help in determining the extent of CLND, thereby reducing the risk of residual positive lymph nodes and surgery-related complications. However, the ability to evaluate the status of LN-prRLN is limited.

Few studies have found some relationship between the clinicopathological characteristics and status of LN-prRLN, but the application was limited due to insufficient study individuals and shortage of genetic background[16]. Our previous study has found $BRAF^{V600E}$ mutation was the independent predictors of LNM in PTC[17]. Given these data, in this study 493 PTC patients were divided into LN-prRLN metastasis positive and LN-prRLN metastasis negative groups according to the status of LN-prRLN from postoperative histopathologic records, and identify the risk factors associated with LN-prRLN metastasis in PTC by investigating preoperative clinicopathological and $BRAF^{V600E}$ status retrospectively. In addition to this, our study also evaluated the association between LN-prRLN and right lateral lymph node metastasis (right-LLNM) and contralateral central lateral lymph node metastasis (con-CLNM), proposed to guide surgical decision making.

Materials And Methods

- Patients and study design

This study was approved by the Ethics Review Committee of Xiangya Hospital, Central South University and all patients gave written informed consent for research prior to surgery. We enrolled the patients who underwent thyroid surgery between January 2015 and June 2021 at the department of general surgery, Xiangya hospital, central south university. The inclusion criteria were: pathologically proven PTC located in the right lobe, patients underwent thyroidectomy and lymph node dissection (LND). Patients will be

excluded if they with any of the following conditions: mixed thyroid carcinomas, history of thyroid surgery, distant metastasis, unknown LN-prRLN status, and incomplete clinical information. Finally, totally 493 patients with PTC were enrolled in this study.

- Surgical strategy

Total thyroidectomy (TT) was performed for bilateral PTC or unilateral PTC patients with tumor size > 1 cm, extrathyroidal extension (ETE), or regional suspicious LN metastasis detected during preoperative or intraoperative examination (cN1), according to the ATA management guidelines[10]. We also performed thyroidectomy for papillary thyroid microcarcinoma (PTMC) patients with unfavorable features (age < 45 years, multifocality, ETE and tumor size > 0.5 cm) for lymph nodes metastasis based on the patient's wishes[18, 19]. We routinely perform at least ipsilateral CLND for unilateral PTC patients. For bilateral PTC patients, cN1 patients, and locally advanced tumor (T3/T4), bilateral CLND will be performed. Therapeutic lateral lymph nodes dissection (LLND) was done only for patients with clinically suspicious lateral LN metastasis which was confirmed by fine needle aspiration biopsy and/or US, CT before surgery[10]. All surgical procedures performed by one surgical team.

The neck central compartment was bounded superiorly by the hyoid bone, inferiorly by the suprasternal notch, laterally by the carotid artery, medially by midline of trachea, and dorsally by the prevertebral fascia. In the right central compartment, the paratrachea-esophageal lymph nodes posterior to the right recurrent laryngeal nerve were marked as paraesophageal lymph nodes also known as LN-prRLN, and the paratrachea-esophageal lymph nodes anterior to the right recurrent laryngeal nerve were marked as paratracheal lymph nodes. After surgery completed, surgeons subdivided the right central lymph node into Delphian, pretracheal, paratracheal, and LN-prRLN groups depending on the anatomical location. Furthermore, pretracheal and paratracheal lymph nodes were labeled as LN-arRLN.

- Clinicopathological characteristics evaluation

The clinicopathological characteristics include age at diagnosis, gender, $BRAF^{V600E}$ mutation, hashimoto's thyroiditis (HT), tumor size and location in the right lobe, capsule invasion and ETE of the primary lesion in the right lobe, and LN metastasis status. Multifocality is defined as two or more lesions in the right lobe regardless of bilateral tumors. Tumor size was calculated as the largest tumor diameter in the right lobe. Capsular invasion and ETE was evaluated by intraoperative gross and pathological findings. Other clinical features include preoperative sonographic characteristics of the primary lesion in the right lobe such as echogenicity, composition, shape, margin, microcalcifications and oval.

Statistical analysis

Statistical analyses were performed by SPSS 26.0 (IBM SPSS, Inc. Chicago, IL, USA). Continuous variables were presented as mean ± standard deviation (SD) while categorical variables were presented as the number of cases, percentages (%). The continuous variables used Student’s *t*-test to compare differences whereas the categorical variables used chi-square test Fisher’s exact test to compare

differences. Univariate and multivariate analysis were used to determine the independent predictors of LN-prRLN metastasis. Subsequently, the prediction model was developed based on the independent predictors. The area under the receiver operating characteristic curve (AUC) was used to assess the discrimination ability between the present model in our study with other models. p-value < 0.05 was considered as statistically significant.

Results

- Clinicopathological characteristics of the PTC patients

As summarized in (Table 1), 343 women (69.6%) and 150 men (30.4%) (female: male was 2.3:1) were included in the study, with a mean age of 39.06 ± 10.63 years (rang, 16 to 72) at diagnosis of PTC and 449 (91.1%) were younger than 55 years. The $BRAF^{V600E}$ positivity rate among these patients was 80.7%. The mean tumor size was 13.26 ± 9.08 mm and 237 (48.1%) patients were with the tumor size ≤ 10 mm. In addition, HT, multifocality, bilateral tumor, capsular invasion, and ETE were found in 176 (35.7%), 84 (17.0%), 114 (23.1), 208 (42.2%), 138 (28.0%) patients respectively.

Table 1
Demographics and clinicopathological characteristics of 493 papillary thyroid carcinoma patients

Characteristic	Number (%)
No. of patients	493 (100)
Sex	
Male / Female	150 (30.4) / 343 (69.6)
Age (mean ± SD, years)	39.06 ± 10.63
≥ 55 / < 55	44 (8.9) / 449 (91.1)
Tumor size (mean ± SD, mm)	13.26 ± 9.08
≤ 10 / > 10	237 (48.1) / 256 (51.9)
Hashimoto's thyroiditis	
Yes / No	176 (35.7) / 317 (64.3)
$BRAF^{V600E}$ mutation	
Positive / Negative	398 (80.7) / 95 (19.3)
Multifocality	
Yes / No	84 (17.0) / 409 (83.0)
Bilateral tumor	
Yes / No	114 (23.1) / 379 (76.9)
Location of right tumor	
Superior lobe	112 (22.7)
Middle lobe	253 (51.3)
Inferior lobe	128 (26.0)
Capsular invasion	
Present / Absent	208 (42.2) / 285 (57.8)
ETE	
Present / Absent	138 (28.0) / 355 (72.0)
cN0 / cN1	331 (67.1) / 162 (32.9)
Con-CLNM (in right tumor only)	40 (50.6)
Right-CLNM	280 (56.8)

Characteristic	Number (%)
LN-prRLN metastasis	158 (56.4)
Only LN-arRLN metastasis	122 (43.6)
Number of right-CLNM (mean ± SD, range)	
LN-arRLN	3.22 ± 2.50 (1–16)
LN-prRLN	2.78 ± 2.10 (1–15)
Right-LLNM	144 (29.2%)

Abbreviations: CLNM, central lymph node metastasis; Con-CLNM, contralateral central lymph node metastasis; cN0, clinical lymph node negative; cN1, clinical lymph node positive; ETE, extrathyroidal extension; LN-arRLN, lymph node anterior to the right recurrent laryngeal nerve; LN-prRLN, lymph nodes posterior to the right recurrent laryngeal nerve; Right-CLNM, right central lymph node metastasis; Right-LLNM, right lateral lymph node metastasis; SD, standard deviation.

In this study, 331 (67.1%) cN0 patients and 162 (32.9) cN1 patients was recruited and with 280 (56.8%) patients were pathologically confirmed having right central lymph node metastasis (right-CLNM), of which 158 (56.4%) patients with LN-prRLN metastasis. Out of the 79 unilateral PTC patients that underwent bilateral CLND, 40 (50.6%) have contralateral CLNM (con-CLNM). Moreover, in this study, only 144 (29.2%) patients were found with pathologically confirmed right lateral lymph node metastasis (right-LLNM).

- Association between clinicopathological characteristics and positive LN-prRLN

Univariate analysis revealed that male patient ($p < 0.001$), oval ($p = 0.002$), microcalcifications ($p = 0.001$), Capsular invasion ($p < 0.001$), ETE ($p < 0.001$), tumor size ($p < 0.001$), positive LN-arRLN ($p < 0.001$), and right-LLNM ($p < 0.001$) were significantly associated with positive LN-prRLN. However, age, HT, $BRAF^{V600E}$ mutation, multifocality, bilateral tumor, location of right tumor, and sonographic features including solid composition, hypoechogenicity, irregular shape, and poorly marginal were found with not significantly associated with positive LN-prRLN ($p > 0.05$) (Table 2).

Table 2
Univariate and multivariate analysis of clinicopathological characteristics correlated with LN-prRLN metastasis in papillary thyroid carcinoma patients

Characteristics	**Univariate**				**Multivariate**	
	Total (n = 493) (%)	**LN-prRLN metastasis (+) (n = 158) (%)**	**LN-prRLN metastasis (-) (n = 335) (%)**	**p**	**OR (95%CI)**	**p**
Age < 55	449 (91.1)	145 (91.8)	304 (90.7)	0.709[a]		
Male	150 (30.4)	74 (46.8)	76 (22.7)	**< 0.001[a]**	1.978 (1.103–3.549)	**0.022**
Hashimoto's thyroiditis	176 (35.7)	53 (33.5)	123 (36.7)	0.493[a]		
$BRAF^{V600E}$ mutation	398 (80.7)	129 (81.6)	269 (80.3)	0.723[a]		
Sonographic Characteristics						
Solid composition	491 (99.6)	157 (99.4)	334 (99.7)	0.999[c]		
Hypoechogenic	455 (92.3)	141 (89.2)	314 (93.7)	0.081[a]		
Irregular shape	385 (78.1)	122 (77.2)	263 (78.5)	0.746[a]		
Poorly marginal	327 (66.3)	110 (69.6)	217 (64.8)	0.288[a]		
Oval	138 (28.0)	30 (19.0)	108 (32.2)	**0.002[a]**	1.321 (0.661–2.640)	0.431
Microcalcifications	395 (80.1)	140 (88.6)	255 (76.1)	**0.001[a]**	0.702 (0.328–1.502)	0.361
Pathological characteristics						
Multifocality	84 (17.0)	31 (19.6)	53 (15.8)	0.295[a]		
Bilateral tumor	114 (23.1)	44 (27.8)	70 (20.9)	0.088[a]		
Location of right tumor						

Characteristics	Univariate				Multivariate	
	Total (n = 493) (%)	LN-prRLN metastasis (+) (n = 158) (%)	LN-prRLN metastasis (-) (n = 335) (%)	p	OR (95%CI)	p
Inferior lobe	128 (26.0)	31 (19.6)	97 (29.0)	0.054[a]		
Middle lobe	253 (51.3)	84 (53.2)	169 (50.4)			
Superior lobe	112 (22.7)	43 (27.2)	69 (20.6)			
Capsular invasion	208 (42.2)	90 (57.0)	118 (35.2)	**< 0.001[a]**	2.119 (0.861–5.216)	0.102
ETE	138 (28.0)	77 (48.7)	61 (18.2)	**< 0.001[a]**	3.558 (1.366–9.265)	**0.009**
Tumor size (mm)	13.26 ± 9.08	19.03 ± 10.45	10.54 ± 6.85	**< 0.001[b]**		
Diameter > 10	256 (51.9)	130 (82.3)	126 (37.6)	**< 0.001[a]**	2.375 (1.223–4.614)	**0.011**
Pathologically confirmed LN metastasis						
LN-arRLN	272 (55.2)	150 (94.9)	122 (36.4)	**< 0.001[a]**		
Right-LLNM	144 (29.2)	113 (71.5)	31 (9.3)	**< 0.001[a]**	8.780 (4.789–16.097)	**< 0.001**
LN-arRLN metastasis						
The number ≥ 1	272 (55.2)	150 (94.9)	122 (36.4)	**< 0.001[a]**	14.488 (6.402–32.788)	**< 0.001**

Note: Variables with statistical significance were shown in bold. [a]Chi-square test, [b]Student's t test and [c]Fisher's exact test were adopted.

Abbreviations: ETE, extrathyroidal extension; LN-arRLN, lymph node anterior to the right recurrent laryngeal nerve; LN-prRLN, lymph nodes posterior to the right recurrent laryngeal nerve; OR, odds ratio; Oval, taller than wide; Right-LLNM, right lateral lymph node metastasis; SD, standard deviation; 95% CI, 95% confidence interval.

It is worth noting that both tumor size and the number of positive LN-arRLN were positively correlated with the risk of positive LN-prRLN in patients with PTC (R^2 = 0.9652, $p < 0.001$; R^2 = 0.9109, $p < 0.001$, respectively) (Fig. 1a and 1b). Based on the receiver operating characteristic curve (ROC) analysis, we found that the number of positive LN-arRLN and tumor size were the well predictors for positive LN-prRLN (Fig. 1c). In our results, the area under the receiver operating characteristic curve (AUC) of number of positive LN-arRLN in positive LN-prRLN group was 0.853 (the optimal cutoff value = 1, 95% CI: 0.818–0.887), indicating that the accuracy of the test was good, which means the number of positive LN-arRLN ≥ 1 was a well predictor of positive LN-prRLN (Fig. 1c). The optimal cutoff value of tumor size in positive LN-prRLN group was defined as 10.05 mm (AUC = 0.779, 95% CI: 0.635–0.824) and means PTC patients with tumor size > 10 mm was at high risk for positive LN-prRLN (Fig. 1c).

To investigate the independent risk factors for positive LN-prRLN, binary logistic regression analyasis was performed. Our results indicated that male sex (OR = 1.978, $p < 0.05$), ETE (OR = 3.558, $p < 0.05$), tumor size > 10 mm (OR = 2.375, $p < 0.05$), presence of right-LLNM (OR = 8.780, $p < 0.001$), and the number of metastatic LN-arRLN ≥ 1 (OR = 14.488, $p < 0.001$) were the independent risk factors for positive LN-prRLN. However, no significant relationship was observed among oval, microcalcifications, capsular invasion and positive LN-prRLN ($p > 0.05$) (Table 2).

- Evaluation and comparison of predictive models with previous reported models for positive LN-prRLN

Based on the independent risk factors by binary analyses, a predictive model for positive LN-prRLN was developed. In our study, the AUC of the present model was 0.915, with Youden index of 0.672, sensitivity of 79.7%, specificity of 87.5%, positive predictive value of 86.4% and a negative predictive value of 81.2%. As several predictive models for positive LN-prRLN were reported in previous studies, we summarized the characteristics of these different models in Supplemental Table 1. In order to verify the superiority of the present model, and to compare the predictive ability between different models, the concordance index (C-index) was assessed by ROC curve. Our results showed that the AUC of our present model was the largest (AUC = 0.915), which means the present model was more appropriate in predicting positive LN-prRLN. In addition, net reclassification improvement index (NRI) was performed to quantify improvements in predictive performance of present model relative to other models. We found that adopt the present model resulted in significant improvement in reclassification for predict positive LN-prRLN (NRI > 0, all) (Fig. 2). Other parameters related to the diagnostic value were summarized in Supplemental Table 1.

- Association between positive LN-prRLN and right-LLNM

Considering specific anatomy of the neck, the paratrachea-esophageal lymph nodes in the right central compartment are divided into two sections and labeled separately as LN-prRLN and LN-arRLN. Wherefore, we analyzed the predictive performance for right-LLNM among the number of right-CLNM, positive LN-arRLN, and positive LN-prRLN separately, and then found that the AUC of the number of positive LN-prRLN was the largest (AUC = 0.818) (see supplemental Fig. 1a), which means the positive LN-prRLN was

more accurate in predicting right-LLNM. In this cohort study, right-LLNM was found in 144 (29.2%) patients. In univariate analysis, we found male sex ($p < 0.001$), oval ($p < 0.001$), microcalcifications ($p < 0.001$), location of right tumor ($p < 0.05$), capsular invasion ($p < 0.001$), ETE ($p < 0.001$), tumor size > 10 mm ($p < 0.001$), and positive LN-prRLN ($p < 0.001$) were significantly associated with right-LLNM (Table 3). However, age, HT, $BRAF^{V600E}$ mutation, multifocality, bilateral tumor, and sonographic features such as solid composition, hypoechogenicity, irregular shape, and poorly marginal were found with not significantly associated with positive LN-prRLN ($p > 0.05$). In the multivariate analysis, male sex (OR = 2.011, $p < 0.05$), microcalcifications (OR = 4.174, $p < 0.05$), tumor size > 10 mm (OR = 3.527, $p < 0.001$), and positive LN-prRLN (OR = 14.345, $p < 0.001$) were independent predictors of right-LLNM.

Table 3
Associations between clinicopathological characteristics and right-LLNM metastasis in papillary thyroid carcinoma patients

Characteristics	**Univariate**				**Multivariate**	
	Total (n = 493) (%)	**Right-LLNM metastasis (+) (n = 144) (%)**	**Right-LLNM metastasis (-) (n = 349) (%)**	**p**	**OR (95%C)**	**p**
Age < 55	449 (91.1)	134 (93.1)	315 (90.3)	0.322[a]		
Male	150 (30.4)	68 (47.2)	82 (23.5)	**< 0.001[a]**	2.011 (1.130–3.577)	**0.017**
Hashimoto's thyroiditis	176 (35.7)	48 (33.3)	128 (36.7)	0.481[a]		
$BRAF^{V600E}$ mutation	398 (80.7)	113 (78.5)	285 (81.7)	0.414[a]		
Sonographic Characteristics						
Solid composition	491 (99.6)	144 (100.0)	347 (99.4)	0.896[c]		
Hypoechogenic	455 (92.3)	128 (88.9)	327 (93.7)	0.069[a]		
Irregular shape	385 (78.1)	119 (82.6)	266 (76.2)	0.117[a]		
Poorly marginal	327 (66.3)	99 (68.8)	228 (65.3)	0.465[a]		
Oval	138 (28.0)	21 (14.6)	117 (33.5)	**< 0.001[a]**	0.518 (0.256–1.050)	0.068
Microcalcifications	395 (80.1)	135 (93.8)	260 (74.5)	**< 0.001[a]**	4.174 (1.590-10.956)	**0.004**
Pathological characteristics						
Multifocality	84 (17.0)	28 (19.4)	56 (16.0)	0.361[a]		
Bilateral tumor	114 (23.1)	37 (25.7)	77 (22.1)	0.385[a]		
Location of right tumor						

Characteristics	Univariate				Multivariate	
	Total (n = 493) (%)	Right-LLNM metastasis (+) (n = 144) (%)	Right-LLNM metastasis (-) (n = 349) (%)	p	OR (95%C)	p
Inferior lobe	128 (26.0)	28 (19.4)	100 (28.7)	**0.042**[a]	Reference	0.216
Middle lobe	253 (51.3)	75 (52.1)	178 (51.0)		1.079 (0.534–2.180)	0.832
Superior lobe	112 (22.7)	41 (28.5)	71 (20.3)		1.836 (0.835–4.035)	0.131
Capsular invasion	208 (42.2)	87 (60.4)	121 (34.7)	**< 0.001**[a]	1.357 (0.576–3.198)	0.486
ETE	138 (28.0)	72 (50.0)	66 (18.9)	**< 0.001**[a]	1.250 (0.501–3.120)	0.632
Tumor size (mm)	13.26 ± 9.08	19.03 ± 10.45	10.54 ± 6.85	**< 0.001**[b]		
Diameter > 10	256 (51.9)	125 (86.8)	131 (37.5)	**< 0.001**[a]	3.527 (1.810–6.871)	**< 0.001**
Pathologically confirmed LNM						
LN-prRLN	158 (32.0)	113 (78.5)	45 (12.9)	**< 0.001**[a]	14.345 (8.136–25.293)	**< 0.001**

Note: Variables with statistical significance were shown in bold. [a]Chi-square test, [b]Student's t test and [c]Fisher's exact test were adopted.

Abbreviations: ETE, extrathyroidal extension; LN-arRLN, lymph node anterior to the right recurrent laryngeal nerve; LN-prRLN, lymph nodes posterior to the right recurrent laryngeal nerve; OR, odds ratio; Oval, taller than wide; Right-LLNM, right lateral lymph node metastasis; 95% CI, 95% confidence interval.

- Association between positive LN-prRLN and con-CLNM

Again, according to specific anatomy of the neck, we analyzed the predictive performance for con-CLNM among the number of right-CLNM, positive LN-arRLN, and positive LN-prRLN separately, and then found that the AUC of the number of positive LN-prRLN was the largest (AUC = 0.828) (see supplemental Fig. 1b), which means the positive LN-prRLN was more accurate in predicting con-CLNM. In our study, 40

(50.6%) con-CLNM was found in 79 right-PTC patients with unilateral lobe lesion performed bilateral CLND because those unfavorable features of ETE, or right-LLNM. In the univariate analysis, male sex ($p < 0.001$), ETE ($p < 0.05$), tumor size > 10 mm ($p < 0.05$), positive LN-prRLN ($p < 0.001$) and right-LLNM ($p < 0.001$) were significantly associated with con-CLNM (Table 4). However, age, HT, $BRAF^{V600E}$ mutation, multifocality, location of right tumor, capsular invasion, and sonographic features like solid composition, hypoechogenic, irregular shape, poorly marginal, oval, and microcalcifications were found with not significantly associated with con-CLNM ($p > 0.05$). In the multivariate analysis, we determined male sex (OR = 4.367, $p < 0.05$), positive LN-prRLN (OR = 21.134, $p < 0.001$) were independent predictors of con-CLNM.

Table 4
Associations between clinicopathological characteristics and con-CLNM metastasis in papillary thyroid carcinoma patients

Characteristics	**Univariate**				**Multivariate**	
	Total (n = 79) (%)	**Con-CLNM metastasis (+) (n = 40) (%)**	**Con-CLNM metastasis (-) (n = 39) (%)**	**p**	**OR (95%C)**	**p**
Age < 55	78 (98.7)	40 (100.0)	38 (97.4)	0.990[c]		
Male	25 (31.6)	20 (50.0)	5 (12.8)	**< 0.001[a]**	4.367 (1.115–17.100)	**0.034**
Hashimoto's thyroiditis	41 (51.9)	17 (42.5)	24 (61.5)	0.090[a]		
$BRAF^{V600E}$ mutation	52 (65.8)	26 (65.0)	26 (66.7)	0.876[a]		
Sonographic Characteristics						
Solid composition	78 (98.7)	40 (100.0)	38 (97.4)	0.990[c]		
Hypoechogenic	73 (92.4)	36 (90.0)	37 (94.9)	0.695[c]		
Irregular shape	66 (83.5)	36 (90.0)	30 (76.9)	0.117[a]		
Poorly marginal	60 (75.9)	30 (75.0)	30 (76.9)	0.842[a]		
Oval	18 (22.8)	7 (17.5)	11 (28.2)	0.257[a]		
Microcalcifications	72 (91.1)	37 (92.5)	35 (89.7)	0.972[c]		
Pathological characteristics						
Multifocality	15 (19.0)	11 (27.5)	4 (10.3)	0.051[a]		
Location of right tumor						
Superior lobe	9 (11.4)	6 (15.0)	3 (7.7)	0.460[c]		
Middle lobe	54 (68.4)	25 (62.5)	29 (74.4)			

Characteristics	Univariate				Multivariate	
	Total (n = 79) (%)	Con-CLNM metastasis (+) (n = 40) (%)	Con-CLNM metastasis (-) (n = 39) (%)	p	OR (95%C)	p
Inferior lobe	16 (20.3)	9 (22.5)	7 (17.9)			
Capsular invasion	48 (60.8)	27 (67.5)	21 (53.8)	0.214[a]		
ETE	37 (46.8	24 (60.0)	13 (33.3)	**0.018[a]**	1.619 (0.455–5.764)	0.457
Tumor size (mm)	13.08 ± 9.00	20.40 ± 9.57	17.62 ± 10.82	0.231[b]		
Diameter > 10	67 (84.8)	38 (95.0)	29 (74.4)	**0.011[a]**	1.008 (0.455–5.764)	0.457
Pathologically confirmed LN metastasis						
LN-prRLN	51 (64.6)	38 (95.0)	13 (33.3)	**< 0.001[a]**	21.134 (3.397-131.491)	**< 0.001**
Right-LLNM	51 (64.6)	34 (85.0)	17 (43.6)	**< 0.001[a]**	1.566 (0.314–7.808)	0.584

Note: Variables with statistical significance were shown in bold. [a]Chi-square test, [b]Student's t test and [c]Fisher's exact test were adopted.

Abbreviations: Con-CLNM, Contralateral central lymph node metastasis; ETE, extrathyroidal extension; LN-arRLN, lymph node anterior to the right recurrent laryngeal nerve; LN-prRLN, lymph nodes posterior to the right recurrent laryngeal nerve; OR, odds ratio; Oval, taller than wide; Right-LLNM, right lateral lymph node metastasis; 95% CI, 95% confidence interval.

Discussion

Generally, central LNs are the first and the most commonly involved regions, and the relationship between insufficient CLND after initial surgery and the recurrence in PTC patients has been well proved[9, 20]. Since LN-prRLN metastasis is not common, the decision regarding the appropriate range of CLND should take into consideration both for the reduction of local recurrence and the incidence of postoperative complications. Besides, reoperation may increase patient's postoperative complications[21]. However, the predictors for LN-prRLN metastasis remains unclear. Consequently, it is imperative to identify patients with high risks of positive LN-prRLN for surgeons to choose the most appropriate operative approach. In

the present study, we are the first to evaluate risk factors of LN-prRLN metastasis in PTC based on clinicopathological characteristics and genetic background, and identified four independent risk factors significantly associated with LN-prRLN metastasis which are male sex, ETE, tumor size > 10 mm, the number of LN-arRLN metastasis and present right-LLNM.

In our study, the incidence of LN-prRLN metastasis was 32.0%, which was slightly higher than previous studies reporting LN-prRLN metastasis rates of 11-26.7%[13, 14], because of we recruited some PTC patients with clinical lymph nodes positive. Moreover, we observed the risk of LN-prRLN metastasis in male was 1.978 times higher compared to female, which also matches with previous studies[13]. In addition, LN-prRLN metastasis accruing to 56.4% patients with CLNM and 71.5% patients with LLNM, which was close to the previously reported results[22, 23]. It is worth noting that 94.9% (150/158) of patients with LN-prRLN metastasis simultaneous with pathologically confirmed LN-arRLN metastasis. Thus, complete CLND including LN-prRLN was necessary for PTC patients when any evidence of LN-arRLN metastasis existed.

Ultrasonography (US) and computed tomography (CT) are the primary examination for lymphadenopathy. Zou M et al. found that US-detected lateral compartment lymph node metastasis (LLNM) was the independent risk factors of LN-prRLN metastasis[23]. However, owing to its anatomically deep position, emerging studies indicated that both the sensitivity of ultrasonography and computed tomography are not sufficient enough to directly detect LNM in the central compartment[24], especially for LN-prRLN metastasis. Other sonographic characteristics like microcalcifications were reported as significantly related to positive LN-prRLN[23]. However, in our results, all sonographic characteristics including solid composition, hypoechogenicity, irregular shape, poorly marginal, oval, microcalcifications were defined as not an independent risk factor for positive LN-prRLN.

Tumor size played an important role in LN-prRLN metastasis and was indicated as an independent risk factor of LN-prRLN metastasis in almost all reported models[12, 22, 23, 25–27]. In our study, we found that tumor size is positively correlated with LN-prRLN metastasis, and tumor size > 10mm was an independent predictor for LN-prRLN metastasis. Consistent with our research result, the relationship also has been well proved by Wang Y. et al, Zou M. et al, and Luo Y. et al[23, 25, 26]. Therefore, tumor size significantly increased the prevalence of LN-prRLN metastasis in PTC patients.

Few researchers have examined metastasis in patients with PTC and taken the genetic background into consideration. $BRAF^{V600E}$ mutation is the most common oncogenic mutation of PTC and occurring in nearly 45% of cases[28]. Our previous study found that $BRAF^{V600E}$ mutation was significantly related to lymph node metastasis, and was a protective factor for Level V LNM in PTC patients[17]. In this study, $BRAF^{V600E}$ mutation occurring to 81.6% patients with LN-prRLN metastasis. However, we didn’t find any significant relationship between $BRAF^{V600E}$ mutation and LN-prRLN metastasis.

For other pathological features such as ETE, capsular invasion, multifocality and bilateral tumor were also reported as the independent risk factor of LN-prRLN metastasis based on the Chinese population[26,

27]. However, in our results, capsular invasion, multifocality and bilateral tumor were defined as not associate with positive LN-prRLN. Consistent with previous reports, we found that ETE was an independent risk factor for LN-prRLN metastasis. Furthermore, we summarized all reported models for predicting LN-prRLN metastasis. Surprisingly, in the seven predictive models that have been reported, there is no common risk factor. In order to further testify its superiority, we compared the predictive performance of the present model with all reported models based on the AUC (C-index) and net reclassification improvement index (NRI). Our results showed that the AUC of the present models was the largest (AUC = 0.915) and the NRI shows significant improvement in reclassification relative to others (NRI > 0, all), which means the present model demonstrates the excellent performance and can be effectively used to discriminate the LN-prRLN metastasis.

Similarly, we confirmed that the positive LN-prPLN shows a significant correlation with right-LLNM and con-CLNM, relative to right-CLNM and positive LN-arPLN. Consistent with our results, a number of recent studies have reported that the ipsilateral CLNM was an independent predictor for ipsilateral LLNM and con-CLNM in PTC patients[29–31]. However, there is no study which stated the association among LN-prRLN metastasis with right-LLNM and con-CLNM. In this study, the prevalence of right-LLNM was 144 (29.2%), that is consistent with results from other studies[32]. Out of the 79 patients underwent bilateral CLND, 40 (50.6%) have LNM in the contralateral central compartment. This comparatively higher incidence of con-CLNM in our study could be explained by the following reason, most of bilateral CLND was performed for these advanced PTC patients (T3/T4) and clinically involved lateral neck lymph nodes (cN1b). In our study, we observed that approximately 78.5% PTC patients with positive LN-prRLN accompanied by right-LLNM, which was 14.35 times higher than in negative LN-prRLN patients. In addition, approximately 95.0% PTC patients with positive LN-prRLN accompanied by con-CLNM, which was 21.13 times higher than in negative LN-prRLN patients. Our study firstly found that LN-prRLN metastasis has a considerable relationship with right-LLNM and con-CLNM, which means LN-prRLN metastasis can indicate that the higher risk of right-LLNM and con-CLNM.

There are some limitations to this study, including the inherent design flaws due to its nonrandomized retrospective study. Besides, although we determine the risk factors for LN-prRLN metastasis in our study, we still cannot be sure whether or not routine LN-prRLN dissection can improve the prognosis of patients with PTC, further studies with longer follow-up periods from multicenter is needed.

Conclusion

LN-prRLN metastasis is an independent predictor of right lateral lymph node metastasis and contralateral central lymph node metastasis, LN-prRLN dissection should be recommended in patients with male sex, ETE, tumor size > 10 mm, the number of LN-arRLN metastasis ≥ 1, and present right-LLNM.

Declarations

Funding

This work was supported by the National Natural Science Foundation of China (grant numbers 81974423, 81902729), the Key Research and Development Program of Hunan Province (grant number 2019SK2031), the China Postdoctoral Science Foundation (grant number 2020M672517, 2021T140749), the Natural Science Foundation of Hunan Province (grant number 2020JJ5904), and the Xiangya Hospital Foundation for Young Scholars (grant number 2018Q01).

Competing Interests

The authors declare that the research was conducted in the absence of any commercial or financial relationship that could be construed as a potential conflict of interests.

Availability of data and material

The datasets analyzed during the current study can be obtained from the corresponding author on reasonable request.

Acknowledgments

We wish to thank all the patients who participated in this study.

Authors' contributions

Study concepts (HLT, RAK). Study design (HLT, PH, SC). Data acquisition (HLT, ZTY, and YXZ). Quality control of data and algorithms (HYH, PH, and SC). Data analysis and interpretation (CZF, PC). Statistical analysis (HLT, ML). Manuscript preparation (DJOY, and RAK). Manuscript editing (HLT, PH). Manuscript review (PH, and SC). All authors contributed to the article and approved the submitted version.

Ethics approval

The studies involving human participants were reviewed and approved by the Ethics Committee of Xiangya Hospital, Central South University (2019030440). The patients/participants provided their written informed consent to participate in this study.

Consent to participate

All of participants patients gave written informed consent for this research.

Consent for publication

All authors gave consent for publication of this study.

Abbreviations

AHNS, American Head and Neck Society; ATA, American Thyroid Association; AUC, the area under the receiver operating characteristic curve; CLNM, central lymph node metastasis; CLND, central lymph node dissection; Con-CLNM, contralateral central lymph node metastasis; CI, confidence interval; C-index, concordance index; CT, computed tomography; ETE, extrathyroidal extension; HT, hashimoto's thyroiditis; LND, lymph nodes dissection; LLND, lateral lymph nodes dissection; LNM, lymph node metastasis; LN-arRLN, lymph nodes anterior to the right recurrent laryngeal nerve; LN-prRLN, lymph node posterior to the right recurrent laryngeal nerve; NPV, negative predictive value; NRI, net reclassification improvement index; OR, odds ratio; OS, overall survival; PTC, papillary thyroid carcinoma; PTMC, papillary thyroid microcarcinoma; PPV, positive predictive value; RLN, recurrent laryngeal nerve; Right-LLNM, right lateral lymph node metastasis; ROC, receiver operating characteristic curve; SD, Standard Deviation; TC, thyroid carcinoma; TT, total thyroidectomy; US, ultrasonography.

References

1. H. Lim, S.S. Devesa, J.A. Sosa et al., Trends in Thyroid Cancer Incidence and Mortality in the United States, 1974–2013. JAMA **317**(13), 1338–1348 (2017). doi:10.1001/jama.2017.2719
2. A.E. Powers, A.R. Marcadis, M. Lee et al., Changes in Trends in Thyroid Cancer Incidence in the United States, 1992 to 2016. JAMA **322**(24), 2440–2441 (2019). doi:10.1001/jama.2019.18528
3. M.E. Cabanillas, D.G. McFadden, C. Durante, Thyroid cancer. Lancet **388**(10061), 2783–2795 (2016). doi:10.1016/S0140-6736(16)30172-6
4. W. Sun, X. Lan, H. Zhang et al., Risk Factors for Central Lymph Node Metastasis in CN0 Papillary Thyroid Carcinoma: A Systematic Review and Meta-Analysis. PLoS One **10**(10), e0139021 (2015). doi:10.1371/journal.pone.0139021
5. M.A. Adam, S. Thomas, T. Hyslop et al., Exploring the Relationship Between Patient Age and Cancer-Specific Survival in Papillary Thyroid Cancer: Rethinking Current Staging Systems. J. Clin. Oncol. **34**(36), 4415–4420 (2016)
6. D.S.A. McLeod, A.M. Sawka, D.S. Cooper, Controversies in primary treatment of low-risk papillary thyroid cancer. Lancet **381**(9871), 1046–1057 (2013). doi:10.1016/S0140-6736(12)62205-3
7. D. Perera, R. Ghossein, N. Camacho et al., Genomic and Transcriptomic Characterization of Papillary Microcarcinomas With Lateral Neck Lymph Node Metastases. J Clin Endocrinol Metab **104**(10), 4889–4899 (2019). doi:10.1210/jc.2019-00431
8. C. Spitzweg, K.C. Bible, L.C. Hofbauer et al., Advanced radioiodine-refractory differentiated thyroid cancer: the sodium iodide symporter and other emerging therapeutic targets. *Lancet Diabetes*

Endocrinol. Oct **2**(10), 830–842 (2014). doi:10.1016/S2213-8587(14)70051-8

9. A. Sabet, I. Binse, H. Grafe et al., Prognostic impact of incomplete surgical clearance of radioiodine sensitive local lymph node metastases diagnosed by post-operative (124)I-NaI-PET/CT in patients with papillary thyroid cancer. *Eur J Nucl Med Mol Imaging*. Oct **43**(11), 1988–1994 (2016). doi:10.1007/s00259-016-3400-y
10. B.R. Haugen, E.K. Alexander, K.C. Bible et al., 2015 American Thyroid Association Management Guidelines for Adult Patients with Thyroid Nodules and Differentiated Thyroid Cancer: The American Thyroid Association Guidelines Task Force on Thyroid Nodules and Differentiated Thyroid Cancer. *Thyroid*. Jan **26**(1), 1–133 (2016). doi:10.1089/thy.2015.0020
11. N. Agrawal, M.R. Evasovich, E. Kandil et al., Indications and extent of central neck dissection for papillary thyroid cancer: An American Head and Neck Society Consensus Statement. *Head Neck*. Jul **39**(7), 1269–1279 (2017). doi:10.1002/hed.24715
12. S.Y. Bae, J.H. Yang, M.Y. Choi et al., Right paraesophageal lymph node dissection in papillary thyroid carcinoma. *Ann Surg Oncol*. Mar **19**(3), 996–1000 (2012). doi:10.1245/s10434-011-2144-y
13. D. Kim, H.K. Kwon, S.C. Shin et al., Right posterior paratracheal lymph nodes metastasis is one of the predictive factors in right-sided papillary thyroid carcinoma. *Surgery*. Dec **166**(6), 1154–1159 (2019). doi:10.1016/j.surg.2019.06.024
14. D.C. Luo, X.C. Xu, J.W. Ding et al. Clinical value and indication for the dissection of lymph nodes posterior to the right recurrent laryngeal nerve in papillary thyroid carcinoma. *Oncotarget*. Oct 3 2017;8(45):79897–79905. doi:10.18632/oncotarget.20275
15. L. Zhang, H. Liu, Y. Xie et al., Risk factors and indication for dissection of right paraesophageal lymph node metastasis in papillary thyroid carcinoma. *Eur J Surg Oncol*. Jan **42**(1), 81–86 (2016). doi:10.1016/j.ejso.2015.10.011
16. C. Li, J. Xiang, Y. Wang, Risk Factors for Predicting Lymph Nodes Posterior to Right Recurrent Laryngeal Nerve (LN-prRLN) Metastasis in Thyroid Papillary Carcinoma: A Meta-Analysis. Int J Endocrinol **2019**, 7064328 (2019). doi:10.1155/2019/7064328
17. G.Y. Li, H.L. Tan, P. Chen et al., Predictive Factors for Level V Lymph Node Metastases in Papillary Thyroid Carcinoma with BRAF(V600E) Mutation and Clinicopathological Features. Cancer Manag Res **12**, 3371–3378 (2020). doi:10.2147/CMAR.S247914
18. S. Siddiqui, M.G. White, T. Antic et al., Clinical and Pathologic Predictors of Lymph Node Metastasis and Recurrence in Papillary Thyroid Microcarcinoma. *Thyroid*. Jun **26**(6), 807–815 (2016). doi:10.1089/thy.2015.0429
19. S.K. Kim, I. Park, J.W. Woo et al., Predictive Factors for Lymph Node Metastasis in Papillary Thyroid Microcarcinoma. *Ann Surg Oncol*. Sep **23**(9), 2866–2873 (2016). doi:10.1245/s10434-016-5225-0
20. J.E. Miller, N.C. Al-Attar, O.H. Brown et al., Location and Causation of Residual Lymph Node Metastasis After Surgical Treatment of Regionally Advanced Differentiated Thyroid Cancer. *Thyroid*. May **28**(5), 593–600 (2018). doi:10.1089/thy.2017.0434

21. Y.M. Park, S.M. Lee, D.W. Kim et al., Predictive factors of right paraesophageal lymph node metastasis in papillary thyroid carcinoma: Single center experience and meta-analysis. PLoS One **12**(5), e0177956 (2017). doi:10.1371/journal.pone.0177956
22. J. Hou, H. Shan, Y. Zhang et al., Risk factors of metastasis to the lymph nodes posterior to the right recurrent laryngeal nerve in papillary thyroid carcinoma. *Eur Arch Otorhinolaryngol*. Mar **277**(3), 881–886 (2020). doi:10.1007/s00405-019-05748-3
23. M. Zou, Y.H. Wang, Y.F. Dong et al., Clinical and sonographic features for the preoperative prediction of lymph nodes posterior to the right recurrent laryngeal nerve metastasis in patients with papillary thyroid carcinoma. *J Endocrinol Invest*. Oct **43**(10), 1511–1517 (2020). doi:10.1007/s40618-020-01238-0
24. E. Kim, J.S. Park, K.R. Son et al., Preoperative diagnosis of cervical metastatic lymph nodes in papillary thyroid carcinoma: comparison of ultrasound, computed tomography, and combined ultrasound with computed tomography. *Thyroid*. Apr **18**(4), 411–418 (2008). doi:10.1089/thy.2007.0269
25. Y. Wang, D. Wang, L. Chen et al., A Comparison of Two Operation Methods Revealed the Risk Factors and the Necessity of LN-prRLN Dissection in Papillary Thyroid Carcinoma: A Retrospective Cohort Study in FUSCC. Int J Endocrinol **2020**, 7162793 (2020). doi:10.1155/2020/7162793
26. Y. Luo, X.C. Xu, J. Shen et al., Model of lymph node metastasis posterior to the right recurrent laryngeal nerve in papillary thyroid carcinoma. Cancer Manag Res **10**, 2449–2455 (2018). doi:10.2147/CMAR.S167997
27. Z. Pinyi, Z. Bin, B. Jianlong et al., Risk factors and clinical indication of metastasis to lymph nodes posterior to right recurrent laryngeal nerve in papillary thyroid carcinoma: a single-center study in China. *Head Neck*. Sep **36**(9), 1335–1342 (2014). doi:10.1002/hed.23451
28. O. Huillard, F. Tenenbaum, J. Clerc et al., Vemurafenib for BRAF(V600E)-positive metastatic papillary thyroid cancer. *Lancet Oncol*. Nov **17**(11), e468 (2016). doi:10.1016/S1470-2045(16)30499-5
29. B. Zhou, J. Qin, High-risk factors for lymph node metastasis in contralateral central compartment in unilateral papillary thyroid carcinomacT1N0. *Eur J Surg Oncol*. Apr **47**(4), 882–887 (2021). doi:10.1016/j.ejso.2020.10.018
30. B.J. Chae, C.K. Jung, D.J. Lim et al., Performing contralateral central lymph node dissection in papillary thyroid carcinoma: a decision approach. *Thyroid*. Aug **21**(8), 873–877 (2011). doi:10.1089/thy.2010.0214
31. S.K. Kim, I. Park, N. Hur et al., Patterns, predictive factors and prognostic impact of multilevel metastasis in N1b papillary thyroid carcinoma. *Br J Surg*. Jun **104**(7), 857–867 (2017). doi:10.1002/bjs.10514
32. Y.K. So, M.J. Kim, S. Kim et al., Lateral lymph node metastasis in papillary thyroid carcinoma: A systematic review and meta-analysis for prevalence, risk factors, and location. *Int J Surg*. Feb **50**, 94–103 (2018). doi:10.1016/j.ijsu.2017.12.029

Figures

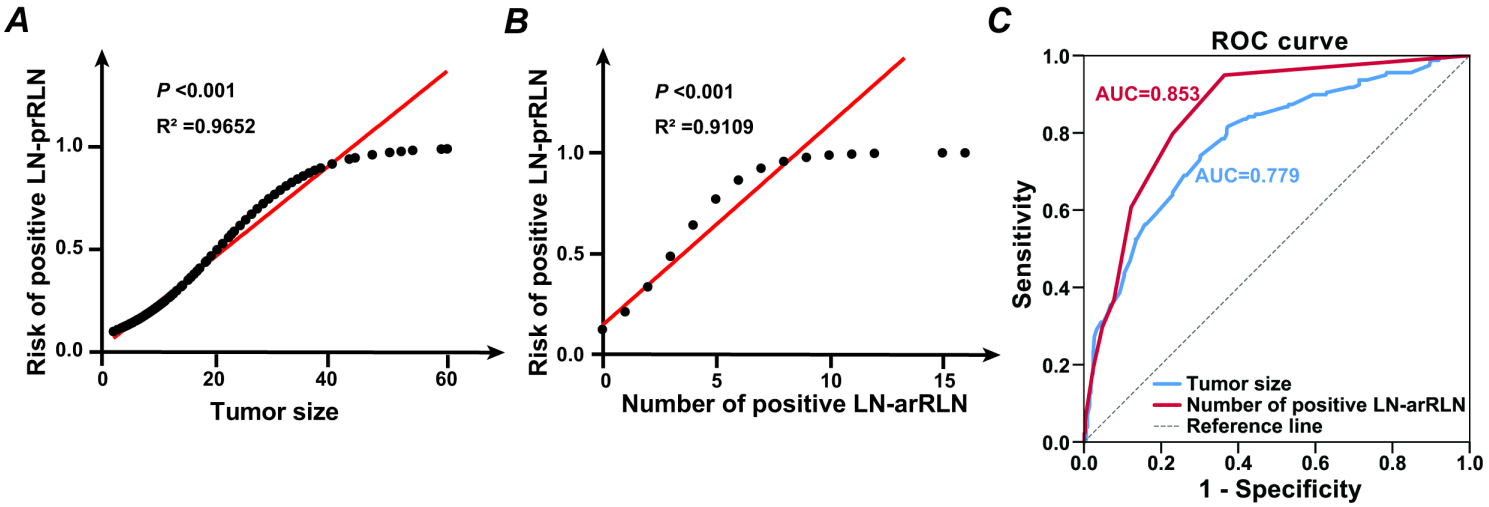

Figure 1

Diagnostic value of risk factors for predicting LN-prRLN in PTC patients. (a, b) The relationship analyses of tumor size, and the number of positive LN-arRLN with risk of positive LN-prRLN in PTC patients are shown, Pearson's r test, n=493, p < 0.001. (c) ROC curve for tumor size (blue line) and the number of positive LN-arRLN (red line). LN-arRLN, lymph nodes anterior to the right recurrent laryngeal nerve; LN-prRLN, the lymph node posterior to the right recurrent laryngeal nerve; PTC, papillary thyroid carcinoma; ROC curve, receiver operating characteristic curve

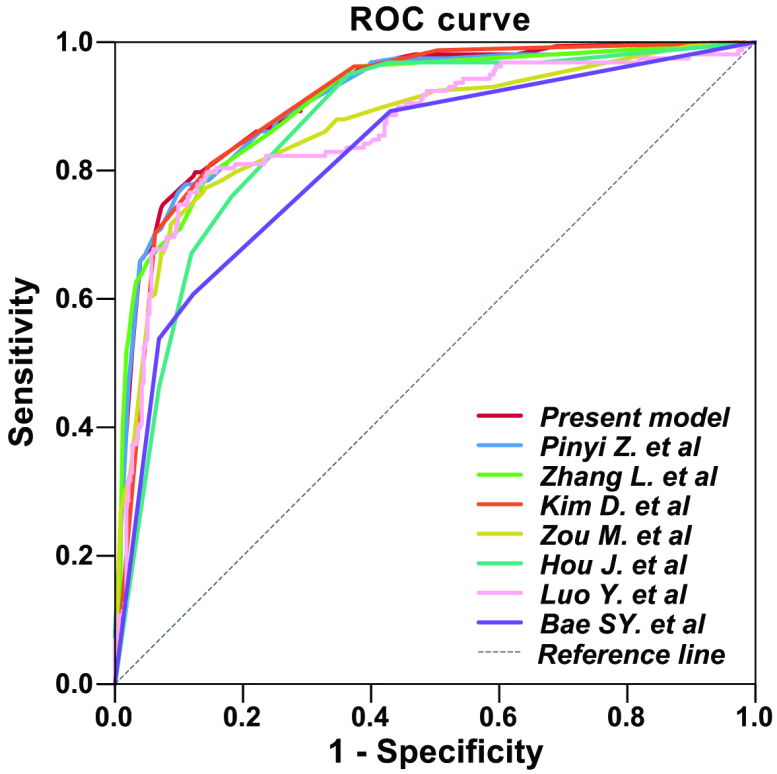

Model	AUC	NRI
Present model	0.915	–
Pinyi Z. et al	0.910	0.004
Zhang L. et al	0.907	0.024
Kim D. et al	0.906	0.011
Zou M. et al	0.906	0.040
Hou J. et al	0.865	0.087
Luo Y. et al	0.865	0.018
Bae SY. et al	0.819	0.187

Figure 2

ROC curves were used to compare the predictive ability among present model (red line), and models described by Pinyi Z (blue line), Zhang L (green line), Kim D (orange-red line), Zou M (yellow line), Hou J (spring-green line), Luo Y (pink line), and Bae SY (purple line); AUC, the area under the receiver operating characteristic curve; NRI, net reclassification improvement index; ROC curve, receiver operating characteristic curve

Supplementary Files

This is a list of supplementary files associated with this preprint. Click to download.

- SupplementalFig1.tif
- SupplementalTable1.docx