Necrotising Vasculitis in Covid-19: watch out for bowel perforation

Tonia Persiano
Università degli Studi di Pavia. Scuola di Specialità Medicina di Emergenza e Urgenza
Francesca Grulli
Università degli Studi di Pavia. Scuola di Specialità Medicina di Emergenza e Urgenza
Pietro Cornara
Università degli Studi di Pavia. Scuola di Specialità Anestesia e Rianimazione
Francesca Bonomi
Università degli Studi di Pavia. Scuola di Specialità Anestesia e Rianimazione
Alberto Casazza (alberto_casazza@asst-pavia.it)
ASST Pavia Ospedale Civile di Vigevano
Anna Coci
ASST Pavia Ospedale Civile di Vigevano
Sabina Teresa Mediani
ASST Pavia Ospedale Civile di Vigevano
Elisabetta Bellazzi
ASST Pavia Ospedale Civile di Vigevano
Livio Carnevale
ASST Pavia Ospedale Civile di Vigevano

Case Report

Keywords: SARS-CoV-2 infection, bowel perforation, Pseudomembranous colitis, necrotising vasculitis.

Posted Date: September 17th, 2020

DOI: https://doi.org/10.21203/rs.3.rs-79258/v1

Abstract

Introduction: SARS-Cov-2 infection can be asymptomatic, greatly impair respiratory function and, sometimes, affect other organs. Gastro-enteric involvement seems to be not so rare and many patients suffered for abdominal pain, anorexia, nausea and vomiting, diarrhoea or jaundice.

Case presentation: Here we report a case of a Covid-19 patient who developed a right colon perforation due to a pseudomembranous colitis without Clostridium Difficile toxins finding associated to a necrotising vasculitis. In this patient a PCR test performed on gastric fluid showed SARS-CoV-2 enteric replication.

Discussion: Necrotizing vasculitis is an anatomopathological typical findings in Covid-19. It has been documented in several organs and tissues. In our case, evident foci of necrotizing vasculitis with intravascular obliteration by fibrin thrombi with macrophagic cells infiltration are anatomopathological findings of a CD toxins free pseudomembranous colitis leading to bowel perforation.

Conclusions: Bowel perforation due to necrotizing vasculitis leading to pseudomembranous colitis could be a SARS-Cov-2 related clinical finding.

Introduction

The Novel Coronavirus disease, caused by a virus named SARS-CoV-2, known also as Covid-19, has spread worldwide causing more than 650.000 deaths up to July 2020: Italy has been the first European country hit by the pandemic and counts, up to endo of July, more than 245.000 infection and 35.000 deaths. SARS-CoV-2 infection can be asymptomatic but the main clinical presentation is respiratory, which can range from a mild flu-like syndrome to acute respiratory distress syndrome (ARDS). In addition, SARS-CoV-2 infection may affect other organs than lungs such as liver, bowel and kidneys mainly, with frequent onset of different pathological features. The most common SARS-CoV-2 infection symptoms are fever followed by dry cough, shortness of breathing, dyspnoea, chest pain, fatigue, intense myalgia and, sometimes, severe acute respiratory failure often complicated by shock [1]. Less commonly, patients present abdominal pain, diarrhoea, nausea and vomiting, cholestatic jaundice [2]. We here report the first case, to our knowledge, of a Covid-19 patient affected by right colon perforation, needing urgent surgery, due to a necrotizing vasculitis leading to pseudomembranous colitis in absence of Clostridium Difficile toxins finding, but with SARS-Cov-2 identification in gastric fluid. Pseudomembranous colitis is a well-known anatomopathological finding and it is mainly related to Clostridium Difficile infection [3], usually associated to long hospital staying and/or prolonged broad-spectrum antibiotic therapy. Pseudomembranous colitis is most rarely due to an inflammatory bowel disease exacerbation, a microscopic colitis, a vasculitis or a chemical damage [4] in absence of Clostridium Difficile toxins findings.

Case Presentation

Informed consent for publication cannot be obtained by authors because the patient is dead and his relatives cannot be traced.

On April 4th, 2020, a 73-years-old man came in our hospital emergency department with 24-hour history of fever and progressive dyspnoea. His remote medical history revealed ischemic heart disease, hypertension, NIDDM and mild chronic renal impairment. At physical examination he presents lower limbs edema, dyspnea, 37.3°C temperature, arterial hypertension, sinus rhythm at 85 bpm and a peripheral oxygen saturation of 94% in spontaneous breathing in air. No abdominal symptoms were reported. Anteroposterior chest X-ray shows right basal consolidation and bilateral lung congestion. A nasopharyngeal swab specimen for Covid-19 is collected, reported back as negative. The patient has been admitted in a General Medicine ward with the diagnosis of Covid-19 negative pneumonia leading to heart failure and pulmonary edema. Antibiotics (ceftriaxone and azithromycin), diuretics and continuous positive airway pressure (CPAP) ventilation has been started. Ten days after (April 14th), a worsening of respiratory involvement despite treatment, and typical radiological findings leads to perform a second nasopharyngeal swab specimen for testing Covid-19: hence resulted positive. The patient has been transferred to a cohort isolation ward and hydroxychloroquine administration and LMWH treatment have been started, CPAP ventilation and antibiotic therapy (azithromycin only) were continued. Meantime the patient develops fever and profuse diarrhea without vomiting: on physical examination abdomen is treatable but widely painful and distended. After collecting urine and blood samples, empirical antibiotic therapy with Piperacillin/tazobactam has been started: laboratory tests show normal WBC count and formula and normal PCT level, while RCP and D-Dimer levels are elevated. On April 25th, given the patient's clinical progressive worsening, an abdominal CT scan is performed showing a 10 cm caudo-cranial extended parietal thickening of the ascending cecum-colon and intraperitoneal free air collection (Fig. 1). Hence, emergency surgery has been performed, leading to right hemicolectomy for bowel perforation. After surgery, the patient has been admitted to our General 7 beds ICU both to treat Covid19 related respiratory failure and to perform postoperative care. The anatomopathological examination of the surgical sample revealed a pseudomembranous colitis with masses of mucus and neutrophilic granulocytes, present from the ileocecal valve to part of the ascending colon. However, a vast oedema, acute inflammation and foci of necrotizing vasculitis, with fibrin thrombi and abundant infiltration of intravascular neutrophilic granulocytes has been identified (Fig. 2-3) Given the typical presentation, the long hospitalisation and the risks factors, samples for Clostridium Difficile toxins research have been collected both from ileostomy and from stool from rectal ampule, with negative result. A PCR test for SARS-CoV-2 isolation were performed in the gastric fluid too, resulting positive. After improvement of clinical conditions, in day 24, the patient was discharged from ICU to a low intensity ward.

Discussion

Covid19 disease is still widely unknown and we are progressively learning its complications and manifestations. Necrotizing vasculitis has been described as a common histopathological finding in SARS-CoV-2 infected patients [4], with typical features. Enteric and bowel involvement, however, is not yet clear: some authors suggest it is present in up to 50% of the cases [5]. Furthermore, SARS- Cov-2 has

been detected in samples from faeces suggesting that virus can actively infect and replicate in the GI tract [6] leading to different forms of colitis; a common feature for the other member of coronavirus family. Nowadays, exact mechanism of viral infection causing intestinal symptomatology is not yet understood, Angiotensin-Converting Enzyme 2 (ACE 2) receptor, known as the SARS CoV-2 receptor on human, is expressed not only by lung but also by intestinal epithelium: mouse models shows that ACE2 receptor modifications can be associated with higher rate in colitis, suggesting that receptor modification due to virus infection can increase risk of developing intestinal inflammation and colitis [5]. It is also known that COVID-19 patient, especially with more severe forms of disease, suffered for an acute systemic inflammatory response due to cytokine storms that can develop a multiple organs injury [7], often driven by vasculitis as initial damage. In our case Clostridium Difficile (CD) Pseudomembranous colitis has been the first suspicion: the surgical specimen was suggestive and the patient presented predisposing factors such as in-hospital length of staying, advanced age, illness severity and prolonged antibiotic therapy. Since laboratory tests were always negative and the patient showed improvement without CD specific therapies, we identified the cause of pseudomembranous colitis and perforation in necrotizing vasculitis, closely related to Covid19[6]. Its presence on histopathology on the surgical piece and the presence of viral RNA in the gastric fluid strongly support the hypothesis of an enteric localization of SARS-Cov-2: our laboratory, unfortunately, is not able to detect the viral presence in the stool.

We, here, describe a possible critical complication of the still largely unknown disease related to SARS-CoV-2 infection. Many Covid 19 patients presents GI symptoms together with respiratory ones (2,5). Gastro-enteric involvement may be due to enteric virus replication. Necrotizing vasculitis is a histopathological pattern commonly found in Covid-19 patients in several organs. Clostridium difficile negative pseudomembranous colitis due to a necrotizing vasculitis, in our case, may be a SARS-CoV-2 infection complication too.

This case highlights how our Covid-19 related clinical findings knowledge is still incomplete, and suggests the need to be aware for every symptom to quickly diagnose and prevent possible complications.

Further data are needed to confirm our observations.

Declarations

All authors declare they have no conflicts of interest.

References

1. Huang C, Wang Y, Li X, Ren L, Zhao J, Hu Y, et al. Clinical features of patients infected with novel coronavirus in Wuhan, China. Lancet. 2020;395:497-506.
2. Bruni A, Garofalo E, Zuccalà V, et al. Histopathological findings in a COVID-19 patient affected by ischemic gangrenous cholecystitis. World J Emerg Surg. 2020;15(1):43

3. Napolitano LM, Edmiston CE. Clostridium difficile disease: Diagnosis, pathogenesis, and treatment update, Ann Surgery. 2017;162,2:325-348
4. Farooq PD, Urrunaga NH, MS, Tang DM, von Rosenvinge EC. Pseudomembranous colitis. Disease a month. 2015; 61:181-206
5. Roncati L, Ligabue G, Fabbiani L, et al. Type 3 hypersensitivity in COVID-19 vasculitis. Clin Immunol. 2020;217:108487
6. D'Amico F, Baumgart DC, Danese S, Peyrin-Biroulet L. Diarrhea During COVID-19 Infection: Pathogenesis, Epidemiology, Prevention, and Management. Clinical Gastroenterology and Hepatology 2020;18:1663–1672
7. Gu J, Han B, Wang J. COVID-19: Gastrointestinal Manifestations and Potential Fecal-Oral Transmission. Gastroenterology. 2020;158(6):1518-1519

Figures

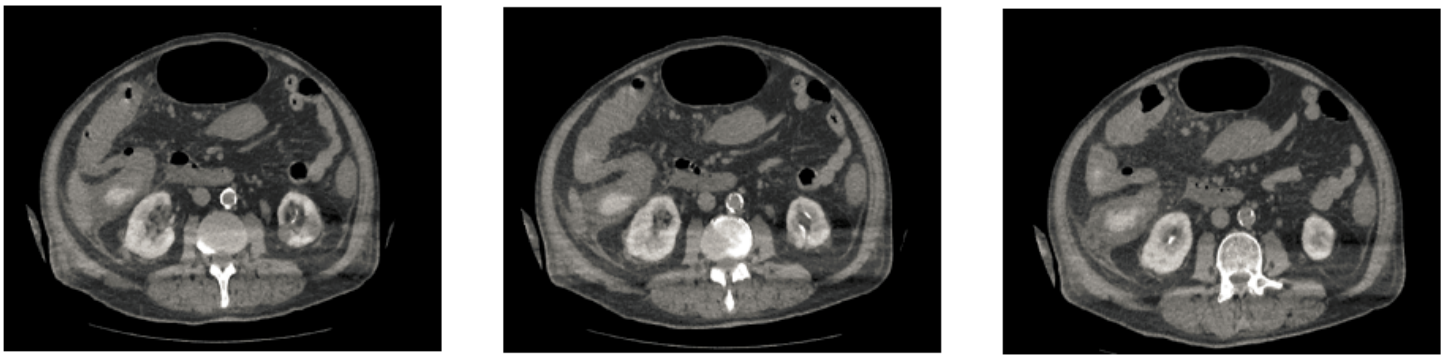

Figure 1

Abdomen CT scan showing parietal thickening of the ascending colon with cranial-caudal extension of 10 cm

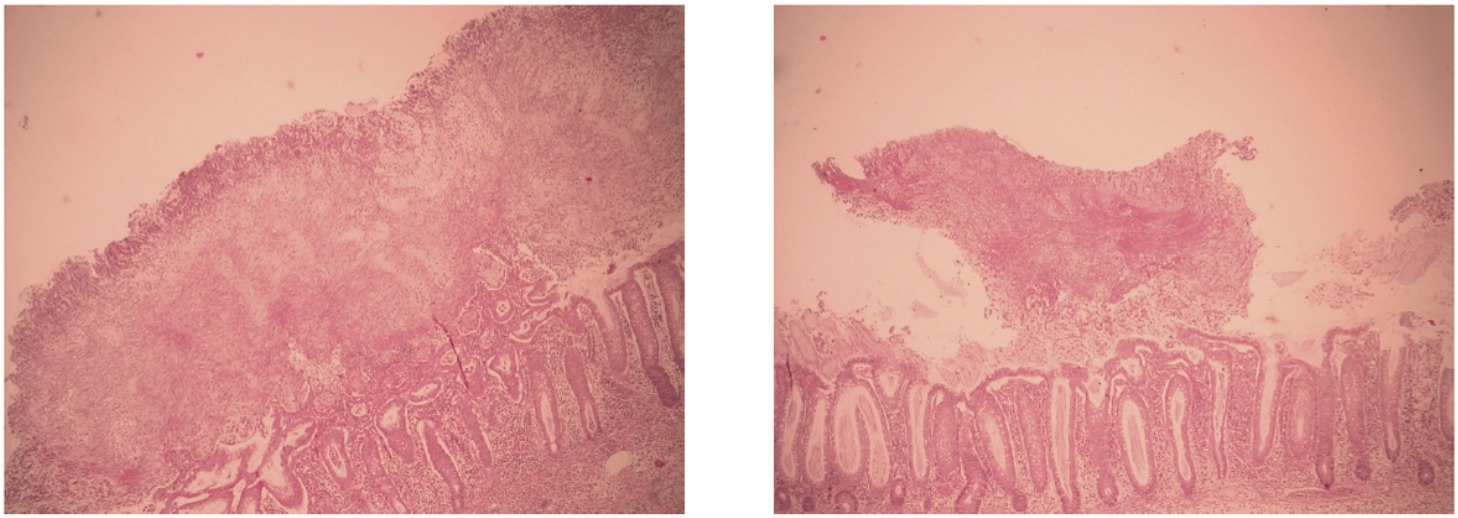

Figure 2

Colic mucosa showing a “focal explosive” lesion typical of pseudomembranous colitis characterized by a mushroom-like mass of mucus and neutrophils

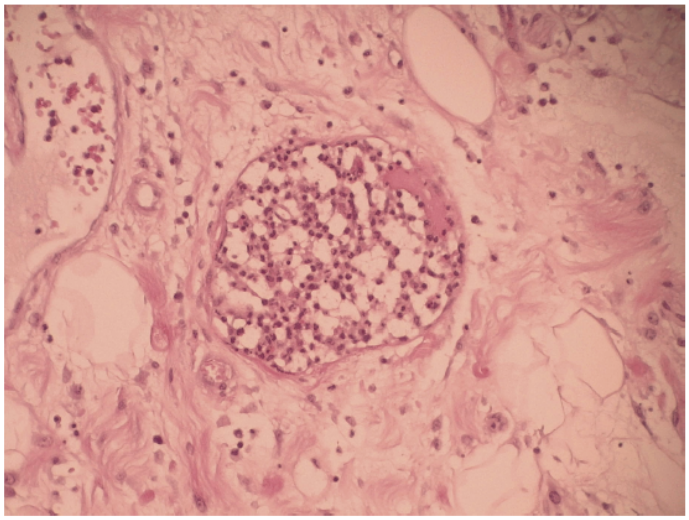

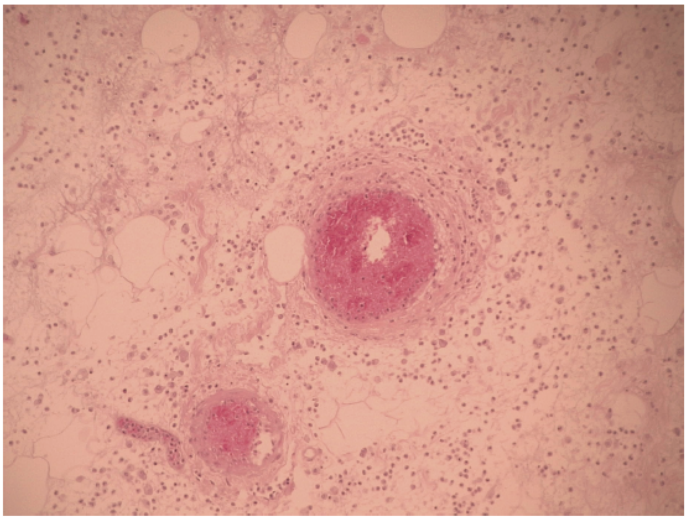

Figure 3

The colic wall presents oedema and acute inflammation with foci of necrotizing vasculitis and intravascular neutrophils