# Short-term Effect of Monosodium glutamate on serum hormonal level and histological changes of uterus during estrus phase in rat

**Mahfoudh Almuslai Mohammed Abdulghani** ( mahfouz08@gmail.com )
Unaizah College of Pharmacy at Qassim University https://orcid.org/0000-0001-7228-1233

**Research Article**

**Keywords:** Monosodium glutamate (MSG), Progesterone, Estrogen

**Posted Date:** August 18th, 2021

**DOI:** https://doi.org/10.21203/rs.3.rs-794465/v1

## Abstract

# Background

Monosodium glutamate (MSG) is commonly used in the Middle East and worldwide as a flavour enhancer in food. MSG is called Chinese salt and is commonly used by the food processing industry, restaurants, and institutional services. The current study was conducted to investigate the effects of monosodium glutamate on the uterine tissue of adult female Sprague Dawley rats with a regular estrus cycle.

# Results

The mean relative values of progesterone and estrogen to the control in the MSG-treated animal group significantly affect ($P < 0.05$) compared with the control group. The means of the relative lumen area ($um^2$) showed smaller than the control group.

# Conclusions

MSG may cause disturbance in serum progesterone and estrogen levels in young female rats. So, a precautionary utilised for this compound, especially for females under risk factor of hormonal abnormality, is recommended. Further study should be conducted to evaluate the effect of MSG on corpus lutea function.

## Introduction

Monosodium glutamate (MSG) is commonly used in the Middle East and worldwide as a flavour enhancer in food. MSG is Chinese salt and is commonly used by the food processing industry, restaurants, and institutional service in the Middle East. The MSG is a salt of the common amino acid glutamic acid produced by the fermentation of some carbohydrate-based products. Three million tons of Monosodium glutamate (MSG) is yearly consumed in the global market (Nakamura and Itsubo 2021). Global consumption was increased in the last five years, and it was estimated that the glutamate acid market size is likely to reach more than four million tons by 2023.

Some scientific reports indicated that MSG was toxic to humans (Walker and Lupien 2000) and experimental animals (Ganesan et al. 2013). MSG consumption could cause numbness, weakness, flushing, sweating, dizziness and headaches (Walker and Lupien 2000). Moreover, ingestion of MSG has been pretended to cause or aggravate numerous conditions, including asthma, urticaria, atopic dermatitis, ventricular arrhythmia, neuropathy and abdominal discomfort (Geha et al. 2000). MSG has a toxic effect on male reproductive organs. MSG caused several abnormalities in experimental animals included oligozoospermia, increases abnormal sperm morphology, testicular haemorrhage, degeneration and

alteration of sperm cell population and morphology (Oforofuo et al. 1997; Nayanatara et al. 2008; Das and Ghosh 2010; Igwebuike et al. 2011; Onakewhor et al. 2017). In the female reproductive system, the limitation of gametes is more susceptive to toxicity (Hillier 1994). Hormonal control and dynamic activity of the reproductive organs like the ovary and uterus have been considered a reason for being more sensitive to physiological stress and ingested chemical (Armenti et al. 2008). In this regard, periodic growth and regression occurring in the uterus under hormonal control induce sensitivity to more physiological stress (Warren and Perlroth 2001; Armenti et al. 2008). The induced disturbances in the female reproductive system could result in abnormalities in embryonic and fetal development. Uterine tissue from women and rodents (rats and mice) share some essential characteristics. Several measured parameters can be used for measurement toxicity in non-pregnant uterus included an alteration in uterine weight (Barlow and Sullivan 1982; Bulger 1985; Hughes Jr 1988), histological changes and measurable changes in the histological section of the different parts of the section (lumen area, length of stroma and myometrium).

In the last decade, fear had increased due to the adverse reactions and toxicity of MSG, with minor and limited literature about the histological studies of the damage in treated animal's uterus caused by MSG. So the current study was conducted to investigate the effects of monosodium glutamate on the uterine tissue of young female rats with a regular estrus cycle.

## Materials And Methods

# Protocol for maintaining rat:

Virgin sexually matured Sprague Dawley adult female rats with regular oestrous cycles, 10–14 weeks old and weighing 200 ± 25 g, were obtained from the Animal Research and Service Centre of Qassim University (QU) Qassim, Saudi Arabia. The animals were housed in a temperature-controlled room (23–26°C) with a 12 h light/dark cycle. Standard commercial rat chow (1st Milling Company, Qassim) and drinking water were provided *ad libitum*. In the current study, the sample size was estimated using previous studies.

# Study Protocol:

The oestrous cycle of the female rats was recorded (ECs) according to (Abdulghani et al. 2012) for two oestrous cycles before the administration of MSG to make sure animals have regular ECs and to exclude animals with irregular EC from the experiment. The 12 animals with regular EC were put in one big cage then assigned randomly into two groups (each group n = 6 animals); the first group, 10 ml/kg distilled water (DW) as a control group, and each animal was numbered with black marker in the tall of each animal. The second animal group was treated with 2 g/kg of MSG [30], and each animal was numbered with the red marker. The oral administrated MSG was prepared by dissolving MSG in distilled water (DW) in a concentration of 200 mg/1 ml. the MSG was orally administered for 14–16 days. The effective dose of MSG (2 g/kg) was selected in this study according to $LD_{50}$ value of MSG in the rat model as reported by Chakraborty, (Chakraborty 2019) and a pilot study of MSG effects on oestrous cycle regularity

(Abdulghani unpublished). Vaginal lavage was performed to control and treated animals. At the end of the experiment, each animal was anaesthetised with ketamine and xylene, and the blood sample was collected by cardiopuncture at the estrus phase for serum progesterone and estrogen analysis. The animals were euthanised by cervical dislocation, and uteri were isolated for calculation of the relative weight of wet uterine according to (Wood et al. 2007; AL-Shemary 2017). The relative weight of uterine were calculated and immediately preserved in 10% formalin for histological evaluation. For each group of animal in this study, all data points for each animal were included in the analysis.

# Gross morphological evaluation of the uterus:

The Uterine tissues were dissected from the sacrificed rat at the end of treatment for histological evaluation and females in the oestrus phase, and they were fixed in 10% formalin immediately after removal for one week. Each Fixed tissue was subjected to tissue dehydration processing and paraffin wax embedding. The prepared uterine tissues in paraffin blocks were sent to the Histopathology Section of Al-Thobhani Specialized Medical labs for further process (section cutting and staining). Two histological slides were made from each uterus for each rat: the hematoxylin and eosin-stained uterine tissues. The image of uterine sections was taken at 10x magnifications under a light microscope connects with the camera. In the uterine section phots, the three major features, lumen area, the stromal uterus is a deep layer of endometrium and myometrium layer is a structural wall of uterus composed primarily of smooth muscle majored using ImageJ software. Each relative value to the respective control was calculated. The photos of uterine sections were taken with 10x magnifications (Labomed, Inc. USA) (Fig. 3). In each animal group, six uterine sections from each animal were evaluated. The lumen area is defined as the inside space of a tubular structure of the uterus. The stromal uterus is a deep layer of endometrium, and the myometrium layer is the structural wall of the uterus composed primarily of smooth muscle—the relative values to the respective control parameters calculated (Fig. 5).

# Female Six hormone level measurement:

At the end of the experiment, each animal with estrus phase (Fig. 2) was anaesthetised, and a blood sample is drawn by cardiopuncture with 27-gauge needles from the heart in a non-heparinised sample test tube between 10–11 am. The collected blood was centrifuged at 5000 rpm for 15 min, and the serum was separated. The separated serum was kept at (-80°C) refrigerator until analysis. The serum samples were sent to the Al Safwa Medical Laboratory to measure estrogen levels for both groups of animals, and the chemiluminescent immunoassay (Beckman coulter Access II, USA) was used.

# Statistical analysis:

Data represent mean relative value to the respective control ± SEM (n = 6) of the lumen area, length of stroma and myometrium, female six hormones level (progesterone and estrogen), and relative weight uterine of the control and MSG-treated groups. All data followed a normal distribution. The student's t-test was used to compare MSG-treated groups with control, and differences were considered significant at $P < 0.05$ by SPSS version 23.

# Results

In the MSG-treated group, the means of relative of lumen area ($\mu m^2$) length of stroma (μm), uterine weight and showed smaller than control group while the mean of the relative of the length of myometrium higher than control (Fig. 1)

The mean relative weight of the wet uterine in the MSG-treated group showed less than the control group but not significant (Fig. 2).

The mean relative value of progesterone to the control in the MSG-treated animal group was significantly higher ($P < 0.05$) compared with the control group. The mean relative value of estrogen to the control in the MSG-treated animal group was significantly less ($P < 0.05$) compared with the control group (Fig. 3).

Oral feeding of MSG 2 g /kg for 14 days showed a non-significantly increased body weight difference compared with the control group (Fig. 4a). The mean of food consumption (g/rat) showed no difference between the MSG-treated animal and control groups (Fig. 4b)

# Discussion

Abnormal progesterone and estrogen levels were recorded in the current work in animals treated with MSG, Concorde with (Mondal et al. 2018; Agbadua et al. 2020) who reported ovarian hormone abnormality, which increase on progesterone levels. However, the observation on estrogen in this study did not agree with (Obochi et al. 2009; Koffuor et al. 2013), who observed a significant elevation of estrogen level elevation.

In the uterine section of MSG-treated animals, no significant morphological parameters include the lumen area and lengths of stroma and myometrium. A study on MSG effects on uterine morphological parameters is not found in the current literature review. So it is not easy to make a compersion. However, few studies reported histological changes in uterine section for MSG-treated animals (AL-Shemary 2017). In the study, observations indicated no significant increase in uterine weight and relative weight in MSG-treated animals, not agreed with (Koffuor et al. 2013) who observed a significant increase in uterine weight. The body weight of animals treated with MSG showed no significant changes, agreed with (Adamo and Ratner 1970) who observed relative uterine weight insignificantly increased compared to the controls.

Prolonged intake of monosodium glutamate (MSG) and glutamate salt with food results in its influencing in the body, predominantly metabolism and oxidation balance in different systems/organs, included nervous system, endocrine system, liver, pancreas, and kidney in humans and animals (Diniz et al. 2004; Hernández-Bautista et al. 2014; Boonnate et al. 2015). The negative effects of MSG on the metabolism and oxidation system may play a critical role in the normal function of the reproductive system in both males and females. SMG showed impaired male reproductive function and caused testicular haemorrhage, degeneration and alteration of sperm cell population and morphology, which implicated in

male infertility (Onakewhor et al. 2017). In histological studies, higher doses of MSG showed deleterious effects on rat's fallopian tubes and ovary and uterus sections (Eweka et al. 2010; Oladipo et al. 2015; Mondal et al. 2018). This negative effect on histological of fallopian tubes and ovary in rats may lead to infertility. The deleterious effects of MSG on the reproductive system in both males and females are suggested due to indirect distorting of the hypothalamic-pituitary-gonads regulatory axis (Igwebuike et al. 2011).

A previous study reported the MSG effect on the oestrous cycle in rodents (Abbasi et al. 2016). Disrupted ovarian cyclicity and modified follicle maturation can thus directly impact progesterone and estrogen level—the primary production of estrogen from matured follicles in ovary and progesterone produced from corpus lutea.

MSG treatment for four oestrous cycles may influence the maturation of follicles in ovaries, leading to the influence of estrogen and subsequence progestogen levels. So MSG may disrupt follicle's function leading to decrease estrogen level and subsequence decrease expression of progesterone receptors in uterine tissue. The MSG may be involved in increasing luteinising hormone, which leads to increased corpus lutea production of progesterone and increased serum progesterone level (Mondal et al. 2018), showing a significant increase in serum LH levels in MSG treated groups of rats. The possible mechanism of disruptions of MSG on female reproductive organs that decrease antioxidant enzymes like glutathione reductase (GR), glutathione peroxidase in ovarian tissues for rats (Mondal et al. 2018) and increase oxidative stress (Umukoro et al. 2015). The other mechanism involved in MSG disruptions on female reproductive function is the metabolic abnormality caused by MSG. MSG showed to cause type two diabetic mellitus in the experimental model (Boonnate et al. 2015), to increase body weight and fat mass in rodents (Hernández-Bautista et al. 2014; Calis et al. 2016; Pelantová et al. 2016). The influence of MSG on the body's metabolism may lead to alteration of reproductive (Gaspar et al. 2016).

# Conclusions

The disturbance in serum progesterone and estrogen levels in young female rats caused by MSG may lead to an abnormality in functions of reproductive organs. So, a precautionary utilised for this compound, especially for females under risk factor of hormonal abnormality, is recommended. Further study should be conducted to evaluate the effect of MSG on corpus lutea function.

# Declarations

### Ethics approval and consent to participate

The Qassim University Committee approved the experimental protocol of Research Ethics under reference number 20-02-01.

### Consent for publication:

Not applicable

**Availability of data and materials**

Data for the research work were made available at submission.

**Competing interests:**

The author declares no competing financial interest.

**Funding**

This work was conducted using Unaizah College of Pharmacy facilities, and the author received no specific financial support.

**Authors' contributions:**

The authors declare that all data were generated in-house and that no paper mill was used.

**Acknowledgements:**

The author would like to express his appreciation to Unaizah College of pharmacy management for their supports and facilitating during the study.

**Author details:**

Pharmacology & Toxicology Department, Unaizah College of Pharmacy, Qassim University, Saudi Arabia

# Abbreviations

MSG
monosodium glutamate; SEM = standard error of mean; EC = estrous cycle

# References

Abbasi S, Rana R, Anjum K (2016) Effect of vitamin C on monosodium glutamate (ajinomoto) induced changes in the ovary of rats. J Islam Int Med Coll 11:66–70

Abdulghani M, Hussin AH, Sulaiman SA, Chan KL (2012) The ameliorative effects of Eurycoma longifolia Jack on testosterone-induced reproductive disorders in female rats. Reprod Biol 12:247–255

Adamo NJ, Ratner A (1970) Monosodium glutamate: lack of effects on brain and reproductive function in rats. Science 169:673–674

Agbadua OG, Idusogie LE, Chukwuebuka AS et al (2020) Evaluating the Protective and Ameliorative Potential of Unripe Palm Kernel Seeds on Monosodium Glutamate-Induced Uterine Fibroids. Open Access Libr J 7:1–11

AL-Shemary NNA (2017) Histological Changes after Monosodium Glutamate Administration on Reproductive System for Each male and Female Adult Albino Mice. Iraqi J Embryos Infertil Res 7

Armenti AE, Zama AM, Passantino L, Uzumcu M (2008) Developmental methoxychlor exposure affects multiple reproductive parameters and ovarian folliculogenesis and gene expression in adult rats. Toxicol Appl Pharmacol 233:286–296

Barlow SM, Sullivan FM (1982) Reproductive hazards of industrial chemicals: An evaluation of human and animal data

Boonnate P, Waraasawapati S, Hipkaeo W et al (2015) Monosodium glutamate dietary consumption decreases pancreatic β-cell mass in adult Wistar rats. PLoS One 10:e0131595

Bulger WH (1985) Estrogenic activity of pesticides and other xenobiotics on the uterus and male reproductive tract. Endocr Toxicol 1–33

Calis IU, Cosan DT, Saydam F et al (2016) The effects of monosodium glutamate and tannic acid on adult rats. Iran Red Crescent Med J 18

Chakraborty SP (2019) Patho-physiological and toxicological aspects of monosodium glutamate. Toxicol Mech Methods 29:389–396

Das RS, Ghosh SK (2010) Long-term effects of monosodium glutamate on spermatogenesis following neonatal exposure in albino mice-A histological study. Nepal Med Coll J 12:149–153

Diniz YS, Fernandes AAH, Campos KE et al (2004) Toxicity of hypercaloric diet and monosodium glutamate: oxidative stress and metabolic shifting in hepatic tissue. Food Chem Toxicol 42:313–319

Eweka AO, Eweka A, Om'Iniabohs FAE (2010) Histological studies of the effects of monosodium glutamate of the fallopian tubes of adult female Wistar rats. N Am J Med Sci 2:146

Ganesan K, Sukalingam K, Balamurali K et al (2013) A STUDIES ON MONOSODIUM L-GLUTAMATE TOXICITY IN ANIMAL MODELS-A REVIEW. Int J Pharm Chem Biol Sci 3

Gaspar RS, Benevides RO, Fontelles JL et al (2016) Reproductive alterations in hyperinsulinemic but normoandrogenic MSG obese female rats. J Endocrinol 229:61–72

Geha RS, Beiser A, Ren C et al (2000) Review of alleged reaction to monosodium glutamate and outcome of a multicenter double-blind placebo-controlled study. J Nutr 130:1058S–1062S

Hernández-Bautista RJ, Alarcón-Aguilar FJ, Escobar-Villanueva DC et al (2014) Biochemical alterations during the obese-aging process in female and male monosodium glutamate (MSG)-treated mice. Int J Mol Sci 15:11473–11494

Hillier SG (1994) Current concepts of the roles of follicle stimulating hormone and luteinizing hormone in folliculogenesis. Hum Reprod 9:188–191

Hughes CL Jr (1988) Phytochemical mimicry of reproductive hormones and modulation of herbivore fertility by phytoestrogens. Environ Health Perspect 78:171–174

Igwebuike UM, Ochiogu IS, Ihedinihu BC et al (2011) The effects of oral administration of monosodium glutamate (MSG) on the testicular morphology and cauda epididymal sperm reserves of young and adult male rats. Vet Arh 81:525–534

Koffuor GA, Annan K, Kyekyeku JO et al (2013) Effect of ethanolic stem bark extract of blighia unijugata (sapindaceae) on monosodium glutamate-induced uterine leiomyoma in Sprague-Dawley rats. J Pharm Res Int 880–896

Mondal M, Sarkar K, Nath PP, Paul G (2018) Monosodium glutamate suppresses the female reproductive function by impairing the functions of ovary and uterus in rat. Environ Toxicol 33:198–208

Nakamura K, Itsubo N (2021) Lifecycle Assessment of Monosodium Glutamate Made from Non-Edible Biomass. Sustainability 13:3951

Nayanatara AK, Vinodini NA, Damodar G et al (2008) Role of ascorbic acid in monosodium glutamate mediated effect on testicular weight, sperm morphology and sperm count, in rat testis. J Chin clin med 3:1–5

Obochi GO, Malu SP, Obi-Abang M et al (2009) Effect of garlic extracts on monosodium glutamate (MSG) induced fibroid in Wistar rats. Pakistan J Nutr 8:970–976

Oforofuo IAO, Onakewhor JUE, Idaewor PE (1997) The effect of chronic administration of MSG on the histology of the adult Wistar rat testes. Bio Res Comm 9:30–56

Oladipo IC, Adebayo EA, Kuye OM (2015) Effects of monosodium glutamate in ovaries of female Sprague-Dawley rats. Int J Curr Microbiol App Sci 4:737–745

Onakewhor JUE, Oforofuo IAO, Singh SP (2017) Chronic administration of monosodium glutamate induces oligozoospermia and glycoen accumulation in Wistar rat testes. Afr J Reprod Health 2

Pelantová H, Bártová S, Anýž J et al (2016) Metabolomic profiling of urinary changes in mice with monosodium glutamate-induced obesity. Anal Bioanal Chem 408:567–578

Umukoro S, Oluwole GO, Olamijowon HE et al (2015) Effect of monosodium glutamate on behavioral phenotypes, biomarkers of oxidative stress in brain tissues and liver enzymes in mice. World J Neurosci 5:339

Walker R, Lupien JR (2000) The safety evaluation of monosodium glutamate. J Nutr 130:1049S–1052S

Warren MP, Perlroth NE (2001) The effects of intense exercise on the female reproductive system. J Endocrinol 170:3–11

Wood GA, Fata JE, Watson KLM, Khokha R (2007) Circulating hormones and estrous stage predict cellular and stromal remodeling in murine uterus. Reproduction 133:1035–1044

# Figures

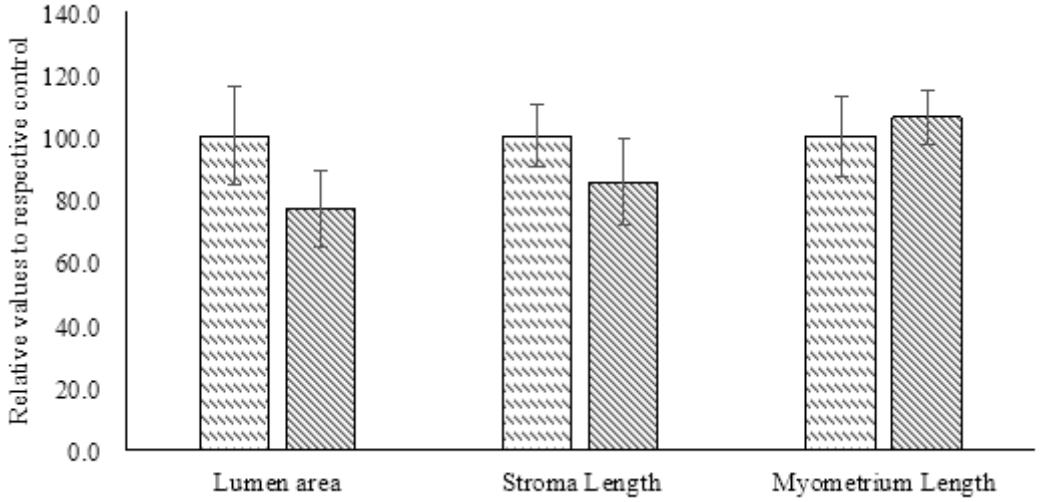


**Figure 1**

Effect of MSG on morphological parameters at estrus phase. The values represent the mean ± SEM of the relative values to the respective control. Comparing the mean of lumen area (µm2), stroma length (µm) and myometrium length (µm) in uterine tissues of the control and the treated groups. The image of uterine sections was taken at 10x magnifications under a light microscope connects with the camera. The ImageJ was used for measurement of the lumen area (µm2), stroma length (µm) and myometrium length (µm). Statics performed by student's t-test, comparing MSG-treated groups with control, and differences were considered significant at $P < 0.05$

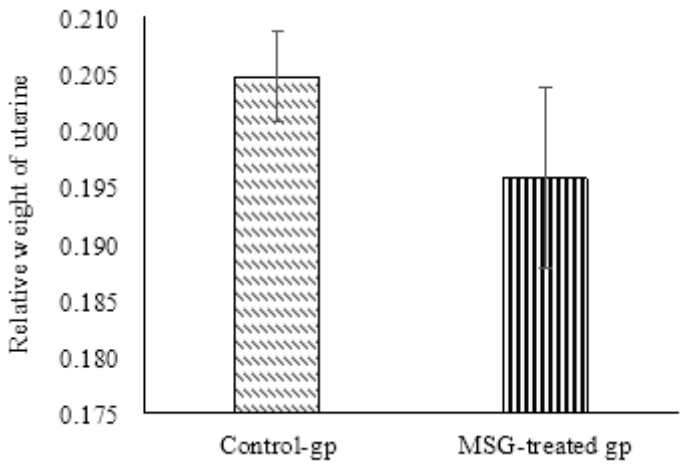


## Figure 2

Effect of MSG on the relative weight of uterine. The values represent the mean ± SEM of the relative weight of uterine. Comparing the mean of the relative weight of uterine tissues in control and the treated groups. At the end of the experiment, the wet uterine trusses were taken using an electronic balance. The student's t-test was used to compare MSG-treated groups with control, and differences were considered significant at $P < 0.05$

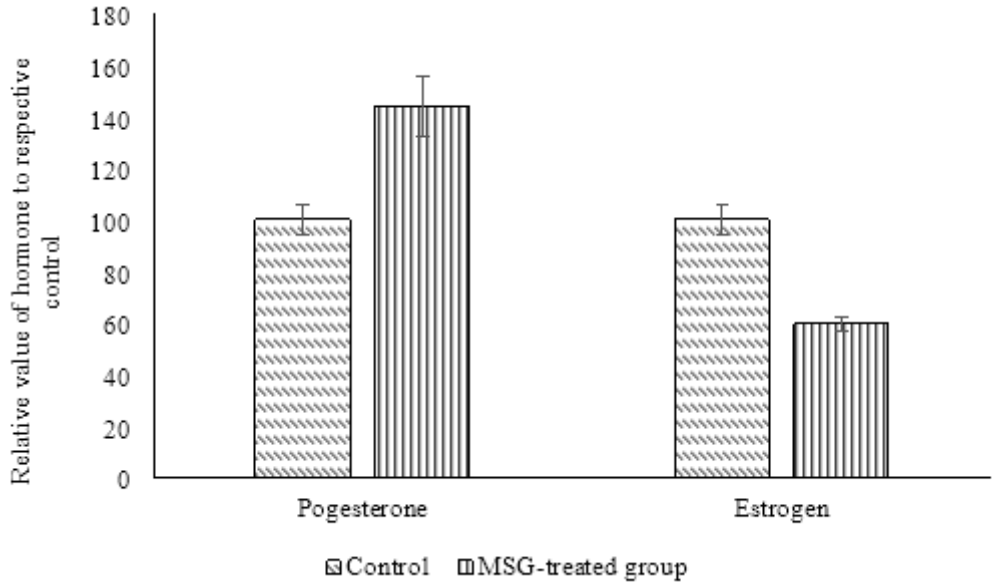


## Figure 3

Effect of MSG on relative values of female sex hormone at estrus phase. The values represent the mean ± SEM of the relative values of hormones to the respective control. The significant difference at P value less than 0.05. Comparing the mean of relative values of estrogen and progesterone in the serum of the control and the treated groups. The chemiluminescent immunoassay (Beckman coulter Access II, USA) was used. Statics performed by student's t-test, comparing MSG-treated groups with control, and differences were considered significant at $P < 0.05$, $*p<0.05$

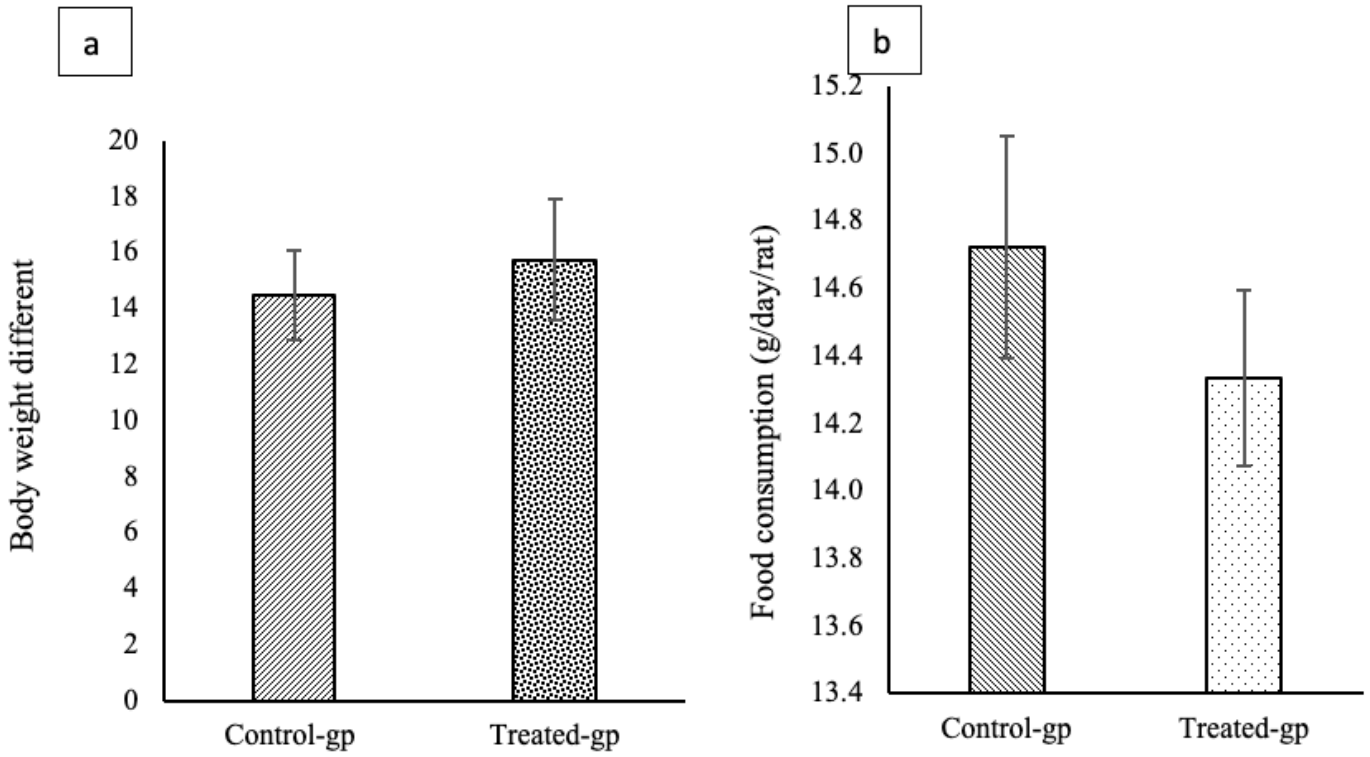


**Figure 4**

Effect of MSG oral administration on body weight and food consumption. The values represent the mean ± SEM of body weight and food consumption. Comparing the mean of different body weights (g) and food consumption (g/day/rat) in the control and the treated groups. The body weight and food consumption were recorded during the experiment. Statics performed by student's t-test, comparing MSG-treated groups with control, and differences were considered significant at $P < 0.05$

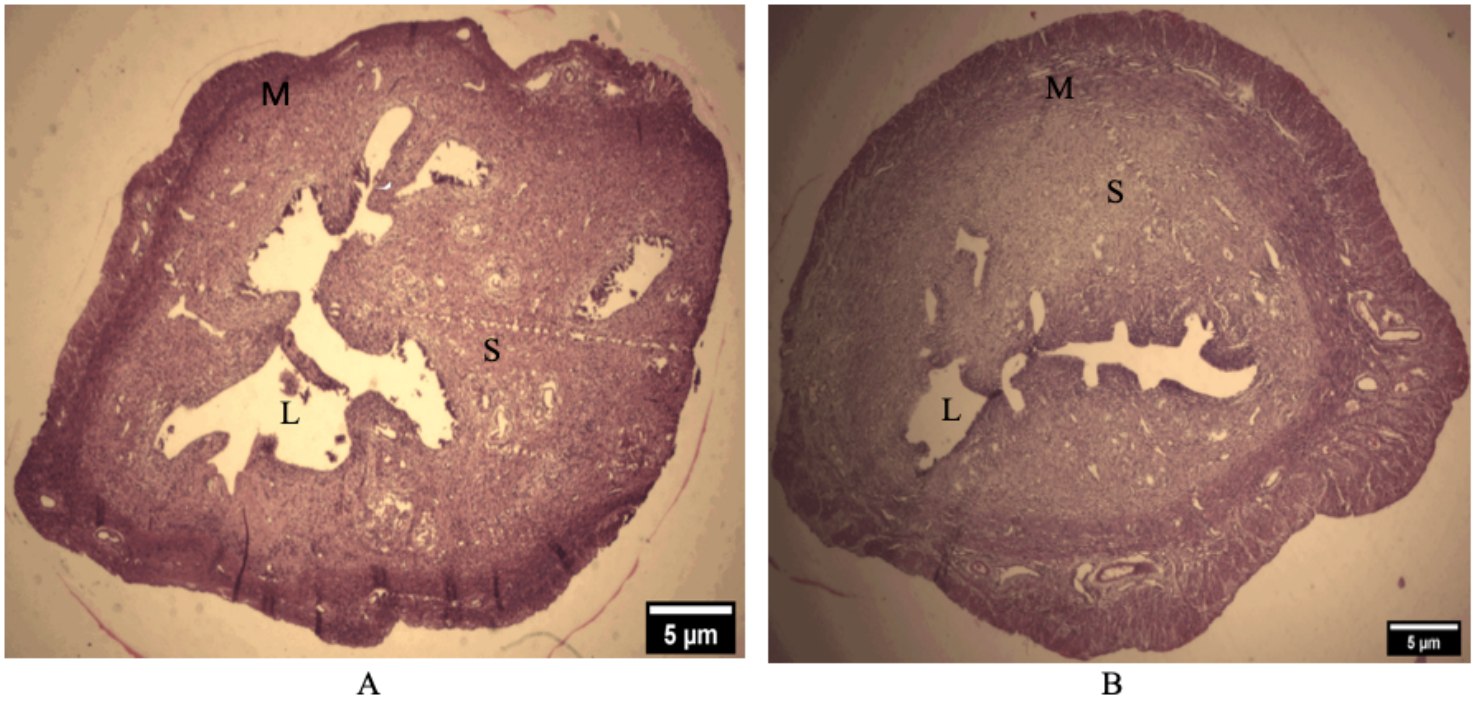


**Figure 5**

Photomicrographs of sections in the rat uterine tissue showing L the lumen area (µm2), S length of stroma (µm) is higher in the control group (A) than treated group (B) and M the length of myometrium in the treated group more (B) than control (H & E, X10). The image of uterine sections was taken at 10x magnifications under a light microscope connects with the camera.

# Supplementary Files

This is a list of supplementary files associated with this preprint. Click to download.

- TheARRIVEguidelines2.0AuthorChecklist.pdf
- supplementaloriginalsourcedata.xlsx