Radiodermatitis as a Consequence of Radiation Recall Induced by Acyclovir: Case Report.

Marcos Tumitan Zorzan (marcostzorzan@gmail.com)
Universidade do Oeste Paulista Faculdade de Medicina https://orcid.org/0000-0002-1046-359X

Renata de Mello Pereira
Universidade do Oeste Paulista Faculdade de Medicina

Lucas Farina Lima
Universidade do Oeste Paulista Faculdade de Medicina

Tatiana Veri de Arruda Mattos
Irmandade da Santa Casa de Misericordia de Sao Paulo

Rafael Sá
Universidade Federal de Sao Paulo

Case report

Keywords: Radiation Recall Dermatitis, Radiodermatitis, Radiotherapy, Acyclovir, Intraductal carcinoma in situ

Posted Date: September 28th, 2020

DOI: https://doi.org/10.21203/rs.3.rs-79463/v1

Abstract

Background: Radiation Recall Dermatitis is defined as an inflammatory reaction in a site of skin previously submitted to radiotherapy, and succeeding the administration of a drug or promoter agent. Manifestations range from mild to severe, resulting in tissue necrosis, treated with removal of the probable causative agent, daily dressings and surgical debridement of the necrotic area.

Case presentation: The patient whose case is reported presented previous diagnosis of intraductal carcinoma in situ, performed lumpectomy and adjuvant radiotherapy and endocrinotherapy. After 1 year of treatment, develops sores suggestive of Herpes Zoster and starts treatment with Acyclovir, concomitantly with the onset of pain, fever, and in the previously irradiated area, breast hardening, skin infiltration and serosanguinolent discharge. Performed incisional biopsy to rule out radioinduced sarcoma, being treated with surgical debridement.

Conclusions: Unlike the cases report of acyclovir drug's eruption, the patient presented radiodermatitis restricted to the skin's tissue in the previously irradiated area, suggestive of the radiation recall. This case report describes the acyclovir as a possible indutor of RRD, a rare condition that requires a better understanding of the disease installation mechanism and the adverse drugs effects after radiotherapy.

1. Introduction

Breast cancer appears as the most common cancer type in women[1]. Approximately 1.97 million diagnoses will be made and 622,000 deaths will occur across the world in 2020. The forecast in USA is that 48,530 new cases of ductal carcinoma in situ will occur, an increase of 0.3% per year, attributed to the constant fall in the fertility rate and the increase in obesity; on the other hand, the death rate decreased, due to better diagnosis, treatment and clinical management of the desease[2]. In Brazil, there are an estimated 17,100 deaths[3], numbers that significantly increase in the 29-49 age group and remain high in the 50-59 age group[1,3,4].

The development of breast cancer occurs from defects in DNA or genes such as BRCA1 and 2 and pro-cancerous, which may be influenced by estrogen[5,6]. Predictive factors include female gender, advanced age and delayed menopause, hormonal contraceptive methods, postmenopausal hormone therapy, a positive family history of breast cancer, benign proliferative breast diseases, obesity, overweight and alcohol intake; some questionable factors are also described in the literature, such as sleep duration, coffee, higher breast density, drugs that stimulate ovulation, abortion, age at menarche and blood type; protective factors include term pregnancy, menstrual cycle, shorter lactation period, physical activity and vitamin D[7-9].

Breast's malignant neoplasm treatment can be local or systemic depending on the stage, location, risk of metastasis and recurrence. There is surgical indication for local cancer control, which may be associated with radiotherapy[5]. Chemotherapy, hormonal therapy or the combination between them seek systemic

control, indicated when there is a risk of recurrence and metastasis or for palliative treatment in advanced stages when surgery is not appropriate[5].

Radiation Recall (RR) is defined as an inflammatory reaction on a local previously irradiated by radiotherapy[10–12] usually occurring after administration of certain promoter agent such as antineoplastic drugs and chemotherapy agents, antituberculosis drugs, antibiotics, tamoxifen, simvastatin and exposure to ultraviolet light[11]. The site most commonly affected by RR is the skin, in this case, it is described as Radiation Recall dermatitis (RRD)[12].

The manifestations vary in intensity and include eruptions maculopapular with erythema and vesicle formation, peeling of the affected skin and even severe skin necrosis, occurring after days to years after the radiation, showing little or none residual reaction resulting from prior radiation[10]. The RRD does not require an acute skin reaction during or at end of the radiotherapies[12].

The radiotherapy uses high energy or gamma rays directly on the tumor or on the affected site after the surgical intervention, promotes local control of the tumor and the death of cancer cells that remain after the traditional surgical approach[5,6]. The radiosensitivity is caused by radiotherapy sessions and are different from RRD, in relation to the time of symptom onset, occurring in up to 7 days after the radiotherapy sessions, while RRD starts after the use of drugs that stimulate this phenomenon[13].

The RRD is a well-known but poorly understood phenomenon. In this report we describe the RRD in a patient with a previous diagnosis of intraductal carcinoma and prophylactic treatment with radiotherapy and tamoxifen, which after one year due to oral administration of acyclovir, an antiviral drug with viral replication inhibiting activity of herpes simplex virus type 1 (HSV-1), 2 (HSV-2) and varicella-zoster virus (VZV), presented the phenomenon[14]. The drug has as common adverse effects events are malaise, nausea, diarrhea, headache and, in rarer cases, immune thrombocytopenia, but is not yet described the relationship with radiodermatitis reinduced[14].

2. Case Description

Female patient, 54 years old, caucasian, married, 4 pregnancies, 4 cesareans, seamstress, no family history of breast cancer, menopause at 42 years, with a history of ovarian cyst exeresis. In September 2015 searched for medical care in a city in the interior of the state of São Paulo with complaint of spontaneous nipple bleeding associated with pain to physical exercise. On physical examination, the breasts were symmetrical, no nodules visualizations, architectural distortions or suspicious calcification. Presence of left uniductal bloody papillary effusion with 6 o’clock trigger point. Mammography and breast ultrasonography were performed, both with BI-RADS 1.

Despite imaging exams showing normality, due to the persistence of suspicious serosanguinous secretion, the patient was forwarded to Regional Hospital’s mastology outpatient clinic at Presidente

Prudente, São Paulo state's city, with indication of lumpectomy/resection of the main ducts in the left breast.

The surgical procedure resected a fragment of the breast's tissue to anatomopathological evaluation, the diagnosis was intraductal carcinoma in situ of low grade, 3mm single focus cribriform standard, ductal ectasia, chronic mastopathy alterations, columnar cell alterations with foci of dystrophic calcification, typical ductal hyperplasia with 1 mm single focus and free circumferential surgical margins. In the immunohistochemistry of the same material, were searched the expression of the oncogene C-erbB-2 (Her-2 SP3), Ki-67 (Mab SP6), Estrogen Receptor (SP1) and Progesterone Receptor (SP2). The immunohistochemistry's profile result has shown positivity for estrogen receptors in about 80% of neoplastic cells, progesterone receptors in about 30%, high rate of cell proliferation measured by Ki-67 (over 14%) and negativity for overexpression of epidermal growth Her-2 factor.

After discharge from the postoperative period, she was referred to radiotherapy, performed in 33 sessions, in the total dose of 5040cGy (180cGy / day). Ensuing, the patient started the use of tamoxifen 20mg / day as endocrinotherapy.

After 1 year of the surgery the patient seeks a dermatologist complaining of left breast's sores, local's hardening and unchecked fever for about 15 days. She reports that she went to the pharmacy near her home and was diagnosed with herpes zoster by the pharmacist, initiating the use of acyclovir 200 mg 6 / 6h during 14 days with onset of breast pain and worsening clinical condition. On physical examination, presence of erythema, hardening and skin infiltration throughout the left breast, presence of serosanguinolent discharge, without signs of herpes zoster or other exclusive skin alteration. She was then referred back to the mastologist (Figure 1a).

At Presidente Prudente's Regional Hospital, an investigation was conducted with chest and upper abdomen computed tomography, and biopsy of the dermal material from the left breast for anatomopathological examination. Macroscopy of the first skin fragment taken for pathological examination presented size 1.0 cm x 0.6 cm, finely grainy surface, brownish color and firm and elastic consistency; in the cuts, the surface was grayish-white. The second fragment with sized 0.6 cm x 0.4 cm, presented on the surface a 0.3 cm raised lesion, vegetative aspect, gray-brown and firm and elastic consistency; in the cuts, the surface was grayish-brown.

The anatomopathological evaluation indicated acute erosive dermatitis, with vascular alterations suggestive of radiotherapy's effects and absence of neoplasia in the material (Figure 2a and 2b). Imaging exams did not show signs of local or distant tumor recurrence. After complete anamnesis and complementary exams, the patient's diagnostic hypothesis was radiation recall, the treatment performed was repeated surgical debridements (figure 1b) associated with papain and SAF-gel® (figure 1c) as recommended by the plastic surgery team. The patient was referred for treatment with hyperbaric chamber (Figure 1d), aiming to complete breast healing and thus avoiding total mastectomy.

3. Discussion And Conclusion

The patient in the case had a previous diagnosis of grade 2 carcinoma in situ with free margins and positive estrogen hormone receptor (ER-positive), was then referred to treat with oncological surgery associated with radiotherapy and use of tamoxifen.

According to Fischer et al., protocol B-17[15], the addition of radiotherapy as an adjuvant treatment after surgery results in the reduction of local recurrence and significantly reduces the number of recurrences in the form of invasive carcinoma, playing a role as a preventive agent since destroys cancer cells and affects the precursors of these cells[15-17]. After 12 years of follow-up of patients submitted to protocol B-17, the reduction in the annual incidence rate of all ipsilateral tumors, invasive or not, remained at 58% per year. The results found in the treatment of ductal carcinoma in situ by the European Organization for Research and Treatment of Cancer (EORTC), are similar to NSABP B17, in which was observed a reduction in local recurrence rate when the group submitted to the lumpectomy was treated with radiotherapy[17].

The use of Tamoxifen, a drug that belongs to the group of selective estrogen receptor modulators[18], in patients with positive estrogen receptors, provides a lower rate of ipsilateral recurrence, as well as a reduction in the occurrence of a new contralateral tumor and recurrence in the form of invasive carcinoma, referenced by the NSABP protocol B24[15,17,19].

In relation to the use of acyclovir, in the literature, some uncommon adverse skin reactions are described: vesicular dermatitis involving palms and soles, peripheral edema, erythema nodosum, rashes, hyperhidrosis, acne, lichenoid and skin rash, pruritus, urticaria, vasculitis and alopecia[10]. However, only one report describes RRD related to the use of acyclovir, in which the rash appeared on the seventh day after oral drug use, with a clinical condition characterized by small macules and erythematous papules involving the trunk and limbs in a symmetrical and bilateral manner, with a predominance in the dermatomes previously affected by Herpes Varicella Zoster[10]. However, characteristics of active HVZ infection were not histopathologically verified, with data associated with drug eruption[10].

The Radiation Recall Dermatitis corresponds to an event widely described in the literature, occurring in patients subjected to radiotherapy with precipitated symptoms after the use of specific drugs, such as: Actinomycin D, Adriamycin, Bleomycin, Docetaxel, Etoposide, 5- Fluorouracil, Gemcitabine, Hydroxyurea, Methotrexate, Paclitaxel, Simvastatin, Tamoxifen, Antituberculosis such as rifampicin, isoniazid and pyrazinamide, Trimetrexate and Vinblastine, among other agents such as ultraviolet radiation[13,20]. The radiodermatitis clinic manifests itself in 4 degrees of toxicity: grade 1 (mild) with erythema, pruritus and dry flaking, grade 2 (mild-moderate) presents with pain, edema, urticaria or the appearance of vesicles, grade 3 (moderate) which appears wet desquamation and grade 4 (severe) that presents necrosis, ulcer or hemorrhage[20,21].

The precise mechanism of the RRD is unknown, however, several hypotheses are described. One of the hypotheses attributes changes in vascular permeability in the irradiated area as a precipitating factor for altering the drug's kinetics in that region, creating a hypersensitivity reaction, leading to acute inflammation[22]. Another accepted hypothesis is related to radiation changes in localized cellular DNA, promoting increased expression of inflammatory cytokines, such as IL-1, IL-6 and TNF-alpha, in the presence of the event-inducing drug[23].

The patient described, after acyclovir use for the treatment of unproven HVZ, presented, different from a drug eruption, onset of breast pain, dermal lesions and fever (not measured), with clinical evolution to grade 4 radiodermatitis, characterized by serosanguinolent secretion accompanied by erythema, hardening and infiltration in left breast's skin, in the previously irradiated area, without signs of herpes zoster and without involvement of the breast tissue, treated with removal of the probable causative agent (Acyclovir), daily dressings and surgical debridement without complications. Imaging exams excluded the possibility of locoregional or distant tumor recurrence, and the anatomopathological examination indicated acute erosive dermatitis with vascular alterations suggestive of radiotherapy effect and absence of neoplasia in the material, which suggests as a diagnostic hypothesis radiation recall radiodermatitis due the use of acyclovir.

For ductal carcinoma in situ's treatment, whenever possible, the conservative treatment is realized followed by radiation therapy and endocrine therapy to reduce the occurrence of local, contralateral recurrence and invasive carcinoma[15]. However, in some cases total mastectomy is indicated, and the immediate breast reconstruction should be analyzed[15]. For the therapeutic success, the control and prevention of the tumor and the treatment must proceed with the clinical and image evaluation periodically, informing the patient about the possibility of recurrence and the resulting risks.

The manifestation of RRD is described in different degrees of tissue involvement induced by different drug classes, however it is very rarely described in association with the use of acyclovir. Due to the absence of known pharmacological characteristics capable of inducing this clinical condition and for a better diagnosis and management of patients, it is necessary not only a better understanding of the disease and the adverse effects of post-radiation therapy medications, but also the use of the lowest effective radiotherapy dose for the desease's.

4. Abbreviations

RR: Radiation Recall; RRD: Radiation Recall Dermatitis; HSV-1: herpes simplex virus type 1; HSV-2: herpes simplex virus type 2; VZV: varicella-zoster virus; HVZ: Herpes Varicella Zoster; EORTC: European Organization for Research and Treatment of Cancer; ER: estrogen hormone receptor.

European Organization for Research and Treatment of Cancer (EORTC),

Herpes Varicella Zoster (HVZ)

estrogen hormone receptor (ER-positive

5. Declarations

Ethics approval and consent to participate:

This case report was approved by our institutional review board and ethics committee. The patient provided consent for publication of her clinical experience.

Consent for publication:

The patient provided consent to publication of her clinical experience.

Availability of data and materials:

Not applicable. All data generated or analyzed during this study are included in this published article and its supplementary information.

Competing interests:

The authors declare that they have no competing interests.

Funding:

None to declare.

Authors' contributions:

MTZ and RMP wrote this report. RS and LFL revised the manuscript. TVAM provided the images used in the report. MTZ, LFL, RMP and RS saw the patient in hospital and contributed the case history notes used in this report. RS performed the clinical treatment and the lumpectomy. All authors read and approved the final manuscript.

Acknowledgements:

We acknowledge our patient for providing informed consent for this case report and for her willingness to have her clinical experience published. We acknowledge TVAM for the work in the Pathology Department in offering the original images and data related to this article.

6. References

1. Rocha-Brischiliari SC, de Oliveira RR, Andrade L, Brischiliari A, Gravena AAF, Carvalho MD de B, et al. The Rise in Mortality from Breast Cancer in Young Women: Trend Analysis in Brazil. PLoS One [Internet]. January 3, 2017 [cited 2020 July 07];12(1). Avaible in: https://www.ncbi.nlm.nih.gov/pmc/articles/PMC5207532/

2. Siegel RL, Miller KD, Jemal A. Cancer statistics, 2020. CA: A Cancer Journal for Clinicians. 2020;70(1):7–30.
3. Carioli G, Malvezzi M, Rodriguez T, Bertuccio P, Negri E, La Vecchia C. Trends and predictions to 2020 in breast cancer mortality: Americas and Australasia. The Breast. february de 2018;37:163–9.
4. Kluthcovsky ACGC, Faria TNP, Carneiro FH, Strona R, Kluthcovsky ACGC, Faria TNP, et al. Female breast cancer mortality in Brazil and its regions. Revista da Associação Médica Brasileira. 2014;60(4):387–93.
5. Alkabban FM, Ferguson T. Cancer, Breast. In: StatPearls [Internet]. Treasure Island (FL): StatPearls Publishing; 2020 [cited 2020 July 07]. Disponível em: http://www.ncbi.nlm.nih.gov/books/NBK482286/
6. Sharma GN, Dave R, Sanadya J, Sharma P, Sharma KK. VARIOUS TYPES AND MANAGEMENT OF BREAST CANCER: AN OVERVIEW. J Adv Pharm Technol Res. 2010;1(2):109–26.
7. Momenimovahed Z, Salehiniya H. Epidemiological characteristics of and risk factors for breast cancer in the world. Breast Cancer (Dove Med Press). April 10 de abril de 2019;11:151–64.
8. Inumaru Lívia Emi, Silveira Érika Aparecida da, Naves Maria Margareth Veloso. Fatores de risco e de proteção para câncer de mama: uma revisão sistemática. Cad. Saúde Pública [Internet]. 2011 July [cited 2020 July 07] ; 27(7): 1259-1270. Available from: http://www.scielo.br/scielo.php?script=sci_arttext&pid=S0102- 311X2011000700002&lng=en. https://doi.org/10.1590/S0102-311X2011000700002.
9. Anothaisintawee T, Wiratkapun C, Lerdsitthichai P, Kasamesup V, Wongwaisayawan S, Srinakarin J, et al. Risk factors of breast cancer: a systematic review and meta-analysis. Asia Pac J Public Health. september de 2013;25(5):368–87.
10. Carrasco L, Pastor MA, Izquierdo MJ, Fariña MC, Martín L, Fortes J, et al. Drug eruption secondary to aciclovir with recall phenomenon in a dermatome previously affected by herpes zoster. Clin Exp Dermatol. march 2002;27(2):132–4.
11. Azria D, Magné N, Zouhair A, Castadot P, Culine S, Ychou M, et al. Radiation recall: a well recognized but neglected phenomenon. Cancer Treat Rev. november 2005;31(7):555–70.
12. Kim GE, Song H-S, Ahn KJ, Kim YS. Radiation recall dermatitis triggered by sorafenib after radiation therapy for hepatocellular carcinoma. Radiat Oncol J. setember 2017;35(3):289–94.
13. Boström A, Sjölin-Forsberg G, Wilking N, Bergh J. Radiation recall–another call with tamoxifen. Acta Oncol. 1999;38(7):955–9.
14. Hong X, Wang X, Wang Z. A rare case report of acyclovir-induced immune thrombocytopenia with tongue hematomas as the first sign, and a literature review. BMC Pharmacol Toxicol. 7 march 2017;18(1):12.
15. Biazús JV, Schuh F. Carcinoma in situ: revisão. Carcinoma in situ. :6.
16. Lumpectomy and radiation therapy for the treatment of intraductal breast cancer: findings from National Surgical Adjuvant Breast and Bowel Project B-17. | Journal of Clinical Oncology [Internet]. [cited 2020 july 7]. Avaible in: https://ascopubs.org/doi/10.1200/jco.1998.16.2.441

17. Fisher B, Land S, Mamounas E, Dignam J, Fisher ER, Wolmark N. Prevention of invasive breast cancer in women with ductal carcinoma in situ: An update of the National Surgical Adjuvant Breast and Bowel Project experience. Seminars in Oncology. 1 august 2001;28(4):400–18.
18. Patterson J, Furr B, Wakeling A, Battersby L. The biology and physiology of 'Nolvadex' (tamoxifen) in the treatment of breast cancer. Breast Cancer Res Tr. 1 december 1982;2(4):363–74.
19. Rhee J, Kim GE, Lee CH, Kwon J-M, Han S-H, Kim YS, et al. Radiation recall dermatitis induced by tamoxifen during adjuvant breast cancer treatment. Radiat Oncol J. december de 2014;32(4):262–5.
20. Camidge R, Price A. Characterizing the phenomenon of radiation recall dermatitis. Radiotherapy and Oncology. 1 june 2001;59(3):237–45.
21. Mehta K, Kaubisch A, Tang J, Pirlamarla A, Kalnicki S. Radiation Recall Dermatitis in Patients Treated with Sorafenib. Case Rep Oncol Med. 2018;2018:2171062.
22. Phillips TL, Fu KK. Quantification of combined radiation therapy and chemotherapy effects on critical normal tissues. Cancer. february 1976;37(2 Suppl):1186–200.
23. Oanta A, Irimie M. Radiation Recall Dermatitis Induced By Tamoxifen. Bulletin of the Transilvania University of Brasov, Seriels VI: Medical Sciences. 2012 Jul 1;5(2).

Figures

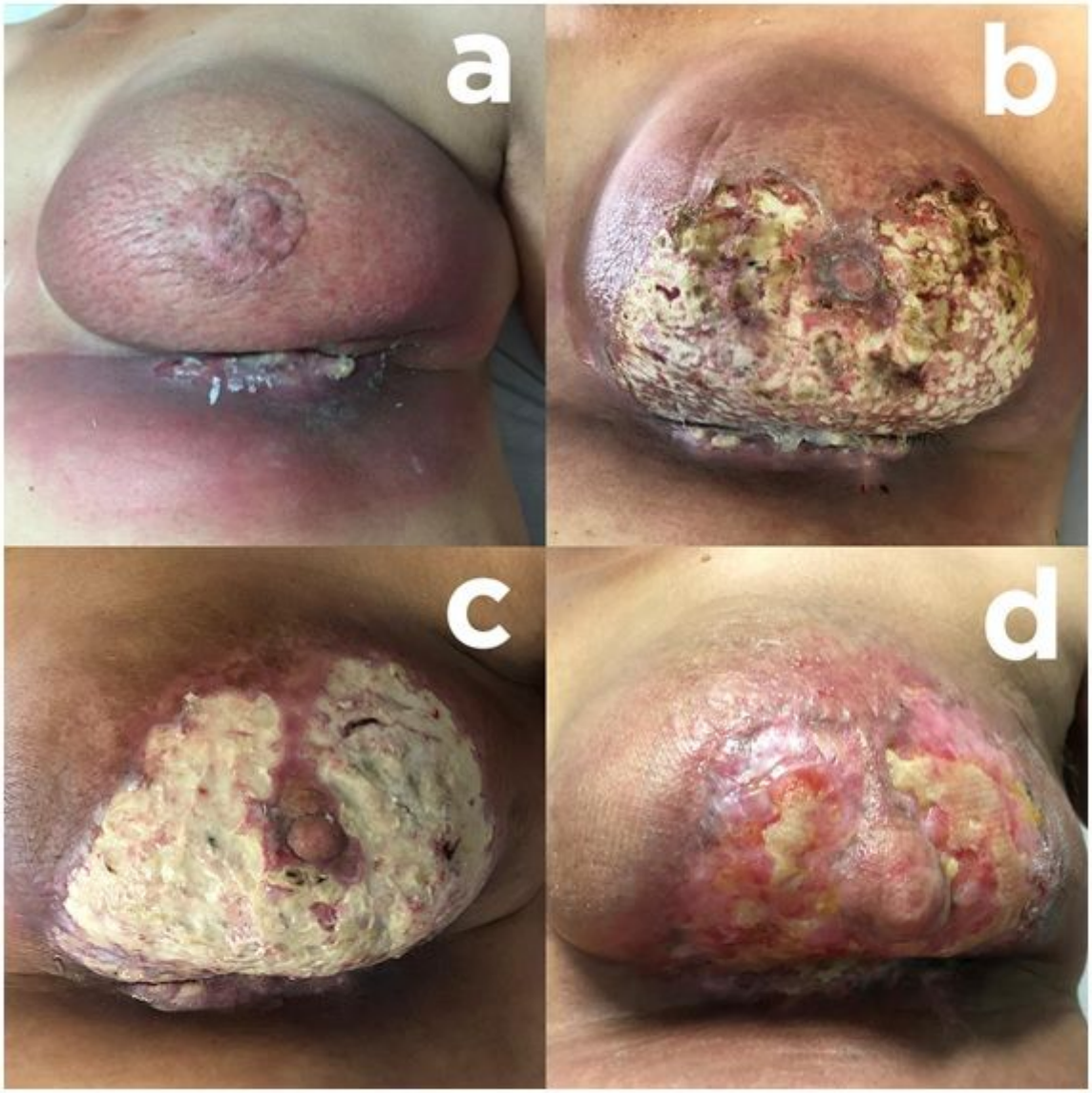

Figure 1

Clinical Evolution Legend: 1a) Hyperemic breast with serosanguinolent secretion. 1b) Breast after surgical debridement. 1c) Supportive treatment with papain and SAF-gel®. 1d) breast in the healing process, with hyperbaric therapy.

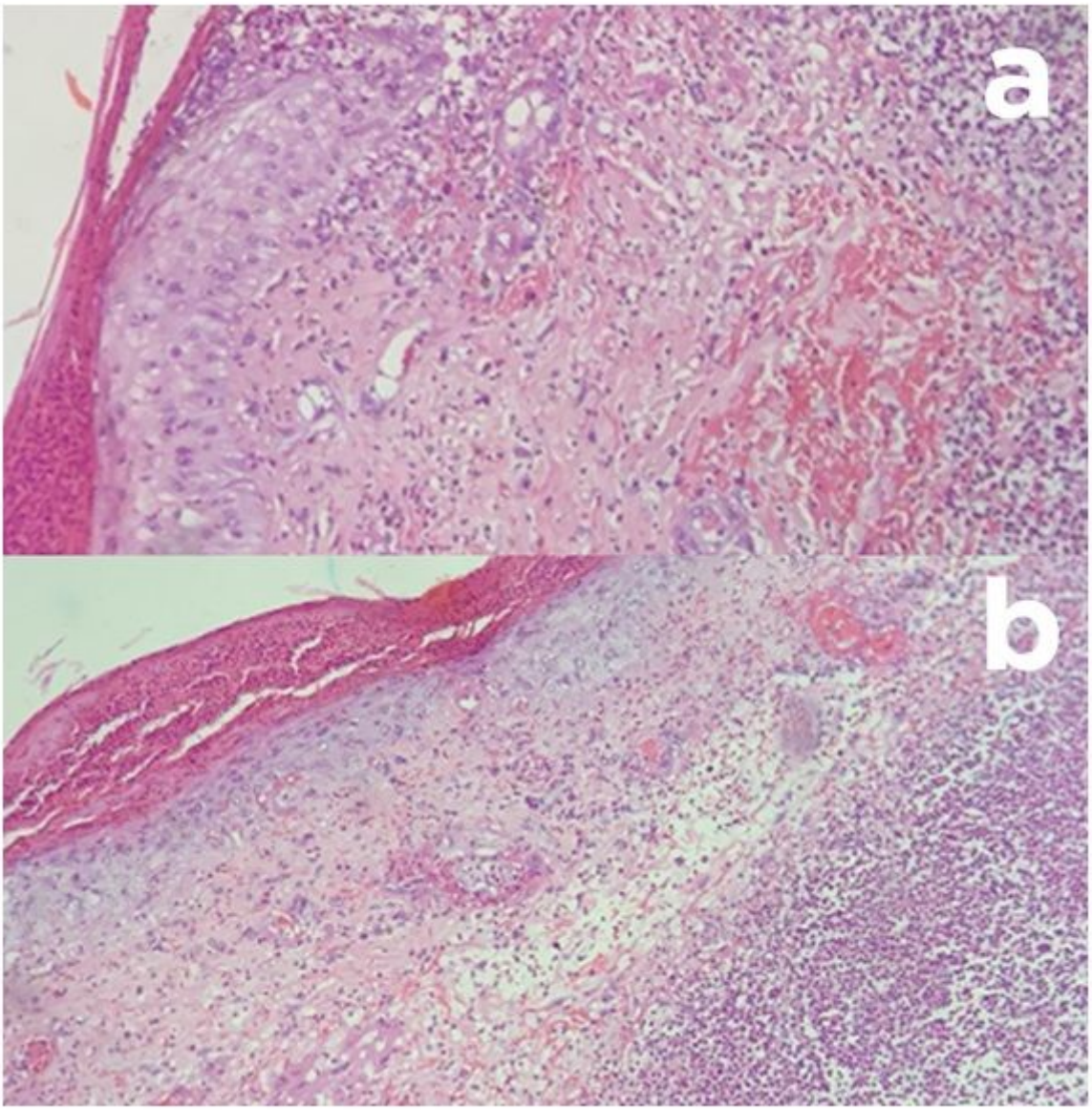

Figure 2

Anatomopathological Evaluation Legend: 2a) The Hematoxylin-Eosin stain with 40x magnification shows intense neutrophilic exudate throughout the epidermis and dermis. 2b) The Hematoxylin-Eosin stain with 100x magnification shows the ulcerated epidermis with foci of parakeratosis and acanthosis, liquefactive and atypical reactions of the basal layer. In the dermis, fibrosis and elastosis are noted, with intense fibrinoid exudate and vascular thickening with extravasation of red blood cells.