Oval Forceps Assisted with Small Incision for Minimally Invasive Treatment of Acute Achilles Tendon Rupture

Yan-Rui Zhao
Beijing Chao-Yang Hospital: Beijing Chaoyang Hospital
Yang Liu
Beijing Chao-Yang Hospital: Beijing Chaoyang Hospital
Bo Yin
Beijing Chao-Yang Hospital: Beijing Chaoyang Hospital
Yihan Li
Beijing Chao-Yang Hospital: Beijing Chaoyang Hospital
Meng Guo
Beijing Chao-Yang Hospital: Beijing Chaoyang Hospital
Junlin Zhou (doctorzyr@163.com)
Beijing Chaoyang Hospital

Research

Keywords: Achilles, Rupture, Minimally Invasive, Oval Forceps

Posted Date: September 21st, 2020

DOI: https://doi.org/10.21203/rs.3.rs-79507/v1

Abstract

Purpose: To review the clinical outcomes of treatment acute Achilles tendon rupture using oval forceps assisted with small incision.

Methods: This was a retrospective study of 23 patients with acute Achilles tendon rupture treated with this technique. Distance from calcaneal insertion to rupture site and the operation time were recorded. During follow-up, all the occurrence of complications was recorded. The AOFAS score and the ROM of the repaired ankle joint were recorded at 3 and 6 months.

Results: All patients were followed up for 7-15 months. There have no cases of Achilles tendon re-rupture and sural nerve injury were found. All incisions healed by first intention, except for one case of delayed suture knot irritation. The AOFAS score was 82–100 (median, 92) at 3 months and 92–100 (median, 98) at 6 months. The 3-month ROM was 28–37, and the 6-month ROM was 36–49.

Conclusion: The technique of oval forceps assisted with small incision for minimally invasive treatment of acute Achilles tendon rupture is a safe, reliable, and have an extremely low complication rate. Furthermore, this technique is easy to learn, utilizes simple instruments, and is cost-effective, making this technique an attractive alternative to traditional techniques.

Introduction

The Achilles tendon is the strongest tendon in the human body and transmits forces from the soleus and gastrocnemius muscles to the calcaneus, which enabling jumping, walking and running [1]. Acute rupture of the Achilles tendon is common, especially in recreational athletes aged 30–49 years, with a male-to-female ratio of 3:1[2]. A 2014 population-based study reported an increasing incidence of acute Achilles tendon rupture, particularly in the age group of 49–60 years [3]. Acute rupture of the Achilles tendon has an annual incidence rates up to 21.5–24 per 100,000 persons [4, 5]. Although orthopaedic surgeons encounter this condition relatively frequently, their treatment remains controversial. The treatment options contain nonoperative or operative via minimally invasive or traditional open techniques. The primary goals of the treatment of acute Achilles tendon ruptures have not changed in the past 15 years, which are to ensure a rapid return to full function and to prevent kinds of complications. The most commonly used technique for traditional open repair uses Krackow locking sutures to bring all the torn Achilles tendon together for end-to-end repair with the foot in plantarflexion [6]. However, the infections and wound-healing complications occur high to 2.4%-4.7% in surgical patients, and increase to 10.4% of patients with risk factors like smoking, diabetes, or steroid use [7–9]. Minimally invasive repairs for acute Achilles tendon ruptures have been developed in recent years to improve functional results and recovery time and to lower the incidence of postoperative complications [10–12]. Since the first report of minimally invasive repair in 1977, numerous minimally invasive options have been described [10–15]. Recently, a meta-analysis has demonstrated that minimally invasive techniques have equivalent re-rupture rates, significantly lower infection risk and higher patient satisfaction rates [16]. We found the same outcome by small incision repair of acute Achilles tendon ruptures using oval forceps. I will report this technique as follow. This technique was following the technique of Elton and Bluman [17], and made some minor improvements.

Methods

Patients

This study was approved by Institutional review board of Beijing Chao-Yang Hospital prior to initiation. All patients signed a surgical consent form. This study was a retrospective study of consecutive patients treated for acute Achilles tendon rupture from January 2017 to December 2019, at Beijing Chao-Yang Hospital. Twenty-three patients were eligible. The diagnosis of the acute Achilles tendon rupture was made based on patient history, physical examination, ultrasound and magnetic resonance imaging. Inclusion criteria for this study include (1) patients with an acute rupture of the Achilles tendon, (2) within 2 weeks of injury, (3) positive Thompson Test and touching palpable gap at the rupture sites of Achilles tendon, (4) Both ultrasound and magnetic resonance imaging showing that the Achilles tendon was completely ruptured (Fig. 2A), (5) the Achilles tendon rupture occurring between 2–8 cm proximal to the calcaneal insertion. Exclusion criteria contain (1) skeletally immature patients, (2) open rupture of Achilles tendons, (3) incomplete clinical data, (4) history of connective tissue disorders, (5) periosteal sleeve avulsions, (6) chronic tears (defined here as > 2 weeks). All clinic and operative notes were carefully reviewed to make sure the inclusion of only those with an acute rupture of Achilles tendon.

Operative Technique

Surgery was performed under spinal anesthesia or general anesthesia. The patients were positioned as prone with a pad under the ankle. A tourniquet was placed around the thigh using for hemostasis. All surgeries were performed by the same surgeon (Fig. 1). Found the attachment for the vedio of surgical operation.

1. The gap at the site of the Achilles rupture is palpated and a 2–3 cm vertical incision is made over the Achilles tendon centered at the injury site.
2. The teared ends were cleared of blood clots, trimmed, and then pulled with Allis clamps or toothed forceps into the incision. Subcutaneous tunnel between the paratenon and Achilles tendon was made by forceps or small retractor. This is repeated distally to allow the oval forceps pass through the lateral and medial aspects of the Achilles tendon.
3. The oval forceps were inserted into the sheath beneath the paratenon, and the proximal Achilles tendon was gently grasped to ensure containment between eyelet rings. The position of the Achilles between oval forceps eyelet rings can be confirmed by palpation.
4. Lumbar puncture needle was passed sequentially through the lateral skin, the lateral ring of the oval forceps, the tendon, the medial ring, and the medial skin. Then a #0 absorbable suture was passed through the needle. Removing the needle and withdrawing the oval forceps with the suture tails into the incision. All suture ends should be carefully separated and maintained as “medial” or “lateral” strands. Stitching effect and adequate strength in the Achilles tendon were confirmed by gentle traction the sutures. This method minimizes the risk of entrapping the sural nerve. This sequence was repeated a total of 3 times in the proximal Achilles tendon, and the distance approximately 0.8 cm between each stitch sutures. The same process was repeated performed in the distal Achilles tendon. A #2 nonabsorbable suture was used in the middle sutures.
5. The ankle is plantar-flexed to reapproximated the rupture Achilles tendon ends, and the sutures were tied firmly. The closest suture was tied above all, then the middle one, and finally the furthest. To prevent concentrated and prominent of suture knots, one side of the same sutures was tied, gentle traction the ends

of the sutures to conceal the knots beneath the paratenon, then tied another side. The last but most important that the Achilles tendon adventitia was stitched to cover the knots in incision.

6. Layer by layer sutured of the paratenon, subcutaneous tissue, and the skin. A plaster splint is applied in plantar flexion.

Postoperative Management

Postoperatively, the ultra-knee long-leg cast front support was used to fix the affected limb at 30-degree knee flexion and 30-degree plantar flexion for 2 weeks, and the short-leg cast front support was used to fix the affected limb at 30-degree flexion for 2–4 weeks, and then replaced with walking brace for 4–6 weeks, and walk with weight bearing. Remove a piece of shims every 3–5 days, a total of 10–12 pieces. After all the shims are removed, walk in normal shoes. After 12 weeks, strength training can be performed gradually, such as jogging (Fig. 2BC). Enoxaparin (40 mg, Qd, subcutaneous injection) was administrated to prevent deep vein thrombosis for 4 weeks.

Outcome Measures

Distance from calcaneal insertion to rupture site and the operation time were recorded. During follow-up, all the occurrence of complications was recorded, such as incision infection, skin necrosis, deep infection, sural nerve injury, re-rupture, and deep venous thrombosis, etc. The American Orthopedic and Ankle Association (AOFAS) score [18] and the range of motion (ROM) of the repaired ankle joint were recorded at 3 and 6 months. Among them, excellent > 90 points, good 75 ~ 89 points, fair 50 ~ 74 points, and poor < 50 points.

Statistical Analysis

Descriptive statistics were used to describe the general patient data. Normally distributed data were expressed as mean ± standard deviation (SD); otherwise, data were expressed as median and range. Data analyses were performed using SPSS 19.0 (Chicago, IL, USA).

Results

The baseline characteristics of the 23 patients are shown in Table 1. In this study, 19 patients were male and 4 were female. They were aged 18–55 years (median, 38 years). The causes of injury were sports in all cases (badminton, n = 12; basketball, n = 6; football, n = 4; and running, n = 1). MRI showed complete rupture in all cases at 33–70 mm (median, 50 mm) from the calcaneal insertion. The operation time was 30–55 min, median of 45 min.

Table 1
Characteristics of the patients and postoperative follow-up index

ID	Age (years)	Gender	Cause of injury	Distance measure (mm)	Operation time (min)	3-month AOFAS	6-month AOFAS	3-month ROM	6-month ROM
1	37	male	badminton	58	40	90	96	34	40
2	22	male	basketball	62	45	88	98	32	43
3	47	male	badminton	60	45	98	100	34	45
4	26	male	football	50	35	92	96	30	42
5	51	female	badminton	33	55	92	98	37	46
6	28	male	basketball	36	50	84	94	31	44
7	18	male	basketball	38	40	82	92	29	36
8	38	male	football	40	30	100	100	28	40
9	39	female	badminton	44	35	94	98	30	41
10	48	male	badminton	55	45	94	96	35	46
11	55	male	badminton	70	50	90	100	32	41
12	51	male	badminton	47	40	96	98	29	42
13	46	male	badminton	43	35	96	96	33	45
14	42	female	badminton	54	45	92	98	34	42
15	33	male	football	58	50	86	94	32	42
16	24	male	badminton	43	50	88	98	36	49
17	39	male	badminton	38	45	90	100	33	46
18	47	male	basketball	55	35	92	98	34	44
19	20	male	basketball	46	45	94	96	33	43
20	53	female	badminton	63	45	90	94	30	40
21	26	male	basketball	46	30	92	100	35	42
22	35	male	football	52	45	94	100	36	48
23	38	male	running	57	50	92	96	32	45
Median	38	-	-	50	45	92	98	33	43
Range	18–55	-	-	33–70	30–55	82–100	92–100	28–37	36–49

The 23 patients were followed up for 7–15 months (median, 11.5 months). All incisions healed by first intention, without incision infection or split, skin necrosis, and deep infection, except for one case of delayed suture knot irritation (5 months after operation, besides, this patient has Psoriasis skin disease). During follow-up, there have no cases of Achilles tendon re-rupture and sural nerve injury were found in this study. The AOFAS score of the affected side was 82–100 (median, 92) at 3 months and 92–100 (median, 98) at 6 months. The 3-month ROM was 28–37 (median, 33), and the 6-month ROM was 36–49 (median, 43).

Discussion

The optimal treatment for acute Achilles tendon ruptures remains controversial, with multiple studies and meta-analyses supporting both operative and nonoperative treatment [16, 19–20]. Recently, there has been enthusiasm for minimally invasive techniques to treatment for acute Achilles tendon ruptures. But the treatment effect is not very satisfactory. Cretnik et al [21] reported that the complication rates for percutaneous repair and open repair were 9.7% and 21% respectively. Wren et al [22] reported that minimally invasive percutaneous methods can have a relatively high sural nerve injury rate, which is 0–10%. Another article report that sural nerve injury rates up to 9%- 18% of percutaneous Achilles repair cases [23]. Moreover, there have no cases of sural nerve injury were found of the twenty-three patients in this study. Cause most operations were under direct vision, the oval forceps were inserted into the sheath beneath the paratenon, so the incidence of sural nerve injury is very low.

With the method used in this study, the incidence of soft tissue complications was significantly reduced, comparison with the traditional operation which skin necrosis, superficial infection and deep infection are occurred in 11–34.1% of the cases [24]. There was only one case of reoperation for delayed suture knot irritation (5 months after operation, besides, this patient has Psoriasis skin disease). This case only using superficial debridement with suture knot excision. And the Achilles tendon heals well with good continuity, so revision Achilles repair was not required. The main reasons for these complications with traditional operation are the larger incision and trauma, and the wrinkled skin after suture.

Nevertheless, A biomechanical research reported that the mechanical resistance was decreased 50% when using percutaneous repair compared with traditional repair [25], following a high risk of Achilles tendon re-rupture [15, 26]. The main reason is because the torn sites are generally not revealed [27]. However, with the advancement of surgery technology, the Achilles tendon re-rupture rate of minimally invasive surgery is comparable to open surgery [10–13]. No re-rupture of the Achilles tendon occurred in this study.

This study found that Achilles ruptures were highly associated with sporting activity, particularly badminton activity (52%) and age less than 55 years. These findings are similar to Raikin’s reports, except the most common activity was basketball (48%) [28]. Most patients with Achilles tendon rupture were caused by doing sports during the weekend, which may be related to the patient's lack of exercise usually and the sudden vigorous sports on the weekend.

The present operation technique is very easy to master. And it is also an economically method. This technique was following the technique of Elton and Bluman [17], and made some minor improvements. Here are some surgical points as following. (1) The incision is made longitudinal direction with the Achilles tendon, as close as possible to the proximal stump, to facilitate search and pull the proximal stump out. And the remote stump can

be obtained through plantar flexion of the ankle. (2) Stitching effect and adequate strength in the Achilles tendon were confirmed by gentle traction the sutures. (3) To prevent concentrated and prominent of suture knots, one side of the same sutures was tied, gentle traction the ends of the sutures to conceal the knots beneath the paratenon, then tied another side. (4) To cover the knots in incision by stitching the Achilles tendon adventitia.

Limitations

First, this is a retrospective uncontrolled study. Secondly, the number of patients is relatively small and the follow-up time is short. Finally, biomechanical experiments of acute Achilles tendon rupture should be studied in the future.

Conclusion

The technique of oval forceps assisted with small incision for minimally invasive treatment of acute Achilles tendon rupture is a safe, reliable, and have an extremely low complication rate. Furthermore, this technique is easy to learn, utilizes simple instruments, and is cost-effective, making this technique an attractive alternative to traditional techniques.

Declarations

Ethics approval and consent to participate

This study was approved by Institutional review board of Beijing Chao-Yang Hospital prior to initiation. All patients signed a surgical consent form.

Consent for publication

The authors declare that they agree with publication.

Availability of data and materials

All data are fully available without restriction.

Competing interests

The authors declare that they have no competing interests.

Funding

There is no funding about this paper.

Authors' contributions

Jun-Lin Zhou designed the study; Yan-Rui Zhao is the chief surgeon; Yang Liu, Bo Yin, Yihan Li and Meng Guo are the assistants, they collected the data, followed up the patients and analyzed the data; and Yan-Rui Zhao wrote the paper.

Acknowledgements

This study was a retrospective study. We thank all the patients who were included.

References

[1] X. Yang, H. Meng, Q. Quan, J. Peng, S. Lu, A. Wang (2018) Management of acute Achilles tendon ruptures. Bone Joint Res, 7:561-569.

[2] Ganestam A, Kallemose T, Troelsen A, Barfod KW (2016) Increasing incidence of acute Achilles tendon rupture and a noticeable decline in surgical treatment from 1994 to 2013. A nationwide registry study of 33,160 patients. Knee Surg Sports Traumatol Arthrosc, 24:3730-7.

[3] Huttunen TT, Kannus P, Rolf C, Felländer-Tsai L, Mattila VM (2014) Acute Achilles tendon ruptures: Incidence of injury and surgery in Sweden between 2001 and 2012. Am J Sports Med, 42(10):2419-2423.

[4] Gwynne-Jones DP, Sims M, Handcock D (2011) Epidemiology and outcomes of acute Achilles tendon rupture with operative or nonoperative treatment using an identical functional bracing protocol. Foot Ankle Int, 32(4):337-343.

[5] Lantto I, Heikkinen J, FlinkkilaT, Ohtonen P, Leppilahti J (2015) Epidemiology of Achilles tendon ruptures: increasing incidence over a 33-year period. Scand J Med Sci Sports, 25(1): e133-e138.

[6] Krackow KA, Thomas SC, Jones LC (1988) Ligament-tendon fixation: analysis of a new stitch and comparison with standard techniques. Orthopedics, 11(6):909-917.

[7] Bruggeman NB, Turner NS, Dahm DL, et al (2014) Wound complications after open Achilles tendon repair: an analysis of risk factors. Clin Orthop Relat Res, (427):63-66.

[8] Khan RJK, Fick D, Keogh A, Crawford J, Brammar T, Parker M (2005) Treatment of acute Achilles tendon ruptures: a meta-analysis of randomized, controlled trials. J Bone Joint Surg Am, 87(10):2202-2210.

[9] Wilkins R, Bisson LJ (2012) Operative versus nonoperative management of acute Achilles tendon ruptures: a quantitative systematic review of randomized controlled trials. Am J Sports Med, 40(9):2154-2160.

[10] Hrnack SA, Crates JM, Barber FA (2012) Primary Achilles tendon repair with mini-dorsolateral incision technique and accelerated rehabilitation. Foot Ankle Int, 33(10):848-851.

[11] Keller A, Ortiz C, Wagner E, Wagner P, Mococain P (2014) Mini-open tenorrhaphy of acute Achilles tendon ruptures: medium-term follow-up of 100 cases. Am J Sports Med, 42(3):731-736.

[12] Tejwani NC, Lee J, Weatherall J, Sherman O (2014) Acute Achilles tendon ruptures: a comparison of minimally invasive and open approach repairs followed by early rehabilitation. Am J Orthop, 43(10): E221-E225.

[13] Andrew R.H, Carroll P. J, et al (2015) Clinical Outcomes and Complications of Percutaneous Achilles Repair System Versus Open Technique for Acute Achilles Tendon Rupture. Foot & Ankle International®, Vol. 36(11) 1279-1286.

[14] Webb JM, Bannister GC (1999) Percutaneous repair of the ruptured tendon Achilles. J Bone Joint Surg Br, 81(5):877-880.

[15] Carmont MR, Maffulli N (2008) Modified percutaneous repair of ruptured Achilles tendon. Knee Surg Sports Traumatol Arthrosc, 16(2): 199-203.

[16] McMahon SE, Smith TO, Hing CB (2011) A meta-analysis of randomized controlled trials comparing conventional to minimally invasive approaches for repair of an Achilles tendon rupture. Foot Ankle Surg, 17(4):211-217.

[17] Elton JP, Bluman EM (2010) Limited open Achilles tendon repair with modified ring forceps: technique tip. Foot Ankle Int, 31:914-915. doi:10.3113/FAI.2010.0914

[18] Kitaoka HB, Alexander IJ, Adelaar RS, Nunley JA, Myerson MS, Sanders M (1994) Clinical rating systems for the ankle-hindfoot, midfoot, hallux, and lesser toes. Foot Ankle Int, 15:349-53.

[19] Chiodo CP, Glazebrook M, Bluman EM, et al (2010) American Academy of Orthopaedic Surgeons clinical practice guideline on treatment of Achilles tendon rupture. J Bone Joint Surg Am, 92(14):2466-2468.

[20] Nilsson-Helander K, Silbernagel KG, Thomee R, et al (2010) Acute Achilles tendon rupture: a randomized, controlled study comparing surgical and nonsurgical treatments using validated outcome measures. Am J Sports Med, 38(11):2186-2193.

[21] Cretnik A, Kosanovic M, Smrkolj V (2005) Percutaneous versus open repair of the ruptured Achilles tendon: a comparative study. Am J Sports Med, 33(9):1369-1379.

[22] Wren TA, Lindsey DP, Beaupre GS, Carter DR (2003) Effects of creep and cyclic loading on the mechanical properties and failure of human Achilles tendons. Ann Biomed Eng, 31:710-7.

[23] Lansdaal JR, Goslings JC, Reichart M, et al (2007) The results of 163 Achilles tendon ruptures treated by a minimally invasive surgical technique and functional aftertreatment. Injury, 38(7):839-844.

[24] Khan RJ, Carey Smith RL (2010) Surgical interventions for treating acute Achilles tendon ruptures. Cochrane Database Syst Rev, 9:CD003674.

[25] Hockenbury RT, Johns JC (1990) A biomechanical in vitro comparison of open versus percutaneous repair of tendon Achilles. Foot Ankle, 11:67-72.

[26] Ververidis AN, Kalifis KG, Touzopoulos P, Drosos GI, Tilkeridis KE, Kazakos KI (2016) Percutaneous repair of the Achilles tendon rupture in athletic population. J Orthop, 13:57-61.

[27] Davies MS, Solan M (2009) Minimal incision techniques for acute Achilles repair. Foot Ankle Clin, 14:685-97.

[28] Raikin SM, Garras DN, Krapchev PV (2013) Achilles tendon injuries in a United States population. Foot Ankle Int, 34(4):475-480.

Figures

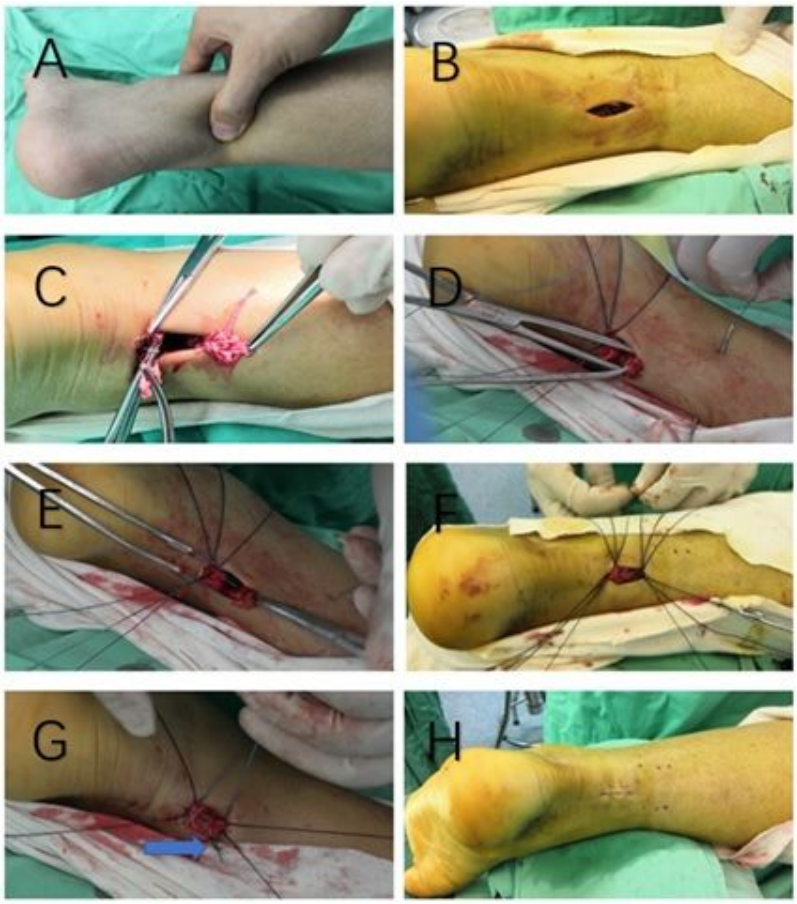

Figure 1

Operation procedure. (A) palpated the gap of the Achilles rupture. (B) the incision. (C) the teared end was revealed. (D) Lumbar puncture needle was passed through the oval forceps and the tendon, then all the sutures were passed through the needle successively. (E) Withdrawing the oval forceps with the suture tails into the incision. (F) All sutures were passed through Achilles and all the suture ends were carefully separated. (G) One side of the same sutures was tied, gentle traction the ends of the sutures to conceal the knots beneath the paratenon (the arrow), then tied another side. (H) postoperative incision.

Figure 2

(A) MRI shows the Achilles tendon was completely ruptured. (B) MRI shows the Achilles tendon heals well with good continuity at 4 months postoperative. (C) Heel raising of the affected foot at 4 months postoperative.