Bezoar types in children and etiological factors affecting bezoar formation: a single center retrospective study

Mustafa Erman Dörterler (m.e.dorterler@hotmil.com)
Harran University Scholl of Medicine https://orcid.org/0000-0001-9304-6830
Tansel Günendi
Harran University Scholl of Medicine https://orcid.org/0000-0001-5356-1061
Mehmet Çakmak
Harran University Scholl of Medicine https://orcid.org/0000-0002-1232-2475
Saime Shermatova
Harran University Scholl of Medicine https://orcid.org/0000-0002-7000-5398

Research Article

Keywords: Anomaly, Bezoar, Child, Duodenum, Endoscopy, Surgery

Posted Date: October 15th, 2020

DOI: https://doi.org/10.21203/rs.3.rs-79508/v1

Abstract

Background: Bezoar is formed as a result of the accumulation of undigested food or foreign substances in the gastrointestinal tract (GIS). The present study aims to investigate the bezoar types seen in children and the etiological factors involved in bezoar formation.

Methods: A total of 16 patients who underwent an endoscopy and/or surgical treatment for bezoar at Harran University, Faculty of Medicine Pediatric Surgery Clinic between 2011 and 2019 were included in the study. The demographic information, laboratory and radiological findings were obtained from the patients' file records

Results: A total of 10 patients (62.5%) were female with a mean age of 7.8 ± 4.9 years. Phytobezoars were detected in 10 patients, trichobezoars in 2 patients, lactobezoar in 1 patient, and other types in 3 patients. The etiological factors were determined to be congenital GIS anomaly in 6 (37.5%) patients; trichotillomania in 2 (12.5%) patients; mental retardation in 2 (12.5%) patients; ingestion of a foreign body during infancy in 2 (12.5%) patients; high intake of high-fiber fruit in 3 (18.5%) patients; and postoperative dysmotility in 2 (12.5%) patients.

Conclusions: Congenital GIS anomalies are mostly responsible for bezoar etiology in children and phytobezoar is the most common type of bezoar.

Background

Bezoar is the accumulation and formation of a mass of substances, such as food, medicines, and hair in the gastrointestinal tract, which are taken orally and cannot be digested [1]. 4 primary types of bezoars have been identified according to their contents. Bezoars containing plant materials such as vegetable and fruit fibers, shells and seeds are called phytobezoars; those, whose main component is hair, are called trichobezoar; those, whose main component are medicines, are called pharmacobezoars; and those, whose main component is milk proteins, are called lactobezoars [2]. In addition, partially digested or undigested substances (e.g., chewing gum, plastic, sponge, paper, etc.) that do not fall into these four categories, are accompanied by gastric mucus and can also cause bezoar formation are called other types of bezoars [3]. Bezoars can occur anywhere in the GIS, but are most common in the stomach [4]. The development of bezoar is common especially in psychiatric disorders such as trichotillomania and trichophagia, and in children with a history of mental retardation and pica [5].

In the literature, there are single case reports about bezoars seen in childhood or small case series describing several patients [6]. No light could be shed on the etiological factors leading to bezoar formation, especially in childhood. In this retrospective single-center study, the aim was to investigate bezoar types and the etiological factors involved in bezoar formation in patients undergoing endoscopy and/or surgery due to the presence of bezoars in childhood.

Methods

Patients who underwent an endoscopy and/or surgical treatment for bezoar between 2011 and 2019 at Harran University Medical Faculty Pediatric Surgery Clinic, were included in this single center retrospective study. Patients who recovered as a result of medical treatment were not included in the study. A total of 16 patients were included in the study. To determine the types of bezoars and etiological factors involved in bezoar formation, patient demographic information such as gender and age, and medical information such as admission symptoms, comorbidities, treatments, bezoar type, bezoar location, and prognoses were obtained from patients' file records.

The extracted bezoars were examined macroscopically and microscopically. Tests were performed with chloroform in cases of suspected animal hair such as wool and felt. The study was carried out with the approval of the Ethics Committee of the Non-Drug Clinical Research Department of Harran University, Medical School (No:28; dated: 27.04.2020).

Statistical Analysis

The Statistical Package for the Social Sciences (SPSS) 22.0 (IBM Corporation, Armonk, New York, United States) program was used in the analysis of the data. Categorical data were expressed using n (number) and percentage (%).

Results

A total of 16 patients, 10 (62.5%) females and 6 (37.5%) males, were included in the study. The mean age of the patients was 7.7 ± 4.9 years. Of the patients, 13 (81.3%) received surgical treatment and 3 (18.7%) were treated with endoscopy. Bezoars were removed by surgical treatment after 3 patients were determined through endoscopy to have duodenal web and 1 to have duodenal stenosis, and the anomalies corrected. Bezoar was detected in the stomach in 4 patients, in the stomach and duodenum in 5 patients, in the duodenum in 2 patients, and in the ileum in 5 patients.

The Clinical features of the cases changed according to age on onset. While younger patients in the first three years of life and patients with mental retardation presented with vomiting, older patients tended to show abdominal pain, abdominal fullness, and distension. Two of our patients with mental retardation had previous chronic constipation. On conventional radiography dilated small bowel loops and multiple air levels were seen in distal bowel obstructions but bezoars could not be clearly identified untill they reached a big size. Barium abdominal X-ray showed gastric fullness in 9 cases. Contrast-enhanced CT was used as the choice of modality to identify the level of the obstruction and most importantly clarify the cause.

With respect to the type of bezoar found, phytobezoars were detected in 10 patients, trichobezoar in 2 patients, lactobezoar in 1 patient, and other types of bezoars (chewing gum, play dough and plastic material) in 3 patients. In case of phytobezoars, the main component of the mass was found to be walnut in 1 patient, hazelnut in 1, seeded grape in 1, and kaki persimmon in 2 patients. The Other phytobezoars contained many vegetative ingredients.

The etiological factors responsible for bezoar formation were congenital GIS anomaly in 6 (37.5%) patients (3 duodenal web, 1 duodenal hyperfixation, 1 annular pancreas, and 1 Meckel's diverticulum), trichotillomania in 2 (12.5%) patients, mental retardation in 2 (12.5%) patients, the ingestion of foreign matter due to an inability to distinguish between nutrients and non-nutrients in 2 (12.5%) patients as a result of age, a high intake of high fiber vegetable matter over a short period in 3 (18.5%) patients (persimmon in 2 patients and hazelnut in 1 patient), and a high intake of fibrous plant nutrients during a period of intestinal dysmotility after appendectomy in 2 (12.5%) patients (Figure 1). In one patient, 2 etiological factors (trichotillomania and duodenal hyperfixation) were detected at the same time. One of the patients with duodenal web had previously received medical treatment for bezoar and had once been treated with endoscopy. All patients with congenital anomaly were under the age of six, except for the patient with Meckel's diverticulum. Phytobezoar was detected in 4, lactobezoar in 1, and trichobezoar in 1 of these patients.

It was found that the formation of bezoar did not recur, and no complications developed during the 1-year follow-up period of the patients. Two of our patients with trichobezoar consumption were discharged with psychiatric consultation. The demographic and clinical features of the patients are summarized in Table 1.

Discussion

In this eight-year single-center retrospective study, it was shown that phytobezoars are most common in children, congenital GIS anomalies play an important role in the etiology, and that these anomalies mostly cause bezoar formation in early childhood. A series of 7 cases in 10 years was reported by Castle et al. [7], and a series of 4 cases in 18 years was reported by Gorter et al. [8] in the literature.

In studies conducted in adult patient groups, it was reported that bezoar formation may develop in any region of the GIS, but mostly in the stomach [9]. As far as we know, the region of the GIS in which bezoar formation occurs most in childhood has not been reported in any study in the literature to date. In the present study, it was found that in more than half of the cases, bezoar developed in the stomach or stomach and duodenum region.

In studies conducted, it has been reported that phytobezoar is the most common type of bezoar [10]. Similar to studies in the literature, vegetable nutrients were detected in approximately two-thirds of patients in the present study. It has been reported that among vegetable nutrients, persimmon is the most common cause of the formation of phytobezoars [11]. In this study, as in other studies in the literature, it was determined that the vegetable nutrients shown as the sole etiological factor for phytobezoar formation were persimmon and hazelnut.

Many studies have reported numerous etiological factors for bezoar formation, such as mental retardation, trichotillomania, GIS surgery, a high intake of high fiber vegetable matter over a short period, and raw vegetable nutrient intake. It has been reported that gastric surgeries are the most common etiological factor for bezoar formation in adult patient groups [10]. As far as we know, there are not enough data in the literature about the frequency of risk factors in childhood. In the present study, it was shown that congenital GIS anomalies, especially duodenal anomalies, were in the etiology of bezoar formation, with a rate of 37.5%.

In the literature, a case of bezoar was reported by Chien et al. due to duodenal web in a 2-year-old patient, who was previously healthy [12]. In the present study, the oldest of the 3 patients with duodenal web was 3.5 years old. While 2 of these patients had no prior history of duodenal obstruction, 1 had received medical treatment and endoscopy for bezoar. Of the patients in this group, 2 had phytobezoars and 1 had lactobezoars. In addition, the patient with duodenal hyperfixation had trichotillomania, and trichobezoar was also detected. In the literature, Meckel’s diverticulum accompanying bezoar was reported in several cases during childhood and it was reported that it was mostly of the phytobezoar type. One of them was Meckel’s diverticulitis, accompanied by phytobezoars in a 12-year-old patient reported by Gasparella et al. [13]. Similarly, in the present study, phytobezoar presented at the Meckel’s diverticulum in one case and also accompanied Meckel’s diverticulitis. In the literature, 2 cases of annular pancreas, which were responsible for bezoar formation, were reported, with one of them reported by Kestel et al. in an adult patient, who had recurrent pancreatitis due to bezoar [14]. In the present study, the patient in whom the annular pancreas was detected was 2 years old and had had no previous complaints.

It has been reported that trichobezoars are mostly seen in patients with psychiatric disorders, especially trichotillomania and depression, and 14% of these patients were under 7 years of age [15]. Similar to the studies in the literature, 2 patients with trichobezoar were also diagnosed with trichotillomania in this study. One of these patients had accompanying duodenal hyperfixation anomaly and was under 7 years of age.

In many studies in the literature, it has been reported that patients with mental retardation can ingest many nonnutrients, especially hair, and bezoar forms as a result [16]. In 1 of 2 patients with mental retardation, bezoar occurred as a result of their ingesting plastic material, while phytobezoar was detected in the other. Similarly, of the 2 patients, who were too young to properly distinguish between nutrients and non-nutrients, one had bezoar due to their ingesting chewing gum and the other had bezoar due to their ingesting play dough.

It has been reported that excessive consumption of high-fiber vegetable foods may cause phytobezoar formation, particularly if immature fruits or vegetables are swallowed in large quantities without sufficient mastication, as they pose a risk for bezoar formation. In particular, immature kaki persimmons in this group of vegetable foods cause phytobezoar formation [17]. In the present study, similar to the literature, phytobezoars occurred in 2 cases without any risk factors after the intake of a large amount of persimmon over a short period. Similarly, in one case, phytobezoars occurred after the intake of a large amount of hazelnuts in a short time.

Bezoars have been reported to occur in conditions such as intestinal diverticulum, neoplasm, and as a result of surgical procedures, which reduce intestinal motility [16]. In this study, as noted in the literature, phytobezoars occurred in 2 cases where patients did not follow their prescribed diets after appendicitis surgery and consumed excessive amounts of high-fiber vegetable matter.

In this study, the aim was to draw attention to bezoar types seen in childhood and the risk factors that play a role in bezoar formation. However, the small number of cases is a limitation of this study. It is thought that large-scale studies are needed on this subject.

Conclusion

In the present study, bezoar types seen in childhood and the etiological factors involved in bezoar formation were evaluated. Phytobezoars were shown to be the most common bezoar type, and congenital GIS anomalies to be the most common etiological factor. It was found that congenital GIS anomalies mostly occurred in the duodenal region and were seen with recurrent phytobezoar or lactobezoar formation, especially in early childhood. Congenital GIS anomalies must be kept in mind in bezoar formations, in which the risk factors in childhood cannot be explained. The reconstructive surgical interventions for these anomalies should be synchronized with the extraction of bezoar masses. In this way, it is believed that recurrence of bezoar formation, and complications that may arise due to congenital GIS anomalies can be prevented.

Abbreviations

GIS: Gastrointestinal System

Declarations

Author's Contributions

MED prepared in conceptualizing the study and drafting introduction, methods and discussion sections of the manuscript. TG maintained the feedback on study design and provided critical feedback on earlier drafts of the manuscript and prepared Figures. SS analyzed the data, played the major role in drafting the results section, and gave oversight for data collection. MC assisted with data preparation and provided critical feedback on earlier drafts of introduction and discussion. All authors read and approved the final manuscript.

Acknowledgements

An earlier version of our manuscript can be found in the following link.
https://www.researchsquare.com/article/rs-34173/v1

Funding

We had no funding support from institutions or third parties.

Availability of data and materials

The data in the article can be used with reference.

Conflicts of Interest

The authors have no conflicts of interest to declare.

Ethics approval and consent to participate

Harran University ethical approval was obtained (document protocol number 13/05/2020-E.18246) prior to recruitment and data collection.

Competing interests

We declare no competing interests or financial conflicts with any institution or third parties.

Data Availability

The data in the article can be used with reference.

References

1. Yeh J, Saul T, Gingrich A, Wassermann J (2013) Bezoar. J Emerg Med 45: 615-16
2. Sanders MK (2004) Bezoars: from mystical charms to medical and nutritional management. Pract Gastroenterol 28(1): 37-50
3. Khan S, Jiang K, Zhu LP, Khan IA, Ullah K, Khan S, et al (2019) Upper Gastrointestinal Manifestation of Bezoars and the Etiological Factors: A Literature Review. Gastroenterol Res Pract 2019: 5698532, https://doi.org/10.1155/2019/5698532, 13 pages
4. Iwamuro M, Tanaka S, Shiode J, Imagawa A, Mizuno M, Fujiki S, et al (2014) Clinical characteristics and treatment outcome of nineteen Japanese patients with gastrointestinal bezoars. Intern Med 53: 1099-1105
5. Kuhn BR, Mezoff AG (2011) Bezoars. In: Wyllie R, Hyams JS, Kay M eds. Pediatric Gastrointestinal and Liver Disease. 4th ed. Philadelphia, PA: WB Saunders 319-22.
6. Mihai C, Mihai B, Drug V, Cijevschi Prelipcean C (2013) Gastric bezoars-diagnostic and therapeutic challenges. J Gastrointestin Liver Dis 22: 111
7. Castle SL, Zmora O, Papillon S, Levin D, Stein JE (2015) Management of Complicated Gastric Bezoars in Children and Adolescents. Isr Med Assoc J 17(9): 541-544
8. Gorter RR, Kneepkens CM, Mattens EC, Aronson DC, Heij HA (2010) Management of trichobezoar: case report and literature review. Pediatr Surg Int 265: 457-463
9. Iwamuro M, Okada H, Matsueda K, Inaba T, Kusumoto C, Imagawa A, et al (2015) Review of the diagnosis and management of gastrointestinal bezoars. World J Gastrointest Endosc 7: 336-345
10. Paschos KA, Chatzigeorgiadis A (2019) Pathophysiological and clinical aspects of the diagnosis and treatment of bezoars. Ann Gastroenterol 32(3): 224-232
11. Dikicier E, Altintoprak F, Ozkan OV, Yagmurkaya O, Uzunoglu MY (2015) Intestinal obstruction due to phytobezoars: An update. World J Clin Cases 3: 721-726
12. Chien JH, Ho TY, Shih-Peng L, Lee CL, Ou SF (2008) Acquired duodenal obstruction in children. Pediatr Neonatol 49(5): 193-196
13. Gasparella M, Marzaro M, Ferro M, Benetton C, Ghirardo V, Zanatta C, et al (2016) Meckel's diverticulum and bowel obstruction due to phytobezoar: a case report. Pediatr Med Chir 38(2): 117
14. Kestel W, Fischbach W, Wilhelm A. Rare cause of acute pancreatitis: Phytobezoar in an intraluminal diverticulum in type I duodenal atresia, intestinal malrotation and rudimentary pancreas anulare. Z Gastroenterol. 1998;36:295–9

15. Frey AS, McKee M, King RA, Martin A (2005) Hair apparent: Rapunzel syndrome. Am J Psychiatry 162(2): 242-248
16. Paschos KA, ChatzigeorgiadisA (2019) Pathophysiologicaland clinical aspects of the diagnosis and treatment of bezoars. Ann Gastroenterol 32(3): 224-232
17. Erzurumlu K, Malazgirt Z, Bektas A, Dervisoglu A, Polat C, Senyurek G, et al (2005) Gastrointestinal bezoars: a retrospective analysis of 34 cases. World J Gastroenterol 11: 1813-1817

Table

Table 1. Demographic and clinical features of patients

Number	Age (year)	Bezoar type	Localization	Etiology	Treatment	Size of Bezoar	Clinical features on onset
1	2,5	Phytobezoar	Duodenum	Annular pancreas	Surgery	4-5 cm	Abdominal distension, vomiting
2	3,5	Phytobezoar	Duodenum	Duodenal web	Surgery	5 cm	Abdominal fullness, discomfort
3	1,5	Phytobezoar	Stomach and duodenum	Duodenal web	Endoscopy	2 cm	Vomiting
4	3	Other type (dough)*	Stomach	Preschoolers group**	Endoscopy	4 cm	Abdominal distension
5	3	Other type (chewing gum)	Stomach	Preschoolers group**	Endoscopy	6-8 cm	Abdominal pain
6	1	Lactobezoar	Stomach and duodenum	Duodenal web	Surgery	2 cm	Vomiting
7	16	Phytobezoar	Stomach	Food with bezoar risk	Surgery	15-17 cm	Abdominal pain, distension
8	6	Phytobezoar	Stomach and duodenum	Food with bezoar risk	Surgery	5 cm	Abdominal pain
9	6	Trichobezoar	Stomach and duodenum	Trichotillomania, duodenal hyperfixation	Surgery	8-9 cm	Abdominal pain
10	12	Trichobezoar	Stomach	Trichotillomania	Surgery	13-15 cm	Abdominal pain, distension
11	13	Phytobezoar	Ileum	Postoperatif dysmotility	Surgery	15-16 cm	Cramping in the lower abdominal quadrants
12	9	Phytobezoar	Ileum	Postoperatif dysmotility	Surgery	10-11 cm	Abdominal pain, distension
13	11	Phytobezoar	Ileum	Meckel diverticulum	Surgery	12-14 cm	Abdominal pain
14	8	Phytobezoar	Ileum	Food with bezoar risk	Surgery	5-6 cm	Abdominal pain
15	14	Other type (plastic)	Ileum	Mental retardation	Surgery	Multipl ranging from 3-5 cm	Vomiting
16	14	Phytobezoar	Stomach and duodenum	Mental retardation	Surgery	15-17 cm	Vomiting

A result of patients being too young distinguish between food and non-nutriens

Figures

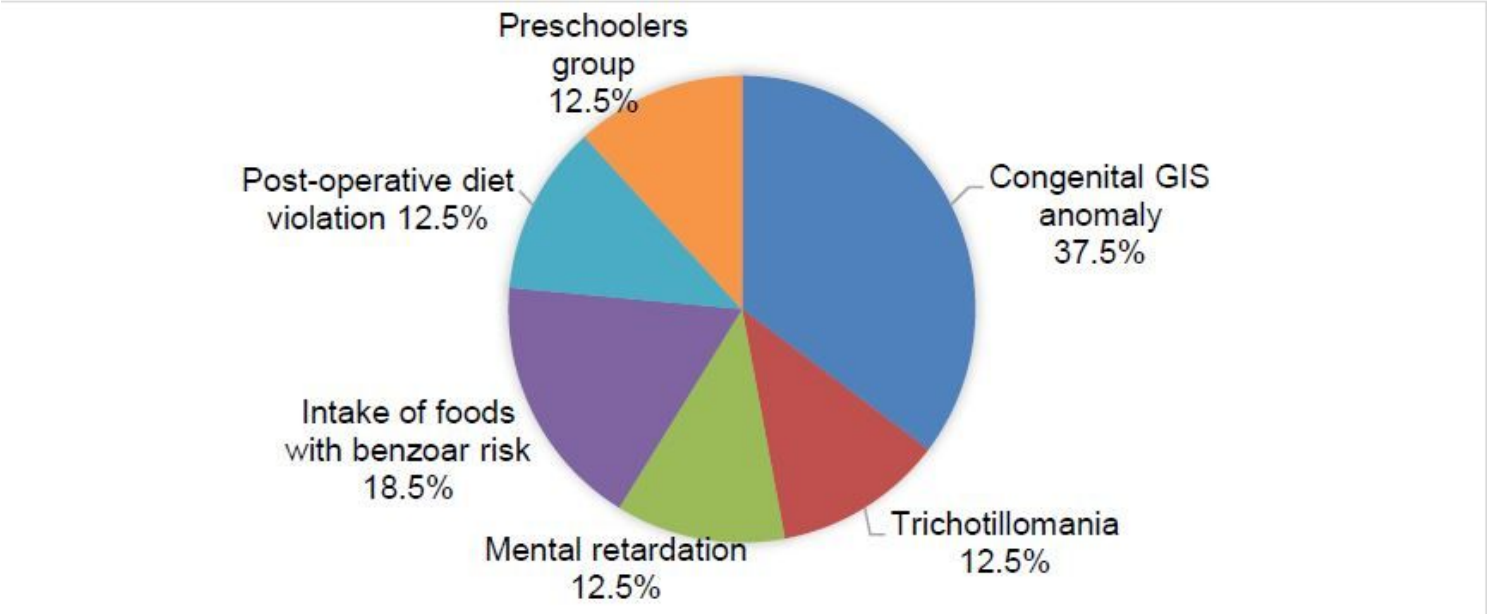

Figure 1

Distribution of factors that contribute to bezoar formation GIS:Gastrointestinal system.Preschoolers group:foreing body ingestion in patients,who were too young to distinguish between food and non-nutrients