A comparative study of laminoplasty with short segment transpedicular screw fixation versus laminoplasty with anterior fusion in treating extensional cervical spinal cord injury without radio graphic abnormality in adults

Bi Zhang
The Affiliated Ganzhou Hospital of Nanchang University,The second Affiliated Hospitai of Nanchang University https://orcid.org/0000-0001-9130-0073

Zhenhai Zhou
The second Affiliated Hospital of Nanchang University

Honggui Yu
The second Affiliated Hospital of Nanchang University

Zhimin Pan
The second Affiliated Hospital of Nanchang University,Yonsei University College of Medicine,Korea

Rongping Zhou
The second Affiliated Hospital of Nanchang Uiniversity

Wenbing Wan
The second Affiliated Hospital of Nanchang University

Lu Chen
The second Affiliated Hospital of Nanchang University

Zhaoxun Zeng
The first Affiliated Hospital of Nanchang University

Kai Cao (kaichaw@126.com)
The second Affiliated Hospital of Nanchang University https://orcid.org/0000-0001-6384-1227

Research article

Keywords: anterior cervical fusion, cervical spinal cord injury, laminoplasty, transpedicular screw fixation

Posted Date: November 15th, 2019

DOI: https://doi.org/10.21203/rs.2.17335/v1

Abstract

Background: Cervical spinal cord injury(CSCI) without major fracture or dislocation is often described as cervical SCI without radiographic abnormality (SCIWORA). Majority of this injury could be without radiographic abnormality but with disrupted anterior longitudinal ligament or intervertebral disc unless examined by MRI. The optimal surgical management of this cervical spinal cord injury remains controversial. This study is to evaluate the clinical advantages of laminoplasty combined with short-segment transpedicular screw fixation for managing this issue.

Methods: SCIWORA patients were collected into two groups according to different surgical methods. Patients in group A received laminoplasty combined with transpedicular screw fixation, and patients in group B received anterior cervical fusion combined with laminoplasty. All cervical spine were assessed by X-ray, CT, MRI preoperatively and postoperatively to evaluate the decompression range, bonegraft fusion and instruments location. ASIA grade and JOA score were recorded to assess the neurological function recovery. Complications, surgery time, intraoperative blood loss and hospital stay were compared between two groups. Mean follow-up was at least 2 years.

Results: In this study, Forty eight patients were in group A and 54 ones were in group B. All cases were decompressed fully and obtained fusion 6-month postoperatively. The ASIA grade was improved postoperatively, but no significantly different between two groups (p=0.907). The JOA was 6.12±1.76 preoperatively and improved to 11.98±2.98 postoperatively with the 53.13% neurofunction recovery rate in group A, with no significantly different compared with group B(vs 6.63±2.45, p=0.235; vs 12.62±3.59, p=0.303; vs 57.76%, p=0.590)respectively. Total 18 complications occurred but the occurrence was significant lower in group A(p=0.020). The average surgery time was 2.2±0.32 hours, intraoperative blood loss was 304±56ml and hospital stay was 8.2±3.1 days, significantly decreased compared with group B(vs 3.1±0.29, p=0.000; vs 388±61ml, p=0.000; vs 12±2.8days, p=0.000)respectively.

Conclusions: Cervical laminoplasty combined with short-segment transpedicular screw fixation is a reliable option to treat SCIWORA patients with CSS. The advantages include achieving sufficient cervical decompression, maintaining cervical stability and avoiding extra anterior cervical fusion which increases surgery time, intraoperative blood loss, postoperative complications and hospital stay.

Background

Traumatic cervical spinal cord injury(CSCI) without major fracture or dislocation often is described as cervical SCI without radiographic abnormality (SCIWORA) [1,2].SCIWORA is considered to represent mainly a pediatric injury, but the incidence of it in adults is relatively underreported and underestimated[3].Actually, the first adult cervical SCIWORA may be reported as early as in 1938 by Dr. Burns[4].A recent study revealed the occurrence rate of adult cervical SCIWORA is not low by reporting 203 SCIWORA cases form 869 cases of traumatic cervical cord injuries[5]. It was as high as 5.74% per million population in Tianjin, a north city of China[5].Adults have a different injury profile from children,

due to different anatomical and physiological properties and exposure to variable risk factors[6].SCIWORA seems to be uncommon among middle-aged and geriatric populations, because compared with the children's spines, the flexibility of adult spine is reduced with increasing age, and the likelihood of spinal injury becomes greater, even catastrophic consequences[7].

Most SCIWORA patients have pre-existing cervical spondylotic changes, cervical ossification of the posterior longitudinal ligament or developmental cervical stenosis, which results in narrowing of the cervical spinal canal [8,9]. As we know, when the cervical spine is hyperextended, the diameter of cervical cord is increased but spinal canal gets narrower [10]. This noxious morphological change will impose the cervical cord into being pinched, which has been postulated to be an important mechanism of CSCI under hyperextension[11]. Meanwhile, hyperextensional injury leading to anterior spinal destruction such as anterior longitudinal ligament disruption and intervertebral disc avulsion can result in cervical potential instability even without obvious fracture and dislocation[12]. which exposes the cervical cord into much higher risk of injury based on the pathological stenosis. Several research demonstrated anterior longitudinal ligament discontinuity, avulsed disc annulus were observed commonly by MRI evaluation in SCIWORA[13–15]. Meanwhile,significant intersegmental displacements may occur when injured cervical spine was subjected to flexion, extension, or distraction forces[16]. Realistically, the potential cervical instability will require surgical stabilization to lest secondary injury.

However, there is little clinical study on the surgical strategy for cervical SCIWORA associated with CSCS. With less postoperative complications, cervical laminoplasty represents a preferred technique to achieve complete decompression in the treating multilevel cervical stenosis. However, included in this study, the patients with multilevel cervical stenosis would not only represent cervical cord injury, but also potential cervical instability due to preexisting anterior structure damage. The destruction on the posterior cervical vertebrae due to laminoplasty could aggravate the instability of cervical vertebrae[17]. Therefore, an extra-anterior approach fusion need supply to stabilize cervical spine after laminoplasty. To fulfill the requirements of both complete decompression and satisfactory reconstruction in only posterior approach is one of the challenges in clinical practice. In this study, we compared the profiles of different surgery regimen to treat extensional cervical SCIWORA in patient with CSCS: laminoplasty combined with anterior fusion *vs* laminoplasty associated with transpedicular screw instrumentation, for establishing the preferred surgical strategy for this injury.

Methods

Patients and groups.

Two hundred-twelve extensional cervical SCIWORA patients admitted in four spine centers between April 2010 and June 2017 were collected for retrospective study. The inclusion criterias were made as follows: age 18–70yeas old, with degenerative orpreexisting cervical spinal stenotic, cervical spinal cord injury without significant localized compression in front of it. And the exclusion criterias were:with cervical fracture or dislocation, patients with cervical infection, tumor or tuberculous disease, Patients with brain

injury. Patients associated with CSCS were 184. All SCIWORA patients with disrupted anterior longitudinal ligament or intervertebral disc were included. The disrupted structures were confirmed by MRI examination. One hundred and two patients met the MRI diagnosis criteria. Forty eight patients who underwent posterior laminoplasty associated with transpedicular screw instrumentation were included into group A. Fifty four patients who underwent posterior laminoplasty combined with anterior fusion were included into group B (See table 1 for details).

Preoperative treatment and radiological examination.

Patients with acute cervical SCI were hospitalized and administered steroids. After admission, all patients were received antibiotics in order to prevent infection [18]. Cervical spine of all patients were assessed radiologically with X-ray, CT, MRI at preoperative as long as stable hemodynamics to confirm the injury profiles.

Surgical techniques.

Briefly, in group A, the patient was placed in a Concorde position with 5 kg Gardner-Well skull traction under general anesthesia. From posterior middle approach, extensional muscles were detached from the spinous process and lamina to expose the mass from C3 to C6. If C7 was involved in responsible segments, C7 articular mass also need be exposed. The lateral margin of the articular mass of the responsible cervical segments need to be extra-exposed. When the short-segmental transpedicular screw instrumentation was completed in the involved cervical spine, laminoplasty was conducted from C3 to C6 (C7 may be necessary if involved in responsible segments) The mass and lamina of responsible segments were decorticated and bonegrafted for fusion(Fig.1). After surgery wound closed, skull traction was removed.

In group B, the patient initially was placed in a supine position with slight cervical extension after general anesthesia. Anterior discectomy and fusion was conducted at involved intervertebral disc then followed a laminoplasty but without short-segmental transpedicular screw instrumentation.

Clinical Assessment.

The routine postoperative X-ray, CT and MRI checks were carried out to confirm the instruments position and the sufficiency of decompression (Fig.1). In addition, neurofunctional rehabilitation exercise at an early stage after surgery was committed to all patients in rehabilitation department. Postoperative and follow-up assessments were committed to the respects of the neurofunction recovery(ASIA scale and JOA score), bonegraft fusion, instruments location, surgery time, intraoperative blood loss and hospital stay between two groups. Neurological function improvement rate was calculated as the formula: (postopeartive JOA score- preoperative JOA score)/ (17-preoperative JOA score)×100%(See table 2–3 for details).

Statistical Analyses.

The analysis of *t* test were used to compare continuous variables between patients in two groups. Chi-squared tests were used to compare categorical variables between groups. The software package IBM SPSS Statistics 19 (IBM, USA) was used for statistical analyses. A p-value of less than 0.05 was considered statistically significant.

The present study was approved by the institutional review board of each participating hospital.

Results

One hundred and two patients obtained final follow-up with mean time of 24.6±3.6 months. The demography of patients was referred to Table 1. Patients profiles between the two groups were no significantly different.

Neurological function improvement and annlysis.

Preoperatively, 102 patients were neurological deficit with ASIA grade C(50%) and B (29.63%), followed by grade D (11.76%) and A (6.86 %). After surgery, the neurofunction of patients in both groups were improved with ASIA grade D(42.16%) and C(26.47%), followed by grade E (14.71%), grade B (12.75%) and A (3.92%).The assessment of the ASIA scale is reflected in Table 2.

The mean preoperative JOA score was 6.12±1.76 in group A, whereas 6.63±2.45 in group B, the mean final follow-up JOA score was 11.98±2.98 in group A, whereas 12.62±3.59 in group B without significant difference. In 102 patients (55.4%) followed with more than 2 years postoperatively, the recovery rates between two groups were calculated using the above formula and compared with each other. No significantly difference was found between both groups. The results were shown in Table 3.

Surgery time, blood loss and hospital stay.

The average surgery time was 2.2±0.32 hours, intraoperative blood loss was 304±56ml and hospital stay was 8.2±3.1days in group A, however, in group B, The average surgery time was 3.1±0.29 hours, intraoperative blood loss was 388±61 ml and hospital stay was 12±2.8days days, significantly increased compared with group A, respectively. The results were shown in Table 4.

Complications.

All cases were decompressed fully in radiographic and obtained bone fusion 3 months postoperatively. Postoperative CT scan revealed that 17 screws (8.9%) of 192 screws had perforated the cortex of the pedicles. However, no neurovascular complications were involved in. One patient was dead in respiratory failure in group B. Total 18 immortal complications occurred including respiratory tract infection, cranial spinal fluid (CSF) leaking, surficial wound infection, dysphagia and instrument failure in both groups, but the occurrence rate was significant different between two groups. Two instrument failures occurred in group B presenting dislodged plate though the anterior fixation were verified with good position

intraopeartively. An extra revisional surgery was conducted to the instrument failure. The results were shown in Table 4.

Discussion

Acute cervical spinal cord injury (SCI) is one of the most devastating conditions, and can lead to paralysis, sensory impairment and bowel, bladder and sexual dysfunction. Individuals with cervical canal stenosis are known at high risk to develop cervical SCI. Among cervical SCI patients with cervical stenosis, extensional injury is the most common injury mechanism, not a few of them radiologically presented no fracture or dislocation(SCIWORA). This injury should be classified into distractive extension type according to Allen's report[19] or included into the B3 type according AO classification, and need surgery intervention. Distractive extension injuries are characterized by progressive failure of the motion segment in an anterior to posterior direction, which consists of failure of the anterior longitudinal ligament and annulus fibrosus. Widening of the disc space could be seen on x-ray under extention. There may be a small avulsion fracture at the anterior margin of the disc space in some cases. If extensional force continued, posterior subluxation could be seen. And this is also not uncommon that the magnitude of posterior displacement could often be vanished by followed flexion of head. Distractive extension injuries often were the result of a fall on the face. So if patients with face injury, who are diagnosed with spinal cord injury but without fracture or dislocation, need be paid attention to the extensional cervical SCIWORA. In this study, we advocated that cervical laminoplasty combined with transpedicular screw fixation is preferred in treating extensional cervical SCIWORA in patients with stenosis.

Early decompression surgery for extensional cervical SCIWORA had an excellent outcome. Controversies exist with regard to the time of surgery intervention for traumatic CSCI. La RosaG[20]reported that early decompression surgery within 24 h of trauma had a significantly better outcome, compared with late surgical management. Guest et al also reported that early surgery (within 24 hours of injury) bring about an improved overall motor recovery in patients whose traumatic central cord syndrome was related to acute disc herniation or fracture [21].On the contrary, another study reported that surgical treatment was not found to be superior to conservative treatment for traumatic CSCI without major fracture or dislocation with spinal cord compression in the acute phase[22]. The patients in this cohort received early decompression, and the obvious improvement of postsurgical neurological scores indicate that patients benefit from early decompressive surgery. We considered the injured cord will be more severely squeezed in patients with a preconditioned stenotic canal under the rapid development edema in the early stage after spinal cord trauma. Therefore, the patients in this cohort may be benefit from the early decompression.

In patients with cervical canal stenosis, sufficient decompression for extensional cervical SCIWORA was critical. Some previous studies recommended surgical treatment for traumatic CSCI without major fracture or dislocation with cervical cord compression at the injured segment [20,23,24]. However, we considered these patients have already had pathological stenotic precondition, in which MRI frequently reveals long hematoma and edema intramedullarily, so multi-segmental decompression could be more

sufficient. Several options for multi-segmental decompression are available including anterior corpectomy and posterior laminoplasty [25–28]. But the multiple cervical vertebrae fusion with a large bone graft through anterior route could lead to severe disability of cervical mobility or poor fusion and severe complications, such as dysphagia and dyspnea[29–31]. Posterior laminoplasty is a relatively simple operation, which could preserve cervical mobility with fewer postoperative complications. Therefore, posterior laminoplasty has become one of the superior approaches for multilevel CSCS[32]. We also advocate to apply laminoplasty not only to fulfill complete decompression, but also to avoid anterior approach associated-complication as compared to corpectomy in this cohort. Extra anterior approach associated- complication such as dysphagia were observed in group B compared with no analogical complications occurred in group A. Patients in both groups obtained sufficient decompression that was verified by postoperative MRI. Laminoplasty decompression conducted in all patients may explain the neurofunction recovery that there is no significant difference between two groups according to postoperative ASIA grades and JOA scores.

Immediately postoperative cervical stabilization is another indispensable factor for avoiding secondary injury in extensional cervical SCIWORA patients. Laminoplasty could decompress sufficiently for stenotic canal, on the other hand, it could aggravate the stability of a cervical spine with a preexisting anterior vertebral destruction by hyperextensional stress. Masaki[17]reported a hypermobility of vertebrae at the cord compression level is a risk factor for poor surgical outcome after laminoplasty. Therefore, stabilization intervention need be committed in this cohort with options of extra anterior fusion or posterior instrumentation. Studies indicated that the posterior transpedicle screw internal fixation had been shown to convey better stability for unstable spine than anterior fixation and fusion[33,34], and the transpedicle screw instrumentation, of its three-column stabilization property, had superior biomechanical advantages, like anti-pullout ability, compared with lateral mass screws fixation [35]. The strategy of short-segmental fixation was for preserving as much as mobile cervical segments, which would decrease the stiffness of cervical spine, retard the probability of cervical degeneration and keep more postoperative cervical range of motion. We found there were no instruments failures in group A, but 2 instrument dislodges occurred in group B. One postoperative fixation displacement occurred with the reason that the intervertebral cage was too much high, which resulted in a focal hyperlordosis of involved segment. Anther postoperative dislodge also happened in the condition of hyperextensional cervical spine.

In this study, compared with laminoplasty combined with anterior fusion procedure, Laminoplasty associated with transpedicular screw instrumentation definitely decreased intraoperative blood loss, surgery time and hospital stay. This was not difficult to understand due to only one surgery approach conducted in group A associated with less surgical trauma, from which patients benefitted more and recovered much fast. Xu[36]reported laminoplasty in combination with posterior fixation brought about several advantages of minimal surgical trauma, less intraoperative blood loss and satisfactory stable effect in treating multilevel CSS and spinal cord injury in the trauma population. Our results were consistent with Xu’s report.

There are some limitations in the study. First, in this retrospective multicenter study, the surgical techniques for decompression and fixation were not controlled and were different in different institutions. Second, the admitted time of patients was different and optimal time for surgery was different. These may influent the treatment results in some respects.

Conclusion

In summary, cervical laminoplasty combined with short-segment transpedicular screw instrumentation is a reliable and preferred option to treat extensional cervical SCIWORA in patient with CSS. The advantages of this regimen include achieving sufficient cervical spinal cord decompression, instant tri-column fixation, immediate cervical spine stability and avoid extra anterior cervical fusion.

Abbreviations

CT: Computed tomography

MRI: Magnetic resonance imaging

CSS:cervical spinal stenotic

CSCI: cervical spinal cord injury

SCIWORA: spinal cord injury without radiographic abnormality

ASIA: American Spinal Injury Associatio

JOA:. Japanese Orthopaedic Association

Declarations

Acknowledgments

We would like to thank subjects included in the current study.

Authors' contributions

Conception and design: BZ, KC; Administrative support: KC; Provision of study materials or patients: KC, ZP, RZ, WW, LC, ZZ; Collection and assembly of data: ZZ, HY; Data analysis and interpretation: ZP, BZ; Manuscript writing: All authors; Final approval of manuscript: All authors.

Funding

The present study was supported by the grants of Natural Science Foundation of China(No. 81860473,81460405;5511),the role of which included providing research equipment support and

equipment wastage; supported by the Innovation-driven Program of Jiangxi Province Department of Science and Technology(No.2165BCB18017),the role of which included design of the study and interpretation of data; supported by the Health Commission of Jiangxi Province(No. 20191029), the role of which included design of the study and English editing.

Availability of data and materials

The data and materials are available from the medical records department of The first, second Affiliated Hospital of Nanchang University, and The Affiliated Ganzhou Hospital of Nanchang University, China. Real data was obtained in this retrospective study. All the authors are accountable for all aspects of the work. The datasets used and analysed during the current study are available from the corresponding author on reasonable request.

Ethics approval and consent to participate

This study was performed in accordance with the Declaration of Helsinki as revised in 2008 and was authorized by the Ethics of The first, second Affiliated Hospital of Nanchang University, and The Affiliated Ganzhou Hospital of Nanchang University. There was no identifying personal information is included in this manuscript. All patients or their families signed the informed consent before surgery and provided the consent to publish and report individual clinical data.

Competing interests

All the authors declare that they have no competing interests. No benefits in any form have been received or will be received from a commercial party related directly or indirectly to the subject of this article.

References

1. Tewari MK, Gifti DS, Singh P, Khosla VK, Mathuriya SN, Gupta SK, Pathak A (2005) Diagnosis and prognostication of adult spinal cord injury without radiographic abnormality using magnetic resonance imaging: analysis of 40 patients. Surg Neurol 63:204–209, 209. 10.1016/j.surneu.2004.05.042*10.1016/j.surneu.2004.05.042
2. Kothari P, Freeman B, Grevitt M, Kerslake R (2000) Injury to the spinal cord without radiological abnormality (SCIWORA) in adults. J Bone Joint Surg Br 82:1034–1037
3. Boese CK, Lechler P (2013) Spinal cord injury without radiologic abnormalities in adults: a systematic review. J Trauma Acute Care Surg 75:320–330. 10.1097/TA.0b013e31829243c9*10.1097/TA.0b013e31829243c9
4. Plewes B (1938) SPINAL CORD INJURY WITHOUT EVIDENCE OF FRACTURE OR DISLOCATION OF THE VERTEBRAL COLUMN. CAN MED ASSOC J 38:475–477
5. Guo H, Liu J, Qi X, Ning G, Zhang H, Li X, Ma X (2012) Epidemiological characteristics of adult SCIWORA in Tianjin, China: a preliminary study. EUR SPINE J 21:165–171. 10.1007/s00586–011–

2041-x*10.1007/s00586–011–2041-x

6. Imajo Y, Hiiragi I, Kato Y, Taguchi T (2009) Use of the finite element method to study the mechanism of spinal cord injury without radiological abnormality in the cervical spine. Spine (Phila Pa 1976) 34:E83-E87. 10.1097/BRS.0b013e31818a2c30*10.1097/BRS.0b013e31818a2c30
7. Kasimatis GB, Panagiotopoulos E, Megas P, Matzaroglou C, Gliatis J, Tyllianakis M, Lambiris E (2008) The adult spinal cord injury without radiographic abnormalities syndrome: magnetic resonance imaging and clinical findings in adults with spinal cord injuries having normal radiographs and computed tomography studies. J Trauma 65:86–93. 10.1097/TA.0b013e318157495a*10.1097/TA.0b013e318157495a
8. Szwedowski D, Walecki J (2014) Spinal Cord Injury without Radiographic Abnormality (SCIWORA) - Clinical and Radiological Aspects. Pol J Radiol 79:461–464. 10.12659/PJR.890944*10.12659/PJR.890944
9. Aebli N, Wicki AG, Ruegg TB, Petrou N, Eisenlohr H, Krebs J (2013) The Torg-Pavlov ratio for the prediction of acute spinal cord injury after a minor trauma to the cervical spine. SPINE J 13:605–612. 10.1016/j.spinee.2012.10.039*10.1016/j.spinee.2012.10.039
10. Dalbayrak S, Yaman O, Firidin MN, Yilmaz T, Yilmaz M (2015) The contribution of cervical dynamic magnetic resonance imaging to the surgical treatment of cervical spondylotic myelopathy. TURK NEUROSURG 25:36–42. 10.5137/1019–5149.JTN.9082–13.1*10.5137/1019–5149.JTN.9082–13.1
11. Koyanagi I, Iwasaki Y, Hida K, Akino M, Imamura H, Abe H (2000) Acute cervical cord injury without fracture or dislocation of the spinal column. J NEUROSURG 93:15–20
12. Stemper BD, Yoganandan N, Pintar FA, Rao RD (2006) Anterior longitudinal ligament injuries in whiplash may lead to cervical instability. MED ENG PHYS 28:515–524. 10.1016/j.medengphy.2005.09.011*10.1016/j.medengphy.2005.09.011
13. Zhang J, Xia Q (2015) Role of Intraoperative Disc Contrast Injection in Determining the Segment Responsible for Cervical Spinal Cord Injury without Radiographic Abnormalities. ORTHOPAEDIC SURGERY 7:239–243. 10.1111/os.12197*10.1111/os.12197
14. Awad BI, Lubelski D, Steinmetz MP (2016) In Reply to the Letter to the Editor Regarding “Adjacent Level Ligamentous Injury Associated with Traumatic Cervical Spine Fractures: Indications for Imaging and Implications for Treatment”. WORLD NEUROSURG 86:7. 10.1016/j.wneu.2015.10.017*10.1016/j.wneu.2015.10.017
15. Szwedowski D, Walecki J (2014) Spinal Cord Injury without Radiographic Abnormality (SCIWORA) - Clinical and Radiological Aspects. Pol J Radiol 79:461–464. 10.12659/PJR.890944*10.12659/PJR.890944
16. Pang D, Pollack IF (1989) Spinal cord injury without radiographic abnormality in children—the SCIWORA syndrome. J Trauma 29:654–664
17. Masaki Y, Yamazaki M, Okawa A, Aramomi M, Hashimoto M, Koda M, Mochizuki M, Moriya H (2007) An analysis of factors causing poor surgical outcome in patients with cervical myelopathy due to ossification of the posterior longitudinal ligament - Anterior decompression with spinal fusion versus

laminoplasty. J SPINAL DISORD TECH 20:7–13. 10.1097/01.bsd.0000211260.28497.35*10.1097/01.bsd.0000211260.28497.35

18. Cao K, Huang L, Liu J, An H, Shu Y, Han Z (2010) Inhibitory effects of high-dose methylprednisolone on bacterial translocation from gut and endotoxin release following acute spinal cord injury-induced paraplegia in rats. NEURAL REGEN RES 5:456–460. 10.3969/j.issn.1673–5374.2010.06.009*10.3969/j.issn.1673–5374.2010.06.009
19. Allen BLJ, Ferguson RL, Lehmann TR, O'Brien RP (1982) A mechanistic classification of closed, indirect fractures and dislocations of the lower cervical spine. SPINE 7:1–27. 10.1097/00007632–198200710–00001*10.1097/00007632–198200710–00001
20. La Rosa G, Conti A, Cardali S, Cacciola F, Tomasello F (2004) Does early decompression improve neurological outcome of spinal cord injured patients? Appraisal of the literature using a meta-analytical approach. SPINAL CORD 42:503–512. 10.1038/sj.sc.3101627*10.1038/sj.sc.3101627
21. Guest J, Eleraky MA, Apostolides PJ, Dickman CA, Sonntag VK (2002) Traumatic central cord syndrome: results of surgical management. J NEUROSURG 97:25–32
22. Kawano O, Ueta T, Shiba K, Iwamoto Y (2010) Outcome of decompression surgery for cervical spinal cord injury without bone and disc injury in patients with spinal cord compression: a multicenter prospective study. SPINAL CORD 48:548–553. 10.1038/sc.2009.179*10.1038/sc.2009.179
23. Yamazaki T, Yanaka K, Fujita K, Kamezaki T, Uemura K, Nose T (2005) Traumatic central cord syndrome: analysis of factors affecting the outcome. Surg Neurol 63:95–99, 99–100. 10.1016/j.surneu.2004.03.020*10.1016/j.surneu.2004.03.020
24. Chen TY, Dickman CA, Eleraky M, Sonntag VK (1998) The role of decompression for acute incomplete cervical spinal cord injury in cervical spondylosis. Spine (Phila Pa 1976) 23:2398–2403
25. Song KJ, Yoon SJ, Lee KB (2012) Three- and four-level anterior cervical discectomy and fusion with a PEEK cage and plate construct. EUR SPINE J 21:2492–2497. 10.1007/s00586–012–2447–0*10.1007/s00586–012–2447–0
26. Fehlings MG, Barry S, Kopjar B, Yoon ST, Arnold P, Massicotte EM, Vaccaro A, Brodke DS, Shaffrey C, Smith JS, Woodard E, Banco RJ, Chapman J, Janssen M, Bono C, Sasso R, Dekutoski M, Gokaslan ZL (2013) Anterior Versus Posterior Surgical Approaches to Treat Cervical Spondylotic Myelopathy Outcomes of the Prospective Multicenter AOSpine North America CSM Study in 264 Patients. SPINE 38:2247–2252. 10.1097/BRS.0000000000000047*10.1097/BRS.0000000000000047
27. Luo J, Cao K, Huang S, Li L, Yu T, Cao C, Zhong R, Gong M, Zhou Z, Zou X (2015) Comparison of anterior approach versus posterior approach for the treatment of multilevel cervical spondylotic myelopathy. EUR SPINE J 24:1621–1630. 10.1007/s00586–015–3911–4*10.1007/s00586–015–3911–4
28. Liu T, Xu W, Cheng T, Yang H (2011) Anterior versus posterior surgery for multilevel cervical myelopathy, which one is better? A systematic review. EUR SPINE J 20:224–235. 10.1007/s00586–010–1486–7*10.1007/s00586–010–1486–7

29. Edwards CC, Heller JG, Murakami H (2002) Corpectomy Versus laminoplasty for multilevel cervical myelopathy - An independent matched-cohort analysis. SPINE 27:1168–1175. 10.1097/00007632–200206010–00007*10.1097/00007632–200206010–00007
30. Heller JG, Edwards CC, Murakami H, Rodts GE (2001) Laminoplasty versus laminectomy and fusion for multilevel cervical myelopathy - An independent matched cohort analysis. SPINE 26:1330–1336. 10.1097/00007632–200106150–00013*10.1097/00007632–200106150–00013
31. Bolesta MJ, Rechtine GR, Chrin AM (2000) Three- and four-level anterior cervical discectomy and fusion with plate fixation - A prospective study. SPINE 25:2040–2044. 10.1097/00007632–200008150–00007*10.1097/00007632–200008150–00007
32. Yoon ST, Hashimoto RE, Raich A, Shaffrey CI, Rhee JM, Riew KD (2013) Outcomes After Laminoplasty Compared With Laminectomy and Fusion in Patients With Cervical Myelopathy A Systematic Review. SPINE 381:S183-S194. 10.1097/BRS.0b013e3182a7eb7c*10.1097/BRS.0b013e3182a7eb7c
33. Nakashima H, Yukawa Y, Ito K, Machino M, El ZH, Kato F (2011) Posterior approach for cervical fracture-dislocations with traumatic disc herniation. EUR SPINE J 20:387–394. 10.1007/s00586–010–1589–1*10.1007/s00586–010–1589–1
34. Huang D, Du K, Zeng S, Gao W, Huang L, Su P (2011) The security analysis of transpedicular screw fixation in the lower cervical spine and a case report. Spine (Phila Pa 1976) 36:E1702-E1708. 10.1097/BRS.0b013e31821a5240*10.1097/BRS.0b013e31821a5240
35. Jones EL, Heller JG, Silcox DH, Hutton WC (1997) Cervical pedicle screws versus lateral mass screws. Anatomic feasibility and biomechanical comparison. Spine (Phila Pa 1976) 22:977–982
36. Xu ZW, Lun DX (2014) Surgical management of multilevel cervical spinal stenosis and spinal cord injury complicated by cervical spine fracture. J ORTHOP SURG RES 9:77. 10.1186/s13018–014–0077–4*10.1186/s13018–014–0077–4

Tables

Table 1 Demographic data of the patients

	Group A (n=48)	Group B (n=54)	P value
Age (years)	46.9±10.2	48.1±9.9	*0.548*
Gender			0.936
Male	43	49	-
Female	5	6	-
Injury time	4.8±2.6	5.2±3.0	0.476
Injured level			0.879
C2/3	1 (2.08 %)	2 (3.7 %)	-
C3/4	6(12.5 %)	7(12.96 %)	-
C4/5	22(45.83%)	27(50.0 %)	-
C5/6	16(33.33%)	16(29.64 %)	-
C6/7	3 (6.25 %)	2 (3.7 %)	-

Table 2 Preoperative and final follow-up ASIA levels between two groups

	Group A (n=48)	Group B (n=54)	Total	P value
Preoperatively ASIA				0.666
A	3 (6.25 %)	4 (7.4 %)	7(6.86%)	-
B	16 (33.33 %)	16 (29.64 %)	32(29.63 %)	-
C	24 (50 %)	27 (50 %)	51(50 %)	-
D	5 (10.42 %)	7 (12.96 %)	12(11.76%)	-
E	0 (0%)	0 (0%)	0(0%)	-
Final follow-up ASIA				0.907
A	2 (4.17 %)	2 (3.7 %)	4(3.92%)	-
B	6 (12.5 %)	7 (12.96 %)	13(12.75%)	-
C	12 (25 %)	15 (22.22 %)	27(26.47%)	-
D	22 (45.83 %)	21 (38.89 %)	43(42.16%)	-
E	6 (12.5 %)	9 (16.67 %)	15(14.71%)	-

Table 3 Preoperative and final follow-up JOA scores between two groups

	Group A (n=48)	Group B (n=54)	P value
Preoperatively JOA	6.12±1.76	6.63±2.45	0.235
Final follow-up JOA	11.98±2.98	12.62±3.59	*0.303*
Neurofunction recovery rate	53.13%	57.76%	*0.590*

Table 4 Surgery time, blood loss, hospital stay and complications between two groups

	Group A (n=48)	Group B (n=54)	P value
Surgery time	2.2±0.32	3.1±0.29	0.000*
Blood loss	304±56	388±61	0.000*
Hospital stay	8.2±3.1	12±2.8	*0.000**
Complication	4	14	*0.020**
CSF leaking	1	1	
Respiratory tract infection	2	3	
Wound infection	1	4	
Instrument failure	0	2	
Dysphagia	0	4	

CSF: cranial spinal fluid*,P value <0.05 is significant.

Figures

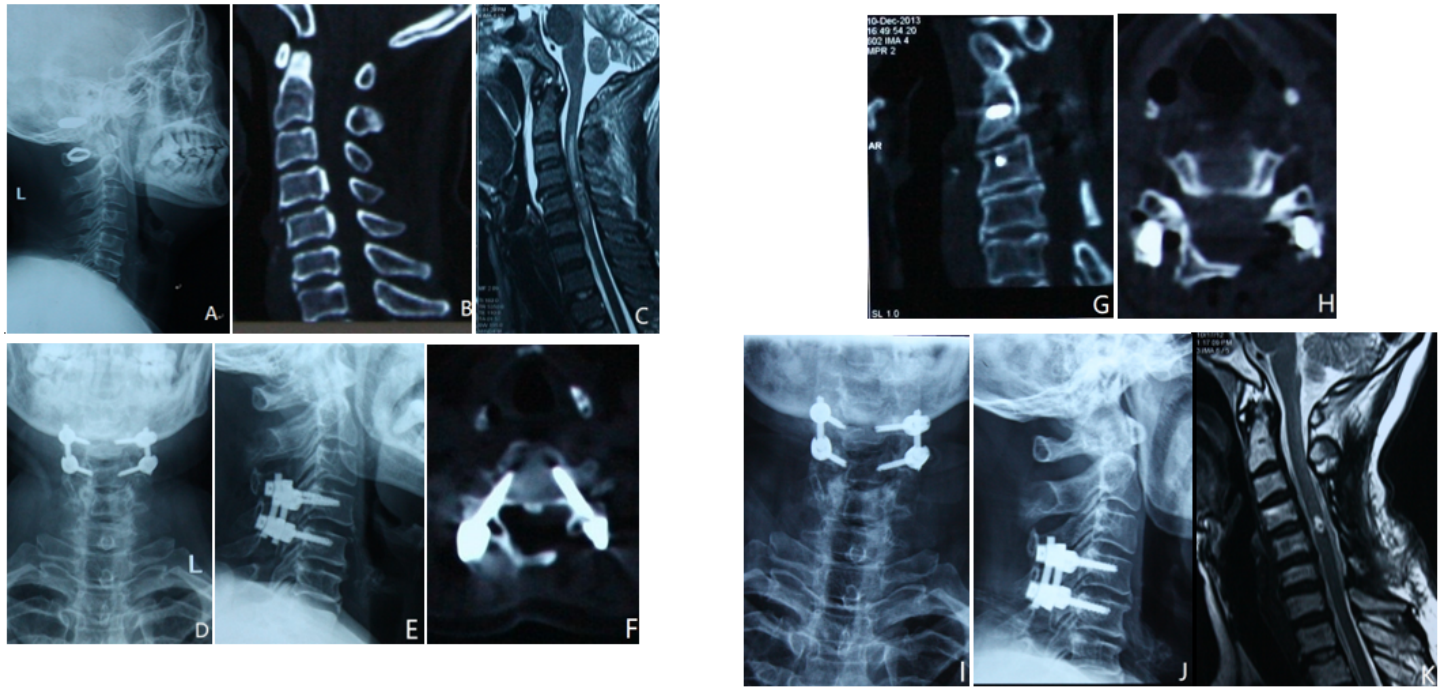

Figure 1

Laminoplasty with short-segmental transpedicular screw fixation in treating extensional cervical SCIWORA patient with CSS. A Lateral X-ray shows no cervical fracture or dislocation. B: Preoperative sagittal CT scan shows CSS and minor segmental ossification of posterior longitudinal ligament at C4–C6; C: Preoperative sagittal T2-weighted image shows an inhomogeneous high signal intensity of cervical cord extending from C3 to C6. Swelled Cervical cord and discontinuity of anterior longitudinal ligament and disc rupture at C4/5 can be observed. D-E: X-ray immediately after the operation shows the screws are inserted in appropriate position and the osseous cervical canal is significantly expanded sufficiently after laminoplasty from C3 to C6. F. The horizontal CT scan shows the screws trajectories are appropriate. G. Sagittal CT scan further confirm the osseous cervical canal is significantly expanded sufficiently after laminoplasty. H: The horizontal CT scan of 6 -months after surgery shows the hinged side of the cervical lamina has been osseously healed. I-J: The X - ray of one year after surgery shows a good position of internal fixation. K: MRI of 24 months after surgery indicates the expansive cervical canal is maintained, but post-trauma syringomyelia renders neurofunction of the patient recovers incompletely.

Supplementary Files

This is a list of supplementary files associated with this preprint. Click to download.

- Titlepage.docx