One Percutaneous Portal Endoscopic Discectomy in the Treatment of Two-Level Lumbar Disc Herniations Patients with Leg Pain and Numbness

Denglu Yan (yandenglu@163.com)
First People's Hospital of Zhaoqing https://orcid.org/0000-0001-6503-5077

Zaiheng Zhang
Shenzhen Baoan People's Hospital

Zhi Zhang
Third Affiliated Hospital of Guangzhou Medical College

Research article

Keywords: Lumbar, Disc, Herniation, Endoscopic, Numbness

Posted Date: September 23rd, 2020

DOI: https://doi.org/10.21203/rs.3.rs-80645/v1

Abstract

Background: Although minimally invasive has been adopted in the treatment of lumbar disc herniation, there were no studies in literature of two-level lumbar disc herniations patients with leg pain and numbness treatment by one portal percutaneous endoscopic procedures. The purpose of this study was to evaluate the efficacy of one percutaneous portal transforaminal endoscopic lumbar discectomy techniques in the treatment of two-level lumbar disc herniations patients with leg pain and numbness.

Methods: A total of 98 patients of two-level lumbar disc herniations who had one portal endoscopic surgery were categorized into two groups depending on the level number of endoscopic procedures. There were 51 patients had leg pain and leg numbness (A group), and 47 patients with leg pain (B group). One portal percutaneous endoscopic discectomy procedures were performed and the clinical outcomes were recorded.

Results: The entry point of two levels disc herniations is planned by parallel to the plane of the proximal disc level and target to the site of distal disc herniation. The procedures in two levels disc herniations was performed beginning at proximal level in L3/4 with L4/5 herniation and distal level in L4/5 with L5/S1. There were no nerve root injury and dural tear of cerebrospinal fluid leakage complications. The postoperative disk and foramen height were no significant difference compare to preoperative in all patients ($P > 0.05$), and no significant difference between two groups ($P > 0.05$). The pain index and Oswestry Disability Index score were better than preoperational in all patients, and no significant difference between two groups ($P > 0.05$). The central disc herniation patients had more leg numbness than lateral disc herniation patients ($P < 0.01$). For patients with leg pain and leg numbness, the leg numbness release in lateral disc herniation patients were better than central herniation patients, and leg numbness dismissed were 6 months post-operation in lateral herniation patients and 12 months post-operation in central herniation patients

Conclusions: Although two-level disc herniation present a significant challenge for spinal surgeon when adopted single portal techniques of endoscopic discectomy, one percutaneous portal transforaminal endoscopic lumbar discectomy was safe and minimally invasive techniques with faster recovery. For patients with leg pain and leg numbness, the central disc herniation patients had more leg numbness than lateral disc herniation patients, and the leg numbness release in lateral disc herniation patients were better than central herniation patients.

Background

Lumbar disc herniation was common in adult population, and most symptomatic lumbar disc herniations can be successfully treated with conservative therapy. When conservative management fails, discectomy have been shown to result in good outcomes [1–6]. With the development of minimally invasive methods in spine surgery, a number of techniques have recently been developed that are applicable in the treatment of lumbar disc herniation [7,8]. The current trend of evolution in lumbar spinal surgery has been

toward endoscopic discectomy, which is a minimally invasive treatments aimed at removing nuclear material and decompression the nerve through the devices were inserted into intervertebral discs by percutaneous [9–11,6]. Endoscopic lumbar discectomy has become attractive procedures for patients because it not only doesn't damage the spinal structures with less trauma and faster recovery but also safe procedures with local anesthesia [12–15]. For multilevel disc herniation case with monoradicular symptom, selective endoscopy discectomy that only deals with the responsible level can relieve symptom with minimal injury [12,16,3,10]. However, there are some multilevel disc herniation patients with more than one radicular symptom, and the multiple responsible level was confirmation on clinical symptom and radiological data. Then, percutaneous transforaminal endoscopic lumbar discectomy technique has evolved in treating multilevel disc herniation [17,2,18,19].

Endoscopic discectomy in multilevel lumbar disc herniation has become attractive procedures for patients due to its advantages of less trauma and local anesthesia [12,20–22,15]. Endoscopic discectomy may sometimes be challenging be performed successfully in patients with multilevel disc herniation because of the prolonged operative times and increased manipulation of the neural elements may cause postoperative complications. In one percutaneous portal discectomy treatment two-level disc herniation techniques, the trajectory from the enter point to two target was planned, and the working channel been precisely placed into the spinal canal for discectomy [13,19,23,24]. The most common lower extremity symptoms of multilevel disc herniation is pain, but often accompanied by numbness, tingling, and sometimes a burning sensation. Multilevel lumbar disc herniation patients, pain and numbness of the lower extremities are the most typical symptoms, which disturbed walking ability and limit their activity of daily living. After discectomy and nerve decompression, the tingling and burning sensation often released with the pain. However, the numbness always present and don't disappear with these accompanying symptoms [25–27].

With the minimally invasive surgery development, more and more patients take the endoscopic discectomy surgery for its minimally injury and fast recovery. However, the residual leg numbness not relieved by the minimally invasive procedures [28,27]. For multilevel lumbar disc herniation patients, pain and numbness are the most typical symptoms, which disturbed walking ability and limit their activity of daily living. After operation, residual leg numbness following endoscopic lumbar discectomy can lower patient satisfaction, which led to patients usually complain of leg numbness during or just after walking or standing [26,29]. The presence of residual leg numbness symptoms was a problem in clinical practice. The purpose of this study was to evaluate the clinical outcomes and efficacy of one percutaneous portal transforaminal endoscopic lumbar discectomy in the treatment of two-level lumbar disc herniation with numbness.

Methods

From February 2016 to January 2019, a total of 98 consecutive patients (42 cases were L3/4 with L4/5 level and 56 cases were L4/5 with L5/S1 level) of two-level lumbar disc herniations had endoscopic discectomy because of leg pain with or without leg numbness. The inclusion criteria were two responsible

level lumbar disc herniations at L3/4 with L4/5 levels and L4/5 with L5/S1 that was confirmed by two root clinical symptom involved and magnetic resonance imaging (MRI). Exclusion criteria included one responsible level with monoradicular symptom, and pathologic conditions of the lumbar spine (trauma, tumor, or infection). According to the symptoms of leg numbness, ninety eight patients were belong to two groups, 51 patients had leg pain and leg numbness (A group), and 47 patients with leg pain (B group).

All patients had single portal endoscopic discectomy for two-level disc herniation, and 12 patients were lost to follow-up (7 cases in A group and 5 patients in B group). Of the remaining 86 patients available for analysis, 44 patients had leg pain and leg numbness (A group, 20 cases was L3/4 and L4/5 levels and 24 cases was L4/5 and L5/S1 levels, included 23 men and 21 women with an average age of 42.73 ± 6.48 years), and 42 patients with leg pain (B group, 19 cases was L3/4 and L4/5 levels and 23 cases was L4/5 and L5/S1 levels, included 22 men and 20 women with an average age of 43.16 ± 5.39 years). The pain history were 11.75 ± 2.39 months in A group patient, and 11.38 ± 3.47 months in B group ($P > 0.05$). There was no significant difference between two groups in age, and gender distribution (Table 1, $P > 0.05$).

Table 1
General date of patients (Means ± SD)

Group	Gender		Age	Herniation locations		Pain history	Levels	
	Male	Female	(Years)	Central	Lateral	(Months)	L3/4/5	L4/5/S1
A (44)	23	21	42.73 ± 6.48	31	13	12.75 ± 2.39	20	24
B (42)	22	20	43.16 ± 5.39	17	25	11.38 ± 3.47	19	23

Surgical procedures

With the patient prone on a radiolucent operating table, the entry point of two levels disc herniations is planned by preoperative imaging according the proximal level, and the route of the working cannulas that from the entry point to the target was planned and marked on the skin (Fig. 1,2). If the iliac crest was higher than L4/5 disc level in L4/5 with L5/S1 patient, the approach line was forming the iliac highest point to the L4/5 level. The procedures in two levels disc herniations was performed beginning at proximal level in L3/4 with L4/5 herniation and distal level in L4/5 with L5/S1. After the first level herniated disc fragment was removed and nerve decompression was completed, the next levels procedures was performed. The transforaminal endoscopic discectomy was performed as the previous reported [30,31].

Since the surgery is done under local anesthesia, the surgeon has complete communication with the patient in procedures, by checking the movements of the affected limb and patient complaining sudden and severe radicular pain during the procedure. Foraminoplasty was performed when disc herniation at L5/S1 level, which removed small portions of anterolateral bone of facet articulation and its attached ligamentum flavum without interrupting the facet joint space, provided enough working space [32,33]. Finally, the endoscope and working cannula are removed from the patient, and the wound is closed with a single skin suture.

Critical of clinical outcomes

Before surgery and at the one-year follow-up, operation times, blood loss, hospital stays, pain (Visual Analog Scale, VAS) and functional disability (Oswestry Disability Index, ODI) were quantified in follow-up. All patients had preoperative and post-operative plain radiographs, computed tomography (CT) scans, and MR images. The focus was to evaluate height of disk space and intervertebral foramen.

Statistical analysis

All measurements were performed by a single observer and are expressed as means ± SD. Using the SPSS 17.0 statistics software, classic t-test and chi-square test were performed. Between-group comparisons should be performed using unpaired t-tests and chi-square tests, while within-group comparisons (preoperative vs. postoperative) should be performed using paired t-tests. The threshold for statistical significance used in this study was $p < 0.05$.

Results

The one percutaneous portal endoscopic discectomy for two-level lumbar disc herniation was performed in all cases. The approach from one entry point to two lumbar disc levels is planned and marked on the skin which parallel to the proximal and trajectory to the distal level. The endoscopic procedures were performed beginning at proximal level in L3/4 with L4/5 herniation and distal level in L4/5 with L5/S1 case. The procedure was performed successfully in all case, and no complication of nerve root injury and dural tear of cerebrospinal fluid leakage in this series cases.

In ends 86 cases had follow-up at least one year and 12 cases lost, and the follow-up rate was 86.3% (44/51) in A, and 89.4% (42/47) in B ($P > 0.05$). The followed time was from 12 to 16 months (average 13 months), and average 13.16 ± 1.57 months on A group, and 13.24 ± 1.73 months on B patients ($P > 0.05$). There were no patients suffered from any symptoms caused by recurrent herniated discs after 12 months of follow-up.

Table 2
Follow up time and operation date of patients (Means ± SD)

Group	Follow up*		Operation time*	Hospital days*	Blood loss*
	Rate	Time (Months)	(Minutes)	(Days)	(mL)
A	86.3% (44/51)	13.16 ± 1.57	51.84 ± 11.73	3.25 ± 1.46	44.58 ± 12.69
B	89.4% (42/47)	13.24 ± 1.73	54.75 ± 12.89	3.68 ± 1.29	42.83 ± 11.71
Note: *, no significant difference (P > 0.05)					

The hospital days, operational time, and blood losses was shown in Table 2. The hospital days were no significant difference between two groups patients (3.25 ± 1.46 days in A, and 3.68 ± 1.29 days in B, P > 0.05). The average operational time was 51.84 ± 11.73 minutes in A group patient and 54.75 ± 12.89 in B group, and there was no significant difference between two groups (P > 0.05). The average blood losses were 44.58 ± 12.69 mL in A group cases and 42.83 ± 11.71 mL B group, and there was no significant difference between two groups patients (P > 0.05).

Table 3
Clinical results date of patients (Means ± SD)

Group	A		B	
	Preoperative	Postoperative	Preoperative	Postoperative
VAS-pain	7.24 ± 1.25	1.12 ± 0.47	7.75 ± 1.29	1.48 ± 0.36
ODI	62.54 ± 12.63	11.68 ± 8.54	61.81 ± 13.49	12.37 ± 8.19
DH (mm)	8.76 ± 2.41	8.62 ± 2.47	8.47 ± 2.69	8.33 ± 2.75
FH (mm)	13.54 ± 1.82	13.42 ± 1.94	13.37 ± 1.68	13.15 ± 1.71

The pain scores, ODI, disk and foramen height were shown in Table 3. The ODI was no significant difference between two groups in preoperative (P > 0.05), which improved from 62.54 ± 12.63 to 11.68 ± 8.54 post-operative in A group patient (P < 0.01) and from 61.81 ± 13.49 to 12.37 ± 8.19 in B group (P < 0.01). The average disk space height decreased from preoperative 8.76 ± 2.41 mm in preoperatively to 8.62 ± 2.47 mm in postoperatively in A group patient (P > 0.05), and from 8.47 ± 2.69 mm to 8.33 ± 2.75 mm in B group (P > 0.05). There was no significant difference between two groups on the average change of disk height and intervertebral foramen height (P > 0.05). The mean foramen height decreased form 13.54 ± 1.82 mm in preoperatively to 13.42 ± 1.94 mm in postoperatively in A group patient (P > 0.05), and from 13.37 ± 1.68 mm to 13.15 ± 1.71 mm in B group (P > 0.05).

There was no significant difference between two groups on the average change of VAS-pain (P > 0.05). VAS-pain improved from 7.24 ± 1.25 to 1.12 ± 0.47 in A group patient (P < 0.01), and from 7.75 ± 1.29 to 1.48 ± 0.36 in B groups (P < 0.01). For patients with leg pain and leg numbness, the leg pain discharged postoperatively (P < 0.01), and leg numbness were last three to six months of post-operation. The average VAS-numbness scores were 7.58 ± 2.64 in preoperative, 7.47 ± 2.72 in post-operative, 5.89 ± 2.15 in 1 month post-operation, 3.34 ± 2.71 in 3 months post-operation, 2.46 ± 0.57 in 6 months post-operation, and 1.05 ± 0.38 in 12 months post-operation.

Table 4
Residual leg numbness patients' data (Means ± SD)

VAS-N	Preoperative	1 Week PO	1 Month PO	3 Months PO	6 Months PO	12 Months PO
Central DH	7.83 ± 2.42	7.39 ± 2.64	6.53 ± 2.46	3.84 ± 2.69	2.95 ± 0.68	1.15 ± 0.48
Lateral DH	7.35 ± 2.18	7.13 ± 2.35	4.47 ± 2.83	2.58 ± 1.42	1.14 ± 0.36	0.56 ± 0.23
Note: DH = Disc Herniation, N = Numbness, PO = Post-Operative						

The residual leg numbness patients' data shown in Table 4. The lumbar disc herniation locations were difference between two groups (Table 1), and the central disc herniation patients had more leg numbness than lateral disc herniation patients (P < 0.01). Patients with leg pain and leg numbness pre-operation complain of leg numbness during or just after walking or standing not diminished after surgery. Among these patients, the leg numbness release in lateral disc herniation patients were better than central herniation patients, and leg numbness dismissed were 6 months post-operation in lateral herniation patients and 12 months post-operation in central herniation patients (P < 0.01).

Discussion

Lumbar disc herniation in adults is characterized by the pain of leg with or without leg numbness due to disk degeneration, which involves a multitude of cellular and biochemical changes [34,16,13]. When conservative management fails, discectomy was safe and effective surgery. With the minimally invasive techniques development, endoscopic discectomy was become popular for its advantages of small incision and faster recovery [11,20,24]. When patients with two responsible levels disc herniation need surgery treatment, patients always want the surgery was minimally [19,14,4]. At the present study, the percutaneous transforaminal endoscopic discectomy was performed from one percutaneous portal. The pain index and ODI scores were significantly better the preoperative in all patients, and no nerve injury and dural tears complication. The results of this series cases were accordance with the previous reported, which show the percutaneous transforaminal endoscopy discectomy to be safe and its complication rate is low. Then, two-level endoscopic discectomy can be successfully performed by one percutaneous portal.

Percutaneous transforaminal endoscopic lumbar discectomy has proven to be a faster and safe practical approach for treating lumbar disc prolapse [34,35,3,21,22]. Ideally, the most direct and safest approach towards the pathology of two-level herniated fragments should be utilized in one portal transforaminal endoscopic discectomy [13,18,23,1,35,36]. The transforaminal approach was reported to be hard to conduct at the level of L5/S1, because iliac crest may bother the cannula installation through the intervertebral foramen especially for the high iliac cases [37,22,19,10]. From the trajectory of skin entry point approaching the foramen, identification of anatomical landmarks will help to follow plan the route and avoid complications of surgery [37,21,14,3]. In this series cases, using the transforaminal routes depending on the characteristics of each level, accuracy of approach has huge bearing on the success of two-level endoscopic discectomy from one portal.

Endoscopic lumbar discectomy has evolved into not only suitable for one level disc herniation, but also to multiple level disc herniation [2,13,18,15]. For patients with leg pain and leg numbness, the leg pain discharged postoperatively, and leg numbness were last three to six months of post-operation. Patients with leg pain and leg numbness pre-operation complain of leg numbness during or just after walking or standing not diminished after surgery. Symptoms of numbness was result in regional nerve and cord ischemia which been compression by pathology tissue[27,38]. Long term of ischemia leads to an imbalance between nerve metabolic demand and oxygen supply and the nerve tissue damage. Inflammatory responses are known as a major component of secondary injury of initial ischemic insult and play an important role in modulating the pathogenesis of leg numbness[26,25]. The leg numbness symptoms were last longer in central disc herniation patients than in paracentral and foraminal disc herniation patients after surgery, which means the inflammatory response from herniated herniate disc fragments compression nerve may be an important factor in affection on it.

Percutaneous one portal endoscopic transforaminal discectomy technique is ideally suited for unilateral disc herniation with leg pain and numbness [23,24,10]. The most direct and safest approach towards the pathology should be utilized in one portal treatment two-level herniation. Although patients with leg pain and leg numbness pre-operation complain of leg numbness during or just after walking or standing not diminished after surgery, the leg numbness dismissed were 6 months post-operation in lateral herniation patients and 12 months post-operation in central herniation patients. Then, percutaneous one portal transforaminal endoscopic lumbar discectomy is the preferred minimally invasive approach in two-level disc herniation case due to less trauma, less blood lost, and short operation time, and faster recover[25].

Conclusions

Although two-level disc herniation present a significant challenge for spinal surgeon when adopted single portal techniques of endoscopic discectomy, one percutaneous portal transforaminal endoscopic lumbar discectomy was safe and minimally invasive techniques with faster recovery. For patients with leg pain and leg numbness, the central disc herniation patients had more leg numbness than lateral disc herniation patients, and the leg numbness release in lateral disc herniation patients were better than central herniation patients.

Abbreviations

VAS: Visual analog scale; **ODI:** Oswestry Disability Index; **CT:** Computed tomography; **MR:** Magnetic resonance

Declarations

Ethical approval and consent to participate

This study was approved by the hospital ethics committee of the First People's Hospital of Zhaoqing, Zhaoqing City, Guangdong Province, and all patients signed had informed consent.

Consent for publish

Written informed consent was obtained from all participants.

Availability of data and materials

The datasets are available under reasonable request, please contact Yan.

Competing interests

All authors declare that they have no conflict of interests.

Funding

Not applicable of funding on this work.

Authors' Contributions

DLY participated in the design of the study, performance the surgery, and drafted the manuscript. ZZH helped to draft the manuscript and performed the statistical analysis. ZZ participated in the design of the study and coordination. All authors have read and approved the manuscript.

Acknowledgements

We sincerely appreciated the genial help from all scholars who contributed to our research.

References

1. Choi DJ, Jung JT, Lee SJ, Kim YS, Jang HJ, Yoo B (2016) Biportal Endoscopic Spinal Surgery for Recurrent Lumbar Disc Herniations. Clin Orthop Surg 8 (3):325-329. doi:10.4055/cios.2016.8.3.325
2. Choi KC, Kim JS, Kang BU, Lee CD, Lee SH (2011) Changes in back pain after percutaneous endoscopic lumbar discectomy and annuloplasty for lumbar disc herniation: a prospective study. Pain Med 12 (11):1615-1621. doi:10.1111/j.1526-4637.2011.01250.x

3. Iprenburg M, Wagner R, Godschalx A, Telfeian AE (2016) Patient radiation exposure during transforaminal lumbar endoscopic spine surgery: a prospective study. Neurosurg Focus 40 (2):E7. doi:10.3171/2015.11.FOCUS15485
4. Mayer HM, Brock M (1993) Percutaneous endoscopic lumbar discectomy (PELD). Neurosurg Rev 16 (2):115-120
5. Wang X, Zhou S, Bian Z, Li M, Jiang W, Hou C, Zhu L (2018) Unilateral percutaneous endoscopic debridement and drainage for lumbar infectious spondylitis. J Orthop Surg Res 13 (1):306. doi:10.1186/s13018-018-1009-5
6. Li X, Dou Q, Hu S, Liu J, Kong Q, Zeng J, Song Y (2016) Treatment of cauda equina syndrome caused by lumbar disc herniation with percutaneous endoscopic lumbar discectomy. Acta Neurol Belg 116 (2):185-190. doi:10.1007/s13760-015-0530-0
7. Komp M, Hahn P, Oezdemir S, Giannakopoulos A, Heikenfeld R, Kasch R, Merk H, Godolias G, Ruetten S (2015) Bilateral spinal decompression of lumbar central stenosis with the full-endoscopic interlaminar versus microsurgical laminotomy technique: a prospective, randomized, controlled study. Pain Physician 18 (1):61-70
8. Kim JE, Choi DJ, Park EJ (2018) Clinical and Radiological Outcomes of Foraminal Decompression Using Unilateral Biportal Endoscopic Spine Surgery for Lumbar Foraminal Stenosis. Clin Orthop Surg 10 (4):439-447. doi:10.4055/cios.2018.10.4.439
9. Lu S, Xu YQ, Ding ZH, Wang YL, Shi JH, Zhong SZ (2008) Clinical anatomic study of the lower lumbar anterolateral vein: with respect to retroperitoneal endoscopic surgery. Chin J Traumatol 11 (2):110-113. doi:10.1016/s1008-1275(08)60023-1
10. Lee CW, Yoon KJ (2019) The Usefulness of Percutaneous Endoscopic Technique in Multifocal Lumbar Pathology. Biomed Res Int 2019:9528102. doi:10.1155/2019/9528102
11. Yokosuka J, Oshima Y, Kaneko T, Takano Y, Inanami H, Koga H (2016) Advantages and disadvantages of posterolateral approach for percutaneous endoscopic lumbar discectomy. J Spine Surg 2 (3):158-166. doi:10.21037/jss.2016.09.03
12. Liu W, Li Q, Li Z, Chen L, Tian D, Jing J (2019) Clinical efficacy of percutaneous transforaminal endoscopic discectomy in treating adolescent lumbar disc herniation. Medicine (Baltimore) 98 (9):e14682. doi:10.1097/MD.0000000000014682
13. Yeom KS, Choi YS (2011) Full endoscopic contralateral transforaminal discectomy for distally migrated lumbar disc herniation. J Orthop Sci 16 (3):263-269. doi:10.1007/s00776-011-0048-0
14. Lee SH, Kang BU, Ahn Y, Choi G, Choi YG, Ahn KU, Shin SW, Kang HY (2006) Operative failure of percutaneous endoscopic lumbar discectomy: a radiologic analysis of 55 cases. Spine (Phila Pa 1976) 31 (10):E285-290. doi:10.1097/01. brs.0000216446.13205.7a
15. Jang JS, An SH, Lee SH (2006) Transforaminal percutaneous endoscopic discectomy in the treatment of foraminal and extraforaminal lumbar disc herniations. J Spinal Disord Tech 19 (5):338-343. doi:10.1097/01.bsd.0000204500.14719.2e

16. Hoogland T, van den Brekel-Dijkstra K, Schubert M, Miklitz B (2008) Endoscopic transforaminal discectomy for recurrent lumbar disc herniation: a prospective, cohort evaluation of 262 consecutive cases. Spine (Phila Pa 1976) 33 (9):973-978. doi:10.1097/BRS.0b013e31816c8ade
17. Sairyo K, Goel VK, Masuda A, Biyani A, Ebraheim N, Mishiro T, Terai T (2005) Biomechanical rationale of endoscopic decompression for lumbar spondylolysis as an effective minimally invasive procedure - a study based on the finite element analysis. Minim Invasive Neurosurg 48 (2):119-122. doi:10.1055/s-2004-830223
18. Passacantilli E, Lenzi J, Caporlingua F, Nardone A, Cannizzaro D, Pescatori L, Santoro A (2016) Full endoscopic transforaminal endoscopic approach for symptomatic lumbar disc herniation, our experience. J Neurosurg Sci 60 (3):410-412
19. Kamson S, Trescot AM, Sampson PD, Zhang Y (2017) Full-Endoscopic Assisted Lumbar Decompressive Surgery Performed in an Outpatient, Ambulatory Facility: Report of 5 Years of Complications and Risk Factors. Pain Physician 20 (2):E221-E231
20. Tu Z, Li YW, Wang B, Lu G, Li L, Kuang L, Dai Y (2017) Clinical Outcome of Full-endoscopic Interlaminar Discectomy for Single-level Lumbar Disc Herniation: A Minimum of 5-year Follow-up. Pain Physician 20 (3):E425-E430
21. Lee SH, Chung SE, Ahn Y, Kim TH, Park JY, Shin SW (2006) Comparative radiologic evaluation of percutaneous endoscopic lumbar discectomy and open microdiscectomy: a matched cohort analysis. Mt Sinai J Med 73 (5):795-801
22. Shiboi R, Oshima Y, Kaneko T, Takano Y, Inanami H, Koga H (2017) Different operative findings of cases predicted to be symptomatic discal pseudocysts after percutaneous endoscopic lumbar discectomy. J Spine Surg 3 (2):233-237. doi:10.21037/jss.2017.05.07
23. Teli M, Lovi A, Brayda-Bruno M, Zagra A, Corriero A, Giudici F, Minoia L (2010) Higher risk of dural tears and recurrent herniation with lumbar micro-endoscopic discectomy. Eur Spine J 19 (3):443-450. doi:10.1007/s00586-010-1290-4
24. Lee JH, Lee SH (2018) Which clinical and radiological variables could predict clinical outcomes of percutaneous endoscopic lumbar discectomy for treatment of patients with lumbosacral disc herniation? Spine J 18 (8):1338-1346. doi:10.1016/j.spinee.2017.12.010
25. Yan D, Zhang Z, Zhang Z (2020) Residual leg numbness after endoscopic discectomy treatment of lumbar disc herniation. BMC Musculoskelet Disord 21 (1):273. doi:10.1186/s12891-020-03302-5
26. Oba H, Tsutsumimoto T, Yui M, Kamanaka T, Ohta H, Kosaku H, Misawa H (2017) A prospective study of recovery from leg numbness following decompression surgery for lumbar spinal stenosis. J Orthop Sci 22 (4):670-675. doi:10.1016/j.jos.2017.04.004
27. Fishman SM (2006) Surgery for leg numbness with back pain, patient controlled analgesia, phantom limb pain. J Pain Palliat Care Pharmacother 20 (3):61-65
28. Lowson D (1885) Case of Displacement and Fracture of the Axis. Life prolonged for ten years. Med Chir Trans 68:135-138. doi:10.1177/095952878506800109

29. Skeik N, Jabr FI (2008) Intermittent back and leg pain with numbness. Tethered spinal cord syndrome. Am Fam Physician 78 (7):869-870
30. Kim HS, Paudel B, Jang JS, Lee K, Oh SH, Jang IT (2018) Percutaneous Endoscopic Lumbar Discectomy for All Types of Lumbar Disc Herniations (LDH) Including Severely Difficult and Extremely Difficult LDH Cases. Pain Physician 21 (4):E401-E408
31. Hu QF, Pan H, Fang YY, Jia GY (2018) Percutaneous endoscopic lumbar discectomy for high-grade down-migrated disc using a trans-facet process and pedicle-complex approach: a technical case series. Eur Spine J 27 (Suppl 3):393-402. doi:10.1007/s00586-017-5365-3
32. Lee S, Kim SK, Lee SH, Kim WJ, Choi WC, Choi G, Shin SW (2007) Percutaneous endoscopic lumbar discectomy for migrated disc herniation: classification of disc migration and surgical approaches. Eur Spine J 16 (3):431-437. doi:10.1007/s00586-006-0219-4
33. Chung J, Kong C, Sun W, Kim D, Kim H, Jeong H (2019) Percutaneous Endoscopic Lumbar Foraminoplasty for Lumbar Foraminal Stenosis of Elderly Patients with Unilateral Radiculopathy: Radiographic Changes in Magnetic Resonance Images. J Neurol Surg A Cent Eur Neurosurg 80 (4):302-311. doi:10.1055/s-0038-1677052
34. Wang YP, Zhang W, Zhang J, Sun YP, An JL, Ding WY (2017) Analysis of the clinical effects of transforaminal endoscopic discectomy on lumbar disk herniation combined with common peroneal nerve paralysis: a 2-year follow-up retrospective study on 32 patients. J Pain Res 10:105-112. doi:10.2147/JPR.S120463
35. Gadjradj PS, van Tulder MW, Dirven CM, Peul WC, Harhangi BS (2016) Clinical outcomes after percutaneous transforaminal endoscopic discectomy for lumbar disc herniation: a prospective case series. Neurosurg Focus 40 (2):E3. doi:10.3171/2015.10.FOCUS15484
36. Dabo X, Ziqiang C, Yinchuan Z, Haijian N, Kai C, Yanbin L, Qiang F, Chuanfeng W (2016) The Clinical Results of Percutaneous Endoscopic Interlaminar Discectomy (PEID) in the Treatment of Calcified Lumbar Disc Herniation: A Case-Control Study. Pain Physician 19 (2):69-76
37. Lee CW, Yoon KJ, Ha SS (2019) Comparative Analysis between Three Different Lumbar Decompression Techniques (Microscopic, Tubular, and Endoscopic) in Lumbar Canal and Lateral Recess Stenosis: Preliminary Report. Biomed Res Int 2019:6078469. doi:10.1155/2019/6078469
38. Strober JB, Zuppa A, Brooks-Kayal AR (1999) A 15-year-old with back pain, fever, and leg numbness. Semin Pediatr Neurol 6 (3):190-194; discussion 194-195. doi:10.1016/s1071-9091(99)80012-6

Figures

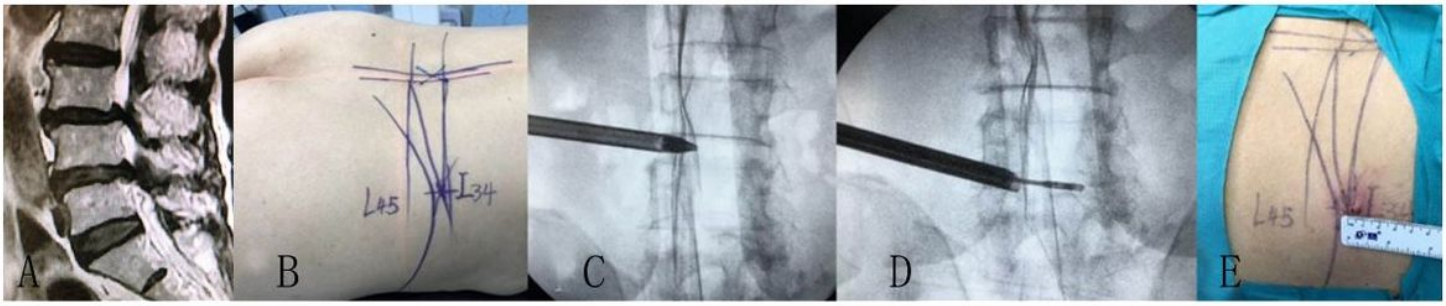

Figure 1

Two-level disc herniations at L3/4 and L4/5 of 39 years old female patient with leg pain and leg numbness taken one portal percutaneous transforaminal endoscopic discectomy. A, L3/4 and L4/5 disc herniation on MRI; B, procedures approach was marked on the skin; C, image of working cannula was placed at L3/4 level; D, image of transforaminal endoscopic discectomy at L4/5 level from the same portal; E, Single percutaneous portal for two level discectomies was shown after procedures.

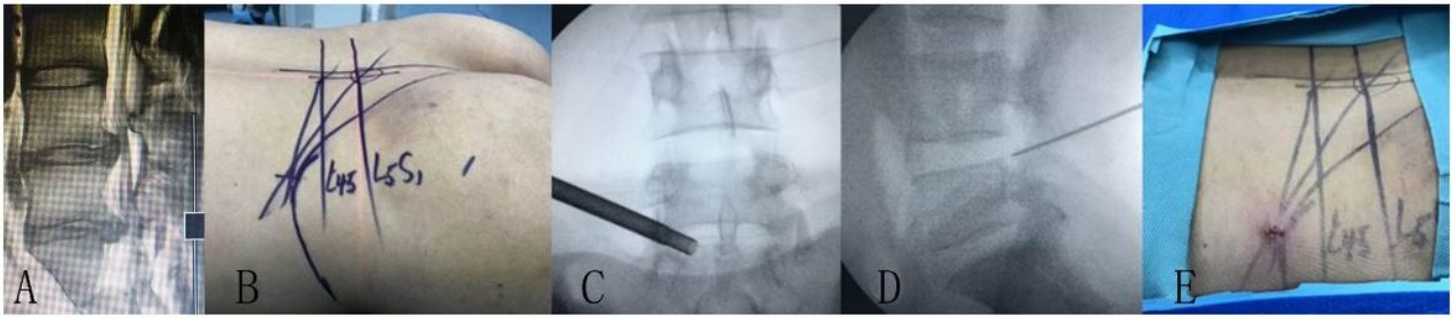

Figure 2

Male patient of 41 years had two level disc herniations at L4/5 and L5/S1 with leg pain and leg numbness underwent the procedures of one portal endoscopic discectomy. A, L4/5 and L5/S1 disc herniation on MRI; B, procedures rote was marked on the skin; C, image of foraminoplasty was performed at L5/S1 level; D, image of needle was inserted the L4/5 level from transforaminal; E, Single percutaneous portal for two level discectomies was shown after procedures.