Refinement of uterine fragment sampling in experimental studies using small ruminants: from leptospirosis to beyond

Bruna Guadelupe
Universidade Federal Fluminense
Gabriel Martins
Universidade Federal Fluminense
Mário Felipe Alvarez Balaro
Universidade Federal Fluminense
Pedro Henrique Nicolau Pinto
Universidade Federal Fluminense
WALTER LILENBAUM (wlilenbaum@id.uff.br)
Universidade Federal Fluminense https://orcid.org/0000-0002-2434-8728

Research Article

Keywords: biopsy, laparotomy, leptospirosis, sheep

Posted Date: September 24th, 2021

DOI: https://doi.org/10.21203/rs.3.rs-809380/v1

Abstract

Ruminant genital leptospirosis is a particular syndrome, in which leptospires remain lodged in the organs of the reproductive tract causing inflammatory changes and/or embryonic/fetal infection resulting in significant reproductive losses. To collect uterine biopsies from small ruminants, surgeries that are costly and time-consuming, causing injury to the animals, are used. In this article, we describe the technique used of videolaparotomy and we dazzle a satisfactory result, with the collected material and the animal welfare. The animals recovered faster and no antibiotics were needed, improving animal welfare. From the technique of collecting the uterine fragment by videolaparoscopy, it was possible to obtain a biological material of high quality, providing also a shorter handling time for animals, less invasive, lower cost and obtaining the same results as a surgery. This is related to ethical principles, particularly with the third of the 3Rs, Refinement, minimizing potential pain and distress and enhance animal welfare.

1. Introduction

Leptospirosis is a worldwide disease caused by pathogenic bacteria of the genus *Leptospira* sp.. It affects several domestic animals, wild and human beings. In livestock it causes reproductive disorders, such as the repetition of estrus, abortion and infertility, leading to important economic losses (Ellis, 2015). The study based on uterine samples is recent, and particularly focused on slaughterhouses sampling due to technical difficulties to obtain uterine samples from live animals (Di Azevedo and Lilenbaum, 2021).

Sheep have been used as a good experimental model for studies of leptospirosis in ruminants (Rocha et al., 2020), particularly in studies focused in reproductive aspects of the disease, known as Bovine Genital Leptospirosis – BGL (Loureiro and Lilenbaum, 2020). Currently, the only method suggested for sampling uterine fragments from live animals for bacteriology or PCR is laparotomy.

Laparotomy requires depravation of food from 24-36h and of water for at least 12h. It also requires sedation followed by general anesthesia. After, the reproductive tract (uterus, uterine coupons and ovaries) is exposed through longitudinal ventral laparotomy with animals in recumbent dorsal position and a small portion of the uterine body is /removed by a scalpel blade. After the process, anti-inflammatories and antibiotic therapy are required for at least three days. It is a costly technique due to the expensive equipment, trained personnel and general anesthesia required. Furthermore, the manipulation of the abdominal cavity may promote adhesions, what may reduce the animal's reproductive life (Fonseca et al., 2011). Our group has previously used laparotomy to sample uterine fragments (Rocha et al., 2018), and, at that occasion, it was visible that the recovery of the animals was difficult and time consuming.

Considering those limitations and trying to follow one of the most important precepts of bioethics, the refinement, we have recently chosen to use a less invasive technique, combining videolaparoscopy with a Tru-Cut® biopsy device. The goals were to reduce cost, the time of surgery and recovery of animals, avoid health risks due to anesthesia, as well as adhesions or injuries to the genital tract. Besides, we also

planned to avoid the unnecessary use of antibiotics as well as reduce the use of anti-inflammatories. In this sense, the new procedure herein described is faster, and, most important, less painful to the animal.

2. Materials And Methods

All procedures described in this Technical note were approved by the Ethical Committee for Animal Use of the Universidade Federal Fluminense (protocol nº1784100719), followed the guidelines of the Conselho Nacional de Controle de Experimentação Animal (CONCEA), and were conducted under the ethical principles of the Sociedade Brasileira de Ciência em Animais de Laboratório.

Sheep were deprived of food for 24h and water for 12h before laparoscopic intervention. The laparoscopies were performed by placing the sheep in the dorsal decubitus in a standard crib for laparoscopic procedures (Fig. 1). The surgical field, cranial to the udder, was scraped and disinfected. The whole procedure was performed under sedation induced by AcePromazine IV (0.1 mg/kg; 12%, Vetnil, São Paulo, Brazil), Diazepam IV (0.3mg/kg; Unidiazepax, Chemical Union, São Paulo, Brazil). Subcutaneous local anesthetic with lidocaine SC (0.05ml/kg lidocaine; Lidovet, Bravet LDTA, Rio de Janeiro, Brazil) was injected into the insertion of the trocar.

Pneumoperitoneum was induced through a cannula by a closed system with carbon dioxide which allows the inlet of approximately 2 liters of inert air into the abdominal cavity. Next, for the uterus visualization, an endoscope of 5 mm 30o (Karl Storz®, Germany), coupled to a video camera, was inserted into the abdominal cavity through a trocar, approximately 5 cm cranially to the udder and 5 cm left of the middle line. The uterus was manipulated by a babcockath path (33533BL Karl Storz®, Germany) through a second trocar, placed approximately 5 cm cranial to the udder and 5 cm to the right of the middle line. Then a tru-cut biopsy needle (14 G) was inserted, about 2 cm cranial to the right trochater, and a sample of the uterine body and another of the uterine horn (mean part) were collected (Video 1 – supplementary material). After the laparoscopic process, all animals were treated with a single dose of Melloxicam IM (2.0 mg/kg; Maxican, Ouro Fino, São Paulo, Brazil).

3. Results

In general, the new procedure herein described is faster, and, most important, less painful to the animal.

Initially, laparotomies were performed on the ewes to collect histological samples, and we realized that it required more time, performing a smaller number of surgeries in a single day, more costly and wearing out the animals. Through videolaparoscopy, it was possible to obtain samples of uterine fragments of excellent quality, which were fractionated and used for various diagnostic techniques, such as culture, histopathology and PCR.

4. Discussion And Conclusions

In our research group, sheep have been used as the main models of leptospire infection in ruminants (Loureiro and Lilenbaum, 2020). Post-surgical sequelae, such as adhesions, risk of loss of fertility and the high cost of the technique, limit its widespread use in sheep (Mobine et al., 2002; Holtz, 2005). It was not until the late 1970s that non-surgical techniques were successfully developed and employed (Brand and Drost, 1977a). It is noteworthy that the issue of animal welfare is in focus in this study, aiming at the knowledge of non-surgical techniques in animal management and in the collection of biological samples.

Overall, no differences were observed between tests using uterine fragments collected by traditional laparotomy or videolaparoscopy. However, videolaparotomy provides the animal with less pain, minimizes surgical trauma and surgery time, being less invasive, inexpensive and without general anesthesia. The animals recovered faster and no antibiotics were needed, improving animal welfare. From the technique of collecting the uterine fragment by videolaparoscopy, it was possible to obtain a biological material of high quality, providing also a shorter handling time for animals, less invasive, lower cost and obtaining the same results as a surgery. This is related to ethical principles, particularly with the third of the 3Rs, Refinement, minimizing potential pain and distress and enhance animal welfare.

Declarations

Acknowlegments

The authors thank for collaboration of Felipe Leal, Helena Ferreira, Isabel Consentino, Luiza Aymee, Pietro Dias, Augusto Ryonosuke in assistence of getting samples for the project. WL is a CNPq and FAPERJ fellow.

Statement of Animal Rights

All procedures described in this Technical note were approved by the Ethical Committee for Animal Use of the Universidade Federal Fluminense (protocol nº1784100719), followed the guidelines of the Conselho Nacional de Controle de Experimentação Animal (CONCEA), and were conducted under the ethical principles of the Sociedade Brasileira de Ciência em Animais de Laboratório.

Conflict of interest

None of the authors have any conflict of interest to declare.

Funding

This work was supported by the Fundação de Amparo à Pesquisa do Estado do Rio de Janeiro (FAPERJ) and Conselho Nacional de Desenvolvimento Cientifico e Tecnológico (CNPq).

Supplementary Data (Video 1)

For a better reference, we provide the video of the procedure performed on the link.
https://youtu.be/5Eaf1HmhP78

Author's contribution

Bruna Guadelupe: Investigation, Data curation, Writing - Original draft; **Gabriel Martins:** Supervision, Project administration, Writing – Review & Editing; **Mário Felipe Alvarez Balaro:** Conceptualization, Methodology, Visualization; **Pedro Henrique Nicolau Pinto:** Conceptualization, Methodology, Visualization; **Walter Lilenbaum**: Conceptualization, Funding acquisition, Project administration, Supervision.

Data Availability Statement: The datasets generated during and/or analysed during the current study are available from the corresponding author on reasonable request.

References

1. Adler, B., 2015. History of leptospirosis and Leptospira. Current Topics in Microbiology and Immunology, 387, 1–9.
2. Di Azevedo Min., Lilenbaum, W., 2021. An overview on the molecular diagnosis of animal leptospirosis. Letters in Applied Microbiology, 72, 496–508.
3. Diogo, C. C., Camassa, J. A., Pereira, J. E., Costa, L. M. D., Filipe, V., Couto, P. A., Geuna, S., Maurício, A. C., Varejão, A.S., 2017. The use of sheep as a model for studying peripheral nerve regeneration following nerve injury: review of the literature. Neurology Resesarch, 39, 926–939.
4. Ellis, W. A., 2015. Animal leptospirosis. Current Topics in Microbiology and Immunology, 387, 99–137.
5. Fonseca, J. F., Oliveira, M. E. F., Viana, J. H. M., 2011. Uso de procedimentos não cirúrgicos para a produção, recuperação e inovulação de embriões em pequenos ruminantes. Revista Brasileira de Reprodução Animal, 35, 113–117.
6. Loureiro, A. P., Lilenbaum, W., 2020. Genital bovine leptospirosis: A new look for an old disease. Theriogenology, 141, 41–47.
7. Mobine S., Heath A.M., Pugh D.G., 2002. Sheep and goat medicine. In: Pugh DG. Theriogenology of sheep and goat. (WB Saunders: Philadelphia). p.129–186.
8. Pinto, P., Barbosa, C., Ferreira, A., Lilenbaum, W., 2020. Uterine leptospiral infection is strongly associated to strains of serogroup Sejroe on experimentally infected hamsters. Microbial Pathogenesis, 142, 104030.
9. Rocha, B.R., Balaro, M., Pereira, P., Martins, G., Lilenbaum, W., 2018. Chronic experimental genital leptospirosis with autochthonous *Leptospira santarosai* strains of serogroup Sejroe. Small Ruminant Research, 164, 28–31.
10. Rocha, B.R., Martins, G., Lilenbaum, W. 2020. An historical view of the experimental leptospiral infection in ruminants. Comparative Immunology, Microbiology & Infectious Diseases. 73, 101532.
11. Silva, A.F., Farias, P.J.A., Silva, M.L.C.R., Araújo Júnior, J.P., Malossi, C.D., Ullmann, L.S., Costa, D.F., Higino, S.S.S., Azevedo, S.S., Alves, C.J., 2019. High frequency of genital carriers of Leptospira sp. in

sheep slaughtered in the semi-arid region of northeastern Brazil. Tropical Animal Health and Production, 51, 43–47.

Figures

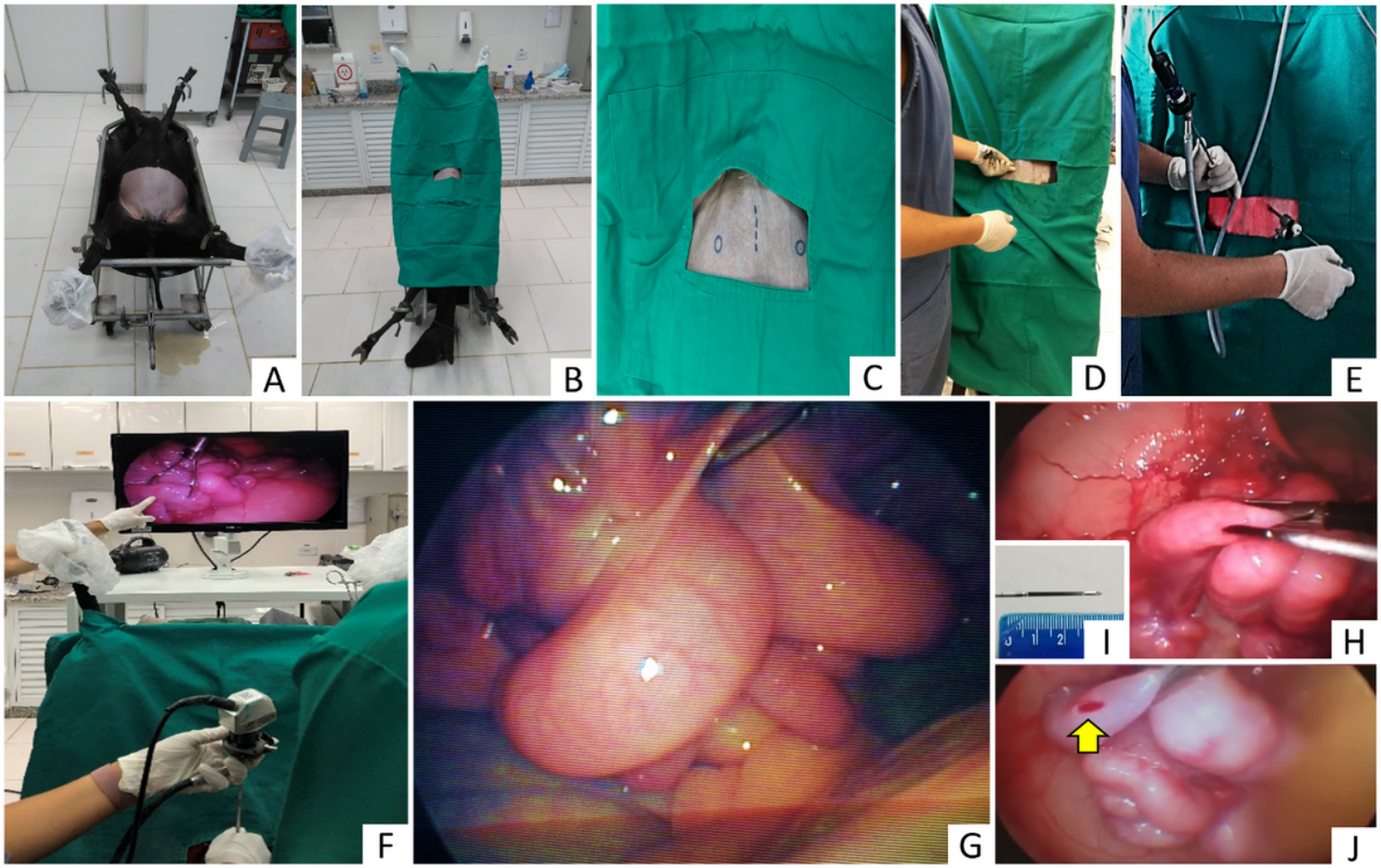

Figure 1

Description of videolaparoscopy technique for the collection of uterine fragments in sheep species. A. Preparation of the animal (after sedation) on an immobilization stretcher with trichotomy and antisepsis of the ventral abdomen. B. Positioning the animal on the stretcher to facilitate the location of the genital tract. C. Demonstration of the trocar introduction regions. D. Introduction of the first trocar, cavity insufflation with gas and entry of the optical equipment. E. Introduction of the second trocar and manipulator clamp entry. F. Location of the genital tract. G. Uterine fixation with forceps. H. Introduction and positioning of the needle for biopsy in the uterine horn. I. Detail of the collection needle with the fragment case. J. device withdrawal and wound visualization.