Oral Rehabilitation of Oncology Patients With Microvascular Free Flaps With a Follow-Up of 2 to 6 Years

Funda Goker
University of Milano
Alessandro Baj
University of Milano
Alessandro Remigio Bolzoni
University of Milano
Carlo Maiorana
University of Milano
Giada Beltramini
University of Milano
Aldo Bruno Gianni
University of Milano
Massimo Del Fabbro (massimo.delfabbro@unimi.it)
IRCCS Orthopedic Institute Galeazzi

Research Article

Keywords: Microvascular free flaps, dental implants, oral rehabilitation, oncologic patients, maxillofacial reconstructive surgery.

Posted Date: September 13th, 2021

DOI: https://doi.org/10.21203/rs.3.rs-811994/v1

Abstract

BACKGROUND: Reconstruction with free flaps after radical cancer surgery in terms of function and esthetics can be quite demanding. The aim of this study was to evaluate retrospectively oral rehabilitation with microvascular free flaps and dental implants for maxillofacial reconstruction in oncologic patients with a minimum follow-up of 2 years after implant insertions.

METHODS: The study consisted of 17 patients diagnosed with either squamous cell carcinoma, fusocellular carcinoma, or mucoepidermoid carcinoma. The reconstruction of the maxillofacial defects was done with microvascular free flaps (free fibular flap, antero-lateral thigh flap, or radial forearm flap). Implants were inserted on the average 30.2±15.5 months after reconstructive operations. A total of 74 implants were inserted. Mean follow up after maxillo-facial surgery was 6.16 years (mean 73.93±14.48 months). Mean follow up after implant insertions was 3.61 years (mean 43.50±12.96). Primary outcome was implant survival. Secondary outcome was evaluation of post-surgical complications.

RESULTS: There were surgical revisions in seven patients after reconstructive surgery with flaps, mainly due to tumor relapse. Complications were seen in 11 patients. 1 implant was lost in a female patient 15 months after placement. Overall implant survival rate was 97.5%. No relations were found between implant survival rate and gender, type of tumor, type of microvascular free flap, radiation therapy, chemotherapy, and prosthesis type.

CONCLUSION: According to the results of this study, oral rehabilitation with dental implants inserted in free flaps for maxillofacial reconstruction after ablative oncologic surgery can be considered as a safe treatment modality with successful outcomes.

Background

One of the main challenges of the maxillofacial reconstruction is the limited supply of well-suited local tissues, that are needed to approximate lost bone, muscle, nerves, skin, and mucosa. Since the late 1950s, the use of distant, regional and pedicled flaps has been a standard treatment method for maxillofacial reconstructions [1]. Currently, the reconstruction of large defects in the maxillofacial region with free autologous tissue transplants and microvascular anastomosis is accepted as the gold standard with well-established protocols [2–4].

During the last decades different distant donor sites have been utilized in literature for reconstruction of large maxillofacial defects by free tissue transfer, and re-anastomosis of vessels for large complex tissue grafts [4–6]. These composite free flaps can be harvested from the fibula, iliac crest, scapula, or radius, more recently, antero-lateral thigh flap (ALT) and the iliac crest bone flap using the deep circumflex iliac artery (DCIA) were introduced with successful results [7–20]. These options have permitted the surgeon to resect large tumors and to provide at least partly functional and aesthetic reconstruction and increase in the quality of life for the oncologic patient. Each flap has its unique features and no single kind of osseous or osteocutaneous flap is considered capable of resolving the wide variety of defects [9].

Since its first introduction by Hidalgo et al. in 1989, free fibula flap (FFF) has become a preferred graft for oromandibular reconstructions [9–10]. The FFF is the primary choice for reconstruction of a large variety of mandibular defects due to its ability to incorporate a reliable skin paddle with bone flap, consistency in size, vascular pedicle length, vessel diameter [11], and low donor site morbidity [9].

The long segment of bone, up to 25 cm in length, can tolerate multiple osteotomies without compromising its blood supply [12–13]. Reinnervation is also possible, using the lateral cutaneous sural nerve [14]. Another major advantage of FFF is the ability to use a two-team approach [13].

The antero-lateral thigh flap (ALT) is a soft tissue perforator free flap, which was first described by Song et al. in 1984 [15]. The length of the soft tissue pedicle ranges from 8 to 16 cm and it runs in the intermuscular septum between the rectus femoralis and vastus lateralis muscles with a motor nerve supply from vastus lateralis [16]. Generally, minimal donor site morbidity is associated with ALT flaps [16].

The radial forearm flap (RFF) was first reported by Yang et al. in 1981 [17]. The pedicle length in average ranges from10 to 12 cm with good vessel diameter of 2.5 mm [17–19]. The sensory nerves also can be harvested with the flap to provide sensory reinnervation to the tongue [18–19]. Soutar et al. in1983, reported ten cases of intraoral reconstruction using a radial forearm flap, including radial bone to replace segments of the mandible [20]. Limitations on the use of RFF are based on two main considerations: adequate blood supply to the donor site hand and the high rate of fracture in the radius after harvesting [9, 18]. Another problem is the bone thickness harvested from the radius, which is too small to endure stress in the mandible [9].

Oral rehabilitation with dental implants placed in autologous bone grafts in head and neck oncology patients was evaluated by various authors in literature with promising results [21–27]. Reconstruction of soft and hard tissues with the use of microvascularized free flaps might reestablish the aesthetics of the patient for the most part. However, due to the loss of alveolar tissues and teeth, the physiological function of the patient such as, chewing and speech can represent a major problem after oncological ablative surgery [21, 22]. Following surgical reconstruction for radical cancer surgery, patients can suffer from functional disabilities and esthetic deformity. The use of prostheses without dental implants may be compromised by changes in oral anatomy of the patients that underwent major oral and maxillofacial reconstructive surgery. The quality of life of the oral cancer patients can be dramatically improved by dental implant treatment, however there are still limited number of reports in literature to assess the outcomes [21–27].

The purpose of this retrospective study was to evaluate the outcomes and complications following reconstructive and implant surgery with microvascular free flaps. The study population consisted of oncology patients that had received microvascular free flaps and dental implants in the same unit with a minimum follow up of 2 years after implant insertions.

Methods

The study population consisted of oncology patients that had received microvascular free flaps and dental implants at Milano University in the department of Maxillofacial Surgery with a minimum follow up of 2 years after implant insertions. The inclusion criterion was oncologic patients who needed maxillofacial reconstruction and oral rehabilitation with dental implants after resection and reconstructive surgery, with or without adjunctive radiation therapy. The patients that had no implant inserted or had dental implant inserted in other clinics after reconstructive surgery were not included. No other specific exclusion criterion was set. Seventeen patients (8 Male, 9 Female) were included. Patients were treated between January 2013 and January 2020 in the IRCCS Ca' Granda Ospedale Maggiore Policlinico unit at the Department of Oral Science and Maxillofacial surgery, University of Milan. The mean age of the patients at the time of surgery was 63.29 years (Standard Deviation (SD) 14.65) ranging from 41 to 82 years.

The pre/post-operative and surgical protocol was described in detail in the previous publications by the same team of authors [28,29]. In brief, the first stage maxillofacial operation was performed simultaneously by two teams. This stage included resective surgery in the head and neck region and simultaneous microvascular reconstruction with distant microvascularized free flaps. Revision surgeries were applied whenever needed. Second stage implant placement surgeries were performed with a mean interval period between two surgeries as: 30.5±SD15.7 months (min 4.7 - max 67.1 months). None of the patients received immediate loading of the dental implants.

In cases of postoperative radiation therapy, 66 or 60 Gy was delivered in fractions of 2 Gy given daily for 5 days each week. In patients with irradiated grafted residual bone, a minimum interval of 12 months elapsed between irradiation and implant placement. In cases of chemotherapy, Cisplatin (CDDP 30mg/mEq) intra venous medication was administered when needed.

Outcomes

Implant survival was the primary outcome of the study. The complications following reconstructive and implant surgeries were assessed as secondary outcomes.

A complete clinical case is documented in Fig. 1 to 5.

Statistical analysis

GraphPad Prism 5.03 (GraphPad Software, Inc., La Jolla, CA, USA) was used for statistical analysis. $p=0.05$ was considered as the significance threshold.

Mean values and standard deviation (SD) data was used in calculations of descriptive statistics for quantitative variables normally distributed. The d'Agostino and Pearson omnibus test was used to evaluate normality of distributions. Both the patient and the implant were considered as the unit of analysis. The effect of each variable (gender, patients' condition, flap type, site, radiotherapy, chemotherapy, type of prosthesis, smoking habits) on implant survival was evaluated by using the Fisher's exact test given the low incidence of complications in each subgroup. In cases with more than two categories for a given variable, the generalized Fisher exact test was applied using the online free package SISA (Simple Interactive Statistical Analysis- http://www.quantitativeskills.com/sisa/).

Results

The study group consisted of 17 patients that received microvascular free flap maxillofacial reconstructions (8 free fibula flaps (FFF), 5 radial forearm flaps (RFF) and 4 anterolateral free flaps (ALT). A total of 74 dental implants were inserted (40 dental implants in free flaps and 34 in native bone). In the study population there were one fusocellular carcinoma (FC), one mucoepidermoid carcinoma (MEC), and 15 squamous cell carcinoma (SCC) patients.

Maxillofacial surgery resection sites (1 Maxillary, 16 Mandibular sites) and flap types:

- Mandibular trigone, soft palate, anterior tonsillar pillar (ALT)
- Right mandible from trigone till mental foramen, mandible right from 45 to 48 (ALT)

- Half-base of the tongue and oral floor (right) removal (ALT)
- Upper maxilla from 13 till pterygoid process (ALT)
- Oral floor and tongue right, bone baguette (RFF)
- Oral floor and tongue left, bone baguette (RFF)
- Mandibular trigone, cheek, bone baguette (RFF)
- Mandibula left and cheek mucosa (RFF)
- Oral floor and half tongue left (RFF)
- Mandible left from 41 till 35 (FFF)
- Mandible left and oral pelvis + tongue left (FFF)
- Left mandible (FFF)
- Mandibular trigone left (FFF)
- Right mandible body (FFF)
- Right mandible including angle (FFF)
- Right mandible (FFF)
- Left mandible from 33 till the angle (FFF)

Mean follow up after maxillofacial surgery was 6.16 years (mean 73.93 ± 14.48 months, range 49 to 97 months). Mean follow up- after implant insertions was 3.61 years (mean 43.50 ± 12.96, range 24 to 72.1 months). Implant survival rates and patient demographics such as, age, gender, oncologic condition, radiotherapy, chemotherapy, smoking, microvascular free flap type, implant site and type of prosthetic denture are listed on Table 1. All the patients received prosthesis (8 Toronto, 1 removable prosthesis, 3 fixed dental bridge restorations, and 5 temporary prosthesis).

Table 1
Patient demographics and implant survival

Patient	Characteristics	Failed patients/Total no of patients	Survival %	P value	Failed implants/Total no of Implants	Survival %	*p* value
Sex	Male	0/8	100	0.53	0/17	100	0.58
	Female	1/9	88.8		1/23	95.6	
Oncologic Condition	SCC	1/15	93.3	0.88	1/35	97.1	0.88
	FC	0/1	100		0/3	100	
	MEC	0/1	100		0/2	100	
Site	Mandible	1/16	93.8	0.94	1/38	97.4	0.95
	Maxilla	0/1	100		0/2	100	
Flap type	FFF	1/8	87.5	0.47	1/21	95.2	0.53
	RFF	0/5	100		0/10	100	
	ALT	0/4	100		0/9	100	
Type of prosthesis	Temporary	0/5	100	0.18	0/10	100	25
	Toronto	0/8	100		0/18	100	
	Removable	0/1	100		0/2	100	
	Bridge	1/3	66.6		1/10	90.0	
Smoking habits	1 smoker	0/1	100	0.94	0/1	100	0.98
	No smoker (9 ex-smokers)	1/16	93.7		1/39	97.4	
Age	=>65	1/12	91.7	0.71	1/27	96.2	0.68
	< 65	0/5	100		0/13	100	
Radiotherapy	yes	0/9	100	0.47	0/19	100	0.53
	no	1/8	87.5		1/21	95.2	
Chemotherapy	yes	0/3	100	0.82	0/6	100	0.85
	no	1/14	92.9		1/34	97.1	
Total		1/17	94.1		1/40	97.5	-

SCC = Squamous cell carcinoma, FC = Fuso-cellular carcinoma, MEC = Mucoepidermoid carcinoma, FFF = Free fibular flap, ALT = Antero-lateral thigh flap, RFF = Radial forearm flap

No relations were found between implant failure and gender, type of tumor, type of microvascular free flap, radiation therapy, chemotherapy, and prosthesis type. There was no correlation between any variable and success.

According to the results, overall implant survival rate was 97.5 %. There was one implant failure (inserted in FFF) in a female patient due to SCC relapse. As treatment, the implant was removed at a surgical revision appointment. There were no implant failures in native bone.

Four of the patients had additional health conditions as follows, 1 human papilloma virus, 1 breast cancer, 1 ovarian and uterus cancer, 1 colorectal polyp.

There were post-operative maxillofacial complications in eight patients. Two of these patients had additional complications after implant insertion operations, and one of these patients lost one implant because of SCC relapse in the same region.

Complications and treatments modalities are listed below:

Complications after ALT flaps

- SCC relapse in oral pelvis. Treatment: surgical removal
- Cutaneous fistula. Treatment: surgical revision.
- Osteoradionecrosis and pseudarthrosis at 8 months in the right mandible. Treatment: FFF right reconstruction after partial mandibulectomy
- Trismus. Treatment: scar debridement with forearm reconstruction

Complications after RFF flaps

- Cutaneous fistula. Treatment: pectoralis flap reconstruction
- Intraoral small dehiscence of sutures and spinal nerve suffering with paresthesia of hand's first finger. Treatment: controls, solved by the time

Following implant insertion: White lesion in posterior left tongue with biopsy that reveal hyperkeratosis. Treatment: Prosthetic adjustments and controls.

- Mandibular pseudarthrosis and osteoradionecrosis. Treatment: Reconstructive surgery with FFF. 11 months after reconstruction a tumor relapse located in left tongue and oral floor. SCC surgically removed and reconstructed with soft tissues from forearm flap.

Complications after FFF flaps

- Painful neuropathy of the lower face 3rd (left mandible). Treatment: Clinical follow up controls and pain therapy.
- Tumor relapse of SCC after 10 months in inferior right mandibular crest. Treatment: surgical revision and removal of 1 implant.
- Cutaneous fistula during osteodistraction. Treatment: Additional surgery with fistulectomy operation and removal of distractor during surgery.

Three of the patients had complications after delivery of dental prosthesis and in each case, prosthesis was adjusted without any additional problems.

Prosthetic complications

- Two patients had chipping of dental prosthetics. Treatment: Restoration of chipped teeth.
- One patient with oral mucositis. Treatment: prosthesis was removed temporarily for few months and healing abutment was repositioned.

Nine patients received radiotherapy and two of them developed osteoradionecrosis. Eight patients did not receive any radiation therapy. Detailed information about radiotherapy dose, modality and complications associated with radiotherapy for each patient are listed on Table 2.

Table 2
Radiotherapy and complications after radiotherapy

Patient number and radiotherapy	Complications
1-No	cutaneous fistula during osteodistraction SCC relapse 3 years after MX surgery
2-No	none
3- No	none
4-No	oral mucositis
5- No	SCC relapse 4 years after MX surgery
6-Yes (66Gy Total)	cutaneous fistula after 2 months and osteoradionecrosis after 10 months
7-Yes (66Gy Total; 59Gy N+; 54 Gy N-) ended in 20/03/2017	intraoral small dehiscence of sutures after one month, hyperkeratosis after 2 years
8-No	none
9-Yes 66Gy Total; barrage 2Gy (40 Gy surgical area; 36Gy high risk areas: N+; 34Gy low risk areas: N-)	none
10-Yes but interrupted because of mucositis	oral mucositis
11-No	neurophatic pain at the lower face 3rd left side SCC tumor relapse 4 years after MX surgery and one implant failure
12-Yes (66Gy T; 56Gy N)	cutaneous fistula after 2 months
13-Yes (60Gy)	none
14-No	none
15- Yes (60Gy Total)	mandibular pseudoarthrosis and osteoradionecrosis after 6 months SCC tumor relapse located in left tongue and oral floor after 4 years
16-Yes (66Gy surgical area; 59,4 Gy high risk areas; 51,6 Gy low risk areas)	Trismus after 2.5 years
17- Yes (66GY T; 56Gy N)	none
MX: Maxillofacial, SCC: Squamous cell carcinoma	

Discussion

Microvascular surgery currently represents one of the most preferred method for mandibular reconstruction. Whenever possible, immediate reconstruction at the time of segmental mandible resection provides the best functional and aesthetic result [6]. Although routine, these procedures are limited by the available suitable donor tissue size, shape, and function [6]. There are various flap options, and the quality of each type of bone and

accompanying soft tissue is different and no single kind of osseous or osteocutaneous flap can be considered capable of resolving the wide variety of mandibular defects. A suitable flap should be selected with caution according to the type of bone and soft-tissue defect and patient condition [9].

Oral rehabilitation with implant supported prosthesis after reconstruction of the lost tissues with microvascular flaps can improve the quality life of the patients significantly, in terms of speech, deglutition and aesthetics [22–27]. Oral rehabilitation success might decrease because of the insufficient retention and stability of the prosthesis. Survival rates of free flaps and subsequent implants were reported by various authors with promising results [22, 24–25, 28–31].

The bicortical bone of FFF has a perfect ability to accept oral implants with promising survival rates reported in literature [26]. In this study FFF was the most applied type of free flap (8 out of 17 patient) due to several advantages it offers, such as available bone length and thickness, low donor site morbidity. According to the results, there was one implant failure in a patient who received FFF for reconstruction. However, the reason of this failure was the recurrence of the tumor, and it was not related to the success of the FFF that was applied.

In our clinic, radial forearm flap (RFF) was selected when a soft tissue graft (with small amount of bone) is needed in regions such as, tongue, oral floor, cheek, and a smaller bone baguette. Main concern about RFF is that bone graft obtained is too small and weak to manage the stress of the mandible and fractures might occur more when compared to FFF. In this study, radial forearm flap (RFF) was the second most applied free flap (5 out of 17 patients). There were no implant failures, however there were post-operative complications in three patients. In two of the patients, additional reconstructive surgeries were performed with success. The other patient had minor prosthetic adjustments due to hyperkeratosis lesion and showed no additional complications.

According to the results of this study with ALT flaps, post-operative complications were seen in three patients with no implant failures. All these patients received additional surgical interventions (1 FFF, 1 RFF reconstruction and 1 surgical removal of SCC). In cases of larger soft tissue defects ALT flaps were chosen, since it offers many advantages as a soft tissue graft. ALT can be raised as fasciocutanous or myocutaneous and it can be custom designed to fit almost any tissue defect in the head and neck [32–33].

A great advantage of all these three grafts (FFF, ALT, RFF) is that the two-team surgery (one team performing resection of the tumor site, the other performing harvesting of the graft) can be easily performed simultaneously without the need for patient repositioning. In the present work, although there were complications associated with microvascular free flaps, none of these were related to success or failure of the procedure applied. As a rule, for a proper flap selection, the defect and patient health condition is considered first. The complications were mostly due to patient specific factors, mostly dependent on health condition of the patient.

There are opposing arguments in literature about the timing of radiotherapy and negative effect of radiotherapy on bone regeneration [26, 34–35]. According to the results of this present study there was no difference between irradiated and non- radiated patients in terms of implant failure, just one patient that received radiation therapy had an implant failure due to SCC relapse, not because of irradiation. However, 66.6% of the patients that had received radiation had complications such as osteoradionecrosis and cutaneous fistula, trismus, and mucositis. In non-radiated patients one cutaneous fistula was seen (one out of eight). Post-operative irradiation can have negative effects on bone healing in terms of incorporation of the graft and implants.

In this work, no prosthetic superstructure was found to be particularly favorable in terms of implant survival mostly due to the diverse individual variability regarding the location and dimension of the maxillofacial defect. All the patients had received temporary prostheses, and none of them had immediate loading of the implants. Decision for prosthesis type and time of delivery of the final prosthesis was dependent on many factors such as health condition of the patient and dimensions of the defects and the flaps. The major limitation of this study was the limited number of patients.

Conclusion

Oral rehabilitation with implant-supported prosthesis following maxillo-mandibular reconstruction with microvascularized free flap after ablative oncologic surgery can be considered as a safe procedure with promising survival rate and successful aesthetic and functional outcomes, which can dramatically increase the quality of life of such patients.

Abbreviations

FFF: Free fibula flaps

RFF:Radial forearm flaps

ALT: Anterolateral free flaps

DCIA: Iliac crest bone flap using the deep circumflex iliac artery

FC: Fusocellular carcinoma

MEC: Mucoepidermoid carcinoma

SCC: Squamous cell carcinoma

Declarations

The protocol of this study was approved by the Ethics Committee of Fondazione IRCCS Ca’ Granda Ospedale Maggiore Policlinico, Regione Lombardia with date 21/02/2017 (Ethics Committee of Milano Area B Act 478/2017). All patients were treated in agreement with the principles laid down in the Declaration of Helsinki on medical protocol and ethics. A signed informed consent form was obtained from all subjects for the medical and surgical procedure and for the use of data in the research.

Availability of Data

Data is available upon request.

Competing Interests

The authors declare no potential conflicts of interest with respect to the authorship and/or publication of this article.

Funding Statement

The authors received no specific funding for this work.

Author Contributions

F.G., and M.D.F. conceived and designed the analysis. Databases were searched and data was collected by F.G., and M.D.F. Maxillofacial surgical interventions were performed by A.R.B., A.B., G.B., and A.B.G. Oral implant rehabilitations were done by F.G., C.M. All the authors contributed on analysis and interpretation of data for the work. F.G. drafted the work and wrote the manuscript with input from all authors. M.D.F., F.G., G.B. and A.B.G. revised the work critically for intellectual content. Integrity of the work was appropriately investigated and resolved by all authors. All authors contributed and approved equally to the final version of the manuscript.

Acknowledgements

None

References

1. Ariyan S. The pectoralis major myocutaneous flap. A versatile flap for reconstruction in the head and neck. Plast Reconstr Surg 1979;63:73-81.
2. Wong CH, Wei FC. Microsurgical free flap in head and neck reconstruction. Head Neck 2010;32:1236-45.
3. Ferrari S, Copelli C, Bianchi B, Ferri A, Poli T, Ferri T, Sesenna E. Free flaps in elderly patients: outcomes and complications in head and neck reconstruction after oncological resection. J Craniomaxillofac Surg 2013;41:167-71
4. Kesting MR, Hölzle F, Wales C, Steinstraesser L, Wagenpfeil S, Mücke T, Rohleder NH, Wolff KD, Hasler RJ. Microsurgical reconstruction of the oral cavity with free flaps from the anterolateral thigh and the radial forearm: a comparison of perioperative data from161 cases. Ann Surg Oncol 2011;18:1988-94.
5. Kessler P, Poort L, Böckmann R, Lethaus B. Definition of quality indicators in microsurgery in head and neck reconstruction based on a 5-year follow-up without a loss. J Craniomaxillofac Surg 2013;41:2-6.
6. Disa JJ, Cordeiro PG. Mandible reconstruction with microvascular surgery. Semin Surg Oncol 2000;19:226-34.
7. Park CW, Miles BA. The expanding role of the anterolateral thigh free flap in head and neck reconstruction. Curr Opin Otolaryngol Head Neck Surg 2011;19:263-8.
8. Gerressen M, Pastaschek CI, Riediger D, Hilgers R-D, Hölzle F, Noroozi N, Ghassemi A. Microsurgical free flap reconstructions of head and neck region in 406 cases: A 13-year experience. J Oral Maxillofacial Surg 2013;71:628–35.
9. Takushima A, Harii K, Asato H, Momosawa A, Okazaki M, Nakatsuka T. Choice of osseous and osteocutaneous flaps for mandibular reconstruction. Int J Clin Oncol 2005;10:234–42.
10. Hidalgo DA. Fibula free flap: a new method of mandible reconstruction. Plast Reconstr Surg 1989;84:71–9.
11. Ward BB, Kang DR. Reconstructive surgery: Fibula. In: Kademani D, Tiwani P, editors. Atlas of oral & maxillofacial surgery. 1st ed. Missouri: Elsevier, 2016, p.1197-1211.

12. Wei FC, Seah CS, Tsai YC, Liu SJ, Tsai MS. Fibula osteoseptocutaneous flap for reconstruction of composite mandibular defects. Plast Reconstr Surg 1994;93:294-304; discussion 305-6.
13. Chim H, Saldago CJ, Mardini S, Chen H-C. Advances in Head and Neck Reconstruction, Part I. IN: Reconstruction of Mandibular Defects. Semin Plast Surg 2010;24:188–97.
14. Wong CH, Tan BK, Wei FC, Song C. Use of the soleus musculocutaneous perforator for skin paddle salvage of the fibula osteoseptocutaneous flap: anatomical study and clinical confirmation. Plast Reconstr Surg 2007;120:1576–84.
15. Song YG, Chen GZ, Song YL. The free thigh flap: a new free flap concept based on the septocutaneous artery. Br J Plast Surg 1984;37:149-59.
16. Barry C, Parmar S. Reconstructive surgery: Anterolateral thigh (ALT) free flap. In: Kademani D, Tiwani P, editors. Atlas of oral & maxillofacial surgery. 1st ed. Missouri: Elsevier, 2016, p.1238-46.
17. Yang G-F, Chen P-J, Gao Y-Z, Liu X-Y, Li J, Jiang S-X, He S-P. Forearm free skin flap transplantation: a report of 56 cases. Chinese Med Journal 1981; 61:139. In: Br J Plast Surg 1997;50:162-5.
18. Lubek JE. Reconstructive surgery: Radial forearm flap. In: Kademani D, Tiwani P, editors. Atlas of Oral & Maxillofacial Surgery. 1st ed. Missouri: Elsevier, 2016, p.1183-98.
19. Thoma A, Archibald S, Jackson S, Young JE. Surgical patterns of venous drainage of the free forearm flap in head and neck reconstruction. Plast Reconstr Surg 1994;93:54-9.
20. Soutar DS, Scheker LR, Tanner NS, Mc Gregor IA. The radial forearm flap: a versatile method for intra-oral reconstruction. Br J Plast Surg 1983;36:1–8.
21. Baccarani A, De Santis G. Mandible Reconstruction: A Review Article. J Surgery 2015;5:7.
22. Pellegrino G, Tarsitano A, Ferri A, Corinaldesi G, Bianchi A, Marchetti C. Long-term results of osseointegrated implant-based dental rehabilitation in oncology patients reconstructed with a fibula free flap. Clin Implant Dent Relat Res 2018; 20:852–9.
23. Okay DJ, Buchbinder D. Implant rehabilation and maxillomandibular free flap reconstruction. In: Kademani D, Tiwani P, editors. Atlas of oral & maxillofacial surgery. 1st ed. Missouri: Elsevier, 2016, p.219-31
24. Attia S, Wiltfang J, Pons-Kühnemann, J, Wilbrand J-F, Streckbein P, Kahling C, Howaldt HP, Schaaf H. Survival of dental implants placed in vascularised fibula free flaps after jaw reconstruction. J Cranio-Maxillo-Fac Surg2018;46:1205-10.
25. Attia S, Wiltfang J, Streckbein P, Wilbrand J-F, El Khassawna T, Mausbach K, Howaldt HP, Schaaf H. Functional and aesthetic treatment outcomes after immediate jaw reconstruction using a fibula flap and dental implants. J Cranio Maxillo-FacSurg 2019;47:786-91.
26. Awad ME, Altman A, Elrefai R, Shipman P, Looney S, Elsalanty M. The use of vascularized fibula flap in mandibular reconstruction. A comprehensive systematic review and meta-analysis of the observational studies. J Cranio-Maxillo-Fac Surg2019;47:629-41.
27. Urken ML, Buchbinder D, Costantino PD,Sinha U, Okay D, Biller HF. Oromandibular reconstruction using microvascular composite flaps: report of 210 cases. Arch Otolaryngol Head Neck Surg 1998;124:46-55.
28. Goker F, Baj A, Bolzoni AR, Maiorana C, Racco P, Taschieri S, Beretta P, Beltramini G, Gianni AB, Del Fabbro M. Effectiveness of dental implants placed into microvascular free flaps. Oral Dis 2020:26;1532-6. doi: 10.1111/odi.13451. Epub 2020 Jun 22. PMID: 32475068.

29. Goker F, Baj A, Bolzoni AR, Maiorana C, Giannì AB, Del Fabbro M. Dental implant-based oral rehabilitation in patients reconstructed with free fibula flaps: Clinical study with a follow-up 3 to 6 years. Clin Implant Dent Relat Res 2020:22;514-522. doi: 10.1111/cid.12928. Epub 2020 Jun 24. PMID: 32578936.
30. Allen RJ, Shenaq DS, Rosen EB, Patel SG, Ganly I, Boyle JO, Nelson JA, Evan Matros E. Immediate implantation in oncologic jaw reconstruction: Workflow optimiozation to decrease time to full dental rehabilitation. Plast Reconstr Surg Glob Open 2019;7:e2100.
31. Laverty DP, Kelly R, Addison O. Survival of dental implants placed in autogenous bone grafts and bone flaps in head and neck oncology patients: a systematic review. Int J Implant Dent, 2018;4:19.
32. Adler N, Dorafshar AH, Agarwal JP, Gottlieb LJ. Harvesting the lateral femoral circumflex chimera free flap: guidelines for elevation. Plast Reconstr Surg 2009;123:918-25.
33. Yu P, Youssef A. Efficacy of the handheld Doppler in preoperative identification of the cutaneous perforators in the anterolateral thigh flap. Plast Reconstr Surg 2006;118:928-33; discussion 934-5.
34. Pompa G, Saccucci M, Di Carlo G, Brauner E, Valentini V, Di Carlo S, Gentile T, Guarino G, Polimeni A. Survival of dental implants in patients with oral cancer treated by surgery and radiotherapy: a retrospective study. BMC Oral Health 2015;15:5.
35. Sammartino G, Marenzi G, Cioffi I. Implant therapy in irradiated patients. J Craniofac Surg 2011; 22: 443–5.

Figures

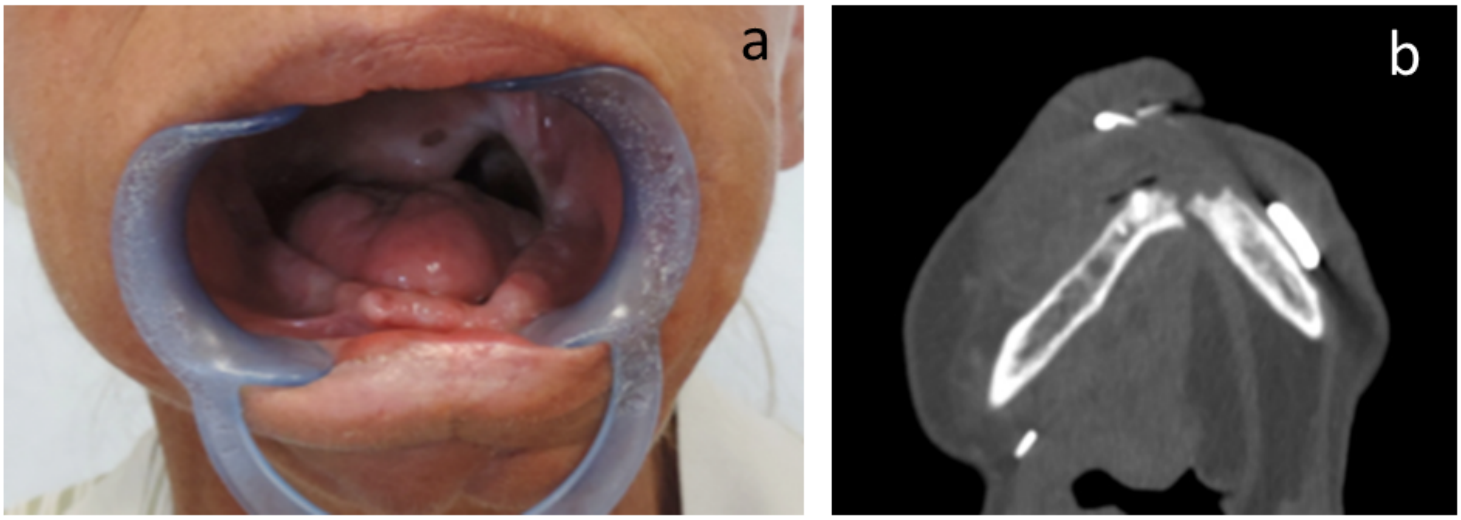

Figure 1

Representative preoperative images of a 59 y-old female patient with SCC. (1a) intraoral view and (1b) radiographic CBCT image.

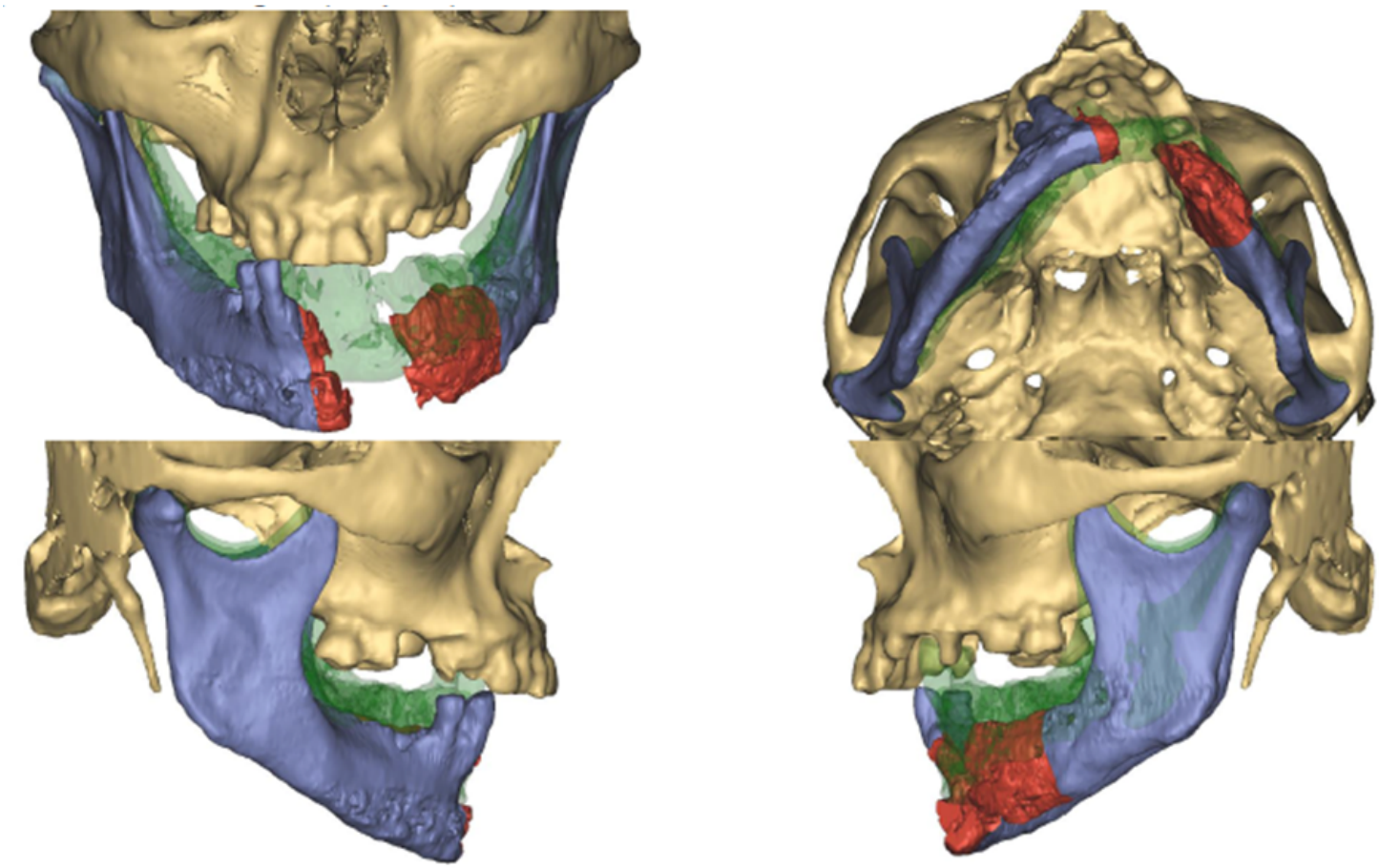

Figure 2

The preoperative 3-Dimensional (3D) CAD/CAM images of the patient showing the location of the mandibular defect.

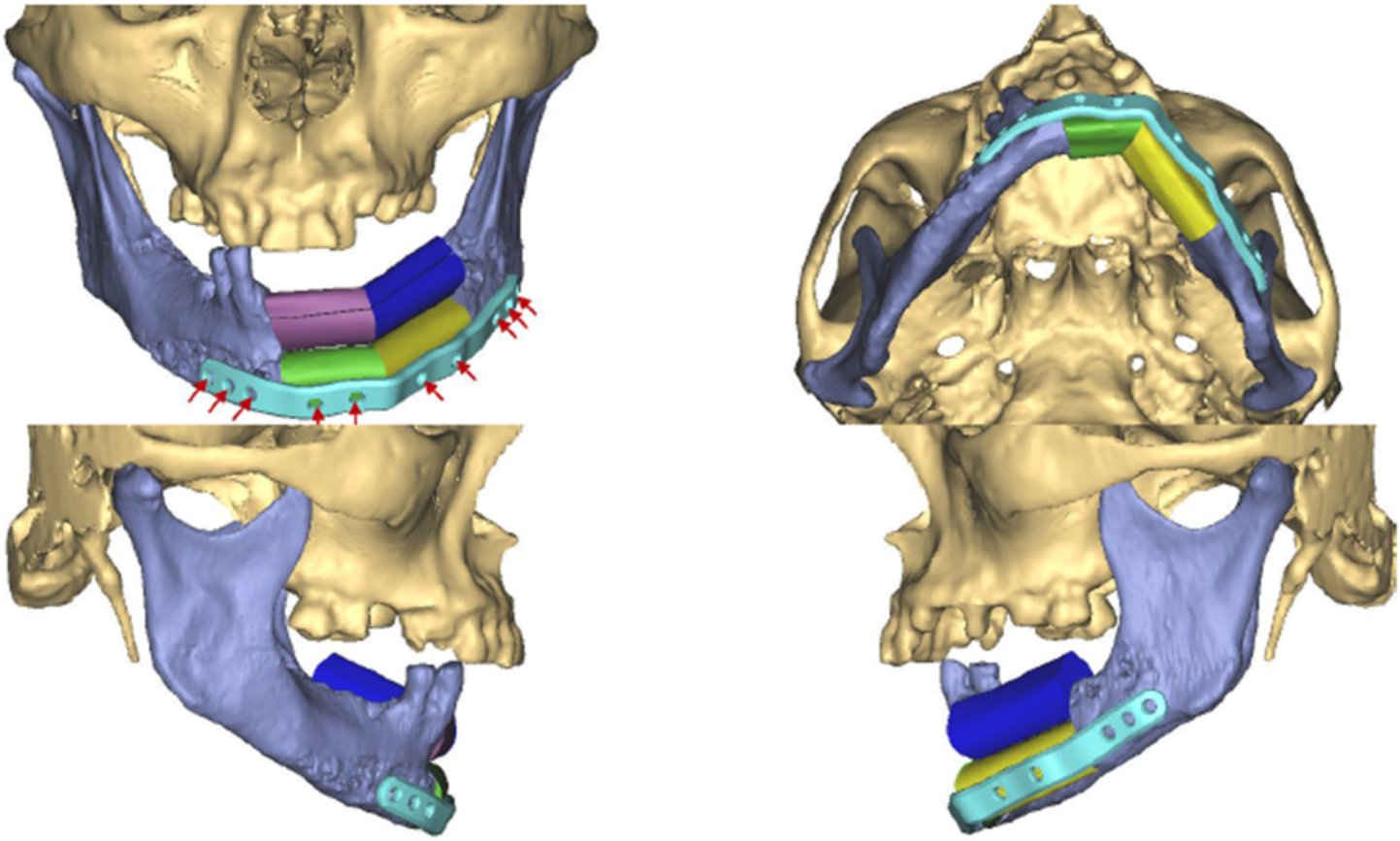

Figure 3

The preoperative 3D CAD/CAM surgical planning images of the patient, showing the planned positioning of the flap and fixation plate.

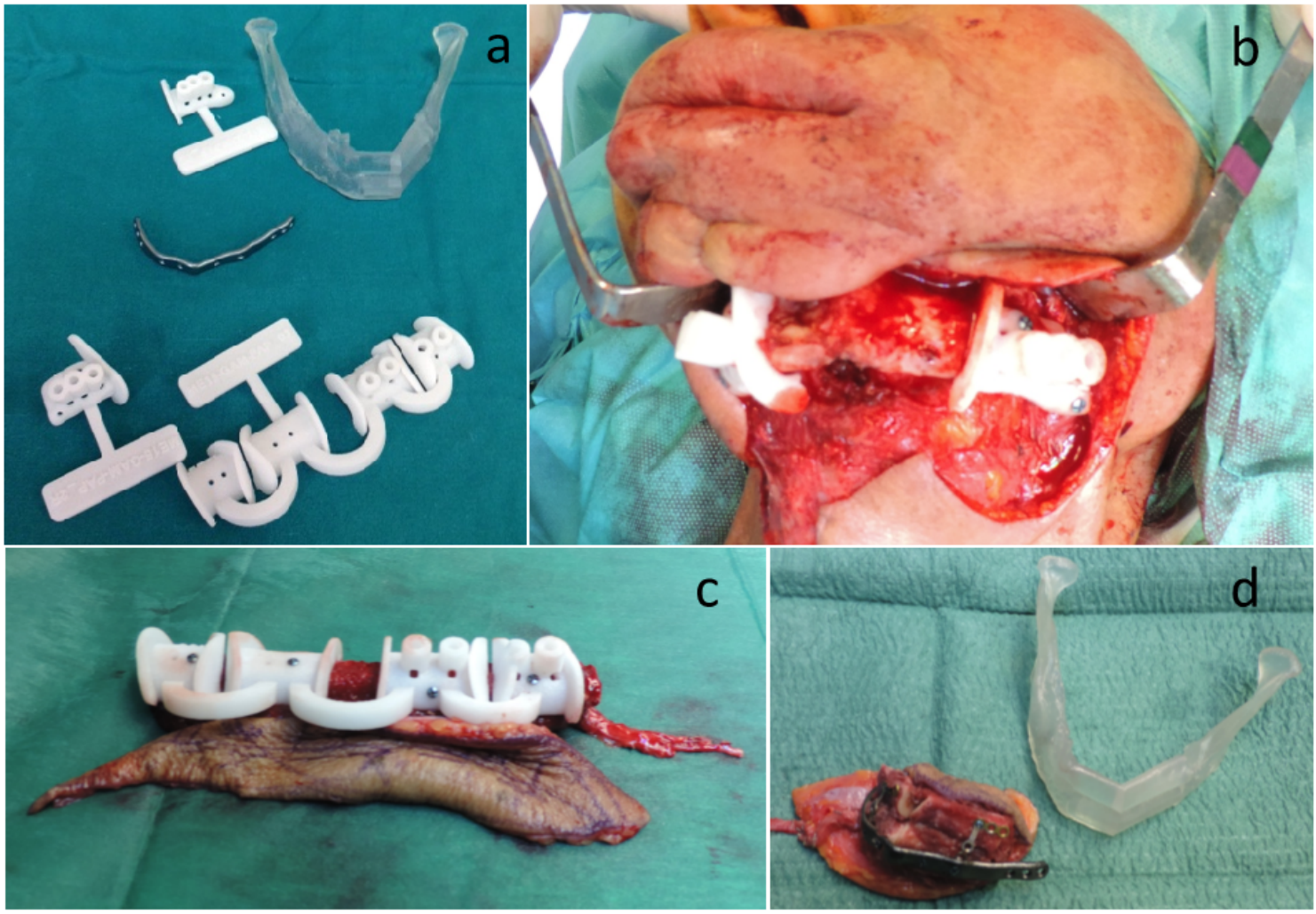

Figure 4

Intraoperative images (4a) Patient specific guides, reconstructive 3D titanium plate and 3D anatomical model of the mandible; (4b) patient with cutting guides for resection; (4c) custom made reconstruction guides with the harvested flap in position; (4d) 3D anatomical model and patient specific reconstructive 3D titanium plate with the harvested free fibular flap in position.

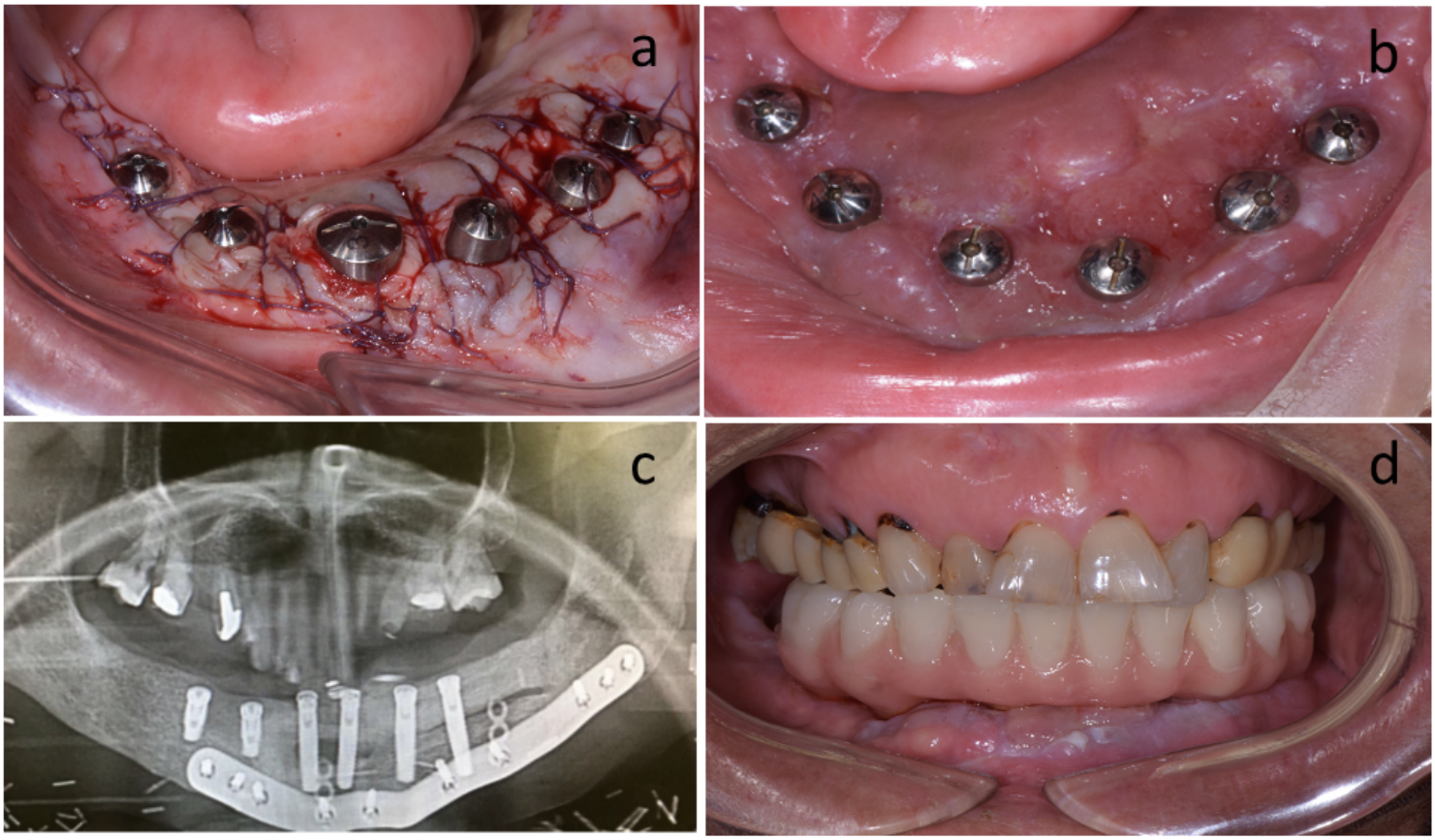

Figure 5

Images of the patient after implant surgery (24 months after reconstructive surgery with microvascular free fibular flap). (5a) postoperative intraoral image of the patient on the day of the insertion of the implants; (5b) intraoral image of the patient after suture removal, ten days after implant placement; (5c) panoramic x-ray of the patient at 6-month follow-up before prosthetic rehabilitation; (5d) intraoral view of the patient after the delivery of the prosthesis.