Treatment of Comminuted Proximal Humeral Fractures with Fibular Autografts

Binggang Wang
The second hospital of Tangshan https://orcid.org/0000-0002-8581-5342

Na Liu
The Second Hospital of Tangshan

Lifeng Zhang (zhanglifeng985@yeah.net)
The Second Hospital of Tangshan, Tangshan

Pengfei Guan
The Second Hospital fo Tangshan

Research article

Keywords: Proximal humerus comminuted fracture, Bone defect, Autogenous fibula segment, Structural bone grafting, Fibular autografts

Posted Date: August 30th, 2021

DOI: https://doi.org/10.21203/rs.3.rs-815863/v1

Abstract

Background: For severe proximal humerus comminuted fractures, which are often accompanied by a large number of fracture defects, there are many cavities left at the fracture end after reconstruction, which is one of the important factors leading to the failure of internal fixation. At present, the appropriate treatment of these proximal humerus comminuted fractures has not been identified. The purpose of this study used locking plates combined with fibular autografts was increased fixed strength for the treatment of severe comminution fractures of the proximal humerus with bone defects.

Methods: 10 cases of comminuted fracture of proximal humerus with bone defect were treated with open reduction and plate internal fixation combined with autologous fibular segment structural bone grafting. The postoperative follow-up was summarized and statistically analyzed by a paired sample t test.

Results: There was a total of 10 cases, including 7 cases that had full follow up data. The constant Murley score of the shoulder joint was 88.57±4.28 points at 12 months after the operation. The preoperative HSS score of the knee joint was 90.14±4.95 points. The HSS score of the knee at 12 months after the operation was 90.5±5.47 points. The preoperative HSS score and the postoperative 12-month score had P=0.088 (>0.05). The shoulder function score at 12 months was defined as excellent in 2 cases, good in 5 case, and 100% of the patients had excellent or good scores.

Conclusions: Locking plates combined with autogenous fibula segment transplantation may be an effective treatment for severe comminution fractures of the proximal humerus with bone defects.

Background

Proximal humeral fractures are the third most common fracture in the elderly with osteoporosis, accounting for approximately 26% of humeral fractures [1]. Proximal humeral fractures are prone to occur during high-energy trauma or low-speed injury in patients over 50 years old, such as simple falls [2]. For Neer III and IV fractures with severe comminution, most doctors give priority to open reduction and internal fixation. Most internal fixation materials are proximal humeral locking plates or proximal humeral intramedullary nails [3]. For severe comminuted fractures, which are often accompanied by a large number of fracture defects, there are many cavities left at the fracture end after reconstruction, which is one of the important factors leading to the failure of internal fixation. At present, the appropriate treatment of these comminuted fractures has not been identified [4].

Autogenous fibula is a bone graft source for the treatment of bone defects and which has the advantages of easy access, no immune rejection and considerable strength. Structural bone grafting with autogenous fibula for the treatment of severely comminuted proximal humeral fractures can reconstruct the medial support of the proximal humerus and increase the strength of fixation [5]. This study started in 2018, We took autogenous fibula segments for the treatment of severe comminuted proximal humeral fractures, and achieved satisfactory results.

Materials And Methods

1、 Inclusion criteria and exclusion criteria

Inclusive criteria: ① Severe comminution of the humeral head with several bone defects; ② Neer classification III, IV cases; ③ Fresh fracture; ④ A shoulder prosthesis replacement was not suitable.

Exclusion criteria: ① There were clear surgical contraindications, infection in the operation area or severe medical diseases; ② Shoulder joint disease; ③ The follow-up data were incomplete or the follow-up time was less than 1 year.

2、 General information

Clinical data: there was a total of 10 cases: 7 cases had complete followed up data, 6 cases had right proximal humerus fractures, 1 case had a left proximal humerus fracture, 6 cases were female, 1 case was male, 4 cases had hypertension, 1 case had diabetes, 2 cases had cerebral infarction, 1 case had osteoporosis. The mean of the patients was age 65.57 ± 11.13 years old. The cases were also classified according to the fracture: Neer fracture type ① 3 cases and type ② 4 cases. The mean height was 157.00 ± 6.83 m, and the mean body weight was 58.14 ± 12.77 kg. One case smoked, 5 cases had a walking injury, 1 case had a collision between an electric bicycle and a tricycle, and 1 case had trauma due to cycling. The mean HSS score of the knee joint before the operation was 90.14 ± 4.95 points. The mean intraoperative blood transfusion was 285.71 ± 219.31 ml, the mean intraoperative blood loss of the shoulder wound was 400.00 ± 294.39 ml, and the mean intraoperative leg wound bleeding was 32. 86 ± 13.80 ml. The mean length of the fibula was 7.00 ± 1.83 cm, the mean operation time was 2.86 ± 0.38 hours, and the mean follow-up time was 18.00 ± 3.65 months.

This study was approved by the ethics committee of the author's unit, and all patients signed the informed consent before the operation.

3、 Operation method

The operation technique of the comminuted fracture of proximal humerus: after successful general anesthesia, iodine and alcohol was used to disinfect the skin of the operation field, and the sterile operation sheet was placed. A deltoid and pectoralis major intramuscular approach was made along the injured shoulder, and the subcutaneous and fascia were dissected layer by layer. The cephalic vein was exposed and protected, the muscle space was entered, the proximal humerus was exposed, the intertubercular groove was found, which was used as the reduction mark, and the large and small nodules were found. The insertion points of supraspinatus and teres major of the large and small tubercles were sutured with "8" shape suture (Johnson, Vicki 1–0 suture), and the suture was reserved for traction reduction. The fracture end was cleaned, and the fibular segment was inserted into the humeral

medullary cavity. Then, the humeral head, large tuberosity and small tuberosity were reset and fixed temporarily with Kirschner wire. Under C-arm fluoroscopy, if the fracture reduction was good, then the proximal humerus was fixed with a locking titanium plate (Shandong Weigao proximal humerus locking plate). The large and small nodules were sutured to strengthen the fixation. The wound was thoroughly washed to stop the bleeding. The fracture reduction and internal fixation position were examined by radiography. After checking the gauze instruments, the wound was closed layer by layer.

The procedure of fibula removal: After successful general anesthesia, the air bag tourniquet of the ipsilateral lower limb was inflated at 50 kPa, the skin of the operation field was disinfected with iodine and alcohol, a sterile operation sheet was laid, a longitudinal incision was made at the middle and upper lateral sides of the ipsilateral leg, the skin and subcutaneous fascia were incised, and the fibula was exposed along the extensor flexor muscle space. At the same time, the superficial peroneal nerve was exposed and protected, a fibular segment was excised with a swing saw, the fibular segment was located in the middle and upper fibula, and the length of the fibular segment was approximately 7–8 cm. The tourniquet was slowly loosened, the wound was washed, the bleeding was thoroughly stopped, and the wound was sutured layer by layer (Fig. 1).

4 Postoperative management

Antibiotics were prophylactically administered 24–72 hours after the operation, the patient would sit up on the first day after the operation, and the patient would get out of bed within 3–7 days based on the functional rehabilitation needs of the combined operation site. The upper limb did not lift any weight for 8 weeks, passive pendulum movements were started within 6 weeks, active movement was started after 6 weeks, the patient received routine dressing changes, and the sutures were removed after 2 weeks.

5 Efficacy evaluation criteria

The patients were reexamined 1, 2, 3, 4, 5, 6 and 12 months after the operation, and the X-ray films were reexamined regularly. The operation time, intraoperative bleeding, postoperative pain score and fracture healing time of proximal humeral fractures were recorded. Shoulder function at 3 months, 6 months and 12 months after the operation was recorded by a constant Murley score. The shoulder range of motion at 3 months, 6 months and 12 months after the operation was recorded by a constant Murley score. The neck shaft angle of the proximal humerus and 12 months after the operation were measured and recorded. The HSS scores of the knee joint before the operation and 3 months, 6 months and 12 months after the operation were recorded.

6 Statistical analysis

SPSS 20.0 software was used to analyze the data, and the range of motion of the shoulder joint, constant Murley score of shoulder joint, humeral neck shaft angle during and after the operation, and HSS score of knee joint before and after operation were tested by a paired sample t test α= 0.05

Result

There was a total of 10 cases, including 7 cases that had full follow up data, and the shoulder wound pain score was 7.29 ± 1.11 points on the first day after the operation. The leg wound pain score was 5.71 ± 0.76 points on the first day after the operation. The fracture healing time was 2.57 ± 0.53 months. The constant Murley score of the shoulder joint was 77.00 ± 3.00 points at 3 months after the operation. The constant Murley score of the shoulder joint was 85.29 ± 5.07 points at 6 months after the operation. The constant Murley score of the shoulder joint was 88.57 ± 4.28 points at 12 months after the operation. The shoulder score at 3 and 6 months after the operation had P = 0.003 (< 0.05), and the shoulder score at 6 and 12 months after the operation had P = 0.214 (> 0.05). The preoperative HSS score of the knee joint was 90.14 ± 4.95 points. The HSS score of the knee at 3 months after the operation was 91.43 ± 6.27 points. The HSS score of the knee at 6 months after the operation was 90.86 ± 5.73 points. The HSS score of the knee at 12 months after the operation was 90.57 ± 5.47 points. The preoperative HSS score and the postoperative 3-month score had P = 0.678 (> 0.05). The preoperative HSS score and the postoperative 6-month score had P = 0.807 (> 0.05), and the preoperative HSS score and the postoperative 12-month score had P = 0.088 (> 0.05). The shoulder abduction score was 7.71 ± 0.76 points at 3 months, 9.14 ± 1.07 points at 6 months and 9.71 ± 0.76 points at 12 months. The shoulder flexion score was 7.71 ± 0.76 points at 3 months, 9.14 ± 1.07 points at 6 months and 9.43 ± 0.98 points at 12 months. The shoulder external rotation score was 2.86 ± 1.07 points at 3 months, 4.86 ± 1.07 points at 6 months and 5.43 ± 0.96 points at 12 months. The shoulder rotation score was 2.57 ± 0.98 points at 3 months, 4.86 ± 1.57 points at 6 months and 5.71 ± 2.14 points at 12 months. The proximal humeral neck trunk angle recovered to 126.86 ± 7.88° during the operation, and the proximal humeral neck trunk angle at 1 year after the operation was recovered to 125.86 ± 7.86°, P = 0.816 (> 0.05). The shoulder abduction scores at 3 months and 6 months after the operation had P = 0.014 (< 0.05), and the shoulder abduction scores at 6 months and 12 months after the operation had P = 0.273 (> 0.05). The shoulder flexion scores at 3 months and 6 months after the operation had P = 0.015 (< 0.05), and the shoulder flexion scores at 6 months and 12 months after the operation had P = 0.611 (> 0.05). The shoulder external rotation scores at 3 months and 6 months after the operation had P = 0.004 (< 0.05), and the shoulder external rotation scores at 3 months and 6 months after the operation had P = 0.218 (> 0.05). The shoulder internal rotation scores at 3 months and 6 months after the operation had P = 0.007 (< 0.05), and the shoulder internal rotation scores at 6 months and 12 months after the operation had P = 0.410 (> 0.05). The shoulder function score at 3 months was defined as excellent in 0 cases, good in 1 case, fair in 6 case; 14.3% of patients had excellent or good scores. At 6 months, the shoulder function score was excellent in 2 cases, good in 4 cases and fair in 1 case, and 85.7% of patients had excellent and good scores. At twelve months: two cases were excellent, 5 cases were good, and 100% of the patients had excellent or good scores.

Classic case(Fig. 2Fig. 3Fig. 4)

Discussion

An excellent shoulder function score 12 months after the operation was noted in all 7 patients in this study who had complete follow up data. The activity and function of the shoulder joint were greatly improved within 6 months after the operation. The functional improvement was not obvious after half a year. There was no statistical significance between the neck shaft angle of the humerus and the neck shaft angle of the humerus 12 months after the operation. It showed that the reduction did not fail. The knee HSS score was not significantly different at 3 months, 6 months and 12 months, which indicated that the fibular segment had little influence on walking function and that it was a safe bone-grafting site.

The method of autogenous fibular bone grafting in this study can not only reduce the difficulty of operation but also can increase the medial support of the proximal end of the humerus, increase the fixed strength, insert the fibula into the medullary cavity, close the large, small nodule and humeral head to the fibula segment, simplify the operation, and be more conducive to the healing of the fracture and the recovery of postoperative function. The operation is simple, the fibular segment can make up the bone defect and support the humeral head, and the internal fixator is also combined with the fibular segment. The screw is fixed on the fibular segment. The fibular section is located in the medullary cavity, which can achieve the effect of intramedullary fixation and is equivalent to the combination of intramedullary fixation and extramedullary fixation, which greatly enhances the control of the screw, increases the fixation strength, and is very suitable for elderly patients with osteoporosis. It is also beneficial to early rehabilitation exercises after fracture repair, and avoids the loosening of screws and fracture displacement.

The following points should be noted when removing the section of fibula: the section of fibula generally needs to be 6–10 cm, it is necessary to make a good preoperative plan, it is important to estimate the width and length of medullary cavity, and the surgeon needs to design the length of fibula section because the section may not conducive to fracture reduction if it is too long or too short. Autogenous fibula does not develop rejection reactions, and compared with the ilium, it is long, strong, and has good support effect on the humeral head, which is equivalent to allogeneic fibula segments. There is no immune rejection, and the source is convenient. The removal of the section of fibula had no significant effect on walking.

Serious comminuted fractures, often accompanied by a large number of fracture defects, and a large cavity left behind after reconstruction is one of the important factors leading to the failure of internal fixation operations [6]. At present, the best treatment is still unknown. Although joint prosthesis replacement can treat severe comminuted fracture [7], due to the expensive price, some patients will reject it and shoulder prosthesis replacement can only be performed in some large hospitals. Some patients agree to have iliac bone grafts, which can promote fracture healing and fill some space, however, the amount of bone of such fractures is often too large, the iliac bone taken out does not fill the defect, and it

is difficult to support the defect. Therefore, some operators try to use the allogeneic fibula segment to implant bone, which can support and achieve satisfactory effects, however, fibular materials are limited, the cost is relatively expensive, there is rejection, and some hospitals cannot do these procedures. Compared with the allogeneic fibula segment, the source of the autogenous fibular segment is convenient and an easy operation, without increasing the excessive medical expenses, which can be accepted by most patients. The disadvantage of the autogenous fibula segment is that an additional incision is needed, which can increase the pain of the patients. It is not recommended to perform it in young patients. The indications for surgery are mainly severe comminuted proximal humeral fractures with a large number of bone defects. At present, the number of cases in this study is small, and further research is still needed.

As a source of bone grafts, autofibular bone is convenient and effective. Locking plates combined with autogenous fibula segment transplantation may be an effective treatment for severe comminution fractures of the proximal humerus with bone defects.

Declarations

Consent for publication

All authors have read and approved the final manuscript for publication.

Availability of data and materials

Applicable

Competing interests

The authors declare that they have no competing interest.

Funding

Not applicable

Authors’ contribution

Binggang Wang and Lifeng Zhang conceptualized and designed the study. Binggang Wang and Na Liu performed scoring systems and image analyses. Binggang Wang, Lifeng Zhang and Pengfei Guan did the operation.

Acknowledgements

The authors would like to thank the support of all members of Department NO.5 of Orthopaedic Surgery.

Authors' information

Department of Orthopaedic Surgery, The Second Hospital of Tangshan, Tangshan, China, 063000.

References

1. Yogesh C, Patel, Pranay R, Laddha. Study of proximal humerus fractures treated with proximal humerus interlocking system (Philos) plating. International Journal of Orthopaedics Sciences. 2019;5(2):935–41.
2. Baron JA, Barrett JA, Karagas MR. The epidemiology of peripheral fractures. Bone. 1996;18(3):209S-13S.
3. Harshavardhana V, Varma KMK, Kumar M. **AN**, **Samarth Arya**. Study on functional outcome of proximal humerus internal locking osteosynthesis system plating for displaced proximal humerus fractures: A prospective and retrospective study. International Journal of Orthopaedics Sciences. 2019; 5(2): 350–3.
4. Lenze U, Pohlig F, Knebel C, Lenze F, Harrasser N, Mühlhofer H, Toepfer A, Rechl H. R von Eisenhart-Rothe. Autologous fibula transplantation for reconstruction of bone defects. Orthopade. 2017;46(8):648–55.
5. Ryan W, Simovitch CP, Roche RB, Jones HD, Routman Y, Marczuk TW, Wright. Joseph D. Zuckerman. Effect of Tuberosity Healing on Clinical Outcomes in Elderly Patients Treated With a Reverse Shoulder Arthroplasty for 3- and 4-Part Proximal Humerus Fractures. J Orthop Trauma. 2019;33(2):e39–45.
6. Han Wei Z, Junqiang TW. Huang Qiang, **Wu**. Xinbao. Clinical effects of fibula allograft combined with locking compression plate in treatment of comminuted proximal humeral fractures in the elderly. J Clin Orthop Res. 2020;5(6):324–39.
7. Shen Shiyun L, Xiongfeng Wu, Meng W. **Dongliang**. Biomechnical stability of proximal humeral fracture fixated by a locking plate plus different fibular allografts. Chin J Orthop Trauma. 2019;21(5):427–31.
8. Joshua L, Hudgens J, Jang K, Aziz MJ, Best US. Three- and 4-part proximal humeral fracture fifixation with an intramedullary cage: 1-year clinical and radiographic outcomes. J Shoulder Elbow Surg. 2019;28(6S):131–7.
9. Kim Y-G, Park K-H, Kim J-W, Oh J-K, Yoon J-P, Kim H-J. **and Chang-Wug Oh**. Is minimally invasive plate osteosynthesis superior to open plating for fixation of two-part fracture of the proximal humerus? Journal of Orthopaedic Surgery (Hong Kong). 2019; 27(2): 1–6.

Figures

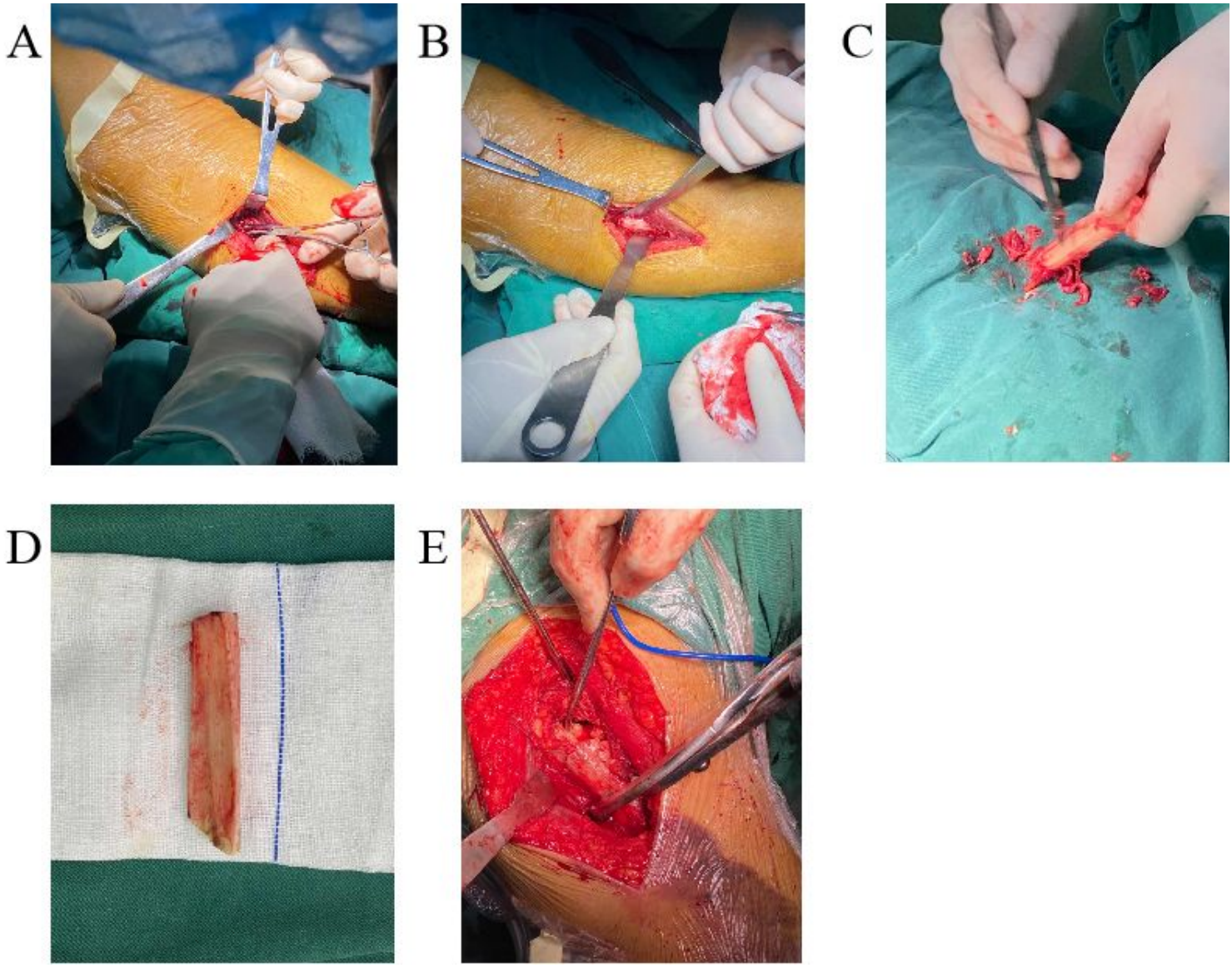

Figure 1

A: Cut the skin and prepare to take the fibula segment; B: The fibula segment has been intercepted; C: The remaining periosteum in fibula segment was cleaned up; D: Repaired fibula segment; E: The fibula segment is filled in the proximal humerus, and the vascular clamp refers to the fibula segment implanted in the medullary cavity.

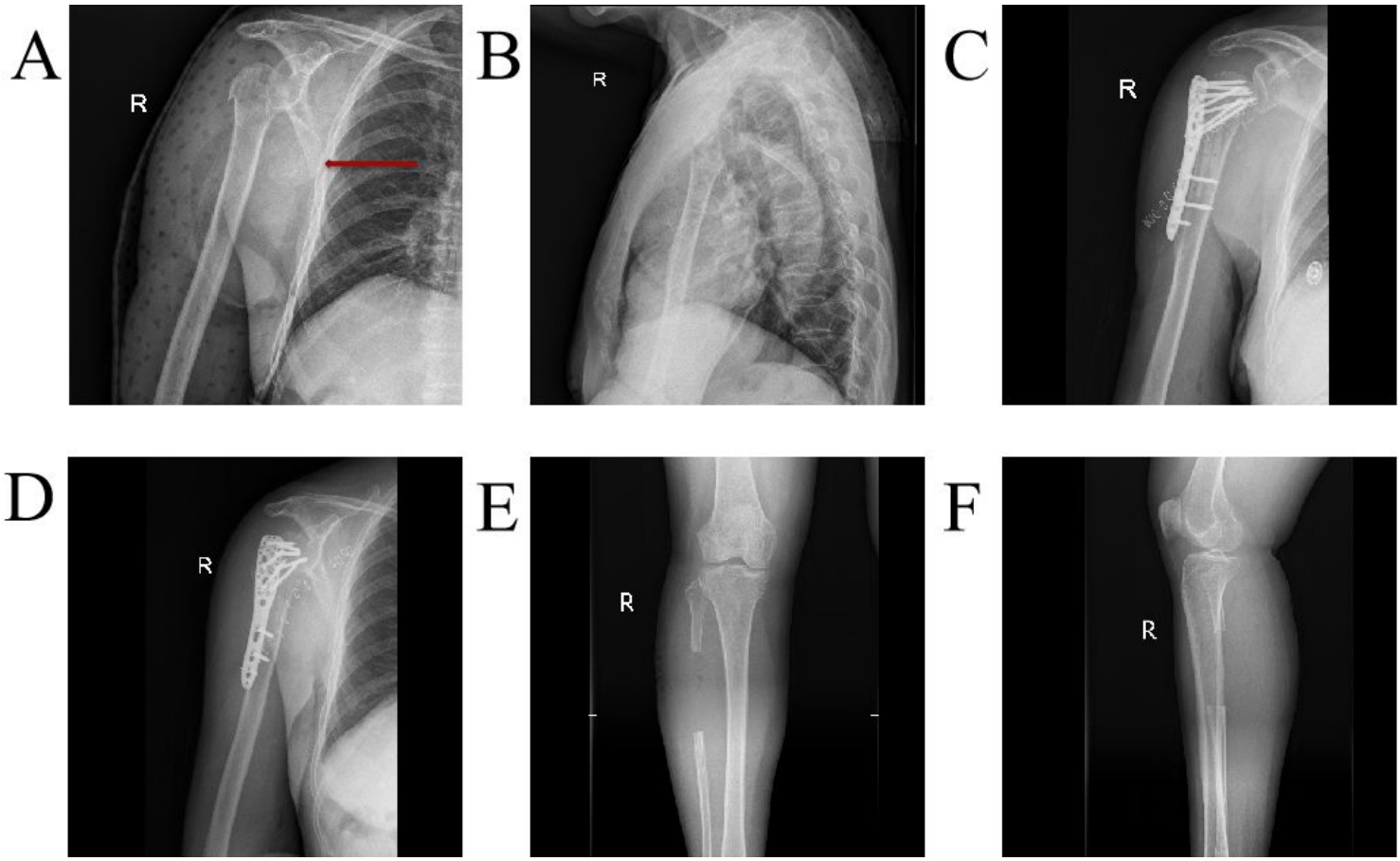

Figure 2

A, B: Anteroposterior and lateral X-ray picture of proximal humerus before operation (Red arrow refers to displaced humeral head); C, D: X-ray picture of proximal humerus in anteroposterior and lateral position after operation; E, F: Anteroposterior x-ray picture of tibia and fibula after fibula removal.

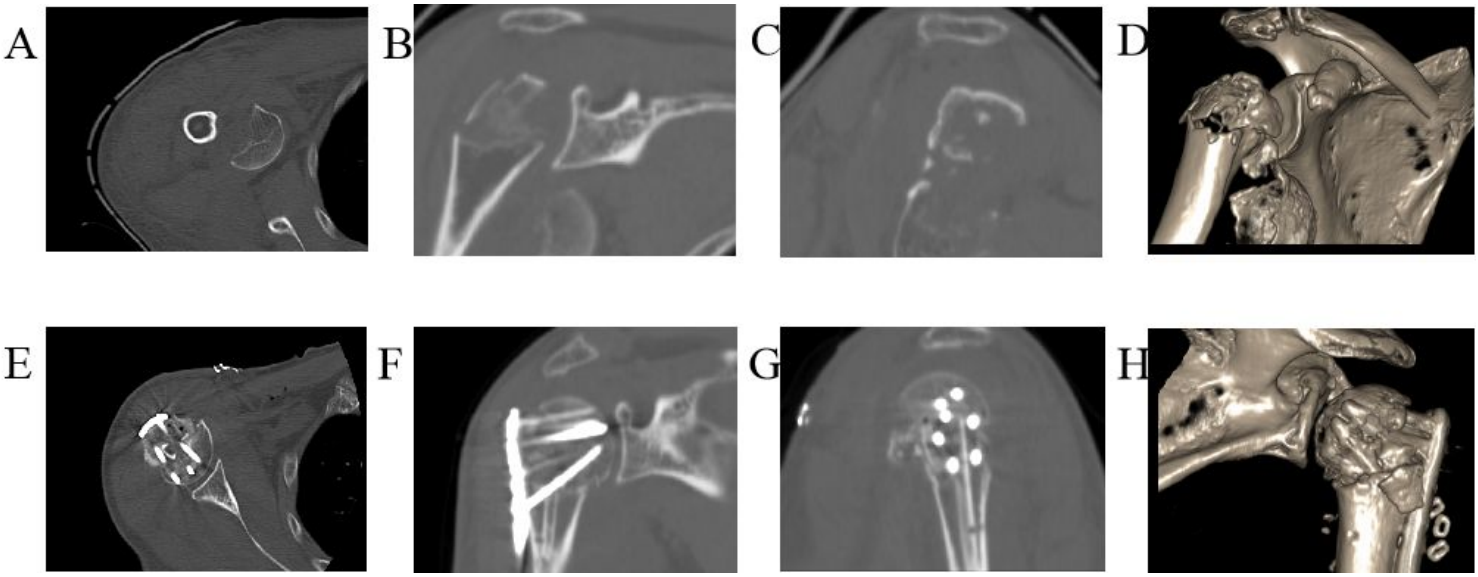

Figure 3

A: Preoperative CT image of the right proximal humerus in horizontal position; B: CT images of the right proximal humerus coronal position before operation; C: Preoperative sagittal CT images of the proximal right humerus; D: Preoperative three-dimensional reconstruction CT of proximal right humerus; E: Postoperative CT images of the right proximal humerus were taken; F: CT images of the right proximal humerus coronal position after operation; G: CT images of the right proximal humerus in sagittal position after operation; H: The right proximal humerus was reconstructed by three-dimensional CT.



Figure 4

A: Shoulder abduction and flexion 12 months after operation; B: Adduction and internal rotation of shoulder joint 12 months after operation; C: 12 months after operation, the patient's shoulder joint was extended and rotated; D: After 12 months of operation, the patient's shoulder joint extension picture.

Supplementary Files

This is a list of supplementary files associated with this preprint. Click to download.

- Tab.1.jpg
- Tab.2.jpg
- Tab.3.jpg
- Tab.4.jpg
- Tab.5.jpg