Research Square

Preprints are preliminary reports that have not undergone peer review. They should not be considered conclusive, used to inform clinical practice, or referenced by the media as validated information.

Retinal imaging study diagnoses a case of COVID-19

Jorge Ruiz-Medrano
Puerta de Hierro-Majadahonda University Hospital, Madrid, Spain.

José Manuel Ortiz-Egea (joemortiz@hotmail.com)
Department of Ophtalmology, Castilla La Mancha University, Albacete, Spain. https://orcid.org/0000-0002-8733-2328

José María Ruiz-Moreno
Puerta de Hierro-Majadahonda University Hospital, Madrid, Spain.

Case Report

Keywords: OCT, COVID-19, SARS-COV-2, Ophthalmology, Retina

Posted Date: September 24th, 2020

DOI: https://doi.org/10.21203/rs.3.rs-82692/v1

License: This work is licensed under a Creative Commons Attribution 4.0 International License. Read Full License

---

Version of Record: A version of this preprint was published at Journal of Medical Case Reports on September 24th, 2020. See the published version at https://doi.org/10.1186/s13256-020-02620-5.

Abstract

Background: Hyper-reflective lesions at the level of ganglion cell (GCL) and inner plexiform retinal layers (IPL) by Optical Coherence Tomography (OCT) and cotton wool spots in the examination of the eye fundus have recently been described as findings in patients with COVID-19 infection.

Case report: We report a case of a 42-year-old male anesthetist who treated COVID patients during the previous five weeks and suddenly debuted with a temporal relative scotoma in his left eye (OS); three weeks before, he presented with ageusia for several days. Best corrected visual acuity was 20/20 for OS; no discromatopsy or afferent pupillary defect were present. Visual field was performed, with no significant findings associated to the focal loss of sensitivity referred by the patient. The anterior segment was unremarkable on slit lamp examination in both eyes. Fundus examination of the left eye showed no significant findings. A placoid, hyperreflective band at the level of GCL and IPL was visible in the temporal and nasal side of the fovea on OCT which spared the outer retina, at the time of diagnosis and at one month. A propharyngeal swab test for SARS-CoV-2 RNA, IgG and IgM ELISA determinations were performed. Real-time reverse-transcriptase polymerase chain reaction (RT-PCR) was negative. ELISA testing and a third rapid antibody detection test performed 7 days after the onset of symptoms were positive.

Conclusions: Ocular signs and symptoms in COVID cases are rarely reported, but may be underestimated, especially those that affect the retina and occur in asymptomatic or paucisymptomatic cases. We present the first case of diagnosis of COVID-19 based on retinal ophthalmic examination.

Background

Coronavirus disease 2019 (COVID-19) is cause by Severe Acute Respiratory Syndrome-Coronavirus 2 (SARS-CoV-2). In humans, diseases of the coronavirus family range from mild common cold to more severe diseases such as Middle East respiratory syndrome (MERS) and SARS [1]. COVID-19 can cause pathological ophthalmologic involvement, initially associated only with conjunctivitis [2] with later descriptions of retinal aggression [3,4].

Case Presentation

We present the case of a 42-year-old male anesthetist who had been working with COVID patients during the previous five weeks prior to onset, who debuted with a sudden temporal relative scotoma in the left eye (OS); three weeks before, he suffered from ageusia for several days. Best corrected visual acuity was 20/20 for OS, while no discromatopsy or afferent pupillary defect were present. Visual field was performed, with no significant findings associated to a focal loss of sensitivity referred by the patient. The anterior segment and fundus examination were unremarkable in both eyes.

Swept Source optical coherence tomography (SS-OCT, Topcon Co., Tokyo, Japan) showed a hyper-reflective band at the level of ganglion cell and inner plexiform layers, which spared the outer retina (Figure 1a and b). Multimodal imaging showed neither hypo- nor hyper-autofluorescence in the area. Fluorescein angiography showed no areas of leakage or vascular exudation in early or late times.

The patient did not report respiratory symptoms, fever or any other clinical symptoms typically described in COVID-19 cases, but he suffered from ageusia for several days, three weeks prior to the ophthalmologic onset. The thoracic computerized tomography did not show lesions compatible with those described in COVID-19 cases with respiratory involvement.

After identifying the aforementioned retinal lesions and considering the patient's high-risk profession with regards to COVID-19 exposure, a pharyngeal swab test for SARS-CoV-2 RNA and ELISA determination of IgG and IgM were requested. Real-time reverse-transcriptase polymerase chain reaction (RT-PCR) was negative. ELISA testing and a third rapid antibody detection test performed 7 days after the onset of symptoms were positive. In the subsequent follow-up of the patient, 30 days after the start of the scotoma perception he continues to refer it. Retinal imaging study shows the same hyperreflective lesions observed in SS-OCT, with even greater intensity (Figure 2a and b).

Discussion And Conclusion

Back in 2013, Sarraf et al. were the first to describe the presence of multiple or isolated band-shaped, focal or diffuse hyper-reflective lesions visible at the level of the internal nuclear layer in patients who present with an acute onset of negative scotoma, and called it Paracentral Acute Medial Maculopathy (PAMM). PAMM is a spectral domain OCT (SD-OCT) finding interpreted as a possible more superficial variant of Acute Macular Neuroretinopathy [5].

Its etiology is unknown, although the most supported hypothesis is based on a vascular origin. A localized retinal capillary ischemia at the level of the intermediate plexus has been proposed as the underlying mechanism for the development of these lesions.

As Chen et al. describes, retinal vascular associations leading to retinal vasculopathy and PAMM include eye compression injuries causing global ocular ischemia, sickle cell crisis, Purtscher's retinopathy, inflammatory occlusive retinal vasculitis, post-H1N1 vac- cine, hypertensive retinopathy, migraine disorder, and post-upper respiratory infection [6].

Early clinical evidence suggests that cases of COVID-19 are frequently characterized by hyperinflammation, renin-angiotensin-aldosterone system imbalance, and a particular form of vasculopathy, thrombotic microangiopathy, and intravascular coagulopathy. In pauci-symptomatic or poorly clinical cases there are no conclusive studies [7].

To date, there is very limited evidence of the correlation between COVID-19 and the appearance of retinal lesions, presumably because there is a wide clinical variation in the presentation and severity of the

disease, that may induce the appearance of different mor- phological patterns of retinal involvement. Marinho et al [3], for instance, describe the presence of hyper-reflective lesions at the level of ganglion cell and inner plexiform layers more prominently at the papillomacular bundle, but we must be extremely careful with these findings because, as Vavvas DG et al [8] point out, OCT hyper-reflective bands in the inner retina and/or ganglion cell layer can confuse us with normal inner retinal vessels. Recently, Landecho [4] described a cotton wool spots in the examination of the eye fundus of the retina and, as corresponds in the B-scan optical coherence tomography, inflammation of the nerve fiber layer of the retina appears, in 6 of 24 asymptomatic subjects fourteen days after hospital discharge for bilateral COVID-19 pneumonia. For this reason, we consider the study with multimodal imaging to be important, agreeing with these authors that we must check at least the near infrared reflectance record to confirm that the hyper-reflective bands do not represent normal vessels (Figure 1 and 2).

Exclusively from an ophthalmological point of view and given the potential implica- tions, COVID-19 infection should be excluded using all means available in cases showing these hyper-reflective lesions at the level of ganglion cell and inner plexiform layers in OCT imaging, to facilitate a timely diagnosis and intervention. Vascular occlusions described in COVID-19 cases might as well be the cause for these retinal findings [7] or could possibly be associated with the neurological manifestations described in animal studies and in COVID-19 neurological events [9,10,11].

This case, and the papers presented by other authors [3,4,8] support a probable hypothesis that these retinal OCT findings should be considered another sign of COVID-19 disease and the importance of retinal imaging study in these patients. Furthermore, as far as we know, our case is the first case of COVID-19 diagnosed through an imaging study of the retina.

Abbreviations

- COVID-19: Coronavirus disease 2019 (COVID-19)
- GCL: Ganglion cell layer
- IPL: Inner plexiform retinal layer
- OCT: Optical Coherence Tomography.
- OS: Left eye.
- PAMM: Paracentral Acute Medial Maculopathy.
- RT-PCR: Real-time reverse-transcriptase polymerase chain reaction.
- SARS-COV-2: Severe Acute Respiratory Syndrome-Coronavirus 2.
- SS-OCT: Swept Source optical coherence tomography.

Declarations

- Ethics approval and consent to participate: Written informed consent was obtained from the patient for publication of this Case Report and any accompanying images. A copy of the written consent is available for review by the Editor of this journal.
- Consent for publication: Not applicable.
- Availability of data and materials: Not applicable.
- Competing interests: The authors declare that they have no competing interest.
- Funding: Not applicable.
- Authors' contributions: JRM and JMRM analyzed and interpreted the OCT images. JR and Ortiz-Egea JOE captures de images the OCT. JOE was a major contributor in writing the manuscript. All authors read and approved the final manuscript.
- Acknowledgements: We would like to thank a PhD Agustín Martínez Alcaraz, at Hospital Virgen de la Luz (Cuenca; Castilla La-Mancha).
- This patient has not been reported in any other submission by me or anyone else.

References

1. Cascella M, Rajnik M, Cuomo A, Dulebohn SC, Di Napoli R. Features, Evaluation and Treatment Coronavirus (COVID-19). In: *StatPearls*. Treasure Island (FL): StatPearls Publishing; 2020.
2. Wu P, Duan F, Luo C, Liu Q, Liang L, Wu K, et al. Characteristics of Ocular Findings of Patients With Coronavirus Disease 2019 (COVID-19) in Hubei Province, China. *JAMA Ophthalmol*. 2020;138(5):575-578.
3. Marinho PM, Marcos AAA, Romano AC, Nascimento H, Belfort R Jr. Retinal findings in patients with COVID-19. *Lancet*. 2020;395(10237):1610.
4. Landecho MF, Yuste JR, Gándara E, et al. COVID-19 retinal microangiopathy as an in vivo biomarker of systemic vascular disease? [published online ahead of print, 2020 Jul 30]. *J Intern Med*. 2020;10.1111/joim.13156. doi:10.1111/joim.13156
5. Tsui I, Sarraf D. Paracentral acute middle maculopathy and acute macular neuroretinopathy. *Ophthalmic Surg Lasers Imaging Retina*. 2013;44(6 Suppl):S33-S35.
6. Chen X, Rahimy E, Sergott RC, Nunes RP, Souza EC, Choudhry N, et al. Spectrum of Retinal Vascular Diseases Associated With Paracentral Acute Middle Maculopathy. *Am J Ophthalmol*. 2015;160(1):26-34.
7. Henry BM, Vikse J, Benoit S, Favaloro EJ, Lippi G. Hyperinflammation and derangement of renin-angiotensin-aldosterone system in COVID-19: A novel hypothesis for clinically suspected

hypercoagulopathy and microvascular immunothrombosis. *Clin Chim Acta*. 2020;507:167-173.

8. Vavvas DG, Sarraf D, Sadda SR, Eliott D, Ehlers JP, Waheed NK et al. Concerns about the interpretation of OCT and fundus findings in COVID-19 patients in recent Lancet publication [published online ahead of print, 2020 Jul 9]. Eye (Lond). 2020;1-2. doi:10.1038/s41433-020-1084-98.
9. Wang Y, Detrick B, Yu ZX, Zhang J, Chesky L, Hooks JJ. The role of apoptosis within the retina of coronavirus-infected mice. Invest Ophthalmol Vis Sci. 2000;41(10):3011-3018.
10. Moriguchi T, Harii N, Goto J, Harada D, Sugawara H, Takamino J, et al. A first case of meningitis/encephalitis associated with SARS-Coronavirus-2. Int J Infect Dis. 2020;94:55-58.
11. Hernández-Fernández F, Valencia HS, Barbella-Aponte RA, Collado-Jiménez R, Ayo-Martín O, Barrena C, et al. Cerebrovascular disease in patients with COVID-19: neuroimaging, histological and clinical description [published online ahead of print, 2020 Jul 9]. Brain. 2020;awaa239. doi:10.1093/brain/awaa239

Figures

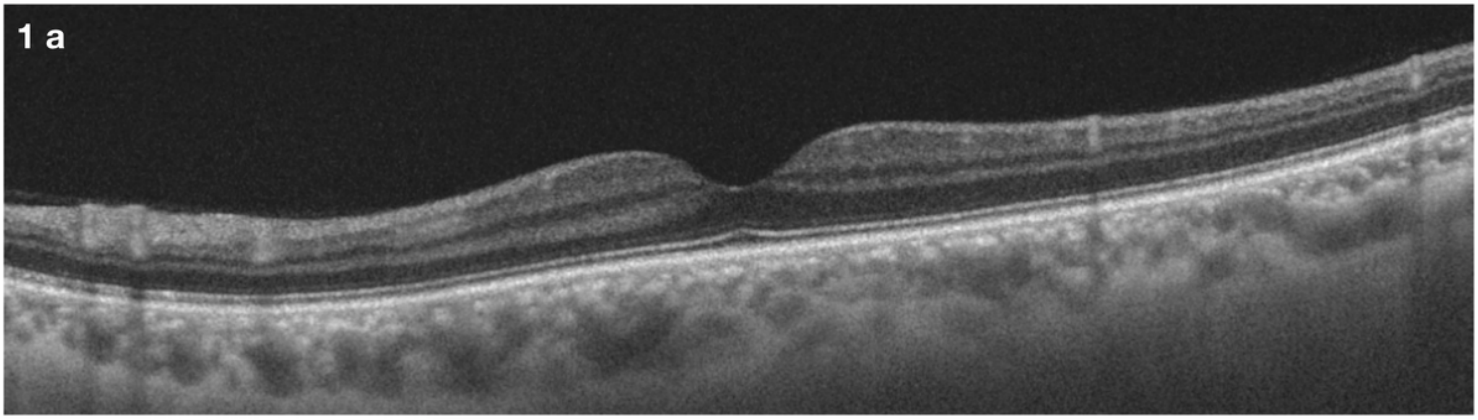

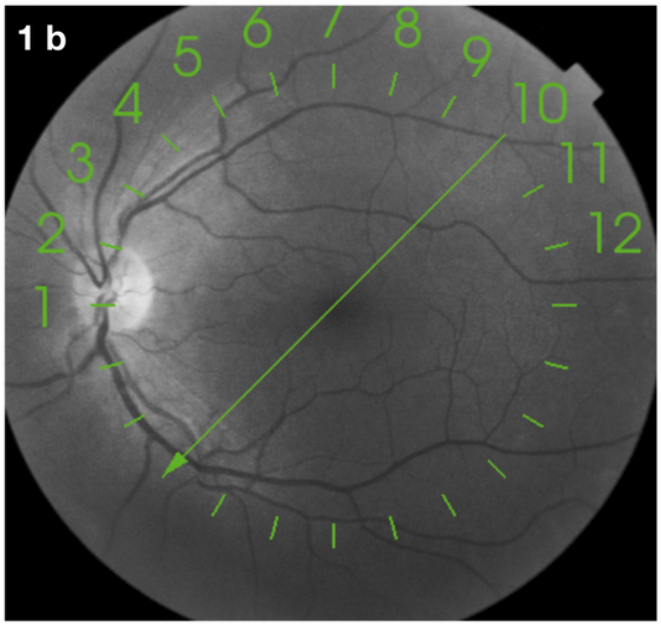

Figure 1

a and b: Swept Source optical coherence tomography (SS-OCT, Topcon Co., Tokyo, Japan) showed a hyperreflective band at the level of ganglion cell and inner plexiform retinal layers, which spared the outer retina. Green line where the B-scan of the OCT was acquired superimposed automatically by the acquisition instrument on an “en face” infrared fundus image.

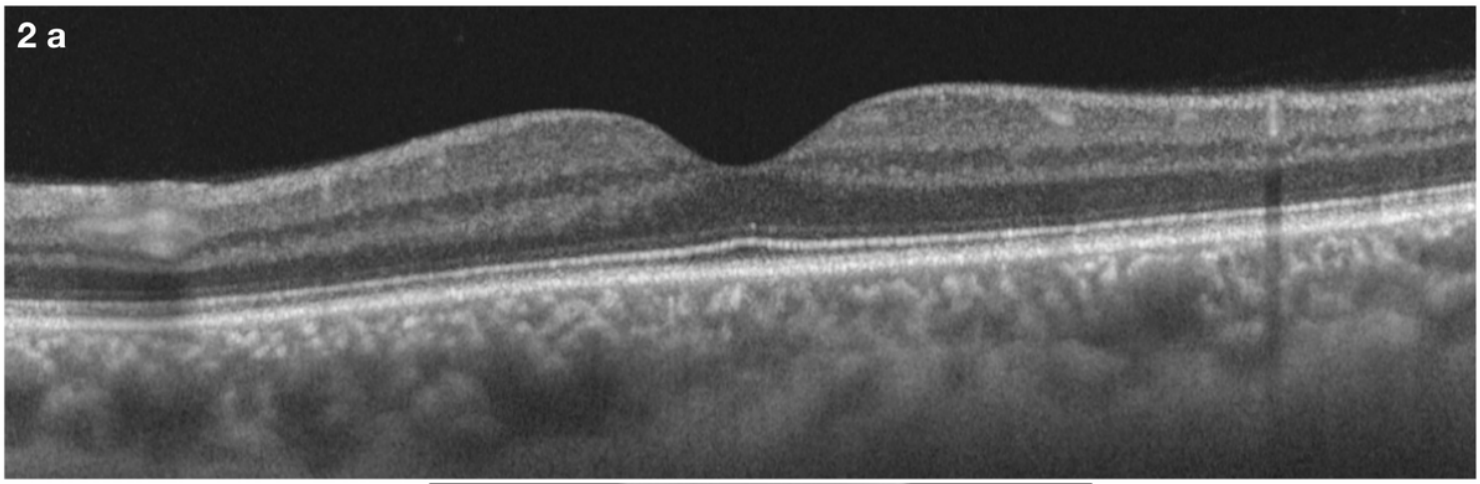

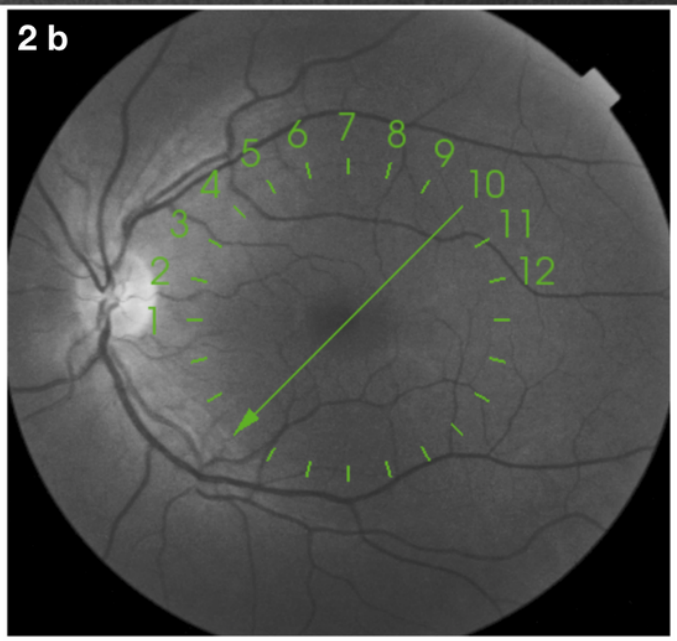

Figure 2

a and b: One month later, Swept-Source Optical Coherence Tomography shows a more prominent hyperreflective band at the level of ganglion cell and inner plexiform retinal layers. An “en face” infrared fundus image with green line where the B-scan of the OCT was acquired superimposed automatically by the acquisition instrument on.