Surgery for Uterine Preservation in Placenta Accreta Spectrum: A Retrospective Cohort Study

Yi-Lei Li
Shandong Provincial Hospital, Affiliated to Shandong First Medical University

Tao Li
Shandong Provincial Hospital, Affiliated to Shandong First Medical University

Wen Peng
Shandong Provincial Hospital, Affiliated to Shandong First Medical University

Xiang-Bin Liu
Maternal and Child Health Care of Shandong Province

Hong-Mei Wang (whmeisd@163.com)
Shandong Provincial Hospital, Affiliated to Shandong First Medical University

---

Research Article

Keywords: cesarean section, hysterectomy, placenta, placenta accreta, placenta previa.

Posted Date: September 13th, 2021

DOI: https://doi.org/10.21203/rs.3.rs-827630/v1

Abstract

Background: Owing to high risks of maternal morbidity, surgical complications, and loss of fertility, including psychological trauma caused by cesarean hysterectomy, innovative approaches for uterine preservation have been investigated. This study aimed to determine the efficacy of a novel eight-step surgical protocol for uterine preservation in placenta accreta spectrum (PAS) overlying the previous cesarean scar.

Methods: We retrospectively studied consecutive patients with PAS overlying the cesarean scar, who were treated between December 2015 and October 2019 using the protocol. The depth and extension of placental invasion and severity of pelvic adhesion were assessed intraoperatively. Information regarding the gestational week at surgery, surgery duration, estimated blood loss (EBL), bladder injury, and post-procedural recovery was retrieved from the hospital database. Multiple linear regression was used to analyze factors influencing surgical blood loss. EBL was compared between the perioperative aortic balloon and non-balloon groups in severe cases using t-tests.

Results: Overall, 115 patients with PAS were included. The mean EBL and surgery duration were 1666.1±1379.0 mL and 2.2±0.8 h, respectively. The uterus was successfully preserved in all patients with one surgery. Incidences of placenta accreta, increta, and percreta were 40 (35.8%), 46 (40.0%), and 29 (25.2%) cases, respectively. Extensive placental invasion and cervical involvement were observed in 41.7% and 28.7% of patients, respectively. EBL was significantly correlated with the extent of placental invasion, cervical involvement, and pelvic adhesion. No difference was seen in EBL between the balloon and non-balloon groups among the 44 patients with severe PAS.

Conclusion: The eight-step protocol is effective for uterine preservation in PAS overlying the cesarean scar. EBL is affected by the extent of placental invasion, cervical involvement, and severity of pelvic adhesion. Perioperative aortic balloon should be used conservatively.

Background

Placenta accreta spectrum (PAS) comprises abnormally invasive placental conditions including placenta accreta, increta, and percreta, when there is abnormal trophoblastic invasion through the endometrial decidua, through the myometrium, or beyond the uterine serosa, respectively.[1,2] The most favored hypothesis regarding the etiology of PAS is the failure of normal decidualization in the area of a uterine scar, which usually occurs in placenta previa after previous cesarean deliveries.[3] Pernicious placenta previa (PPP), first reported by Chattopadhyay in 1993, was used to describe the conditions of the placenta overlying previous cesarean scars, with or without accreta.[4] The incidence of PAS increases with the number of previous cesarean deliveries.[5] With the increasing rates of cesarean section (CS), the incidence of PAS has increased from 1 in 4,000 deliveries in the 1970s to approximately 1 in 500 recently.[6,7]

PAS carries the risk of life-threatening hemorrhage, which may result in massive blood transfusion, coagulopathy, hysterectomy, reoperation, and even maternal death.[8–10] The optimal surgical management strategy for PAS remains uncertain. Elective cesarean hysterectomy without disrupting the placenta has generally been the most accepted approach.[6,11,12] A cesarean delivery with the placenta left *in situ*, followed by a delayed hysterectomy, has also been investigated to decrease blood loss.[8,13] However, this approach requires two major surgeries, and the delay poses a risk of bleeding or infection that may require emergency surgery.[2,14] Due to the high risks of maternal morbidity, surgical complications, and loss of fertility, including the accompanying psychological trauma caused by cesarean hysterectomy, innovative approaches have been investigated for uterine preservation.

We developed a novel eight-step surgical protocol and have used it in surgery for patients with PAS for several years. In this study, we aimed to determine the efficacy of this protocol for uterine preservation in PAS overlying the previous cesarean scar and investigate the factors influencing the estimated blood loss (EBL) during the procedure.

Methods

We retrospectively investigated data of all consecutive patients diagnosed with PAS overlying the cesarean scar and treated in accordance with the eight-step protocol between December 2015 and October 2019 in our hospital. Information regarding history of CS, gestational week at surgery, surgery duration, EBL, bladder injury, and post-procedural recovery was retrieved from the hospital database. The inclusion criteria were as follows: one or more previous CS, placenta previa overlying the previous cesarean scar, and PAS confirmed by intraoperative examination. Those with spontaneous placental abruption were excluded.

Perioperative sonography was performed to determine the location and invasion of the placenta and the length and shape of the cervix. Cervical involvement was determined when the placenta covered the internal cervical orifice and blood flow could be detected inside the shortened cervical canal (length, <2 cm).[15] Cases with two or more of the following signs were considered to be severe: patients who had two or more previous CS, cervical involvement, complete placenta previa, placental lacunae and turbulence, loss of myometrial interface with a width >3 cm, bladder wall interruption, or uterovesical hypervascularity, and a preoperative aortic balloon was recommended.

The depth and extent of placental invasion and severity of pelvic adhesion were determined intraoperatively and reassessed according to the International Federation of Gynecology and Obstetrics classification for the clinical diagnosis of PAS disorders.[16] Placenta accreta was diagnosed when manual removal of the placenta was required. Placenta increta was diagnosed when part of the placenta was cut with scissors, and the remaining part of the uterine wall was thinner than the adjacent parts. Placenta percreta was diagnosed when the placental tissue had penetrated through the serosa of the uterus with hypervascularity, or a clear surgical plane could not be identified between the bladder and uterus. The extent of placental invasion was graded based on the involved area as: grade 1, no invasion; grade 2, estimated extension <1/6 of the placenta; grade 3, estimated extension 1/6–1/3 of the placenta; and grade 4 or extensive invasion, estimated extension >1/3 of the placenta. The location of the placenta was classified as mainly anterior, mainly posterior, or central. EBL was evaluated by recording the volume of blood in the vacuum pump and calculating the difference in the weight of the gauze and surgical drape pre- and postoperatively, with each extra gram of weight being estimated as approximately 1 mL of blood. Severe pelvic adhesion was determined when the border of the uterus was unclear and required elaborate dissection to be separated from the surrounding organs.

Data were analyzed using SPSS version 25.0 (IBM Corp., Armonk, NY, USA). Continuous variables are presented as means and standard deviations, whereas categorical variables are expressed as absolute numbers and percentages. Several variables including maternal age, number of previous CS, gestational week at surgery, emergency surgery, preoperative aortic balloon, depth and extent of placental invasion, main location of the placenta, pelvic adhesion, and cervical involvement, were studied using the Spearman correlation analysis to determine the factors correlated with EBL and were further evaluated with a multiple linear regression analysis to determine their independence in relation to EBL. An independent t-test was used to compare the EBL in severe cases from the balloon and non-balloon groups. Differences were considered significant when p values were <0.05.

Elective CS was planned after 34–37 weeks of gestation or after necessary preparations when the patient was transferred from a local hospital after 37 weeks. Before surgery, the hemoglobin levels were increased to >100 g/L

by blood transfusion. The possibility of intractable blood loss and hysterectomy were discussed with the family, and written consent was obtained. Combined lumbar anesthesia was performed in patients without any risk factors, based on the preoperative sonography, and general anesthesia was performed in the others. The study complied with the Declaration of Helsinki, and all human subjects provided written informed consent with guarantees of confidentiality.

The incision was made on the previous CS scar to avoid a cruciate incision unless the original transverse incision was very low. An incision sleeve was used for better exposure of the surgical field in both transverse and longitudinal incisions. The following eight-step procedure was then performed:

1. Open the uterovesical serosa and try to separate the bladder from the lower uterine segment. If the procedure is difficult owing to severe adhesion and bleeding, this procedure can be performed post-delivery.
2. Cut the uterine wall while avoiding the placenta, if possible. Otherwise, decisively cut the placenta by hand to deliver the baby as soon as possible. Exteriorize the uterus from the pelvic cavity and grasp the lower uterine segment with one hand to block bleeding. Detach the bulk of the placenta with the other hand and then clamp the lower uterine segment on both sides with ovum forceps (Figure 1). Bleeding usually attenuates dramatically.
3. While the assistant extracts the uterus, use the left hand to replace one of the ovum forceps and push the bladder sufficiently down. Ligate the uterine artery and simultaneously compress the lateral part of the lower uterine segment. Do this thrice at 2–3-cm intervals in the upward direction on each side (suture A) (Figure 2). Bleeding will attenuate remarkably.
4. Perform several full-thickness sutures on the anterior lower uterine segment (suture B) (Figure 2).
5. Perform several full-thickness horizontal sutures on the posterior lower uterine segment (suture C) (Figure 3).
6. Scrape the remaining placenta and cut around the uterine incision if the uterine wall has been penetrated or is very thin (Figure 2), which will also decrease the uterine volume and help with hemostasis.
7. Perform another long-step suture on each end of the uterine incision (suture D) (Figure 2). Additional local hemostatic sutures on the uterine wall may be needed. In most cases, complete hemostasis can be achieved. However, bleeding from the corpus may occur due to uterine inertia and coagulopathy after massive blood loss.
8. Perform vertical compression suture in the uterine corpus (suture E) (Figure 2). Compression on the uterine body to tighten the suture is crucial. Usually, five stitches for a term-pregnancy uterus and three stitches for a smaller uterus are needed. These sutures will compress the upper part of the uterus and simultaneously allow drainage. The tiny space on the top of the uterus is used to prevent enclosure of the bowel as the uterus later shrinks.

All possible bleeding sites in the entire uterus are subsequently compressed with sutures. The uterine incision is then closed and embedded carefully. Finally, the abdominal wall is closed after extensive hemostasis in the vesico-uterine pouch.

Large-step sutures are recommended to achieve rapid hemostasis and avoid potential ischemic necrosis in the uterus. Timely blood infusion is also important. Otherwise, hypoperfusion and coagulopathy after instant blood loss can lead to uterine inertia and intractable bleeding in the uterine corpus. The vertical compression suture in the uterine corpus is the only effective procedure to stop this vicious cycle.

Results

Of the 19,057 women who delivered during the study period, 4,488 women had a history of CS; PAS was observed in 758 women, with an incidence rate of 16.9%. Among these, 115 patients with PAS overlying the cesarean scar received surgical treatment following the eight-step protocol by the same surgeon. The basic characteristics, surgical information, and outcomes are presented in Table 1. The number of previous CS varied between 1 and 3. The average gestational week at surgery was 35.9 ± 2.2 weeks. Fourteen (12.2%) patients underwent emergency operation for hemorrhage or uterine contraction before surgery. The overall EBL was 1666.1 ± 1379.0 mL, with an average surgery duration of 2.2 ± 0.8 h. Vertical compression sutures in the uterine corpus were performed in 16 (13.9%) of 115 patients. The uterus was preserved successfully in all patients with one surgery, and no post-procedural hemorrhage or placenta residue was reported.

Table 1
Characteristics, surgical details, and outcomes of patients undergoing the eight-step protocol

	Variables	**Statistics**
Characteristics	Mean maternal age in years (SD)	33.3 ± 5.2
	Mean gestational age at surgery (SD)	35.9 ± 2.2
	Number of previous cesarean sections (1/2/3)	94/19/2(81.7/16.5/1.7%)
	Emergency surgery (%)	14/115 (12.2%)
Surgical details	Preventive aortic balloon occlusion	23/115 (20.0%)
	Estimated blood loss (mL)	1666.1 ± 1379.0
	Estimated blood loss (< 1000 mL/1000–3000 mL/>3000 mL)	60/36/19 (52.2/31.3/16.5%)
	RBC transfusion (U)	4.6 ± 4.2
	Surgical time (h)	2.2 ± 0.8
	Vertical compression suture in the uterine corpus(Y/N)	16/115 (13.9%)
	Additional operations (Dissection of myoma or ovarian cyst, Tubal ligation)	23/115(20.0%)
	Hysterectomy	0
Surgical complications	Fever	9/115 (7.8%)
	Lower extremity embolism	1/115(0.9%)
	Bladder rupture (Y/N)	13/115 (11.3%)
	Ureter rupture	0
Outcomes	Uterine preservation	115/115(100%)
	Neonatal Birth Weight(g)	2778.5 ± 522.2
	Hospital stay after surgery(d)	4.4 ± 2.1
	Late postpartum hemorrhage	0
SD,standard deviation; Y,yes; N,no		

Bladder rupture occurred in 13 (11.3%) of 115 patients, which was repaired instantly during the surgery; good recovery was achieved after continuous bladder irrigation (1–2 days) and drainage (3 weeks). Urine leakage was observed in one patient, which was treated successfully with continuous drainage for 2 months subsequently. Lower extremity embolism occurred in one patient in whom an aortic balloon had been used and was treated with the administration of low-molecular-weight heparin; complete functional and sensory recovery was achieved. Nine patients (7.8%) experienced post-procedural fever. All patients recovered well without severe complications such as ureter rupture, serious infection, or ischemic uterine necrosis.

Placenta accreta, increta, and percreta occurred in 40, 46, and 29 cases (34.7%, 40.0, 25.2%) respectively, as per the intraoperative assessment. Extensive placenta invasion was observed in 41.7% (48/115) of patients, and cervical involvement was seen in 28.7% (33/115). Severe pelvic adhesion was determined in 20/115 (17.9%) patients. The variables of placental location, extent and depth of placental invasion, cervical involvement, pelvic adhesion, and preoperative aortic balloon were entered into the multiple linear regression analysis (Table 2). EBL was significantly correlated with the extent of placenta invasion, cervical involvement, and pelvic adhesion, but not with the depth of placenta invasion or the placenta location (Table 3).

Table 2
The variables to determine the factors correlated with surgical blood loss

	Groups	EBL < 1000 mL	EBL 1000–3000 mL	EBL > 3000 mL	Coef.	*P*
Previous CS	1	51(54.2%)	30(31.9%)	13(13.8%)	0.146	0.118
	2	7(36.8%)	6(31.6%)	6(31.6%)		
	3	1(50.0%)	1(50.0%)	0(0%)		
Gestational week at surgery	< 36W	30(53.5%)	17(30.4%)	9(16.1%)	-0.097	0.304
	>=36W	29(49.1%)	20(33.9%)	10(16.7%)		
Emergency surgery	N	51(50.5%)	34(33.7%)	16(15.8%)	0.027	0.778
	Y	8(57.14%)	3(21.43%)	3(21.43%)		
Cervical involvement	N	57(69.5%)	22(26.8%)	3(3.7%)	0.692	**< 0.001**
	Y	2(6.1%)	20(60.6%)	11(33.3%)		
Extent of placenta invasion	None	12(80.0%)	3(20.0%)	0(0%)	0.655	**< 0.001**
	< 1/6	23(88.5%)	3(11.5%)	0(0%)		
	1/6 – 1/3	17(65.4%)	8(30.7%)	1(3.6%)		
	> 1/3	7(14.6%)	23(47.9%)	18(37.5%)		
Depth of placenta invasion	Accreta	33(82.5%)	7(17.5%)	0(0%)	0.509	**< 0.001**
	Increta	17(36.9%)	20(43.5%)	9(19.6%)		
	Percreta	9(31.0%)	10(34.5%)	10(34.5%)		
Placenta location	Posterior	6(66.7%)	3(33.3%)	0(0%)	0.510	**< 0.001**
	Anterior	32(78.1%)	8(19.5%)	1(2.4%)		
	Central	21(32.3%)	26(40.0%)	18(27.7%)		
Preoperative aortic balloon	N	56(60.9%)	24(26.1%)	12(13.0%)	0.447	**< 0.001**
	Y	3(13.0%)	13(56.5%)	7(30.4%)		
Pelvic adhesion	Mild/none	56(59.0%)	27(28.4%)	12(12.6%)	0.324	**< 0.001**
	Severe	3(15.0%)	10(50.0%)	7(35.0%)		

EBL, estimated blood loss; Y,yes; N,no

Table 3
Risk factors influencing estimated blood loss during the eight-step protocol

	Coef.	Std. Err	*P*
Preoperative aortic balloon	1.929	247.202	0.994
Placenta location	36.198	155.846	0.817
Depth of placenta invasion	118.156	145.391	0.418
Extent of placenta invasion	290.965	109.838	**0.009**
Cervical involvement	1588.170	239.630	**< 0.001**
Pelvic adhesion	611.053	234.479	**0.010**
Coef, coefficient; Std.Err, standard error			

The extent of placental invasion, pelvic adhesion, and cervical involvement were the main risk factors for excessive blood loss, and the severity was determined according to intraoperative assessments of these indexes. Based on this, 44/115 (38.2%) cases were severe. However, only 21/44 (47.7%) patients were treated using a perioperative aortic balloon, as some of them refused it due to economic reasons, some needed emergency surgery, and some were diagnosed intraoperatively. In the 44 severe cases determined during surgery, EBL in the balloon group (n = 21) was slightly lower than that in the non-balloon group (n = 23) (2850.0 ± 1229.7 mL vs 2913.0 ± 1773.6 mL); however, the difference was not significant (p = 0.286) (Table 4).

Table 4
Estimated blood loss between the balloon and non-balloon groups in 44 severe cases.

	Case number	Mean ± SD.	*P*
Non-balloon group	23	2913.0 ± 1773.6	0.286
Balloon group	21	2850.0 ± 1229.7	
SD, standard error			

Discussion

Placenta overlying the cesarean scar is dangerous, as it can lead to excessive blood loss, regardless of whether there is placental invasion. PAS overlying the cesarean scar is more challenging to treat. Secondary hemorrhaging might require another surgery after attempts to preserve the uterus. The strategies of uterine preservation for PAS or PPP include expectant management by leaving the placenta *in situ*,[9,17–20] local resection of the placenta with the involved uterine wall and uterine reconstruction,[21–27] and multiple compression sutures.[15,28–32] These methods have usually been used in combination with interventional radiology techniques, such as arterial balloon occlusion,[23,25,26,32] arterial embolization,[17–19, 26] or dysvascular techniques with tourniquet,[23,24] or pelvic artery ligation.[9,15, 20–22,24,29] The success rate of uterine preservation varied greatly from 25–100% (Table 5).[9,15,17–32] Leaving the placenta untouched resulted in a higher incidence of later postpartum hemorrhage and hysterectomy. In this study, we provided a stepwise protocol to compress any possible intrauterine bleeding sites. Complete

hemostasis was achieved in all patients with one surgery. With blockage of hemorrhage immediately post-delivery, this protocol allowed for thorough cleaning of the placental tissue, with no additional treatment.

Table 5
Outcomes of conservative strategies for PAS or PPP in the literature

Main measurements		Author	Diagnosis	Case number	Dysvascular technique	Hysterectomy rate
Expectant Management		Sentilhes L 2010[9]	Placenta accreta	167	Pelvic devascularization	22%
		Miyakoshi K 2018[17]	PPP	36	Uterine artery embolization	30.6%
		Huang KL 2020[18]	Placenta increta or percreta	21	Arterial embolization	19.0%
		Su 2017[19]	PAS	8	Embolization of uterine arteries and other pelvic collateral vessels	75%
		Kutuk 2018[20]	PAS	15	Uterine artery ligation, Utero-ovarian artery ligation	6.7%
Local resection and reconstruction		Karaman E 2016[21]	Placenta percreta	12	Artery ligation; Balloon tamponade	33.3%
		Kilicci C 2017[22]	Placenta invasion previous CS	22	Artery ligation	0%
		Zhao 2018[23]	PPP, increta, percreta	62	Aortic balloon, Tourniquet	1.6%
		Cırpan T 2019[24]	PAS	21	Artery ligation, Tourniquet	9.5%
		Palacios 2020[25]	Invasive placenta	326	Aortic balloon	29.5%
	Triple P procedure	Teixidor VM 2015[26]	MAP	13	Internal iliac balloon; Embolization	0%
		Abo-Elroose AA 2019[27]	Anterior placenta previa; accreta/increta	20	Uterine artery ligation	5%
Compression sutures	Stepwise approach	Shabana A 2015[15]	Anterior placenta percreta	71	Artery ligation	8.5%
	Funnel compression suture	Li GT 2016[28]	PPP	22	No	18.2%

PAS, placenta accreta spectrum; PPP, pernicious placenta previa; MAP, morbidly adherent placenta.

Main measurements		Author	Diagnosis	Case number	Dysvascular technique	Hysterectomy rate
	Intracavity suture	Acar A 2018[29]	Placenta previa, invasion	62	Artery ligation	6%
	Lower segment folding	Mohamed MA 2019[30]	MAP	32	No	0%
	Parallel vertical compression suture	Mohamed MA 2019[31]	Placenta previa; MAP	49	Intrauterine balloon	6.1%
	Transverse parallel compression suture	Zhao B 2020[32]	PPP	32	Internal iliac balloon	0

PAS, placenta accreta spectrum; PPP, pernicious placenta previa; MAP, morbidly adherent placenta.

Few studies have investigated the factors influencing surgical blood loss in PAS. It has been reported that patients with deep PAS are more likely to undergo hysterectomy, with more blood loss during the surgery.[32] Invasions in the inferior third of the lower uterine segment carry a higher risk of surgical morbidity than those in the upper segment.[33] However, large variability may be observed during surgery in patients presenting with the same degree of placental invasion.[32,34] The possibility of uterine preservation and surgical blood loss depends on the surgical techniques and severity of placental invasion. By using the eight-step-protocol, we observed that the EBL during surgery was not correlated with the depth of placental invasion. Instead, the EBL was significantly correlated with the extent of placental invasion and the involvement of the cervix.

We observed that pelvic adhesion was another important factor affecting EBL. With extensive pelvic adhesion, it is difficult to perform bladder dissection, which is necessary to place compression sutures in the lower uterine segment.[35] Furthermore, uterine exteriorization and step 2 are difficult to implement effectively to block bleeding. Unfortunately, it is difficult to predict the severity of adhesion before surgery.

Preoperative arterial balloon has been proven to be effective in reducing surgical bleeding and shortening surgery duration[36,37] in patients with PAS. However, in this cohort, the EBL in the balloon group was not significantly lower than that in the non-balloon group. The probable reason is that following this protocol, the immediate blockage of hemorrhage with hands and oval clamps resembled the effect of blockage using a balloon. Several complications of the balloon technique, such as ischemia in the lower extremities, arterial thrombosis, and aortic rupture, have been reported.[38–39] Therefore, the balloon technique should be used conservatively, and routine use is not recommended.[11,38]

The limitations of this research are its retrospective nature and the lack of standard diagnostic criteria on the severity of placental invasion. Furthermore, the effect of this procedure on subsequent fertility is unknown as most of the patients did not have plans for another pregnancy after surgery. A prospective controlled study is needed to prove the efficacy of this protocol and to investigate its effect on subsequent fertility.

Conclusions

In conclusion, uterine preservation with one surgery is possible in PAS patients using the proposed eight-step protocol. EBL is affected by the extent of placental invasion, cervical involvement, and severity of pelvic adhesion. Thus, perioperative aortic balloon should be used conservatively.

Abbreviations

PAS Placenta accrete spectrum

EBL Estimated blood loss

PPP Pernicious placenta previa

CS Cesarian section

MAP Morbidly adherent placenta

Declarations

Ethics approval and consent to participate

This study was approved by the ethical committee of Shandong Provincial Hospital affiliated to Shandong First Medical University（SWYX:NO.2021-369） and written informed consent was signed by patients who agreed to participate.

Consent for publication

Written informed consent was obtained from the patients for publication of this study.

Availability of data

The datasets generated during and/or analyzed during the current study are available from the corresponding author on reasonable request.

Competing interests

The authors have no conflicts of interest to disclose.

Funding:

None

Author’s contributions:

YLL and TL drafted and revised the manuscript, and analysed and interpreted data for the work. WP was responsible for conceiving the work. XBL collected and analysed the data. HMW designed the work and gave the final approval of the version to be published. All authors have read and approved the manuscript.

Acknowledgements

We would like to thank Zeqi Wang for artwork.

References

1. Jauniaux E, Bhide A, Kennedy A, Woodward P, Hubinont C, Collins S, et al. FIGO consensus guidelines on placenta accreta spectrum disorders: prenatal diagnosis and screening. Int J Gynaecol Obstet. 2018;140:274-80.
2. Silver RM, Branch DW. Placenta accreta spectrum. N Engl J Med. 2018;378:1529-36.
3. Fitzpatrick KE, Sellers S, Spark P, Kurinczuk JJ, Brocklehurst P, Knight M. Incidence and risk factors for placenta accreta/increta/percreta in the UK: a national case-control study. PLOS ONE. 2012;7:e52893.
4. Chattopadhyay SK, Kharif H, Sherbeeni MM. Placenta praevia and accreta after previous caesarean section. Eur J Obstet Gynecol Reprod Biol. 1993;52:151-6.
5. Silver RM, Landon MB, Rouse DJ, Leveno KJ, Spong CY, Thom EA, et al. Maternal morbidity associated with multiple repeat cesarean deliveries. Obstet Gynecol. 2006;107:1226-32.
6. American College of Obstetricians and Gynecologists; Society for Maternal-Fetal Medicine, Society for Maternal-Fetal Medicine. Obstetric care Consensus No. 7: placenta accreta spectrum. Obstet Gynecol. 2018;132:e259-75.
7. Wu S, Kocherginsky M, Hibbard JU. Abnormal placentation: twenty-year analysis. Am J Obstet Gynecol. 2005;192:1458-61.
8. Thurn L, Wikman A, Westgren M, Lindqvist PG. Massive blood transfusion in relation to delivery: incidence, trends and risk factors: a population-based cohort study. BJOG. 2019;126:1577-86.
9. Zuckerwise LC, Craig AM, Newton JM, Zhao S, Bennett KA, Crispens MA. Outcomes following a clinical algorithm allowing for delayed hysterectomy in the management of severe placenta accreta spectrum. Am J Obstet Gynecol. 2020;222:179.e1-9.
10. Sentilhes L, Ambroselli C, Kayem G, Provansal M, Fernandez H, Perrotin F, et al. Maternal outcome after conservative treatment of placenta accreta. Obstet Gynecol. 2010;115:526-34.
11. Sentilhes L, Kayem G, Chandraharan E, Palacios-Jaraquemada J, Jauniaux E, FIGO Placenta Accreta Diagnosis and Management Expert Consensus Panel. FIGO consensus guidelines on placenta accreta spectrum disorders: conservative management. Int J Gynaecol Obstet. 2018;140:291-8.
12. Turan OM, Shannon A, Asoglu MR, Goetzinger KR. A novel approach to reduce blood loss in patients with placenta accreta spectrum disorder. J Matern Fetal Neonatal Med. 2021;34: 2061-70.
13. Chevalier G, Devisme L, Coulon C. Placenta accreta spectrum disorder: management and morbidity in a French type-3 maternity. Gynecol Obstet Fertil Senol. 2020;48:500-5.
14. Timmermans S, van Hof AC, Duvekot JJ. Conservative management of abnormally invasive placentation. Obstet Gynecol Surv. 2007;62:529-39.
15. Shabana A, Fawzy M, Refaie W. Conservative management of placenta percreta: a stepwise approach. Arch Gynecol Obstet. 2015;291:993-8.
16. Jauniaux E, Ayres-de-Campos D, Langhoff-Roos J, Fox KA, Collins S, Figo Placenta Accreta Diagnosis and Management Expert Consensus Panel. FIGO classification for the clinical diagnosis of placenta accreta spectrum disorders. Int J Gynaecol Obstet. 2019;146:20-4.
17. Miyakoshi K, Otani T, Kondoh E, Makino S, Tanaka M, Takeda S, et al. Retrospective multicenter study of leaving the placenta in situ for patients with placenta previa on a cesarean scar. Int J Gynaecol Obstet. 2018;140:345-51.

18. Huang KL, Leung-Chit Tsang L-C, Cheng YF, Huang FJ, Fu HC, Kung FT, *et al.* Planned conservative management of placenta increta and percreta with prophylactic transcatheter arterial embolization and leaving placenta in situ for women who desire fertility preservation. Placenta. 2020;97:51-7.
19. Su HW, Yi YC, Tseng JJ, Chen WC, Chen YF, Kung HF, et al. Maternal outcome after conservative management of abnormally invasive placenta. Taiwan J Obstet Gynecol. 2017;56:353-7.
20. Kutuk MS, Ak M, Ozgun MT. Leaving the placenta in situ versus conservative and radical surgery in the treatment of placenta accreta spectrum disorders. Int J Gynaecol Obstet. 2018;140:338-44.
21. Karaman E, Kolusarı A, Çetin O, Çim N, Alkış İ, Yıldızhan R, et al. Local resection may be a strong alternative to cesarean hysterectomy in conservative surgical management of placenta percreta: experiences from a tertiary hospital. J Matern Fetal Neonatal Med. 2017;30:947-52.
22. Kilicci C, Sanverdi I, Ozkaya E, Eser A, Bostanci E, Yayla Abide C, et al. Segmental resection of anterior uterine wall in cases with placenta percreta: a modified technique for fertility preserving approach. J Matern Fetal Neonatal Med. 2018;31:1198-203.
23. Zhao X, Tao Y, Du Y, Zhao L, Liu C, Zhou Y, et al. The application of uterine wall local resection and reconstruction to preserve the uterus for the management of morbidly adherent placenta: case series. Taiwan J Obstet Gynecol. 2018;57:276-82.
24. Cirpan T, Akdemir A, Okmen F, Hortu I, Ekici H, Imamoglu M. Effectiveness of segmental resection technique in the treatment of placenta accreta spectrum. J Matern Fetal Neonatal Med. 2021;34: 3227-33.
25. Palacios-Jaraquemada JM, Fiorillo A, Hamer J, Martínez M, Bruno C. Placenta accreta spectrum: a hysterectomy can be prevented in almost 80% of cases using a resective-reconstructive technique. J Matern Fetal Neonatal Med. 2020;26:1-8.
26. Teixidor Viñas M, Belli AM, Arulkumaran S, Chandraharan E. Prevention of postpartum hemorrhage and hysterectomy in patients with morbidly adherent placenta: a cohort study comparing outcomes before and after introduction of the Triple-P procedure. Ultrasound Obstet Gynecol. 2015;46:350-5.
27. Abo-Elroose AA, Ahmed MR, Shaaban MM, Ghoneim HM, Mohamed TY. Triple P with T-shaped lower segment suture; an effective novel alternative to hysterectomy in morbidly adherent anterior placenta previa. J Matern Fetal Neonatal Med. 2021;34: 3187-91.
28. Li GT, Li GR, Li XF, Wu BP. Funnel compression suture: a conservative procedure to control postpartum bleeding from the lower uterine segment. BJOG. 2016;123:1380-5.
29. Acar A, Ercan F, Pekin A, Elci Atilgan A, Sayal HB, Balci O, et al. Conservative management of placental invasion anomalies with an intracavitary suture technique. Int J Gynaecol Obstet. 2018;143:184-90.
30. Mohamed MA. Lower segment folding as novel technique to control bleeding in cases of morbidly adherent placenta. J Matern Fetal Neonatal Med. 2019;13:1-5.
31. Mohamed MA, Mohammed AH. Parallel vertical compression sutures to control bleeding in cases of placenta previa and accreta. J Matern Fetal Neonatal Med. 2019;32:641-5.
32. Zhao B, Lv M, Dong T, Chen Y, Xi F, Lv W, et al. Transverse parallel compression suture: a new suturing method for successful treating pernicious placenta previa during cesarean section. Arch Gynecol Obstet. 2020;301:465-72.
33. Yasin N, Slade L, Atkinson E, Kennedy-Andrews S, Scroggs S, Grivell R. The multidisciplinary management of placenta accreta spectrum (PAS) within a single tertiary centre: A ten-year experience. Aust N Z J Obstet Gynaecol. 2019;59:550-4.

34. D'Antonio F, Palacios-Jaraquemada J, Lim PS, Forlani F, Lanzone A, Timor-Tritsch I, et al. Counseling in fetal medicine: evidence-based answers to clinical questions on morbidly adherent placenta. Ultrasound Obstet Gynecol. 2016;47:290-301.
35. Cali G, Forlani F, Lees C, Timor-Tritsch I, Palacios-Jaraquemada J, Dall'Asta A, et al. Prenatal ultrasound staging system for placenta accreta spectrum disorders. Ultrasound Obstet Gynecol. 2019;53:752-60.
36. Chen L, Wang X, Wang H, Li Q, Shan N, Qi H. Clinical evaluation of prophylactic abdominal aortic balloon occlusion in patients with placenta accreta: a systematic review and meta-analysis. BMC Pregnancy Childbirth. 2019;19:30.
37. Luo F, Xie L, Xie P, Liu S, Zhu Y. Intraoperative aortic balloon occlusion in patients with placenta previa and/or placenta accreta: a retrospective study. Taiwan J Obstet Gynecol. 2017;56:147-52.
38. Tokue H, Tokue A, Tsushima Y, Kameda T. Safety and efficacy of aortic vs internal Iliac balloon occlusion for cesarean delivery in coexisting placenta accreta and placenta previa. Cardiovasc Intervent Radiol. 2020;43:1277-84.
39. Peng W, Shen L, Wang S, Wang H. Retrospective analysis of 586 cases of placenta previa and accreta. J Obstet Gynaecol. 2020;40:609-13.

Figures

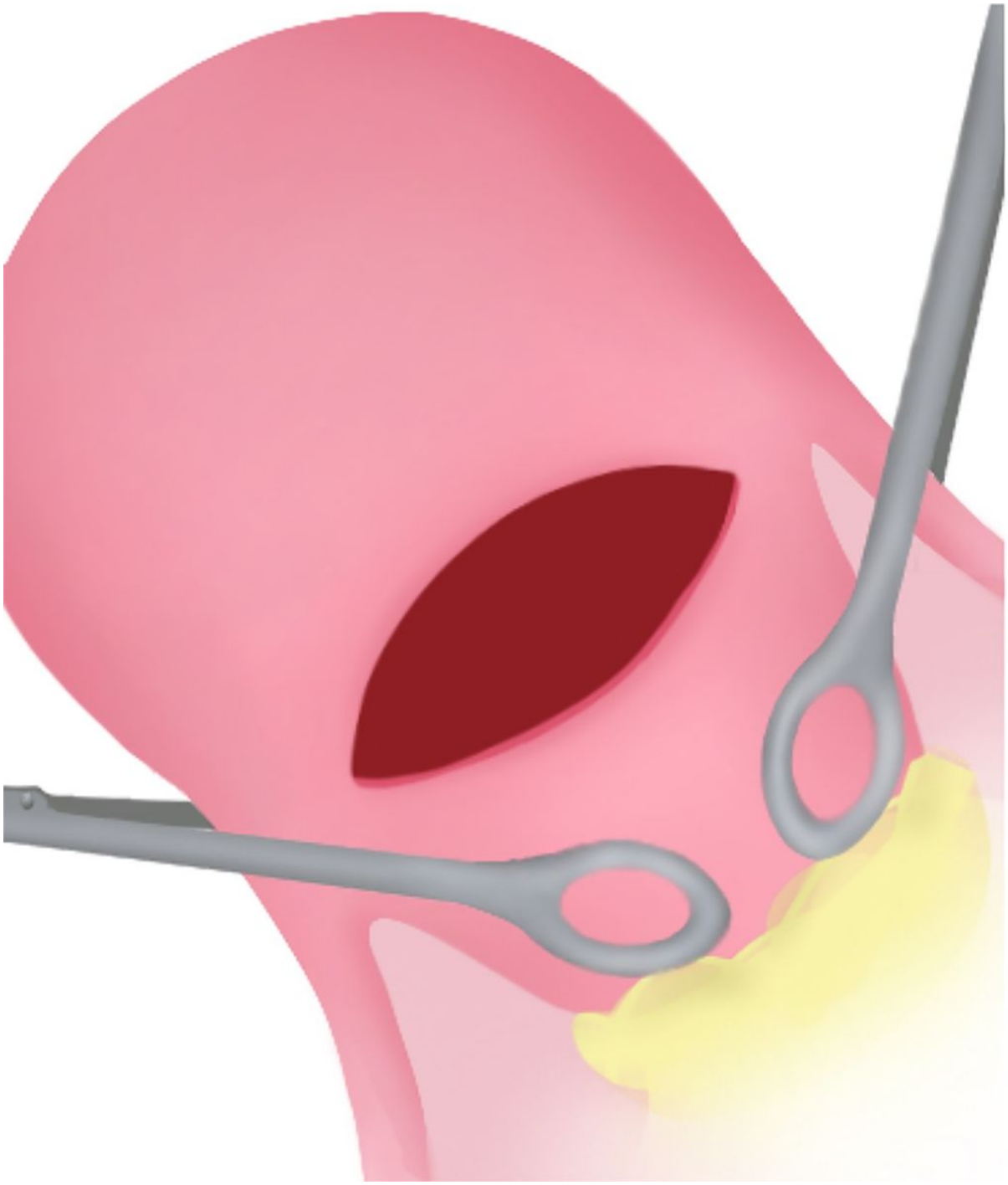

Figure 1

The lower uterine segment is appropriately clamped with ovum forceps to decrease bleeding after delivering the baby

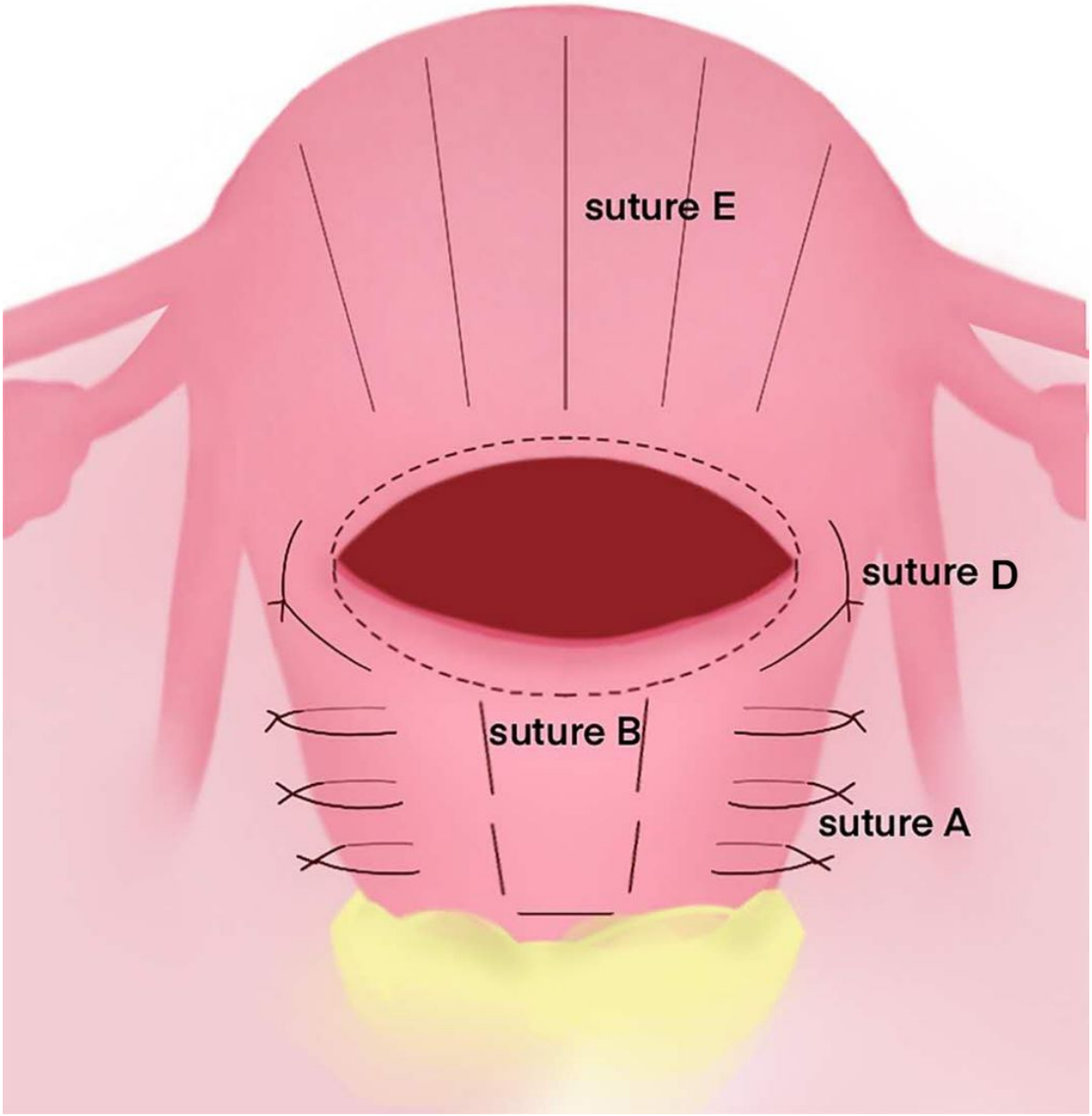

Figure 2

Sutures on the anterior wall

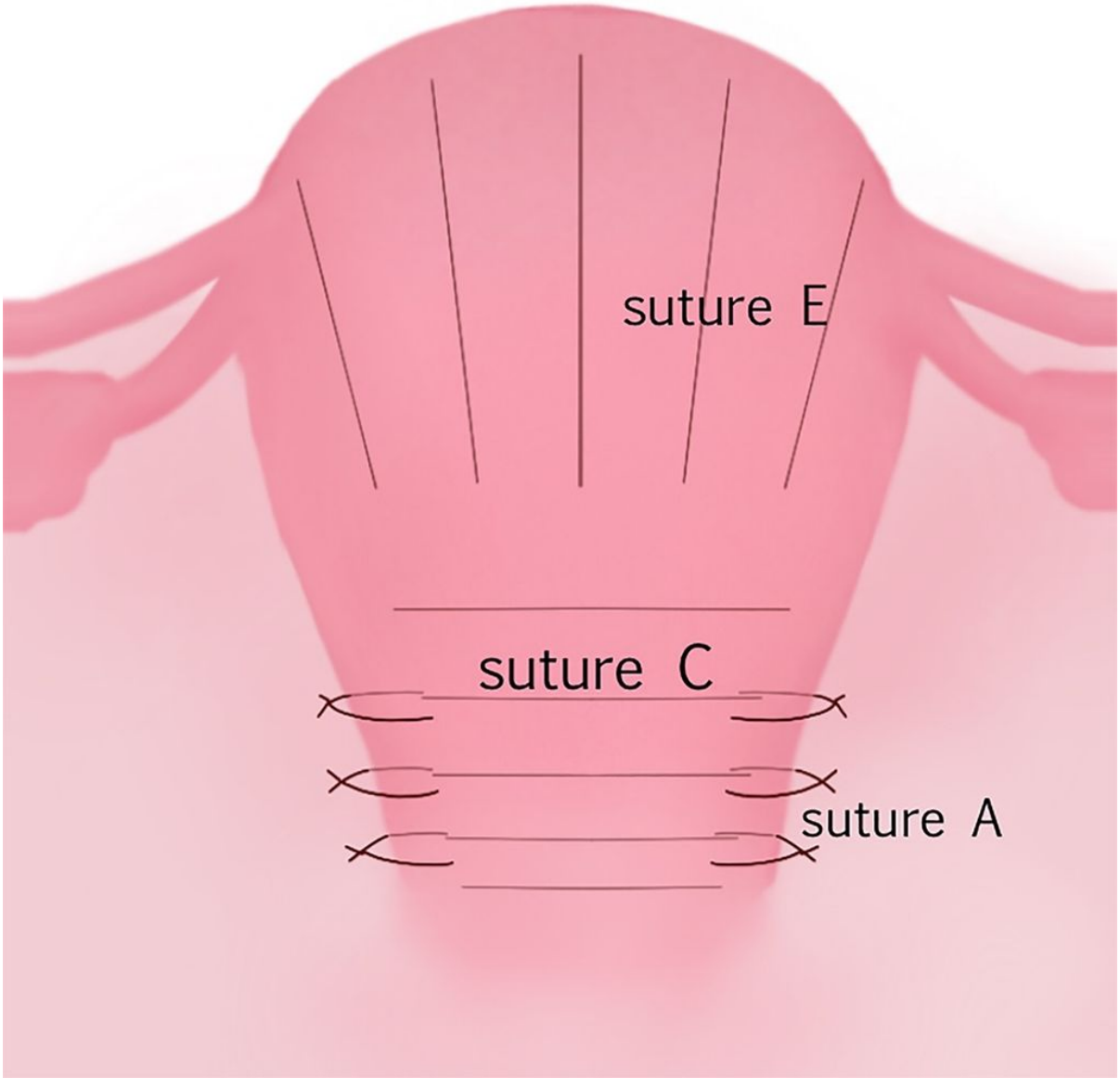

Figure 3

Sutures on the posterior wall