Anti-SAE Autoantibody-Positive Japanese Patient with Juvenile Dermatomyositis complicated with Interstitial Lung Disease - A Case Report

Takayuki Kishi (kishi.takayuki@twmu.ac.jp)
Tokyo Women's Medical University Hospital: Tokyo Joshi Ika Daigaku Byoin https://orcid.org/0000-0002-7208-1562

Yumi Tani
Tokyo Women's Medical University Hospital: Tokyo Joshi Ika Daigaku Byoin

Naoko Okiyama
University of Tsukuba Faculty of Medicine: Tsukuba Daigaku Igaku Iryokei

Kiyoshi Mizuochi
Tokyo Women's Medical University Hospital: Tokyo Joshi Ika Daigaku Byoin

Yuki Ichimura
University of Tsukuba Faculty of Medicine: Tsukuba Daigaku Igaku Iryokei

Masayoshi Harigai
Tokyo Women's Medical University Hospital: Tokyo Joshi Ika Daigaku Byoin

Satoru Nagata
Tokyo Women's Medical University Hospital: Tokyo Joshi Ika Daigaku Byoin

Takako Miyamae
Tokyo Women's Medical University Hospital: Tokyo Joshi Ika Daigaku Byoin

---

Case Report

Keywords: juvenile dermatomyositis, myositis-specific autoantibody, interstitial lung disease, anti-SAE autoantibody

Posted Date: September 29th, 2020

DOI: https://doi.org/10.21203/rs.3.rs-83639/v1

Version of Record: A version of this preprint was published on March 19th, 2021. See the published version at https://doi.org/10.1186/s12969-021-00532-2.

Abstract

Background Clinical phenotypes and outcomes in juvenile dermatomyositis (JDM) have been defined by various myositis-specific autoantibodies (MSAs). One of the recently described MSAs associated with DM is targeted against the small ubiquitin-like modifier 1 activating enzyme (SAE). We report an anti-SAE autoantibody-positive JDM patient complicated with interstitial lung disease (ILD).

Case presentation: An 8-year-8-month-old Japanese girl presented with bilateral eyelid edema and facial erythema. At 8 years 4 months, she had dry cough and a papule with erythema on the dorsal side of the bilateral phalangeal joints. Her facial erythema gradually worsened and did not improve with topical steroids. At the first visit to our department at 8 years 8 months of age, she had a typical heliotrope rash and Gottron's papules, with no fever or weight loss, and a chest computed tomography scan showed ground-grass opacity under visceral pleura. There was no clinical evidence of myositis, muscle weakness, myalgia, or muscle magnetic resonance imaging (MRI) findings. She had mild dry cough, without any signs of respiratory distress. Laboratory tests showed no elevated inflammatory markers. She had a normal serum creatine kinase level with a slightly elevated aldolase level, and serum anti-SAE autoantibody was detected by immunoprecipitation—western blotting. She was diagnosed with juvenile amyopathic DM complicated by ILD and received two courses of methylprednisolone pulse therapy followed by oral corticosteroid and cyclosporin A. We gradually reduced the corticosteroid dose as her skin rash tended to improve after treatment initiation. There was no progression of muscle symptoms, dysphagia, or disease flare during an 18-month follow-up period.

Conclusions: We report a patient with anti-SAE autoantibody-positive JDM complicated by interstitial pneumonia. This patient had no progression of muscle symptoms and dysphagia during an 18-month follow-up period, which differs from previous reports in adult patients with MSAs. There have been no previous reports of pediatric patients with SAE presenting with ILD. However, ILD seen in this case was not rapidly progressive and did not require cytotoxic agents. To prevent overtreatment, appropriate treatment choices are required considering the type of ILD.

Background

Clinical phenotypes and outcomes in juvenile dermatomyositis (JDM) have been defined by various myositis-specific autoantibodies (MSAs) (1, 2). One of the recently described MSAs associated with dermatomyositis (DM) is targeted against small ubiquitin-like modifier 1 (SUMO-1) activating enzyme (SAE) (3). Anti-SAE autoantibody-positive myositis patients have been reported in Caucasian (6–8%) and Asian adults (1–3%) (3–8) and are associated with severe cutaneous disease, progressive muscle disease with dysphagia, fever, and weight loss (9, 10). It has also been reported that anti-SAE autoantibody-positive patients were at a lower frequency in the juvenile population (< 1%) (11, 12). It is rare in children, with the details of its clinical course often unknown. We report an anti-SAE autoantibody-positive JDM patient with interstitial lung disease (ILD).

Case Presentation

The patient, an 8-year-8-month-old Japanese girl, first manifested bilateral eyelid edema at 8 years 0 months and facial erythema 2 months later. At 8 years 4 months, she had dry cough and a papule with erythema on the dorsal side of the bilateral phalangeal joints. Her facial erythema gradually worsened and did not improve with topical steroids. She was referred to our department at 8 years and 8 months because of positive antinuclear antibodies and a chest computed tomography (CT) scan showing ground-grass opacity under the visceral pleura (Fig. 1A). At the first visit to our department, she had a typical heliotrope rash and Gottron's papules, with no fever or weight loss. Her childhood myositis assessment scale (CMAS) score was normal (51/52) and there was no clinical evidence of myositis, muscle weakness, or myalgia. Magnetic resonance imaging (MRI) of the lower extremities showed normal findings without any muscle edema or myositis. She had mild dry cough, without signs of respiratory distress, including decreased oxygen saturation. Laboratory tests showed no elevation of inflammatory markers (Table 1). Although her serum creatine kinase (CK) level was normal (91 IU/L, upper limit of normal < 163), her aldolase level was slightly elevated (9.9 U/L, upper limit of normal < 6.1). Serum Krebs von den Lungen-6 (KL-6) level was mildly elevated, serum ferritin level was normal, and anti-melanoma differentiation-associated gene 5 (MDA5) antibodies were negative. Serum anti-SAE autoantibodies were detected using immunoprecipitation—western blotting (4, 13).

Table 1
Laboratory findings on admission

WBC	**4,800**	**/μl**	**AST**	**27**	**U/l**	**C3**	**100**	**mg/dl**
Neutrophil	33	%	ALT	20	U/l	C4	19	mg/dl
Lymphocyte	58	%	LDH	296	U/l	CH50	45	U/ml
Hb	13.1	g/dl	CK	91	U/l	ANA	1:80	
PLTs	23.3	/μl	Aldorase	9.9	IU/L			
ESR	7	mm/hr	CRP	0.1	mg/dl	anti-SAE Ab	positive	(IP-WB)
			KL-6	646	U/ml	anti-NXP2 Ab	negative	(IP-WB)
PT (INR)	0.93		ferritin	33	mg/ml	anti-MDA5 Ab	negative	(NR < 32 titer index, EIA)
APTT	32.8	sec	IgG	1287	mg/dl	anti-ARS Ab	negative	(NR < 25, titer index, EIA)
FDP	1.0	μg/ml	IgA	133	mg/dl	anti-TIF1 Ab	negative	(NR < 32, titer index, EIA)
D-dimer	0.9	μg/ml	IgM	87	mg/dl	anti-Mi-2 Ab	negative	(NR < 53 titer index, EIA)

Abbreviation: Ab: autoantibodies, ALT: alanine aminotransferase; ANA: antinuclear antibody; APTT: activated partial thromboplastin time; ARS: aminoacyl tRNA synthetase; AST: aspartate aminotransferase; CH50: complement hemolytic activity; CK: creatine kinase; CRP: C-reactive protein; C3: complement component 3; C4: complement component 4; EIA: enzyme immunoassay; ESR: erythrocyte sedimentation rate; FDP: fibrin degradation products; Hb: hemoglobin; IgA: immunoglobrin A; IgG: immunoglobrin G; IgM: immunoglobrin M; IP-WB: immunoprecipitation Western blotting; KL-6: Krebs von den Lungen-6; LDH: lactate dehydrogenase; MDA5: melanoma differentiation-associated gene 5; NR: normal range; NXP2: nuclear matrix protein 2; PLTs: platelets; PT(INR): prothrombin time (international normalized ratio); SAE: small ubiquitin-like modifier activating enzyme; TIF1: transcriptional intermediary factor 1; WBC: white blood count

The patient met the 2017 American college of rheumatology/European league against rheumatism classification criteria for adult and juvenile idiopathic inflammatory myopathies (14) and was diagnosed with juvenile amyopathic DM complicated by ILD. She received two courses of methylprednisolone pulse therapy followed by oral corticosteroid (20 mg/day, 0.7 mg/kg/day) and cyclosporin A (150 mg/day, 5 mg/kg/day) administration. We gradually reduced the corticosteroid dose as her skin rash tended to improve after treatment initiation. There were no new muscle symptoms or dysphagia during the follow-up period. There was no exacerbation of abnormal findings on chest CT scan (Fig. 1B), and no increase in serum KL-6 levels during follow-up. There was no flare of disease by the age of 10 years and 3 months, which was 18 months after treatment initiation.

Discussion And Conclusions

Most JDM patients have MSAs alone or those associated with specific clinical phenotypes (1, 2). Although several phenotypic features are similar in both adult and juvenile MSA patients, some important differences exist (15). For example, the association of an increased risk of malignancy with anti-p155/140 (TIF1) autoantibody is significant in the adults, whereas the association is unclear in juvenile patients (1, 16). The frequency of each MSA differs between adult DM and JDM patients. Anti-synthetase autoantibodies are positive in 20%-30% of adults and are less than 5% in juveniles (2, 15). On the other hand, anti-NXP2 (MJ) autoantibody is rare in adult patients, while it is positive in 20%-25% of juveniles (2), which is the second most frequent MSA in JDM. There are also differences in the rate of MSAs positivity between races. Anti-MDA5 autoantibodies are more common in the Asian population, and anti-SRP autoantibodies are seen primarily in the African American teenage girls (17, 18). Although the same MSAs are present, the prevalence can vary by age and race, and identifying the clinical characteristics of children with MSAs is crucial to estimate prognosis and other aspects of the disease.

Anti-SAE autoantibody is the recently identified MSA first reported in 2007 by Betteridge *et al.* (19). The target autoantigens are the SUMO-1 activating enzyme heterodimer consisting of 40 kDa SAE1 and 90 kDa SAE2 (3, 19). The frequency of anti-SAE autoantibodies positivity in adult DM patients has been reported to be 5.5%-8% in the European cohorts and 1.5%-3.0% in the Asians (3–8). The clinical presentation at the onset of the illness was characterized by severe cutaneous symptoms and mild myopathic symptoms. During follow-up, patients showed the progression of myositis, dysphagia, and systemic symptoms, such as fever, weight loss, and increased inflammatory markers (3, 4, 7, 13). In addition, a study on Japanese adults showed complications of interstitial pneumonia (4, 13, 20).

Few pediatric cases with anti-SAE antibody have been reported to date, with less than 1% of the juvenile myositis cohort. Only 3 patients (0.7%) had anti-SAE autoantibodies among 379 juvenile myositis patients in the United Kingdom (UK) cohort (11). Of the three patients, two presented with typical rash and limited or no muscle involvement but subsequently developed weakness and raised muscle enzymes. Skin diseases were persistent in both patients. In contrast, the third patient presented with seven-month history of myalgia and weakness with no rash. Myositis was diagnosed based on elevated muscle

enzymes with consistent MRI and muscle biopsy findings. This patient developed typical cutaneous features of JDM two years later (11).

Our patient showed typical cutaneous findings of JDM, almost no muscle weakness, and ILD. Although typical cutaneous symptoms have been previously reported in juvenile patients with anti-SAE autoantibodies, no juvenile patients with ILD have been reported. Our patient had ILD from disease onset and was not a rapidly progressive (RP) type, similar to the adult Japanese patients with this autoantibody (4, 13, 20). We have shown that the Asian patients with anti-SAE autoantibodies could have ILD, even in juvenile patients. There have been few reports of pediatric patients from Asia. An association between anti-SAE autoantibody and HLA-DRB1*04-DQA1*03-DQB1*03 haplotype in adult patients with DM has been reported (3), possibly as one of the reasons for the racial differences in phenotype and frequency of these MSA-positive patients. Although the patient had no dysphagia during the 18-month follow-up, other symptoms were similar to those reported in adults, and therefore, we must be cautious about whether muscle weakness or dysphagia will occur in this patient in the near future.

In the Japanese patients, the frequency of anti-MDA5 autoantibody-positive patients is even higher in JDM patients (21). Adult DM or JDM with anti-MDA5 autoantibody-positive patients are often complicated with ILD, which usually shows an RP type with poor prognosis (18, 21). Therefore, combination therapy using three immunosuppressive agents, including corticosteroids, calcineurin inhibitors, and cyclophosphamide, is recommended from the early stage of illness for adult DM patients with ILD (22). When a patient is complicated with ILD, we tend to opt for potent immunosuppressive therapy to improve the prognosis. However, depending on the differences in MSAs, the ILD may not show the RP type, as observed in this patient with anti-SAE autoantibody. Prognostic factors for RP-ILD include positive anti-MDA5 autoantibody, the deterioration of CT findings on a weekly basis, and elevated serum ferritin, KL-6, and IL-18 levels (18, 23). For patients complicated with ILD without these prognostic factors, the possibility of non-RP-ILD should be considered along with the possibility that combination therapy of immunosuppressive agents may be over-treating these patients. As in our patient, JDM patients with ILD should be carefully evaluated before making appropriate treatment choices.

We report a patient with anti-SAE autoantibody-positive JDM complicated by ILD. The patient had no progression of muscle symptoms and dysphagia during an 18-month follow-up period, which differs from the previous reports in adult patients with MSA. There have been no previous reports of pediatric patients complicated with ILD. However, ILD identified in our patient was not an RP type and did not require a cytotoxic agent. Further studies are needed to determine the characteristics of the clinical course in pediatric patients with anti-SAE autoantibodies.

List Of Abbreviations

ACR; American college of rheumatology

ANA; antinuclear antibodies

CK; creatine kinase

CMAS; childhood myositis assessment scale

CT; computed tomography

DM; dermatomyositis

EULAR; European league against rheumatism

HLA; human leukocyte antigen

IL; interleukin

ILD; interstitial lung disease

JDM; juvenile dermatomyositis

KL-6; Krebs von den Lungen-6

MDA5; melanoma differentiation-associated gene 5

MRI; magnetic resonance imaging

MSAs; myositis-specific autoantibodies

NXP2; nuclear matrix protein 2

RP; rapidly progressive

SAE; small ubiquitin-like modifier 1 activating enzyme

SRP; signal recognition particle

SUMO-1; small ubiquitin-like modifier 1

TIF1; transcriptional intermediary factor 1

UK; United Kingdom

Declarations

Ethics approval and consent to participate: The report was conducted in compliance with the Declaration of Helsinki, and written informed consent was obtained from the patient. The IRB/Ethics Committee ruled that an approval was not required for publishing this case report.

Consent for publication: Publication consent was obtained from the patient and her guardian.

Availability of data and materials: Not applicable.

Competing interests: The authors declare that they have no competing interests.

Funding: No funding.

Authors' contributions: TK planned and carried out the patients' treatment, and wrote the manuscript. YT, KM and TM planned and carried out the patients' treatment and helped draft the manuscript. NO and YI performed the autoantibody examination and contributed critical revisions of the manuscript. MH contributed critical revisions of the manuscript for important intellectual content. SN participated in the patients' treatment and contributed critical revisions of the manuscript for important intellectual content. All authors read and approved the final manuscript.

Acknowledgements: We would like to thank Dr. Toru Igarashi (Nippon Medical School) for referring this patient to us. We also would like to thank Editage (www.editage.com) for English language editing.

References

1. Rider LG, Shah M, Mamyrova G, Huber AM, Rice MM, Targoff IN, et al. The myositis autoantibody phenotypes of the juvenile idiopathic inflammatory myopathies. Medicine. 2013;92(4):223-43.
2. Rider LG, Nistala K. The juvenile idiopathic inflammatory myopathies: pathogenesis, clinical and autoantibody phenotypes, and outcomes. J Intern Med. 2016;280(1):24-38.
3. Betteridge ZE, Gunawardena H, Chinoy H, North J, Ollier WE, Cooper RG, et al. Clinical and human leucocyte antigen class II haplotype associations of autoantibodies to small ubiquitin-like modifier enzyme, a dermatomyositis-specific autoantigen target, in UK Caucasian adult-onset myositis. Annals of the rheumatic diseases. 2009;68(10):1621-5.
4. Fujimoto M, Matsushita T, Hamaguchi Y, Kaji K, Asano Y, Ogawa F, et al. Autoantibodies to small ubiquitin-like modifier activating enzymes in Japanese patients with dermatomyositis: comparison with a UK Caucasian cohort. Annals of the rheumatic diseases. 2013;72(1):151-3.
5. Muro Y, Sugiura K, Akiyama M. Low prevalence of anti-small ubiquitin-like modifier activating enzyme antibodies in dermatomyositis patients. Autoimmunity. 2013;46(4):279-84.
6. Tarricone E, Ghirardello A, Rampudda M, Bassi N, Punzi L, Doria A. Anti-SAE antibodies in autoimmune myositis: identification by unlabelled protein immunoprecipitation in an Italian patient cohort. Journal of Immunological Methods. 2012;384(1-2):128-34.
7. Bodoki L, Nagy-Vincze M, Griger Z, Betteridge Z, Szollosi L, Danko K. Four dermatomyositis-specific autoantibodies-anti-TIF1gamma, anti-NXP2, anti-SAE and anti-MDA5-in adult and juvenile patients with idiopathic inflammatory myopathies in a Hungarian cohort. Autoimmun Rev. 2014;13(12):1211-9.
8. Ge Y, Lu X, Shu X, Peng Q, Wang G. Clinical characteristics of anti-SAE antibodies in Chinese patients with dermatomyositis in comparison with different patient cohorts. Sci Rep. 2017;7(1):188.

9. Betteridge Z, McHugh N. Myositis-specific autoantibodies: an important tool to support diagnosis of myositis. J Intern Med. 2016;280(1):8-23.
10. DeWane ME, Waldman R, Lu J. Dermatomyositis: Clinical features and pathogenesis. Journal of the American Academy of Dermatology. 2020;82(2):267-81.
11. Tansley SL, Simou S, Shaddick G, Betteridge ZE, Almeida B, Gunawardena H, et al. Autoantibodies in juvenile-onset myositis: Their diagnostic value and associated clinical phenotype in a large UK cohort. J Autoimmun. 2017;84:55-64.
12. Deakin CT, Yasin SA, Simou S, Arnold KA, Tansley SL, Betteridge ZE, et al. Muscle Biopsy Findings in Combination With Myositis-Specific Autoantibodies Aid Prediction of Outcomes in Juvenile Dermatomyositis. Arthritis Rheumatol. 2016;68(11):2806-16.
13. Inoue S, Okiyama N, Shobo M, Motegi S, Hirano H, Nakagawa Y, et al. Diffuse erythema with 'angel wings' sign in Japanese patients with anti-small ubiquitin-like modifier activating enzyme antibody-associated dermatomyositis. Br J Dermatol. 2018;179(6):1414-5.
14. Lundberg IE, Tjarnlund A, Bottai M, Werth VP, Pilkington C, Visser M, et al. 2017 European League Against Rheumatism/American College of Rheumatology classification criteria for adult and juvenile idiopathic inflammatory myopathies and their major subgroups. Annals of the rheumatic diseases. 2017;76(12):1955-64.
15. Shah M, Mamyrova G, Targoff IN, Huber AM, Malley JD, Rice MM, et al. The clinical phenotypes of the juvenile idiopathic inflammatory myopathies. Medicine. 2013;92(1):25-41.
16. Targoff IN, Mamyrova G, Trieu EP, Perurena O, Koneru B, O'Hanlon TP, et al. A novel autoantibody to a 155-kd protein is associated with dermatomyositis. Arthritis and rheumatism. 2006;54(11):3682-9.
17. Rouster-Stevens KA, Pachman LM. Autoantibody to signal recognition particle in African American girls with juvenile polymyositis. Journal of Rheumatology. 2008;35(5):927-9.
18. Kobayashi N, Takezaki S, Kobayashi I, Iwata N, Mori M, Nagai K, et al. Clinical and laboratory features of fatal rapidly progressive interstitial lung disease associated with juvenile dermatomyositis. Rheumatology (Oxford). 2015;54(5):784-91.
19. Betteridge Z, Gunawardena H, North J, Slinn J, McHugh N. Identification of a novel autoantibody directed against small ubiquitin-like modifier activating enzyme in dermatomyositis. Arthritis Rheum. 2007;56(9):3132-7.
20. Gono T, Tanino Y, Nishikawa A, Kawamata T, Hirai K, Okazaki Y, et al. Two cases with autoantibodies to small ubiquitin-like modifier activating enzyme: A potential unique subset of dermatomyositis-associated interstitial lung disease. Int J Rheum Dis. 2019;22(8):1582-6.
21. Kobayashi I, Okura Y, Yamada M, Kawamura N, Kuwana M, Ariga T. Anti-melanoma differentiation-associated gene 5 antibody is a diagnostic and predictive marker for interstitial lung diseases associated with juvenile dermatomyositis. The Journal of pediatrics. 2011;158(4):675-7.
22. Nakashima R, Hosono Y, Mimori T. Clinical significance and new detection system of autoantibodies in myositis with interstitial lung disease. Lupus. 2016;25(8):925-33.

23. Gono T, Sato S, Kawaguchi Y, Kuwana M, Hanaoka M, Katsumata Y, et al. Anti-MDA5 antibody, ferritin and IL-18 are useful for the evaluation of response to treatment in interstitial lung disease with anti-MDA5 antibody-positive dermatomyositis. Rheumatology(Oxford). 2012;51(9):1563-70.

Figures

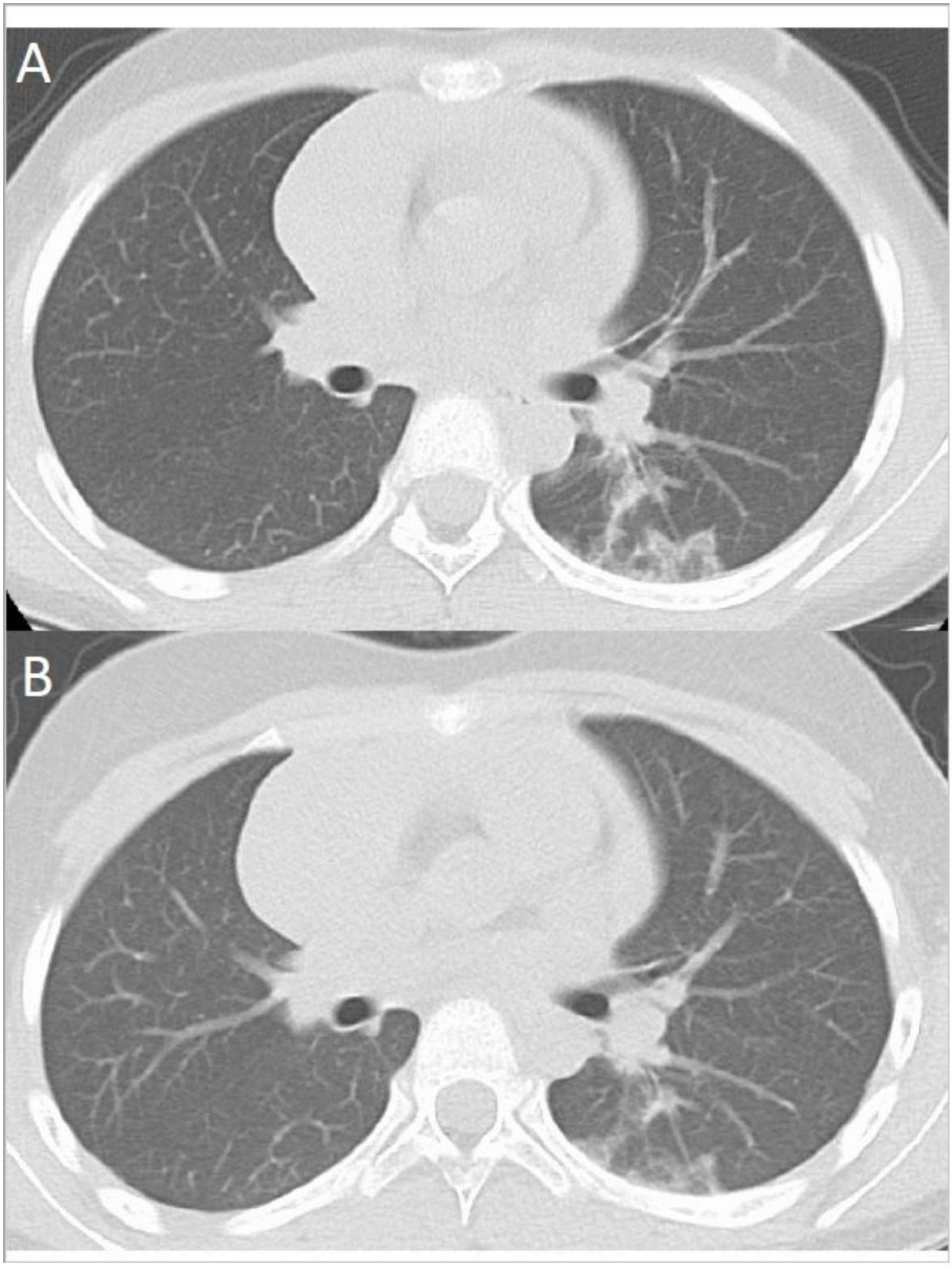

Figure 1

Chest computed tomography (CT) findings A: A ground-grass opacity was observed in the left segment 6 under the visceral pleura before treatment. B: Ground-grass opacity was slightly improved but not progressive 18 months after treatment initiation.