# MIPO For Complex Comminuted Bone Fractures in the Floating Knee IIC According Fraser: a Case Report

**Chuangang Peng**
Jilin University Second Hospital
**Guangkai Ren**
Jilin University Second Hospital
**Minghan Dou**
Jilin University Second Hospital
**Baoming Yuan**
Jilin University Second Hospital
**Dankai Wu** ( wudk@jlu.edu.cn )
Jilin University Second Hospital

---

**Case report**

**Keywords:** case report, complex comminuted bone fractures, femoral mid-distal segments, floating knee

**Posted Date:** September 3rd, 2021

**DOI:** https://doi.org/10.21203/rs.3.rs-841367/v1



---

# Abstract

**Objective:**

Floating knee type IIC according to Fraser's classification is an uncommon severe injury that typically occurs in polytrauma. In this case, mainly due to both intraarticular fracture and the high degree of comminution and malformation on the femoral mid-distal segments, fixation was challenging. The purpose of this study was to prove that minimally invasive plate osteosynthesis (MIPO) technology can simplify complex problems and improve prognosis.

**Case Presentation:**

A 38-year-old man injured his left leg in a car accident, causing pain, swelling, deformity, and limited mobility on his left knee and thigh, and two small open wounds were noted mainly on the anterior aspect of the mid-distal thigh. Physical examination and lower limb computed tomography angiography (CTA) confirmed that the neurovascular status was normal. The clinical diagnosis were closed intraarticular fracture of the proximal tibia, open intraarticular fracture of the distal femur with extension to the diaphysis, and a patellar fracture on the ipsilateral knee.

In this case, a locking plate system characterized by minimally invasive plate osteosynthesis (MIPO) technology was used as the treatment.

**Results and Conclusion:**

Postoperative evolution was satisfactory, with immediate functional exercise, full weight bearing after three months, and return to daily activity without pain. Final follow-up taken at 3 years showed good lower limb alignment and complete plasticity of the bone structure, by which time the patient showed good limb function. Minimally invasive techniques can provide a simple and effective treatment for some complex fractures.


# Introduction

Ipsilateral fractures of the femur and tibia, also known as the floating knee, are uncommon severe injuries that typically occur in polytrauma. In some series, poorer results have been reported, especially when both fractures are intraarticular (floating knee type IIC according to Fraser's classification)[1]. In such cases, operative treatment is mandatory to restore the articular congruency and overall alignment of the leg. Recent reports have shown that surgical stabilization of both fractures and early mobilization can avoid most complications and achieve the best clinical results.[2, 3, 4]

The purpose of this study was to evaluate the perioperative results and functional outcomes following operative treatment in a case of severe floating knee. In this case, the most characteristic fracture was the complex comminuted bone fractures of the femoral mid-distal segments; and mainly owing to the high degree of comminution and malformation, the fixation was challenging.

### Ethical approval

The study was conducted in accordance with the principles outlined in the Declaration of Helsinki and was approved by the Ethics Committee of the Second Hospital of Jilin University. The patient provided written informed consent for participation. Data anonymity was maintained to protect patient privacy.

## Case Presentation

### 3.1 Patient characteristics

A 38-year-old man injured his left leg in a car accident, sustaining a closed intraarticular fracture of the proximal tibia and open intraarticular fracture of the distal femur with extension to the diaphysis. A patellar fracture was observed in the ipsilateral knee. Two small open wounds were noted mainly on the anterior aspect of the mid-distal femur. The level of contamination was minimal, and there were no soft tissue defects that needed to be covered with a flap. The initial management consisted of debridement and application of skeletal traction. The soft tissue settled after a week. Physical examination and lower limb computed tomography angiography (CTA) confirmed that the neurovascular status was normal. This patient denied any previous illness or surgery history, and none of the family members had any inherited diseases.

Preoperative radiographs show a multifragmentary fracture of the distal femur involving both condyles and extending into the diaphysis. A sagittal split of the medial condyle was observed. Three-dimensional CT scans showed the extent and location of the articular fractures (Fig. 1). Furthermore, the medial condyle fracture was separated and displaced. Long-stage comminuted bone fractures of the femoral mid-distal segments are the most complex part of the operation. Supracondylar and shaft fracture of the left femur exposed Gustilo Anderson (GA) II and minor bone loss of the metaphyseal area was < 5%.

The distal femoral fracture was classified as type 31C3.3, and the patellar fracture was classified as type 34B2.2 (according to the AO and the Orthopaedic Trauma Association [OTA] system); the proximal tibia fracture was classified as type IV (according to Schatzker type).

### 3.2. Surgical procedures

Operative treatment was mandatory to restore the articular congruency and the overall alignment of the leg. Because this was an open fracture, debridement of the wound and skeletal traction were planned as the initial management. Intramedullary nailing was difficult to use because of fracture morphology. In this case, we chose the MIPO technique for the treatment of complex floating knee injuries (Fig. 2).

After induction of general anesthesia, the patient was positioned supine on a radiolucent table with both legs draped free and a support placed under the injured knee. The medial parapatellar approach was adopted, and decision making was dependent on the location of the sagittal fracture separation of the femoral medial articular surface. The medial parapatellar approach was also useful for fixation of an associated patellar fracture (34 B2.2). After the patella was repositioned, two 2.0-mm cortical bone

screws were used to fix the patella fracture. Tibial fractures (Schatzker IV) were treated using the medial patella approach combined with the MIPO technique. Indirect percutaneous articular reduction with pointed reduction forceps was performed and a subchondral raft of 4.5-mm cancellous screws was used. A locking medial plate was slid through the medial parapatellar approach, and percutaneous locking screws were inserted to complete the fixation.

This article focuses on the treatment of femoral mid-distal segments using the distal femoral lock compression plate (LCP-DF) using the MIPO technique. Through the medial parapatellar approach, slight eversion of the patella and flexion of the knee exposes the distal articular surface, particularly of the medial femoral condyle, thereby enabling reduction and fixation of the articular fractures. Large pointed reduction forceps were useful to hold the medial and lateral femoral condyles together after reduction. A Kirschner wire was inserted into the medial condyle for temporary fixation of the articular surface fractures. The distal femoral fracture changed from C3 to A3.

For extraarticular fractures, a modified standard lateral approach was used. The implant was slipped into a submuscular tunnel along the lateral cortex of the femur. A minimum 7-hole–length coverage over the shaft fixation with five screws was optimum. The screw cannot be placed in the middle segment. Therefore, in this case, a 14-hole LCP-PLT was chosen. The distal part of the LCP-DF was aligned according to the anatomical reference with the distal femur, and the proximal part of the plate then ran along the femoral shaft. To obtain a closed reduction, traction was performed after temporary fixation of the femoral condyle with the distal part of the plate. Manual traction was applied to the ankle with a force vector that was directed posteriorly using the supracondylar pad as a fulcrum to help reduce the fracture and restore limb length and rotational and axial alignments. Fluoroscopic images were rechecked. Final fixation was achieved using locking screws at either end of the plate. A total of seven 5.0-mm locking screws were placed into the distal fragment and five screws were placed in the shaft fragment. This construct aimed to combine absolute stability with fixed angle stability and relative stability using bridging technology. After fixation, the stability of the knee joint should always be checked. Limb length, axes, and rotation were checked using clinical and radiological methods.

Bone defects were observed in the middle fragment. Bone grafting to correct the fragment loss was not performed, because the loss did not affect the length and alignment of the femur, and the entire construct had a stable and balanced fixation as previously described.

A final check of fracture reduction and fixation was performed using the image intensifier. Overall, the construct achieved a balanced and adequate fixation. After internal fixation, passive exercises were performed on the patient under anesthesia.

### 3.3. Outcomes and follow-up

Postoperative 3D CT and radiography confirmed that the intraarticular fractures underwent anatomic reduction, and the left femur line was restored, with internal fixation in a good position. However, there were three unreduced reverse fragments (1, 2 and 3) in the femoral mid-distal segment after plating (Fig.

3 a-e). On the first postoperative day, the patient began continuous passive range-of-motion (ROM) exercises under the guidance of an orthopedic surgeon. The patient was allowed to walk on crutches with toe-touch weight-bearing during the first 6 weeks. Because of the need for functional exercise, the unreduced reverse fragment (3) was removed through small incisions 1.5 month postoperatively. Depending on fracture consolidation visible on the radiographs 1.5 month, weight bearing is progressively increased to full weight bearing at 3 months. Radiographic examination at 3 months showed no displacement at the fracture end, and the fracture line was blurred by the formation of a large amount of callus. A further radiographic examination at 1 year showed good lower limb alignment and good plasticity of the bone structure. Final follow-up taken at 3 years showed good lower limb alignment and complete plasticity of the bone structure, by which time the patient showed good limb function (acceptable range of knee motion of 0°–100° was achieved). Although fractures of the middle and lower femur have healed, the bone strength is insufficient ; hence, implant removal will not be considered (Fig. 3 i-r).

# Discussion

“Floating knee” injury is often the result of high-energy trauma, which may lead to complex fractures and extensive soft-tissue injuries[(4)]. In our case, we encountered ipsilateral fractures of the tibial plateau and femoral condyle featuring extensive articular involvement, which are very rare in floating knee type IIc injuries (Fraser’s classification). In particular, the extremely comminuted fracture morphology of the mid-distal femur is clinically rare. Reconstruction of complex comminuted bone fractures of femoral mid-distal segments by means of open reduction is technically challenging and can lead to a significant stripping of soft tissue. Successful surgery depends on effective reduction and internal fixation of the fracture with maximal preservation of the blood supply at the fracture site[(5)].

Minimally invasive osteosynthesis is a commonly performed technique designed to provide stable internal fixation through a minimally invasive surgical technique. In this fracture pattern, intramedullary nailing is difficult because of the fracture morphology that involves the articular surface. Minimally invasive plate osteosynthesis (MIPO) is the preferred approach in clinical situations where the fracture involves the articular surface.

For complex comminuted bone fractures, flexible fixation using the bridge plate concept without touching the fracture zone is preferred. The length of the fracture comminution usually determines the bridging length or working length of the plate. A plate with insufficient supporting length is presumed to be the main cause of fracture nonunion and internal fixation fractures[(6)]. Again, as the patient in this report had comminuted distal femoral fractures with diaphyseal involvement comprising a large segmental component, plates of appropriate length were chosen to achieve mechanical sound fixation, which is the key to allowing healing through callus formation. Hence, we chose a 14-hole plate for our patient according to these principles to achieve a ‘balanced fixation construct’. In addition, one anatomical study showed some discrepancies between the side plate and femoral shaft[(7)]. Because of this possible mismatch, surgeons may have to consciously accept a certain gap between the plate and the bone when

using a 9-hole or longer LCP-DF. In our case, there was a clear gap between the 14-hole plate and the femoral diaphyseal fracture. The LCP is fixed to the bone and a space of 0.5–1 cm between the bone and the plate is left to preserve the periosteum. In the case of multifragmentary fractures with relative stability, the reserved gap allows micromotion to induce callus formation.

A decision on whether an additional medial plate should be added must be made during the operation. Double plating proved stronger than single lateral plate in biomechanical testing, but it was not superior to traditional lateral plating with respect to clinical outcomes [8–10]. In our patient, we decided not to add a medial plate for the following reasons: the single lateral locking plate was strong enough to maintain sufficient stability to allow functionality after treatment. Furthermore, the double plate technique is associated with the risk of delayed union or nonunion due to extensive soft-tissue dissection and periosteal injury, even when performed by skilled operators. When the overall structure is balanced and stable, lateral-only locked plates can reduce surgical time, blood loss and limit soft-tissue stripping.

Restoration of limb alignment is critical for the stabilization of complex floating knee injuries to produce an optimal outcome. Malalignment of the femur and tibia in any plane can lead to abnormal load transmission across the adjacent joints, resulting in shearing of the articular cartilage and development of earlier joint arthrosis, leading to clinically relevant degenerative changes.[11, 12] However, with respect to the metaphyseal/diaphyseal component, clinicians should be more willing to accept the basic restoration of the femoral line rather than the anatomic reduction of all fracture fragments. A minor residual gap after closed reduction does not seem to result in a higher risk of nonunion; however, in the open technique, anatomical reduction of all these small pieces is extremely challenging and risks devitalizing the free bone fragments.[4, 13] In our patient, there were three free fragments that represented a reversed morphology, in that the endosteum was turned inside out. It is possible that neo-vascularization to the callus was compromised as the periosteal callus was set in the opposite direction given the reversed morphology[14]. One of the unreduced reverse fragments was removed 1.5 months after surgery, and the remaining two fragments began to show signs of necrotic absorption three months after surgery, until they were completely absorbed. Finally, an acceptable healing strength was achieved for the entire lower limb.

The advantages of indirect fracture reduction and submuscular plating in the treatment of floating knee injury lie in the fact that the soft tissue envelope surrounding the fracture remains largely intact, thus preserving the biology and enhancing the chances of fracture union, reducing the need for bone grafting and the incidence of infection. The surgical technique described in this report had some limitations. First, the style of bone graft requiring adequate exposure of the graft site in the metadiaphyseal component is limited by the minimally invasive incision in MIPO technology. Second, minimally invasive techniques with indirect fracture reduction can lead to higher rates of limb malalignment, and improved reduction methods to avoid deformity, especially malrotation, and repeated intraoperative fluoroscopy to check the restoration should be advocated. Third, the anterior unreduced reverse fragment affected the knee flexion movement in the early postoperative period, because its tip was inserted into the quadriceps muscle (Fig.

3 f-h). Finally, with the reduced bone mass, the healing strength of a femoral fracture is partially affected; thus, implant removal is prone to refracture.

## Conclusions

The advantages of MIPO for treating complex floating knee injuries are rapid and optimal healing, minimization of soft-tissue complications and loss of function, and prevention of nonunion or malunion. In particular, the recommended current method of a single lateral locking plate using MIPO technology has ensured good outcomes for comminuted bone fractures of the femoral mid-distal segments.

## Declarations

The authors have no conflicts of interest to declare that are relevant to the content of this article. No funding was received to assist with the preparation of this manuscript. The study was conducted in accordance with the principles outlined in the Declaration of Helsinki and was approved by the Ethics Committee of the Second Hospital of Jilin University. The patient provided written informed consent for participation. Data anonymity was maintained to protect patient privacy. The datasets used and analysed during the current study are available from the corresponding author on reasonable request. All authors consent for publication. Chuangang Peng mainly writes papers. Minghan Dou and Guangkai Ren were responsible for postoperative follow-up and making pictures. Baoming Yuan and Dankai Wu revised articles and conducted scientific evaluation. No acknowledgements.

## References


1. Hung SH, Chen TB, Cheng YM, Cheng NJ, Lin SY. Concomitant fractures of the ipsilateral femur and tibia with intra-articular extension into the knee joint. J Trauma. 2000;48(3):547-51.
2. Lundy DW, Johnson KD. "Floating knee" injuries: ipsilateral fractures of the femur and tibia. J Am Acad Orthop Surg. 2001;9(4):238-45.
3. Kao F-C, Tu Y-K, Hsu K-Y, Su J-Y, Yen C-Y, Chou M-C. Floating knee injuries: a high complication rate. Orthopedics. 2010;33(1):14-.
4. Rethnam U, Yesupalan RS, Nair R. The floating knee: epidemiology, prognostic indicators & outcome following surgical management. J Trauma Manag Outcomes. 2007;1(1):2-.
5. Krettek C, Muller M, Miclau T. Evolution of minimally invasive plate osteosynthesis (MIPO) in the femur. Injury. 2001;32:14-23.
6. Liu H, Yuan BM, Yu T, Ren GK, Zhang Y, Wu Y, et al. Accurate fixation of complicated comminuted femur fracture with customized LCP referencing a life-size 3D-printed model: a case report. Ann Transl Med. 2020;8(7):9.
7. Hwang J-H, Oh J-K, Oh C-W, Yoon Y-C, Choi HW. Mismatch of anatomically pre-shaped locking plate on asian femurs could lead to malalignment in the minimally invasive plating of distal femoral fractures: a cadaveric study. Arch Orthop Trauma Surg. 2012;132(1):51-6.

8. Epari DR, Gurung R, Hofmann-Fliri L, Schwyn R, Schuetz M, Windolf M. Biphasic plating improves the mechanical performance of locked plating for distal femur fractures. J Biomech. 2021;115:110192-.
9. El Beaino M, Morris RP, Lindsey RW, Gugala Z. Biomechanical Evaluation of Dual Plate Configurations for Femoral Shaft Fracture Fixation. Biomed Res Int. 2019;2019:7.
10. Zhang J, Wei Y, Yin W, Shen Y, Cao S. Biomechanical and clinical comparison of single lateral plate and double plating of comminuted supracondylar femoral fractures. Acta Orthop Belg. 2018;84(2):141-8.
11. Kettelkamp DB, Hillberry BM, Murrish DE, Heck DA. Degenerative arthritis of the knee secondary to fracture malunion. Clin Orthop Relat Res. 1988(234):159-69.
12. Buckley R, Mohanty K, Malish D. Lower limb malrotation following MIPO technique of distal femoral and proximal tibial fractures. Injury. 2011;42(2):194-9.
13. Nayak RM, Koichade MR, Umre AN, Ingle MV. Minimally invasive plate osteosynthesis using a locking compression plate for distal femoral fractures. J Orthop Surg (Hong Kong). 2011;19(2):185-90.
14. Lin S-J, Chen C-L, Peng K-T, Hsu W-H. Effect of fragmentary displacement and morphology in the treatment of comminuted femoral shaft fractures with an intramedullary nail. Injury. 2014;45(4):752-6.

# Figures

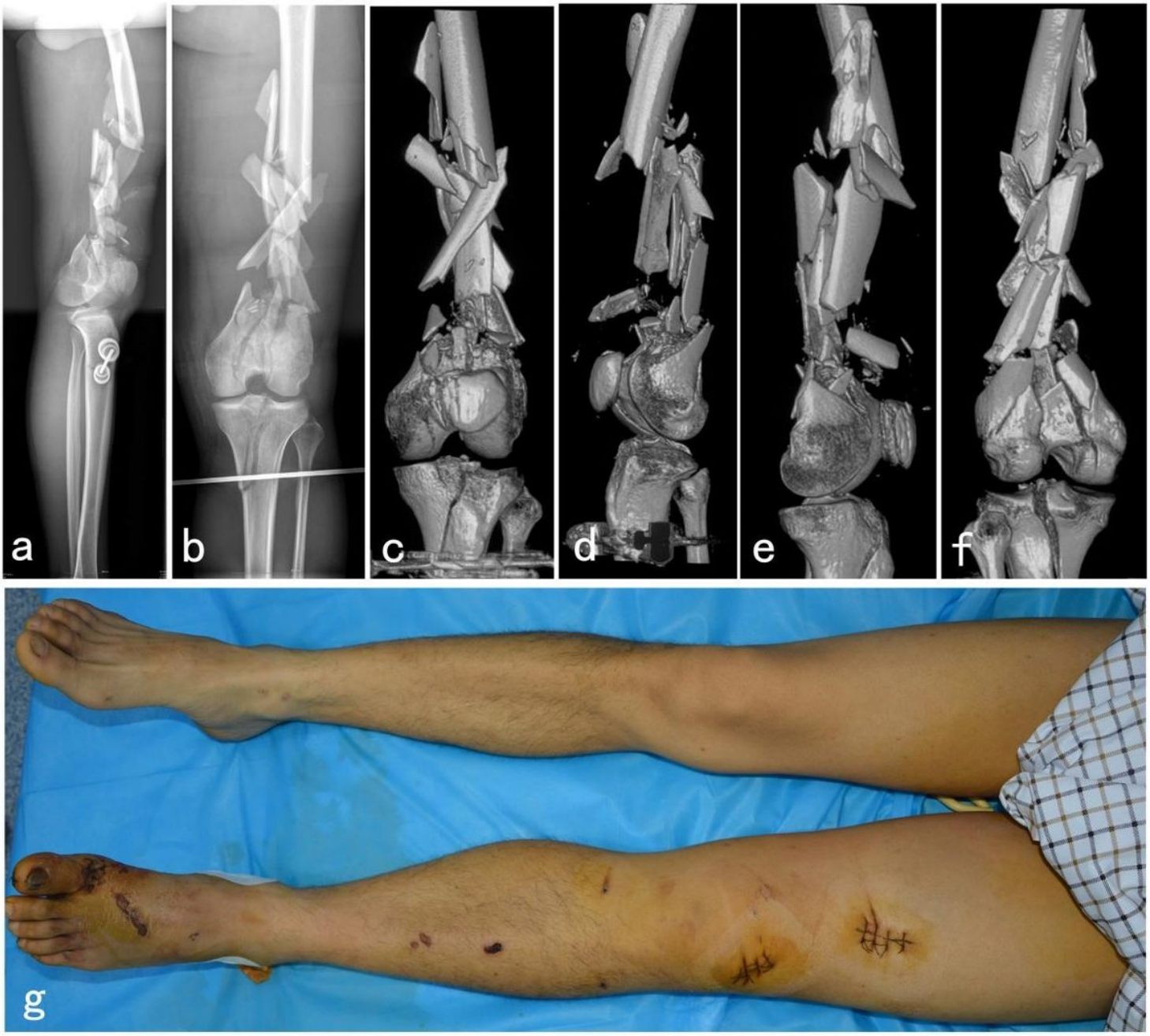


**Figure 1**

a–b: preoperative radiographs: anterior view and lateral view of the lower limb; c–f: preoperative three-dimensional CT scans; g: preoperative soft-tissue condition around the knee joint.

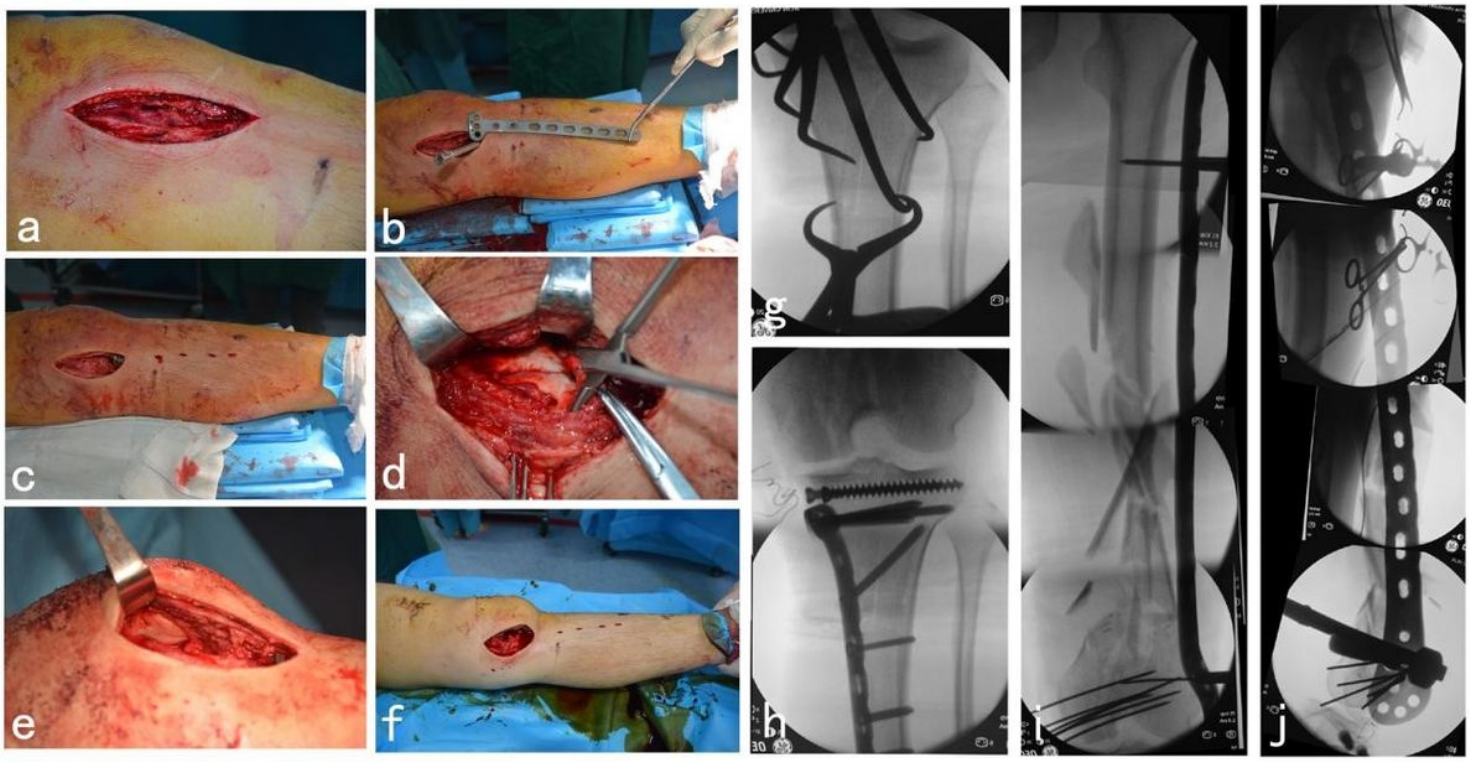


**Figure 2**

a: medial parapatellar approach; b–c: percutaneous placement of the proximal medial tibia plate; d: reduction and temporary fixation of femoral condyle fracture under direct vision; g–h: intraoperative imaging showing reduction and fixation of tibial plateau fractures; e: exposing and fixing the patellar fracture; f: a modified standard lateral approach; i–j: Intraoperative fluoroscopy of the femoral fracture force line and plate position.

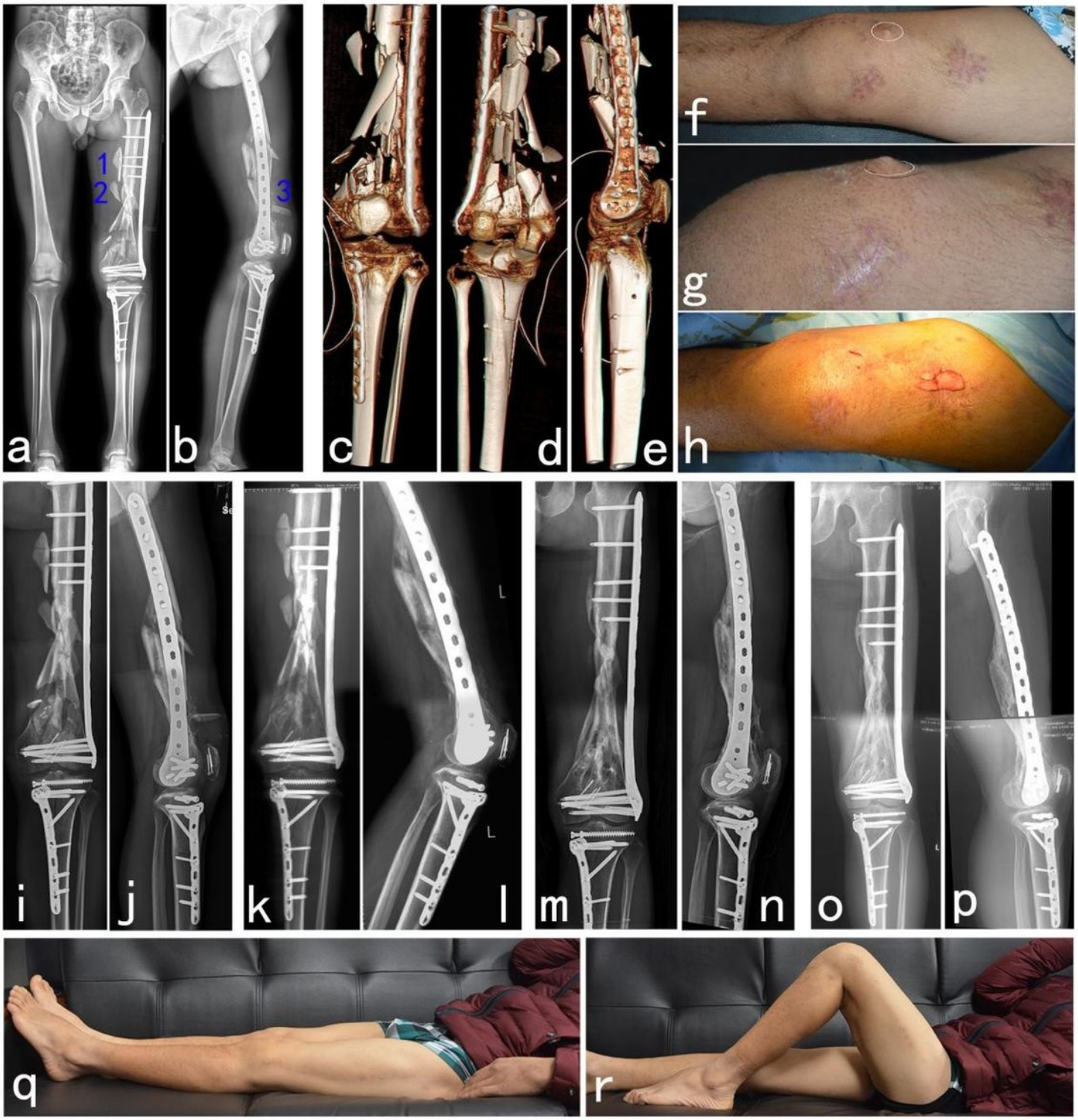


**Figure 3**

a–e: Immediate postoperative radiographs and three-dimensional CT scans demonstrate correct mechanical axis and good plate position. f–g: unreduced reverse fragment of the femoral metaphysis; h: the bone fragments were removed through small incisions at 1.5 months postoperatively. i–p: Radiographic examinations at follow-up. 1.5 months (i–j), 3 months (k–l), 1 years (m–n), and 3 years(o–p) post-operation. q–r: Clinical images showing functional outcomes at the last follow-up.