Laparoscopy or Laparotomy for High-risk Caesarean Scar Pregnancy: A Retrospective Study

Ting Zhou
Tongji Hospital, Tongji Medical College, Huazhong University of Science and Technology
Shixuan Wang
Tongji Hospital, Tongji Medical College, Huazhong University of Science and Technology
Peiying Fu
Tongji Hospital, Tongji Medical College, Huazhong University of Science and Technology
Pengfei Cui
Tongji Hospital, Tongji Medical College, Huazhong University of Science and Technology
Ronghua Liu (Liuzhu38@126.com)
Tongji Hospital, Tongji Medical College, Huazhong University of Science and Technology

Research Article

Keywords: caesarean scar pregnancy, hysterotomy, laparoscopy, laparotomy, arterial occlusion

Posted Date: September 7th, 2021

DOI: https://doi.org/10.21203/rs.3.rs-842213/v1

Abstract

Background: Caesarean scar pregnancy (CSP) can have catastrophic consequences. A standardized diagnosis and treatment for CSP are still lacking. The currently available treatment methods are confusing, and at least 10 different treatment measures exist. The aim of this study was to compare the outcomes of with laparotomy or laparoscopy in the treatment of high-risk CSP.

Methods: We reviewed 935 patients with CSP from 1 January 2013 and 31 December 2018. A total of 278 patients were included in the study, of whom 121 were treated with laparoscopy and 157 were treated with laparotomy.

Results: We compared and analysed the characteristics of the laparoscopic and open surgeries in the treatment of high-risk CSP and the advantages and disadvantages of different methods of vascular pretreatment. Intraoperative bleeding, transfusion rate, total days of hospitalization and postoperative hospital stay were better in laparoscopy than in laparotomy ($P < 0.05$). There was no difference in the factors (β-HCG decrease, reoperation and tissue residues) closely related to the success of the surgery in the two groups. Furthermore, we pretreated blood vessels differently before the operation in some patients. Tissue residue, reoperation and intraoperative blood transfusion rates in patients with temporary vascular occlusion were better than in patients with permanent vascular occlusion.

Conclusions: This study revealed that laparoscopic surgery is superior to laparotomic surgery in the treatment of high-risk CSP. Patients benefited from temporary arterial occlusion in both groups. Temporary arterial occlusion under laparoscopic surgery may be the best treatment for high-risk CSP.

Introduction

Caesarean scar pregnancy (CSP) is a rare form of ectopic pregnancy that can have potentially catastrophic consequences, including massive bleeding, uterine rupture and even life-threatening events. Compared with placenta implantation alone without uterine scarring, in CSP, implantation in the scar tissue that is deficient in myometrium results in poor contractility, which may carry additional risks and further aggravate haemorrhage [1–3]. CSP also has been linked with the risk of placenta accreta spectrum (PAS) [4]. There are several methods for classifying CSP. Vial et al classified CSP according to the degree of implantation of the gestational sac into the uterine scar tissue and the direction of gestational sac growth [5]. Chinese experts classified CSP into three types according to scar thickness and gestational sac location [6]; however, there is a lack of data and quantitative indicators to guide clinical treatments of CSP that are conducive to the actual operation. Furthermore, in a large part of the literature, CSP is not classified.

There are no standardized global guidelines or consensuses for dealing with CSP. At present, popular treatment methods for CSP include the ultrasound-guided direct injection of methotrexate (MTX), potassium chloride or absolute ethanol into the embryonic sac, the bilateral uterine artery injection of MTX, the intramuscular or systemic injection of MTX alone or in combination with dilatation and

curettage (D&C) guided by ultrasonography, hysteroscopy or laparoscopy [7, 8]. In addition, high-intensity focused ultrasound followed by ultrasound-guided D&C has also been used for the treatment of CSP [9, 10]. Finally, transabdominal and laparoscopic approaches have been used to perform hysterotomy or even hysterectomy [11]. However, conservative treatments do not alter the thin or defective muscular layers in CSP and instead only aggravate the condition of the muscular layer. Should these types of CSP be positively treated with surgery for repair and reconstruction of the defective muscular layer of the lower segment of the uterus?

Many scholars believe that hysterotomy could be used not only to remove the pregnancy but also to repair defects in the lower uterine segment. Therefore, Fylstra indicated that it may be the best treatment option for CSP[12]. First, laparotomy is available in almost all hospitals, and some patients had to switch to open surgery because of uncontrollable bleeding during laparoscopic surgery. On the other hand, laparoscopic surgery is safe for the removal of pregnancy tissue, requires a short in-hospital stay and results in little blood loss. In addition, many doctors have treated CSP through transvaginal hysterotomy, which is also considered an alternative approach for treating this condition. There are currently no studies in the literature comparing hysterotomy with laparotomy and laparoscopy in the treatment of CSP.

The goal of this study was to explore the evaluation and necessity of the surgical treatment of CSP and to compare the advantages and disadvantages of laparoscopic and laparotomic surgery.

Materials And Methods

Patients

We retrospectively reviewed patients with CSP at our institution between 1 January 2013 and 31 December 2018, identifying a total of 935 patients suspected of having CSP. The Ethics Committee of the Tongji Hospital, Tongji Medical College, Huazhong University of Science and Technology, approved the study. Among the 278 patients who were eligible for the study, 121 patients were treated with laparoscopy, and 157 patients were treated with laparotomy (Fig. 1).

Diagnostic and inclusion criteria

At present, none of the existing diagnostic or classification methods for CSP are universally acknowledged. The standard adopted by many physicians was proposed by Vial in 2000 (Vial et al., 2000). The inclusion criteria for this study were as follows: (1) a history of lower uterine segment caesarean delivery; (2) amenorrhea; (3) positive serum β-human chorionic gonadotropin (hCG); (4) CSP clinically diagnosed by transvaginal ultrasound, with findings that included an empty cervix and uterine cavity, gestational sac or mixed mass with or without foetal cardiac activity at the anterior wall of the uterine isthmus at the lower uterine incision scar, a visibly absent myometrial layer between the gestational sac and the bladder, or gestational sac implantation or infiltration to the muscular layer in

some cases; (5) postoperative histopathologic confirmation of tissues that prove conception; and (6) treatment with laparoscopy or laparotomy.

Surgical Methods

Laparoscopy

First, the peritoneum was opened, the bladder was pushed aside, and the lower segment of the uterus and the protrusion of the mass were exposed completely. Importantly, the lower boundary needed to exceed the normal cervical tissue by approximately 1.5 cm. This is conducive to subsequent rapid suturing and avoiding damaging the bladder, ureters and uterine arteries, even if massive bleeding occurs. D&C of the uterus was performed by the assistant before the lower uterine scar was cut open. Next, the bulging part of the gestational ectopic mass was wedge-resected, and the scar was trimmed using scissors without any energy modalities. Finally, 1-0 absorbable sutures were employed to perform interrupted suturing of the incision in the myometrium, and the peritoneum was reapproximated.

According to the surgical technique and habits of different surgeons, different methods of vascular pretreatment have been performed for many patients when assessing the risk of massive intraoperative haemorrhage. (1) Uterine artery embolism (UAE): Bilateral UAE was performed using gelatine sponge particles within 24 hours before surgery. (2) Arterial occlusion: After opening the lateral peritoneum and confirming the ureter, the bilateral uterine or internal iliac arteries were exposed. Arteries were occluded by either temporary arterial occlusion with metal vascular clamps or permanent arterial occlusion with clamping or sewing. After suturing the uterine incision, the clips were removed, and the uterine arteries were recanalized. The laparotomic procedure is similar to that of laparoscopic surgery.

Laparotomy

In the more conservative treatment process, if there was a large amount of life-threatening bleeding that was difficult to control during D&C, laparoscopic surgery (mainly for surgeons less skilled in laparoscopic vascular management) or transvaginal surgery, it would be necessary to switch to open surgery quickly, which could prevent serious complications such as hysterectomy and other catastrophic complications (even death). The laparotomic procedure is similar to that of laparoscopic surgery.

In some ways, vascular pretreatment for laparotomy is different from that for laparoscopic surgery. In transabdominal surgery, temporary occlusion of the bilateral uterine arteries was performed to pretreat the vasculature. A rubber tourniquet was passed through the avascular zone on both sides of the broad ligament and was temporarily tied around the uterine isthmus for temporary haemostasis after the bladder was pushed aside. The vascular band was released, and the uterine arteries were recanalized

after the uterine incision was sutured. After the bilateral uterine or internal iliac arteries were exposed, the arteries were double ligated with 1-0 non-absorbable sutures.

Follow-up

The initial follow-up schedule was once per week from the first day after discharge until the serum β-hCG level returned to normal. The first phase of follow-up included measuring vaginal bleeding and serum β-hCG levels, a routine blood test and ultrasonography. During the second phase, the schedule was adjusted to once every three months for one year. The follow-up items included the menstrual status, pregnancy status, ovarian function and endocrine levels in addition to the above items.

Statistical analysis

We used SPSS 17.0 software (SPSS, Inc.) to statistically analyse the data. All data are represented as the mean ± standard deviation (SD). Categorical data are expressed as frequencies. Significance between groups was assessed by the chi-squared test and Fisher's exact test for categorical variables. Multifactor logistic regression analysis were subsequently carried out to analyse the relationship between factors. $P < 0.05$ was considered statistically significant.

Results

Study population

During 2013–2018, 935 women suspected of having CSP were treated at our institution (a major tertiary referral hospital in China). Twenty-nine patients failed to meet the diagnostic criteria of CSP, and 628 patients underwent other types of treatments (Fig. 1). Of the remaining women, 121 (13.35%) underwent laparoscopic surgery, and 157 (17.33%) underwent transabdominal surgery. The baseline characteristics and clinical data of the two groups are presented in Table I. Most of the clinical factors in the two groups, such as age, gestational age, number of abortions, number of caesarean sections, interval from the last caesarean section, main symptoms (vaginal bleeding and abdominal pain), type of CSP (Consensus of Chinese experts in 2016), characteristic features of ultrasound scans (diameter of gestational sac, colour Doppler signal and foetal heart beat) and haematological indicators (haemoglobin and β-hCG levels), were all similar, except for gestational sac width and gestational sac volume.

Table 1
Clinical and sonographic characteristics of women with caesarean scar pregnancy

Characteristics	Laparoscopy	Laparotomy	
	(n = 121)	(n = 157)	*P*-value
Age	31.32 ± 4.92	32.43 ± 4.85	0.4435
<35	93 (76.86%)	112 (71.34%)	
≥35	28 (23.14%)	44 (28.03%)	
Unknown	0 (0.00%)	1 (0.64%)	
Type of CSP			0.1543
I	8 (6.61%)	12 (7.64%)	
II	89 (73.55%)	97 (61.78%)	
III	14 (11.57%)	33 (21.02%)	
Unknown	10 (8.26%)	15 (9.55%)	
Number of abortions			0.9154
0	26 (21.49%)	31 (19.75%)	
1	34 (28.10%)	45 (28.66%)	
2	35 (28.93%)	44 (28.03%)	
≥3	26 (21.49%)	36 (22.93%)	
Unknown	0 (0.00%)	1 (0.64%)	
Number of caesarean sections			0.7715
1	84 (69.42)	113 (71.97%)	
≥ 2	37 (30.58)	43 (27.39%)	
Unknown	0 (0.00%)	1 (0.64%)	
Interval from last CS (y)			0.2942
≤ 1	18 (14.88%)	20 (12.74%)	
2–4	45 (37.19%)	47 (29.94%)	
≥ 5	58 (47.93%)	90 (57.32%)	
Gestational age (d)			0.4396

*CSP, caesarean scar pregnancy; CS, caesarean section; β-HCG, beta human chorionic gonadotropin

Characteristics	Laparoscopy	Laparotomy	
	(n = 121)	(n = 157)	*P*-value
≤ 42	17 (14.05%)	24 (15.29%)	
43–63	70 (57.85%)	79 (50.32%)	
≥ 64	30 (24.79%)	43 (27.39%)	
Unknown	4 (3.31%)	11 (7.01%)	
Diameter of gestational sac (cm)	3.79 ± 1.73	4.42 ± 1.99	0.0066
<2.0	23 (19.01%)	17 (10.83%)	
2.0–4.0	47 (38.84%)	66 (42.04%)	
> 4.0	43 (35.54%)	70 (44.59%)	
Unknown	8 (6.61%)	4 (2.55%)	
Remnant myometrial thickness (cm)	0.17 ± 0.11	0.14 ± 0.16	0.1819
Colour doppler signal			0.1812
Yes	88 (72.73%)	115 (73.25%)	
No	15 (12.40%)	28 (17.83%)	
Unknown	18 (14.88%)	14 (8.92%)	
Foetal heartbeat			0.3832
Yes	38 (31.40%)	59 (37.58%)	
No	74 (61.16%)	91 (57.96%)	
Unknown	9 (7.44%)	7 (4.46%)	
Vaginal bleeding			0.1112
Yes	89 (73.55%)	128 (81.53%)	
No	32 (26.45%)	29 (18.47%)	
Abdominal pain			0.4086
Yes	33 (27.27%)	50 (31.85%)	
No	88 (72.73%)	107 (68.15%)	
Haemoglobin (g/L)	115.50 ± 16.81	112.32 ± 17.73	0.8895
β-HCG (mIU/ml)	42,706.51 ± 48,242.58	43,649.28 ± 53,045.41	0.1315

*CSP, caesarean scar pregnancy; CS, caesarean section; β-HCG, beta human chorionic gonadotropin

Comparison of clinical outcomes between the two groups

The main outcomes from the perioperative period in the two groups are shown in Fig. 2. Of 906 patients, 146 underwent two or more types of therapies. Because of massive vaginal bleeding during the treatment of these women, these patients were transferred to open or laparoscopic surgery. The number of patients who underwent combined treatments in the laparoscopy group was greater than that in the laparotomy group ($p < 0.001$, Fig. 2C). It is remarkable that the intraoperative bleeding volume in the transabdominal surgery group was obviously greater than that in the laparoscopic surgery group (Fig. 2A, 2D). Due to the differences between the two groups in gestational sac diameter, width and area (Table 1), we used multifactor logistic regression analysis to analyse the relationship between these factors and the intraoperative bleeding volume of the different surgical methods. Moreover, the three factors were collinear and should not be included in the multivariate analysis. Therefore, we only included the gestational sac diameter as a factor and analysed its relationship with the operation method. According to the analysis, the bleeding risk for laparotomy was 1.78 times higher than that for laparoscopy given the same gestational sac diameter (Table 2).

In addition, two indicators of surgical success (postoperative haemoglobin and β-hCG decline) were not different between the two groups. We also found that the transfusion rate in the transabdominal surgery group was higher than that in the laparoscopic surgery group (Fig. 2A). Finally, when we analysed the postoperative data, there were no statistically significant differences between the two groups. The total number of days of hospitalization and postoperative hospitalization in the laparoscopic group were lower than those in the transabdominal group (Fig. 2D).

Table 2
Relationship between the gestational sac diameter and the intraoperative bleeding volume of the two surgical methods analysed by multifactor logistic regression analysis

	β	OR	Wald	*P*	95% CI
Operative method					
Laparoscopy	0	1			
Laparotomy	0.58	1.78	4.83	0.03	1.06–2.97
Diameter of gestational sac (cm)					
≤ 2.1	0	1			
2.2–3.1	0.29	1.34	0.40	0.53	0.54–3.30
3.2–4.3	0.49	1.64	1.22	0.27	0.68–3.9
> 4.3	0.86	2.36	4.45	0.03	1.06–5.22

Clinical outcomes of different methods of artery pretreatment in the two groups

In both groups, we pretreated the blood vessels differently before the operation in some patients. In the laparoscopy group, the incidence of residual tissue, reoperation, pain and transfusion was lower for patients who underwent temporary arterial occlusion than for patients who underwent no artery pretreatment, UAE or permanent arterial occlusion (Fig. 3). It is worth mentioning that the transfusion rate reached 42.86% during the operation after UAE treatment (Table 3). The differences in the rates of residual tissue, reoperation and transfusion were statistically significant in the laparotomy group, which was similar to the laparoscopy group (Table 4). However, the transfusion rate (41.67%) for permanent vascular occlusion was less than that for the other three arterial pretreatments (77.69%, 72.22% and 73.33%). It should be noted that the majority of patients who chose laparoscopic or open surgery were categorized as having type II (Vial et al) or type III (consensus of China) CSP. Some patients had received one or more conservative treatments before surgery. The duration of drainage tube placement and postoperative length of stay were shorter in the temporary arterial occlusion group than in the other three groups.

Table 3
Comparison of clinical outcomes by different methods of vessel pretreatment in the laparoscopy group

Characteristics	A (n = 76)	B (n = 7)	C (n = 9)	D (n = 35)	*P*-value
Residual tissue					0.0080
Yes	1 (1.32%)	0 (0.00%)	0 (0.00%)	1 (2.86%)	
No	66 (86.84%)	7 (100%)	9 (100%)	33 (94.29%)	
Unknown	9 (11.84%)	0 (0.00%)	0 (0.00%)	1 (2.86%)	
Reoperation					0.0003
Yes	10 (13.16%)	3 (42.86%)	0 (0.00%)	5 (14.29%)	
No	66 (86.84%)	4 (57.14%)	8 (88.89%)	30 (85.71%)	
Unknown	0 (0.00%)	0 (0.00%)	1 (11.11%)	0 (0.00%)	
Pain					0.0107
Yes	0 (0.00%)	0 (0.00%)	0 (0.00%)	1 (2.86%)	
No	76 (100%)	7 (100%)	8 (88.89%)	33 (94.29%)	
Unknown	0 (0.00%)	0 (0.00%)	1 (11.11%)	1 (2.86%)	
Transfusion					0.0003
Yes	9 (11.84%)	3 (42.86%)	1 (11.11%)	5 (14.29%)	
No	67 (88.16%)	4 (57.14%)	7 (77.78%)	30 (85.71%)	
Unknown	0 (0.00%)	0 (0.00%)	1 (11.11%)	0 (0.00%)	
Combined with other treatments	15 (19.74%)	0 (0.00%)	3 (33.33%)	12 (34.29%)	0.0014
β-HCG on the first postoperative day (mIU/ml)	3315.04 ± 4806.55	4454.92 ± 5478.97	9089.86 ± 9287.9	7186.04 ± 7873.65	0.0133
Haemoglobin on the first postoperative day (g/L)	99.22 ± 12.29	100.57 ± 6.88	97.33 ± 16.48	97.91 ± 15.27	0.9810
Intraoperative bleeding volume (ml)	170.92 ± 175.47	140 ± 65.19	250.13 ± 315.03	124.06 ± 144.87	0.2263

* A, No pre-treatment of vessel; B, Uterine artery embolism (UAE); C, Temporary arterial occlusion (metal vascular clamp); D, Permanent arterial occlusion (clamping or sewing).

Characteristics	A (n = 76)	B (n = 7)	C (n = 9)	D (n = 35)	*P*-value
Haemoglobin decline (g/L)	16.2 ± 16.07	10 ± 27.03	22 ± 13.14	16.21 ± 11.22	0.5160
β-hCG decline (mIU/ml)	27,878.6 ± 35,947.87	45,392.85 ± 67,352.82	61,291 ± 21,085	42,033.47 ± 38,881.95	0.1988
Total hospitalization days (d)	10.68 ± 3.21	10.29 ± 3.99	8.13 ± 2.17	9.77 ± 2.37	0.0543
Postoperative length of stay (d)	6.45 ± 1.46	6.71 ± 0.76	5.75 ± 0.71	6.14 ± 1	0.2605
Placement time of drainage tube (d)	2.8 ± 0.87	3.86 ± 1.21	2.75 ± 1.16	3.45 ± 1.33	0.0319

* A, No pre-treatment of vessel; B, Uterine artery embolism (UAE); C, Temporary arterial occlusion (metal vascular clamp); D, Permanent arterial occlusion (clamping or sewing).

Table 4
Comparison of clinical outcomes by different methods of vessel pretreatment in the laparotomy group

Characteristics	A (n = 130)	B (n = 18)	C (n = 15)	D (n = 12)	*P*-value
Tissue residues					< 0.0001
No	5 (3.85%)	2 (11.11%)	15 (100%)	2 (16.67%)	
Yes	109 (83.85%)	16 (88.89%)	0 (0.00%)	10 (83.33%)	
Unknown	16 (12.31%)	0 (0.00%)	0 (0.00%)	0 (0.00%)	
Reoperation					0.0020
No	20 (15.38%)	6 (33.33%)	14 (93.33%)	1 (8.33%)	
Yes	109 (83.85%)	12 (66.67%)	1 (6.67%)	1 1(91.67%)	
Unknown	1 (0.77%)	0 (0.00%)	0 (0.00%)	0 (0.00%)	
Pain					0.1537
No	1 (0.77%)	1 (5.56%)	15 (100%)	0 (0.00%)	
Yes	129 (99.23%)	17 (94.44%)	0 (0.00%)	12 (100%)	
Transfusion					0.0001
No	101 (77.69%)	13 (72.22%)	11 (73.33%)	5 (41.67%)	
Yes	29 (22.31%)	5 (27.78%)	4 (26.67%)	6 (50%)	
Unknown	0 (0.00%)	0 (0.00%)	0 (0.00%)	1 (8.33%)	
Combined with other treatments	8 (6.15%)	2 (11.11%)	1 (6.67%)	1 (8.33%)	0.0382
β-HCG on the first postoperative day (mIU/ml)	4568.89 ± 11,337.18	3275.11 ± 5568.45	2733.44 ± 4642.64	5044.06 ± 6522.29	0.8610
Haemoglobin on the first postoperative day (g/L)	94.7 ± 15.31	94.94 ± 15.53	96.2 ± 14.65	90.59 ± 12.21	0.6128

* A, No pre-treatment of vessel; B, Uterine artery embolism (UAE); C, Temporary arterial occlusion (rubber tourniquet); D, Permanent arterial occlusion (sewing).

Characteristics	A (n = 130)	B (n = 18)	C (n = 15)	D (n = 12)	*P*-value
Intraoperative bleeding volume (ml)	237.24 ± 479.19	175.29 ± 159.3	370 ± 505.61	874.17 ± 1268.27	0.1539
Haemoglobin decline (g/L)	17.43 ± 14.22	15.48 ± 14.74	17.76 ± 14.67	20.49 ± 20.73	0.9179
β-hCG decline (mIU/ml)	40,145.71 ± 50,171.28	34,227.37 ± 60,592.57	39,340.33 ± 57,682.06	38,669.74 ± 48,451.66	0.9566
Total hospitalization days (d)	11.19 ± 3.34	10.39 ± 3.33	11 ± 3.76	11.73 ± 3.04	0.8942
Postoperative length of stay (d)	7.17 ± 1.85	7.22 ± 1	7.67 ± 2.16	9 ± 3.49	0.0087
Duration of drainage tube placement (d)	2.69 ± 1.08	2.93 ± 1	2.67 ± 1.61	2.88 ± 0.99	0.8615

* A, No pre-treatment of vessel; B, Uterine artery embolism (UAE); C, Temporary arterial occlusion (rubber tourniquet); D, Permanent arterial occlusion (sewing).

Discussion

Comparisons between laparoscopic and laparotomic surgery for CSP have not been reported. Laparotomic resection has many advantages, such as completely removing pregnancy tissue implanted in the scar, repairing scar defects and reducing the risk of recurrence, but it leaves large surgical wounds [13]. Laparoscopy has been widely used in gynaecology. Likewise, laparoscopic surgery has many advantages in the treatment of CSP. In the present study, 278 cases met the inclusion criteria. These patients were treated with laparoscopic surgery or transabdominal surgery. The hysterotomy rate was 30.68%, which reflects the proportion of high-risk CSP patients admitted to our centre. Moreover, few studies have focused on exploring the best treatment strategy in high-risk CSP, and there are no similar reports in the available literature. Hysterotomy with laparoscopy in the treatment of high-risk CSP resulted in fewer complications than laparotomy in this work.

In this study, more patients underwent laparoscopic surgery than laparotomy after other treatments failed. In addition, laparoscopy involved less bleeding and fewer blood transfusions than laparotomy. At the same time, we also observed that the total number of days of hospitalization and postoperative hospitalization were better in the laparoscopic group than in the laparotomic surgery group. In summary, we have shown that laparoscopic surgery is superior to laparotomic surgery in the treatment of high-risk CSP. Hysterotomy with laparoscopy in the treatment of high-risk CSP resulted in fewer complications than laparotomy in this work.

To reduce the risk of bleeding during or after the operation, some surgeons try to pretreat blood vessels in various ways. UAE is currently accepted as a treatment or pretreatment for CSP. However, UAE may affect the blood supply of the uterus and ovaries and cause pelvic pain, pulmonary embolism and endometrial atrophy [14]. Bilateral uterine artery (or internal iliac artery) ligation or temporary arterial occlusion has been used for vascular pretreatment in CSP [15]. In our retrospective analysis, the residual tissue, reoperation and intraoperative blood transfusion rates in patients treated with temporary vascular occlusion were better than those in patients treated with permanent vascular occlusion. Therefore, patients benefitted more from temporary arterial occlusion in both groups.

In some of the retrospective studies, laparoscopic or open surgery was used as a remedy after other treatments were ineffective or after massive bleeding. Therefore, there is the possibility of underestimation of the severity of the disease before the operation. This leads to a potential increase in risk and an increased burden on patients [16–18]. In other studies, laparoscopic or open surgery was used. However, there was no explanation for the use of these treatments or for the inability to compare laparoscopic with open surgery [19–22]. In a prospective study, all patients underwent MTX embolization under UAE, followed by D&C or hysteroscopy combined with laparoscopy. As a remedial measure after D&C, laparotomy was performed in 21.2% of patients and even led to hysterectomy in a patient [23]. In the case of high-risk CSP, D&C may not be appropriate.

More importantly, we cannot go to the other extreme and must carefully choose medical treatment or D&C under hysteroscopy or ultrasound monitoring for the most dangerous type of CSP. For type II CSP, fatal intraoperative and/or postoperative bleeding, tardive intermittent massive vaginal bleeding, residual tissue, a slow decrease or even an increase in the serum β-hCG level and intrauterine infection were likely to occur following treatment by the above methods. In addition, CSDs are often deep or irregular, making it difficult for the instrument to reach the deepest part and inevitably resulting in residual tissue. Furthermore, intraoperative bleeding, perforation of the uterus, bladder injury and other serious complications could occur [24]. Therefore, timely hysterotomy may avoid the above situations given a definite diagnosis.

In the present study, 278 cases met the inclusion criteria. These patients were treated with laparoscopic surgery or transabdominal surgery. The hysterotomy rate was 30.68%, which reflects the proportion of high-risk CSP patients admitted to our centre. Of course, as one of the major tertiary referral hospitals in China, these data also indicate that doctors must pay proper attention to CSP. However, we found that the CSP classification as determined either by the Vial criteria or by Chinese experts could not truly reflect the seriousness of the CSP we observed, which was inconsistent with our clinical practice. Hysterotomy was performed for most type II CSP (according to the Chinese expert consensus) patients who underwent laparoscopy or laparotomy. This may lead to an overemphasis on excessive surgical treatment, which increases patient pain, hospitalization costs and length of stay. Is this true outside of our own observations? Previous studies have shown that either laparoscopy or laparotomy was performed mainly for type II CSP (Val et al).

Our research aimed to explore a suitable, effective and safe surgical approach for the treatment of high-risk CSP. To better guide clinical practice, we propose a new method for the classification of CSP, which could improve the awareness and identification of high-risk CSP. We also suggest that a comprehensive assessment be made of the probability of recurrent CSP or CSD after hysterotomy. It is not clear whether blocking the arteries will affect the function of the female reproductive system. When subsequent follow-up data become available, there will be a new evaluation.

Our study still has some shortcomings. It is limited by its retrospective nature, the heterogeneity of the data and the reliance on clinical CSP data not originally collected for research purposes. Additionally, it was limited by being a single-centre experience and having potential selection bias, which may limit its external validity. Our results may not represent the findings of other hospitals. Another limitation of our study is the incomplete follow-up, which makes it difficult to conduct a comprehensive analysis of the follow-up parameters, such as menstruation, ovarian function and fertility.

Conclusions

Our study suggests that adequate assessment of CSP is most important in choosing the right treatment strategies and that temporary arterial occlusion under laparoscopy may be the best treatment. We have proposed a new classification system for CSP that is more conducive to screening for high-risk CSP and delivering appropriate treatment. Future work will include comprehensive follow-up data, and a multicentre clinical study of CSP is currently being carried out.

Declarations

Ethics approval and consent to participate

The Ethics Committee of the Tongji Hospital, Tongji Medical College, Huazhong University of Science and Technology approved the study (No: TJ-IRB20191214). The Ethics Committee does not require written or verbal informed consent for retrospective studies and was, thus, not sought after.The study was conducted ethically in accordance with the 2013 Helsinki World Medical Association Declaration.

Consent for publication

Not applicable.

Availability of data and materials

The data used and analysed during the study will be made available upon reasonable request made through the corresponding author.

Competing interests

The authors declare that they have no conflicts of interest.

Funding

This work was supported by the National Natural Science Foundation of China (81572563).

Authors' contributions

Conceived and designed the experiments: RL. Analysed the data: RL and SW. Wrote the first draft of the manuscript: SW and TZ. Assisted with the data analysis: PF and PC. Agree with the manuscript results and conclusions: TZ, SW, PF, PC and RL. All authors reviewed the manuscript.

Acknowledgements

None

References

1. Jurkovic D, Ben-Nagi J, Ofilli-Yebovi D **et al (**2007**)**. **Efficacy of Shirodkar cervical suture in securing hemostasis following surgical evacuation of Cesarean scar ectopic pregnancy**. Ultrasound Obstet Gynecol **30**:**95–100**.
2. Chiang YC, Tu YA, Yang JH **et al (**2017**)** Risk factors associated with failure of treatment for cesarean scar pregnancy. Int J Gynaecol Obstet 138(1):28–36.
3. Timor-Tritsch I, Buca D, Di Mascio D et al (2021). Outcome of cesarean scar pregnancy according to gestational age at diagnosis: A systematic review and meta-analysis. Eur J Obstet Gynecol Reprod Biol 258:53–59.
4. Cali G, Timor-Tritsch I, Forlani F, et al (2020). Value of first-trimester ultrasound in prediction of third-trimester sonographic stage of placenta accreta spectrum disorder and surgical outcome. Ultrasound Obstet Gynecol 55:450–459.
5. Y Vial, P Petignat, **P Hohlfeld (**2000 **) Pregnancy in a cesarean scar**. Ultrasound Obstet Gynecol **16**(**6**):**592–593**.
6. **Family Planning Group**, **Obstetrics and** Gynecology Branch, Chinese Medical A ssociation **(**2016**)**. **Expert consensus on diagnosis and treatment of uterine scar pregnancy after cesarean Sect**. (**2016**). **Chin J Obstet Gynecol 51**:**568**–**572**(**In Chinese**).
7. Naeh A, Shrim A, Shalom-Paz E et al (2019) **Cesarean scar pregnancy managed with local and systemic methotrexate: A single center case series**. Eur J Obstet Gynecol Reprod Biol **238**:**138–142**.

8. Lu F, Liu Y, Tang W et al (2019) **Successful treatment of cesarean scar pregnancy with transvaginal injection of absolute ethanol around the gestation sac via ultrasound**. BMC Pregnancy Childbirth **19**:**312**.
9. Zhang C, Zhang Y, He J et al (2019) **Outcomes of subsequent pregnancies in patients following treatment of cesarean scar pregnancy with high intensity focused ultrasound followed by ultrasound–guided dilation and curettage**. Int J Hyperthermia **36**:**926–931**.
10. Liu CN, Tang L, Sun Y et al (2020) **Clinical outcome of high-intensity focused ultrasound as the preoperative management of cesarean scar pregnancy**. Taiwan J Obstet Gynecol **59**(**3**):**387–391**.
11. Gao L, Huang Z, Gao J et al (2014) **Uterine artery embolization followed by dilation and curettage within 24 hours compared with systemic methotrexate for cesarean scar pregnancy**. Int J Gynaecol Obstet **127**:**147–151**.
12. Fylstra DL (2002) **Ectopic pregnancy within a cesarean scar: a review**. Obstet Gynecol Surv **57**:**537–543**.
13. Wang G, Liu X, Bi F et al (2014) **Evaluation of the efficacy of laparoscopic resection for the management of exogenous cesarean scar pregnancy**. Fertil Steril **101**:**1501–1507**.
14. Holub Z, Mara M, Kuzel D et al (2008) **Pregnancy outcomes after uterine artery occlusion: prospective multicentric study**. Fertil Steril **90**:**1886–1891**.
15. Dior UP, Palma-Dias R, Reidy KL et al (2019) **Cesarean Scar Pregnancies: Incidence and Factors Associated with Conversion to Surgery from Medical Management**. J Minim Invasive Gynecol **26**:**919–927**.
16. Fang Q, Sun L, Tang Y et al (2017) **Quantitative risk assessment to guide the treatment of cesarean scar pregnancy**. Int J Gynaecol Obstet **139**:**78–83**.
17. Jiao LZ, Zhao J, Wan XR **et al (**2008**) Diagnosis and treatment of cesarean scar pregnancy**. Chin Med Sci J **23**:**10–15**.
18. Le A, Li M, Xu Y **et al (**2019**) Different Surgical Approaches to 313 Cesarean Scar Pregnancies**. J Minim Invasive Gynecol **26**:**148–152**.
19. Özcan HÇ, Uğur MG, Balat Ö **et al (**2018**) Is ultrasound–guided suction curettage a reliable option for treatment of cesarean scar pregnancy? A cross–sectional retrospective study**. J Matern Fetal Neonatal Med **31**:**2953–2958**.
20. Sun YY, Xi XW, Yan Q et al (2015) **Management of type II unruptured cesarean scar pregnancy: Comparison of gestational mass excision and uterine artery embolization combined with methotrexate**. Taiwan J Obstet Gynecol **54**:**489–492**.
21. *Wang YL*<bi>,</bi> *Weng SS*<bi>,</bi> *Huang WC et al (2014*) *Laparoscopic management of ectopic pregnancies in unusual locations*<bi>.</bi> *Taiwan J Obstet Gynecol 53*<bi>:</bi>*466–470*<bi>.</bi>
22. *Giampaolino P*<bi>,</bi> *De Rosa N*<bi>,</bi> *Morra I* <bi>et al (</bi>*2018*<bi>) Management of Cesarean Scar Pregnancy: A Single-Institution Retrospective Review. Biomed Res Int 2018:6486407. </bi>

23. Wu X, Xue X, Wu X **et al (**2014**) Combined laparoscopy and hysteroscopy vs. uterine curettage in the uterine artery embolization-based management of cesarean scar pregnancy: a cohort study**. Int J Clin Exp Med **7**:**2793–803**.
24. Wang L, Sun L, Wang L et al (2015) **Laparoscopic temporary bilateral uterine artery occlusion with silicone tubing to prevent hemorrhage during vacuum aspiration of cesarean scar pregnancies**. J Obstet Gynaecol Res **41**:**1762–1768**.

Figures

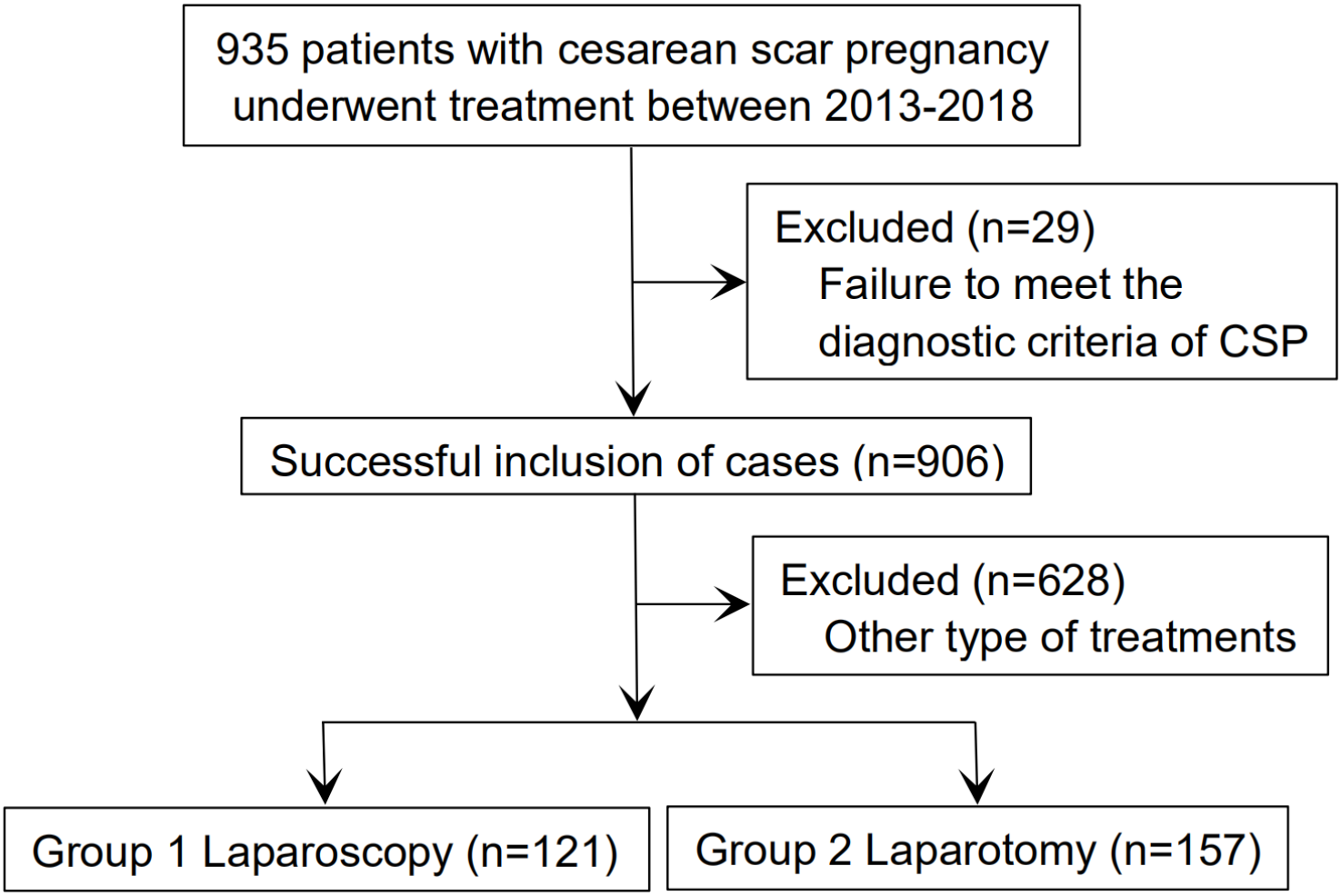

Figure 1

Flowchart of the study population.

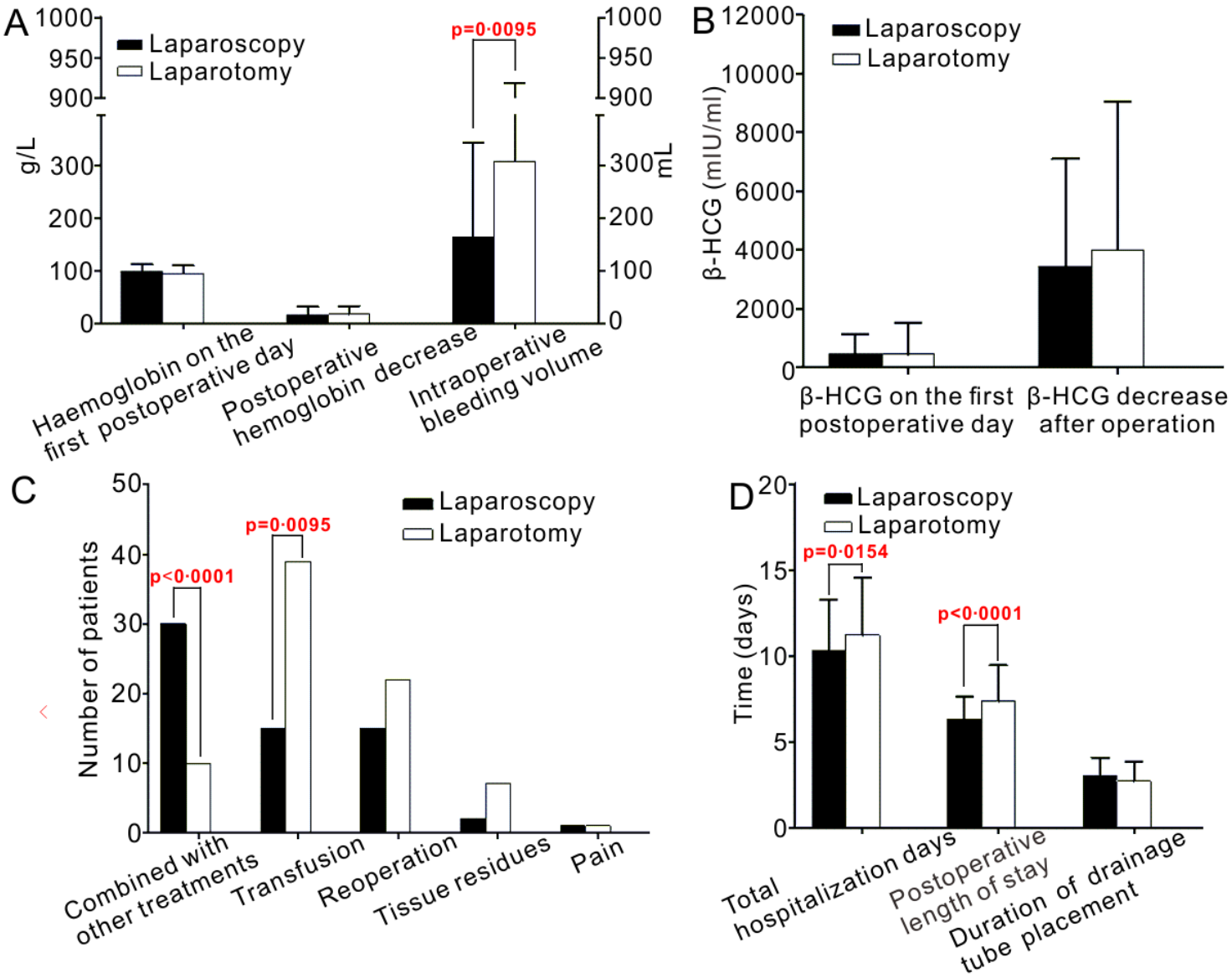

Figure 2

Comparison of the main intraoperative and postoperative outcomes between the two groups. (A) Perioperative haemorrhage and haemoglobin changes in the two groups. The haemoglobin level on the first postoperative day and the postoperative haemoglobin decrease were not different between the laparoscopy and laparotomy groups, but the intraoperative bleeding volume was different between the two groups (p=0.0095). (B) Serum concentration of β-hCG after operation. The β-hCG level on the first postoperative day and postoperative β-hCG decrease between were not different the two groups. (C-D) Evaluation of relevant indicators of surgical and postoperative recovery. A small number of patients were treated with one or more techniques prior to laparoscopic or transabdominal surgery, with more patients in the laparoscopy group than in the laparotomy group (p<0.0001). The numbers of transfusions, the total number of days of hospitalization and postoperative hospitalization in the laparoscopy group were all better than those in the laparotomy group (p<0.05). Reoperation, residual tissue, pain and drainage tube placement duration wcere not different between the two groups.

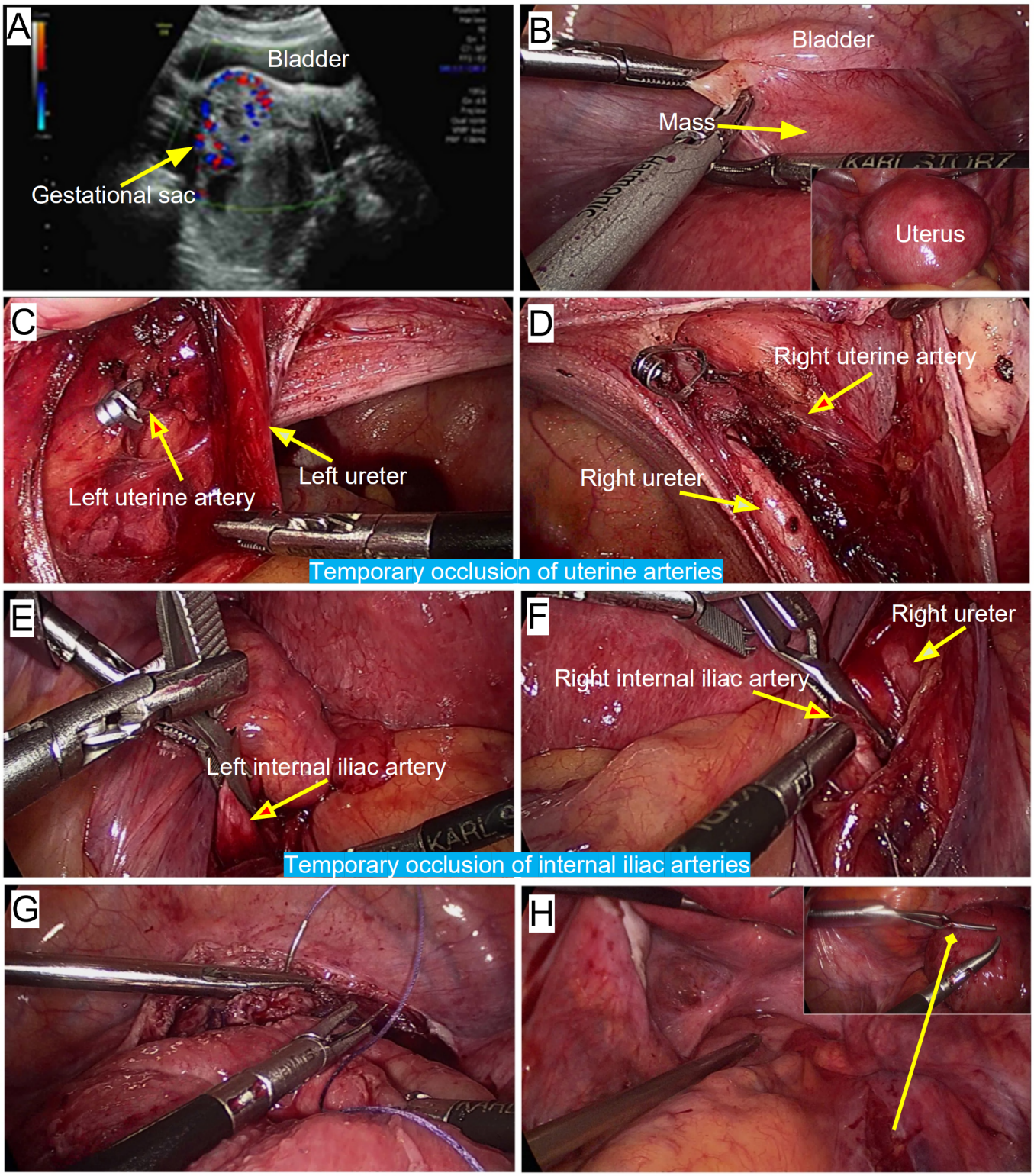

Figure 3

Laparoscopic management of the uterine or internal iliac arteries and surgical procedures in caesarean scar pregnancy. (A) Ultrasound demonstrated pregnancy tissue implanted in the scar protruding from the uterus and growing towards the bladder. (B) The uterus was markedly enlarged and full in shape, and the mass impinged towards the abdominal cavity (yellow arrow). (C-D) After dissection of the pelvic sidewalls, the ureters (yellow arrows) and uterine arteries (blue arrows) were separated and identified. The

uterine arteries were temporarily occluded with flexible metal clips. (E-F) The bilateral internal iliac arteries (blue arrows) were occluded with flexible metal clips. (G) Scissors were used to remove scar tissue after pregnancy tissue removal. Fast interrupted suturing of the incision of the lower uterine segment was performed with 1-0 absorbable sutures. Finally, peritonealisation was performed. (H) After suturing, the metal clamps on both sides were removed.