Research Square

Preprints are preliminary reports that have not undergone peer review. They should not be considered conclusive, used to inform clinical practice, or referenced by the media as validated information.

Post-stroke Hemichorea Responding to Repetitive Transcranial Magnetic Stimulation Using a Parabolic Coil: A Case Report

Xiaowei Chen
Jilin University First Hospital
Shihuan Cheng
Jilin University First Hospital
Xuncan Liu
Jilin University First Hospital
Haoyang Duan
Jilin University First Hospital
Jiaming Zhang
Jilin University First Hospital
Guoxing Xu
Jilin University First Hospital
ZHENLAN LI (zhenlan@jlu.edu.cn)
Jilin University First Hospital https://orcid.org/0000-0002-3177-1073

Case report

Keywords: repetitive transcranial magnetic stimulation, post-stroke hemichorea, stroke, movement disorders, non-invasive stimulation

Posted Date: August 27th, 2021

DOI: https://doi.org/10.21203/rs.3.rs-845740/v1

License: This work is licensed under a Creative Commons Attribution 4.0 International License. Read Full License

---

Abstract

Background: Hemichorea is a common post-stroke movement disorder. Although the general prognosis is good, permanent functional impairment remains in a substantial number of patients with post-stroke hemichorea. Anti-choreic drugs may alleviate symptoms in mild cases, but they often incur unacceptable side effects like tardive dyskinesia and parkinsonism. Surgery is rarely indicated for the treatment of vascular chorea, except in refractory cases.

Case presentation: Here we reported a case of a 71-year-old man with severe choreatic movements after stroke, which caused the inability to perform the activities of daily living. Computed tomography revealed signs of former bleeding in the left caudate nucleus. Due to poor response to pharmacologic treatment, he was subjected to physical therapy and repetitive magnetic stimulation (rTMS) using a parabolic coil with 1 Hz over the left M1 area. The patient reported reduced symptoms after the 1st week of stimulation. rTMS substantially reduced choreatic movements and improved functional scores, including Brunnstrom recovery stage, Fugl–Meyer Assessment, Barthel index, Berg balance scale, and Dyskinesias scale. After 4 weeks of therapy, he was discharged with only a slight involuntary movement on the left side. No relapse occurred during the 1-year follow-up.

Conclusions: Further studies are needed to reveal the mechanism of the observed effects and confirm the efficacy of rTMS as an alternative treatment for severe post-stroke hemichorea.

Background

Post-stroke hemichorea (PSH) is the second most common post-stroke movement disorder (PSMD) [1]. PSH has an early onset (< 24 h) after stroke, and its prognosis may differ depending on the location of the lesion. The caudate and putamen are the most common location in cases with persisting PSH (61.4%), and over one-third of patients have poor outcomes [1]. Patients with severe symptoms cannot accomplish the activities of daily living, and they also have poor functional outcomes. Strategies for hemichorea include pharmacological and surgical therapy [2]. Low doses of neuroleptics are often well-tolerated, but with unsatisfactory efficacy; in contrast, high doses are rarely helpful because of unacceptable side effects. Deep brain stimulation (DBS) is a technique for the treatment of certain neuropsychiatric disorders by stereotactic surgery, in which stimulation electrodes are implanted into a deep brain area. However, its application in the treatment of PSH is limited due to the relatively strict inclusion criteria and invasive characteristics[3]. In recent years, a noninvasive brain stimulation technique - repetitive transcranial stimulation (rTMS)—has been widely applied in the therapy of the nervous system diseases, such as motor dysfunction, aphasia after stroke, and Parkinson's disease, etc. Currently, there is an increasing amount of evidence showing that rTMS is effective in patient with tremor and that its biological effects could last even some time after the stimulation. In this study, we reported a PSH case successfully treated with rTMS by a parabolic coil.

Case Description

A 71-year-old right-handed man was admitted to the Department of Rehabilitation because of right-sided hemiparesis and severe right-sided involuntary movements following a hemorrhage over 2 weeks. The patient had a 30-year history of hypertension and a 40-year history of smoking and drinking. His family history was unremarkable. On admission to the Department, he was conscious and fully oriented; the neurological examination was unremarkable, except for right-sided hemiparesis and right-sided hemichorea. The assessments were displayed in Table 1. Hemichorea was evaluated by Dyskinesias scale (ranging from 0 to 4, see Table 2). The patient displayed severe choreatic movements in his right limbs during rest and voluntary actions. The frequency of choreatic movements was 30–36 times/min during awake state (Supplementary data, Video 1) and decreased during sleep. He could not accomplish daily activities, stand and walk by himself, and even had difficulty falling asleep. The diagnosis of hemichorea was confirmed by a high-intensity signal in the left caudate nucleus on brain computed tomography (Fig. 1). Tiapride hydrochloride (50 mg, 3 times a day) was applied to alleviate the choreatic movements, but it was not effective.

Table 1
The patient's functional evaluations before and after therapy

	Before therapy	2 weeks after therapy	4 weeks after therapy
BRS	**3-3-3**	**4-3-5**	**5-5-5**
FMA score	40/100	50/100	78/100
BBS score	4/56	40/100	48/56
BI score	20/100	45/100	75/100
Frequency of choreatic movements	30–36 times/min	20–25 times/min	4–8 times/min
BRS: Brunnstrom Recovery Stage; FMA: Fugl–Meyer Assessment (FMA);			
BBS: Berg Balance Scale; BI: Barthel index.			

Table 2
Dyskinesias scale before treatment, 2 weeks, and 4 weeks post-treatment

	Before	**2 weeks**	**4 weeks**
At rest while performing an attention task	4	2	1
Walking	4	2	1
Pouring water	4	3	1
Drinking from a glass	4	3	1
Putting on a lab coat and buttoning	4	3	1
Finger-to-nose manoeuver	4	3	1

Table 1. The patient's functional evaluations before and after therapy

Table 2. Dyskinesias scale before treatment, 2 weeks, and 4 weeks post-treatment

Therapeutic approach

Considering that dose increase may increase side effects, we did not change the doses of tiapride hydrochloride. rTMS was delivered to modulate the excitability of the cortex.

Physical and occupational therapy was performed after magnetic stimulation, including the practice of transfers (lying-to-sit, sit-to-stand, standing), general strengthening exercise, posture, coordination, and balance training, task-specific mobility training, and activities related to daily living, 80 min a day, 4 weeks in total.

rTMS procedure

Resting motor threshold (RMT) was evaluated before therapy as previously reported [4]. In brief, the electromyogram signal was monitored by Ag/AgCl electrodes. An active electrode and a reference electrode were attached to the skin overlying contra-lesional abductor pollicis brevis (APB) and the adjacent joint, respectively. RMT was described as the minimum intensity of a magnetic stimulus that generated at least 5 Motor Evoked Potentials (MEPs) of ≥ 50 μV peak-to-peak amplitude per 10 consecutive stimuli. rTMS was delivered via a parabolic coil (Magventure MMC-140 coil, Magventure Magpro R30 stimulator, Denmark) over the left M1 area (6–7 cm lateral to the vertex), and the optimal location was adjusted to evoke the maximum MEP in the contralateral APB. The stimulation was applied using 1 Hz, 90% of RMT, 1000 pulses in total, 1 session a day, 5 days per week, 4 weeks in total. No uncomfortable feelings were reported by the patient.

No side effects were reported during and after the rTMS sessions.

Outcomes

The patient reported an obvious reduction of symptoms after the 1st week of rTMS, the frequency of choreatic movements reduced from 30–36 times/min to 20–25 times/min. The involuntary movements relapsed about 2 h later albeit with a reduced intensity compared with before the stimulation. The choreatic movements improved gradually. Four weeks later, the choreatic movements improved a lot. The frequency decreased to 4–8 times/min during the awake state, with no obvious involuntary movements while sleeping (Supplementary data, Video 2). The patient was discharged 4 weeks later with only a slight involuntary movement. He could accomplish most of the daily activities and walk without a monitor. Both BI, FMA, BRS and BBS scores increased after therapy (see Table 1). Dyskinesias scores improved when at rest and performing functional movement (see Table 2). At 1-year follow-up, the patient reported no relapse of choreatic movements.

Discussion

Hemichorea is the most frequent PSMD. Patients with hemichorea continually exhibit involuntary and irregular movements, which could increase morbidity through injury and extend recovery of motor function and ability of daily living [5, 6]. Pharmacological therapy, such as antidopaminergic and dopamine-depleting agents, may be effective in some cases, but drug-induced parkinsonism and tardive dyskinesia are unavoidable [7, 8]. Although hemichorea may improve with medical therapy, in certain circumstances patients could suffer from persistent and refractory symptoms. It was reported hemichorea arising from cortical stroke has a better prognosis due to integrity of deep structures circuity [9]. In this case, the lesion was observed in the caudate nucleus—the most common location involved in persistent hemichorea symptoms [1, 10]. The medication was not effective in this patient considering that after taking tiapride hydrochloride for 2 weeks, hemichorea was not alleviated.

The pathophysiology remains uncertain. Movement disorders caused by stroke are often associated with the lesions of the basal ganglia. The basal ganglia plays an important role in generating movement; it receives signals from the cerebral cortex and sends output to the cerebellum and spinal cord through the thalamus [6]. The neurocircuits projected by the basal ganglia to the cerebral cortex include direct and indirect pathways. When the cerebral cortex is excited, the direct pathway increases the thalamic activity, while the indirect pathway decreases the thalamic activity, the excessive inhibition of the indirect pathway will cause chorea. rTMS can inhibit the excitability of the cerebral cortex and reduce the thalamic which alleviated the symptoms of chorea[11]. Besides, low-frequency rTMS could significantly shorter cortical silent periods (CSPs) on the M1, which is related to cortical hyper-excitability [4].

In this patient, 1 Hz rTMS was adopted over the left M1. After the first week of rTMS therapy, the symptoms were significantly reduced, and the frequency and intensity of involuntary movements reduced; this indicated that rTMS can have a quick effect and rapidly inhibit the excitability of the cerebral cortex. After 4 weeks, the frequency of involuntary movements decreased significantly, with no significant movements occurring during sleep. The patient was discharged with mild symptoms after 4 weeks of stimulation and rehabilitation therapy. The choreatic movements disappeared at 1-year follow-up, and the anti-choreaic drug was discontinued. which indicated that the therapeutic effect of rTMS was time-cumulative and that the excitation–inhibition balance between direct and indirect pathways was re-established to reach the optimal state. The patient was discharged after 4 weeks with only slight involuntary movement and was able to perform most of daily activities, the choreatic movements disappeared at 1-year follow-up, and the anti-choreaic drug was discontinued. These findings suggested that the efficacy of rTMS in the patient was sustained, and the biological effects were sustained for some time after the stimulation.

In this report, we used a parabolic coil instead of the figure-8 coil. The figure-8 coil is more focused, so it can only stimulate the superficial cortical regions just under the coil; in contrast, according to the designer, the parabolic coil can stimulate deeper and wider areas (supplemental Fig. 1). Evidence showed that most movement disorders result from a network dysfunction, not from a single lesion[12], and both M1 and SMA are closely related to hyperkinetic movement disorders. Therefore, in this study, a parabolic coil was adopted over the left M1, which could stimulate the SMA at the same time to enhance the

therapeutic effect. The parabolic coil was often used peripherally to improve swallowing and respiratory and motor function after stroke [13–15]. However, to our knowledge, this is the first description of post-stroke hemichorea treated with rTMS by a parabolic coil. We also hope to stimulate deeper structures such as basal ganglia, which would have a direct effect. However, further research is needed to prove whether rTMS can stimulate subcortical gray matter directly. The outcomes observed in this patient suggest that the combination of rTMS and rehabilitation therapy may be a safe and viable strategy for PSH as an alternative to the invasive DBS method.

Conclusion

rTMS via a parabolic coil could be a good choice in patients with PSH.

Although it is only a single case report, this study shows that the parabolic coil has a good effect on the treatment of PHC, and the effect lasts for a long time without side effects.

Abbreviations

PSH: post-stroke hemichorea; PSMD: post-stroke movement disorder; DBS: deep brain stimulation; rTMS: repetitive transcranial stimulation; M1: primary motor cortex; SMA: supplemental motor area; BRS: brunnstrom recovery stage; FMA: Fugl-meyer Assessment; BI: Barthel index; BBS: Berg balance scale; RMT: resting motor threshold; MEPs: Motor Evoked Potentials;

Declarations

Acknowledgment

Not applicable.

Funding

This work was supported by the Changchun Science and Technology Bureau (grant no. 17YJ016).

Availability of data and materials

The datasets used in this study are available to the corresponding author on a reasonable request.

Ethics approval and consent to participate

This study was reviewed and approved by the local ethics review committee of the First Hospital of Jilin University. The patient completed the rTMS treatment as a part of a randomized, single-blinded, control study (Trial Registration chictr.org.cn Identifier: ChiCTR1800019757. Registered 28 November 2018-Retrospectively registered, http://www.chictr.org.cn/showproj.aspx?proj=32580.) The patient has approved the study and signed written informed consent. He also consented to publish this case report.

Competing interests

The authors declare that the research was conducted in the absence of any commercial or financial relationships that could be construed as a potential conflict of interest.

Authors' contributions

XC and ZL contributed to the design and monitoring of the project. XC wrote the manuscript. SC enrolled and managed the patient clinically. XL performed all evaluations of the patient. JZ was responsible for rTMS delivery. HD carried out physical therapy. GX collected the data. All authors contributed to and agreed with the final manuscript.

Authors' Contributions

XC contributed to the project administration and writing the original draft. ZL was responsible of funding acquisition and project supervision. SC provided the case and performed all evaluations. XL was in charge of investigation and methodology. JZ was responsible for rTMS delivery. HD carried out physical therapy. GX collected the data. All authors contributed to and agreed with the final manuscript.

References

1. Suri R, Rodriguez-Porcel F, Donohue K, Jesse E, Lovera L, Dwivedi AK, Espay AJ. Post-stroke Movement Disorders: The Clinical, Neuroanatomic, and Demographic Portrait of 284 Published Cases. J Stroke Cerebrovasc Dis. 2018;27(9):2388–97.
2. Ramirez-Zamora A, Eisinger RS, Haider SA, Youn Y, Shin D, Molho ES, Pilitsis JG. Pallidal deep brain stimulation and intraoperative neurophysiology for treatment of poststroke hemiballism. Ann Clin Transl Neurol. 2018;5(7):865–9.
3. Bashir H, Jankovic J. Treatment options for chorea. Expert Rev Neurother. 2018;18(1):51–63.
4. Kaseda Y, Yamawaki T, Ikeda J, Hayata M, Dohi E, Ohshita T, Ochi K, Nomura E, Matsumoto M. Amelioration of persistent, non-ketotic hyperglycemia-induced hemichorea by repetitive transcranial magnetic stimulation. Case Rep Neurol. 2013;5(1):68–73.
5. Alarcón F, Zijlmans JC, Dueñas G, Cevallos N. Post-stroke movement disorders: report of 56 patients. J Neurol Neurosurg Psychiatry. 2004;75(11):1568–74.
6. Mehanna R, Jankovic J. Movement disorders in cerebrovascular disease. Lancet Neurol. 2013;12(6):597–608.
7. Grandas F. Hemiballismus. Handb Clin Neurol. 2011;100:249–60.
8. Mukand JA, Fitzsimmons C, Wennemer HK, Carrillo A, Cai C, Bailey KM. Olanzapine for the treatment of hemiballismus: A case report. Arch Phys Med Rehabil. 2005;86(3):587–90.
9. Chung SJ, Im JH, Lee MC, Kim JS. Hemichorea after stroke: clinical-radiological correlation. J Neurol. 2004;251(6):725–9.

10. Kobayashi K, Aoyama N, Sasaki J, Oshima H, Fukaya C, Yamamoto T, Katayama Y. MRI appearance of a cerebral cavernous malformation in the caudate nucleus before and after chorea onset. J Clin Neurosci. 2011;18(5):719–21.
11. Di Lazzaro V, Dileone M, Pilato F, Contarino MF, Musumeci G, Bentivoglio AR, Tonali PA, Rothwell JC. Repetitive transcranial magnetic stimulation of the motor cortex for hemichorea. J Neurol Neurosurg Psychiatry. 2006;77(9):1095–7.
12. Holtbernd F, Eidelberg D. Functional brain networks in movement disorders: recent advances. Curr Opin Neurol. 2012;25(4):392–401.
13. Chen X, Liu X, Cui Y, Xu G, Liu L, Zhang X, Jiang K, Li Z. Efficacy of functional magnetic stimulation in improving upper extremity function after stroke: a randomized, single-blind, controlled study. J Int Med Res. 2020;48(6):300060520927881.
14. Momosaki R, Abo M, Watanabe S, Kakuda W, Yamada N, Mochio K. Functional magnetic stimulation using a parabolic coil for dysphagia after stroke. Neuromodulation. 2014;17(7):637–41. discussion 641.
15. Zhang X, Plow E, Ranganthan V, Huang H, Schmitt M, Nemunaitis G, Kelly C, Frost F, Lin V. Functional Magnetic Stimulation of Inspiratory and Expiratory Muscles in Subjects With Tetraplegia. Pm r. 2016;8(7):651–9.

Figures

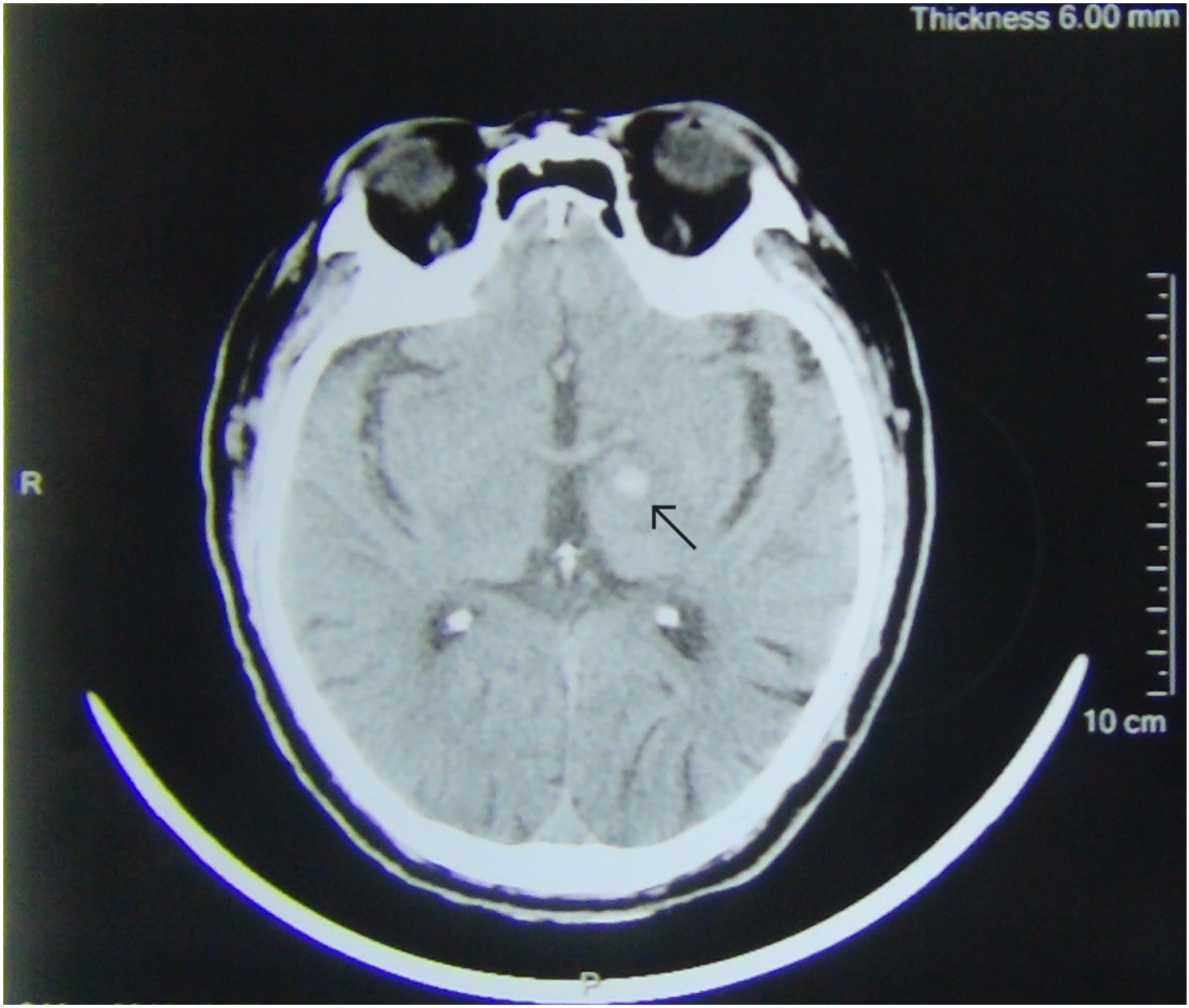

Figure 1

Computed tomography of the brain, showing hemorrhage in the left caudate nucleus (black arrow).

Supplementary Files

This is a list of supplementary files associated with this preprint. Click to download.

- Video1.mp4
- Video2.mp4
- supplementalFigure1.tif