Case Reports On The Multimodal Management of Refractory Chronic Oncological Pain of The Chest Wall: The Use of The Spinal Erector Plane Neurolysis

John Cardenas (jolica@hotmail.com)
Hospital Pablo Tobon Uribe https://orcid.org/0000-0002-1710-6384

Juan Felipe Vargas-Silva
Hospital Pablo Tobon Uribe

Alejandro Ramirez
Universidad de Caldas

Research Article

Keywords: cancer pain, multimodal management, interventional therapy, spinal erector plane, neurolysis, case reports

Posted Date: December 29th, 2021

DOI: https://doi.org/10.21203/rs.3.rs-847803/v1

Abstract

Chronic pain of oncological origin is one of the most frequent complications and is difficult to control, that results in a decrease in the quality of life and disability among patients suffering from this pathology. Primary or metastatic tumors originating from lung, colonic, or breast neoplasms can invade the chest wall, causing progressive respiratory pain and symptoms that require multiple interventions to achieve adequate control. Many of these cases presenting with advanced-stage cancer are often incurable; thus, pain management and palliative care are primary objectives. Multimodal management is the strategy of choice in these cases through the participation of a multidisciplinary team. Analgesic therapy covers the use of potent opioids, opioid rotation, adjuvant analgesics, and interventional pain management strategies. We report two cases of chronic oncological pain of the chest wall refractory to pharmacological analgesic management. The optimization of multimodal management and the performance of neurolysis by phenolization of the erector spinae plane achieved an adequate response.

Introduction

Cancer patients frequently experience difficult oncological chronic pain refractory to multiple analgesics and combined therapies, causing distress and suffering(1, 2). According to studies, the prevalence of chronic pain of oncological origin ranges from 20–60% (3). In cases of chronic pain refractory to conventional multimodal analgesic therapy, an advanced multidisciplinary approach is required, with the participation of a multidisciplinary team and use of interventional techniques, to achieve proper pain relief (4–6). The erector spinae plane block is a novel regional technique described in 2016 that was initially reported to control neuropathic pain in the chest (7). Moreover, multiple case reports and clinical trials have demonstrated the usefulness of this technique in different fields. This is a report of two cases of patients with advanced metastatic cancer in a terminal state with oncological chronic pain in the chest wall refractory to optimal analgesic management who underwent erector spinae plane chemical neurolysis with phenol for management and had favorable responses and improved analgesic activity and quality of life.

Case 1 Description

A 60-year-old female patient was diagnosed with infiltrating ductal carcinoma of the right breast with metastases to the lungs, liver, peritoneum, retroperitoneum, and mediastinum and infiltration of the chest wall (Image 1). She had severe pain in the right hemithorax for 2 years, which was difficult to control with conventional treatment. The pain increased due to the presence of burns and skin ulceration secondary to radiotherapy. She presented with a 10/10 pain score on the Visual Analogue Scale (VAS), with a great limitation for trunk movements and ambulation and intolerance in the supine position and no improvement with morphine. She was managed by a multidisciplinary team composed of an oncologist, a specialist in pain and palliative care, and a specialist in pain interventionism. She was subjected to multimodal analgesic treatment with hydromorphone in a patient-controlled analgesia (PCA), with a baseline infusion of 1 mg h^{-1}, a bolus dose on demand of 0.2 mg, and pregabalin, paracetamol,

ketamine, and metamizole with progressive dose increase without adequate pain control. Due to the severity of the chronic pain, we decided to perform an interventional technique. Using the spinal erector muscle plane and the ultrasound technique for the erector spinae plane (ESP) block, we performed nerve thoracic wall neurolysis using phenol. In the sitting position, a 10–15-MHz high-frequency linear transducer (ACUSON P500 Ultrasound System, Siemens, Germany) was placed at the level of the T4 spinous process in a longitudinal parasagittal location. The trapezius muscle, major rhomboid, and erector spinae groups were identified with a superficial location to the edge of the T4 transverse process. A 10-cm 22-gauge needle (Sonoplex, Germany) was inserted until the tip was located in the erector spinae plane using a caudal-cephalic plane technique. The position of the erector spinae plane was confirmed by dissection and dilatation of the erector spinae interfascial plane. After negative aspiration, 2% lidocaine (5 mL) and iodinated contrast (Iopamidol 300, 5 mL) were administered. Caudal cephalic diffusion through the erector spinae plane was observed under fluoroscopic guidance without apparent dissemination inside the intervertebral foramina on anteroposterior and lateral projections (Images 2A-2B). Five percent phenol (20 mL) was then injected. The patient reported improvement of pain immediately after the procedure, and the pain intensity decreased by more than 60% (VAS, 4/10) after 48 h. It was possible to suspend the administration of hydromorphone by PCA, treating her pain with conventional analgesia and achieving improvement in her quality of life. The patient was discharged and administered subcutaneous hydromorphone (2 mg) subcutaneously every 4 h with adequate control. The patient died at home 2 weeks later in the company of her family. Informed consent was obtained from the patient’s family for the publication of her case details.

Case 2 Description

A 47-year-old male patient diagnosed with metastatic lung adenocarcinoma under oncology management was referred to a palliative care and pain clinic. He presented with severe somatic and neuropathic oncologic pain involving the right hemithorax due to disease progression. He presented with an 8/10 pain score on the VAS. It was difficult to control his pain despite multimodal analgesia with morphine, oxycodone, hydromorphone, metamizole, acetaminophen, and pregabalin. He received pulsed radiofrequency on the intercostal nerves without any response. Even with this management, adequate pain control was not achieved. Phenol injection on ESP was performed at the right T5 level spinous process. In the sitting position, a 10-15 MHz high-frequency ultrasonic linear transducer (ACUSON P500 Ultrasound System, Siemens, Germany) was placed at the T5 spinous process. A 10-cm 22-gauge needle (Sonoplex, Germany) was inserted until the tip was located in the erector spinae plane using a caudal-cephalic plane technique. The position of the erector spinae plane was confirmed by observing the dissection of fluid and dilatation of the interfascial plane. After negative aspiration, 2% lidocaine (5 mL) and iodinated contrast (Iopamidol 300, 5 mL) were administered. Caudal cephalic diffusion through the erector spinae plane was observed under fluoroscopic guidance without apparent dissemination inside the intervertebral foramina on anteroposterior and lateral projections. Five percent phenol (20 mL) was then injected. The patient reported improvement of pain immediately after the chemical neurolysis, and the pain intensity decreased by >80% upon continuous outpatient management with a fentanyl patch,

with adequate pain control until his death 3 months after the procedure. Informed consent was obtained from the patient's family for the publication of his case details.

Discussion

In 2019, in the United States, 1,762,450 new cancer cases were estimated, equivalent to 4,800 cases per day (8). Cancer and its consequences cause multiple chronic diseases in surviving patients. One of them, chronic cancer pain, has been described with a prevalence of 20–60% in survivors. Despite the availability of effective treatments for pain, over 50% of cases cannot achieve adequate oncologic pain (9).

Pain is the most common symptom of malignant chest wall tumors. Metastasis to bone structures or peripheral tissues is the most common etiology (85%) (6). Other causes of cancer pain in the chest wall include those caused by the adverse effects of surgical treatment, radiotherapy, or chemotherapy (17%) (9).

Although 70–80% of chronic cancer pain can be treated with multimodal analgesic therapy, tolerance with its long-term use, the presence of adverse drug effects or lack of effectiveness, multidisciplinary management by pain specialists and palliative care, and the use of interventional techniques are necessary for proper pain control in these cases (6). Among the interventions described in the literature for the management of chronic pain at the chest wall are intercostal nerve block, intercostal nerve neurolysis, paravertebral block, or the use of intrathecal devices (10, 11).

Regional interfascial techniques have been increasingly used in the recent years, using different deep interfascial planes for the dissemination of local anesthetics to a greater extent, managing to block several interfascial nerves with a single puncture (12). This technique has become massive in the recent years because of its lower technical complexity, few complications, and good results in the management of acute and chronic pain.

Here, we presented two cases of chronic chest wall pain of oncological origin refractory to multimodal pharmacological analgesic management, wherein ESP chemical neurolysis was performed under ultrasound guidance and fluoroscopic confirmation. In 2016, the blockade of the spine erector plane was described by Forero et al. as an alternative treatment for neuropathic pain in the chest wall (7). Due to its easy technical application, low risk of complications, and analgesic and anesthetic effects in a large area of multiple thoracic dermatomes with a single puncture, this technique has become an alternative with potential utility for the control of acute, chronic, traumatic, and acute postoperative pain in cardiothoracic surgery, abdominal surgery, and orthopedic surgery (13).

According to studies on cadavers and using imaging techniques with tomography and nuclear magnetic resonance, the most probable mechanism of action is the spread of local anesthetic from the lower plane of the erector spinae muscle group to the dorsal branch of the nerve root, which explains its analgesic

and anesthetic effect in the dorsal region, and diffusion to the anterior branch, intervertebral space, epidural space, and even the sympathetic paravertebral chain (14, 15).

The use of neurolytic agents through the interfascial plane makes use of this technical superiority through the neurolysis of nerves located in the interfascial planes. This technique has the advantage of achieving a greater extension of its effect due to its greater dissemination and, in turn, achieving an analgesic effect of greater duration by denervation of afferent nociceptive fibers. Additionally, an opioid-sparing saving effect on opioid consumption would be achieved by this mechanism, reducing the adverse effects of chronic opioid consumption among patients with chronic cancer pain (16).

In our case, the ultrasound guide was initially used for the location of the erector plane of the spine, and an iodinated contrast medium was subsequently injected to verify the dissemination of the injected volume by fluoroscopy and to observe if there was dissemination to the paravertebral or epidural space. Discarding dissemination to these sites, a single injection of flat phenol was administered via the spine erector fascia, without demonstration during the procedure or subsequent monitoring of complications in both cases.

The cases of the two patients reported had a clear indication to perform this interventional procedure because, despite the use of a high dose of opioids, they did not experience adequate pain control and were exposed to greater adverse effects.

Other intervention options in these cases could include the use of neuraxial opioids, employing an implantable intrathecal pump (17); however, because of the short life expectancy in both cases, this technique would not be the first choice. An interfascial neurolytic procedure was chosen, which is a minimally invasive and low-cost procedure and can be used to look for the afferent pathways of nociception in the chest wall.

There are potentially serious adverse effects derived from the use of chemical neurolysis at a neuraxial level using phenol or alcohol. These include paraplegia, autonomic dysfunction, bowel dysfunction, bladder dysfunction, or death (18, 19). The authors suggest caution in the indications. It is not recommended as a systematic procedure, reserving it only for cases refractory to conventional medical treatment (20). Candidates for this technique include patients with a short life expectancy and intractable pain despite conventional treatment, without response to other less invasive measures, including maximum doses of opioids by any route of administration or the presence of marked tolerance or serious adverse effects to the use of these medications in the long term (11).

Ultrasound guidance is a reliable method to avoid intravascular administration of the neurolytic agent and to add a fluoroscopic guide to identify dissemination to the interfascial plane and decrease the risk of its neuraxial administration. We decided to administer the injection of phenol in the transverse process of T5 because it is a point closer to the areas of pain afflicting our patients, providing adequate coverage area of neurolysis in order to improve its analgesic effect. In both cases, an improvement in pain severity measured with VAS was achieved above 50%, with a duration of analgesia > 4 weeks.

These cases illustrate a novel use of interfascial neurolysis in the erector spinae plane, using a hybrid technique (ultrasound and fluoroscopic guidance) for the treatment of chronic refractory oncological pain. However, we highlight the fact that it should not be a first-line procedure due to the balance of risk-benefit in its application; however, it has been a useful tool in our pain clinic in patients with oncological severe chronic pain that involves the chest wall.

We acknowledge that evidence of the usefulness of the ESP block in the context of the treatment of acute and chronic pain is still scarce, and randomized controlled studies are underway to clarify its effectiveness and usefulness in these cases. Our intention is to report these cases showing a potential tool that, in the future, could be considered within the protocols of intractable chronic pain management in the chest wall. Additional prospective studies with a larger number of patients are required to clarify their clinical utility and determine the risk-benefit balance.

Declarations

Acknowledgements

None

Funding: We declare that we do not receive funds for this research and publication

Conflicts of interest/Competing interests: None (attach respectives disclosure formats)

Availability of data and material: We declare that all dates in this publication are originals

Code availability: Not applicable

Authors' contributions: All autor participated in the collecton datas, literatura review and results, the clinical following was performed by the palliative care specialist and the intervencional procedure was performed by pain interventional specialist and the anesthesia resident.

Ethics approval: The clinic histories review and the cases publication was authorized by the ethic committee of the Pablo Tobon Uribe Hospital

Consent to participate: Not appplicable

Consent for publication: Patient and hospital consent were obteined (Patients images or individual datas are not disclosed)

References

1. Neufeld NJ, Elnahal SM, Alvarez RH. Cancer pain: A review of epidemiology, clinical quality and value impact. Futur Oncol. 2017;13(9):833–41.

2. Zaza C, Baine N. Cancer pain and psychosocial factors: A critical review of the literature. J Pain Symptom Manage. 2002;24(5):526–42.
3. van den Beuken-van Everdingen MHJ, de Rijke JM, Kessels AG, Schouten HC, van Kleef M, Patijn J. Prevalence of pain in patients with cancer: A systematic review of the past 40 years. Ann Oncol. 2007;18(9):1437–49.
4. Mercadante S, Vitrano V. Pain in patients with lung cancer: Pathophysiology and treatment. Lung Cancer. 2010;68(1):10–5.
5. Teunissen SCCM, Wesker W, Kruitwagen C, de Haes HCJM, Voest EE, de Graeff A. Symptom Prevalence in Patients with Incurable Cancer: A Systematic Review. J Pain Symptom Manage. 2007;34(1):94–104.
6. Gulati A, Shah R, Puttanniah V, Hung JC, Malhotra V. A Retrospective Review and Treatment Paradigm of Interventional Therapies for Patients Suffering from Intractable Thoracic Chest Wall Pain in the Oncologic Population. Pain Med. 2015;16(4):802–10.
7. Forero M, Adhikary SD, Lopez H, Tsui C, Chin KJ. The erector spinae plane block a novel analgesic technique in thoracic neuropathic pain. Reg Anesth Pain Med. 2016;41(5):621–7.
8. Siegel RL, Miller KD, Jemal A. Cancer statistics, 2019. CA Cancer J Clin. 2019;69(1):7–34.
9. Candido KD, Kusper TM, Knezevic NN. New Cancer Pain Treatment Options. Curr Pain Headache Rep. 2017;21(2).
10. Fallon M, Giusti R, Aielli F, Hoskin P, Rolke R, Sharma M, et al. Management of cancer pain in adult patients: ESMO Clinical Practice Guidelines. Ann Oncol. 2018;29(July):iv166–91.
11. Candido K, Stevens RA. Intrathecal neurolytic blocks for the relief of cancer pain. Best Pract Res Clin Anaesthesiol. 2003;17(3):407–28.
12. Elsharkawy H, Pawa A, Mariano ER. Interfascial Plane Blocks: Back to Basics. Reg Anesth Pain Med. 2018;43(4):341–6.
13. Kot P, Rodriguez P, Granell M, Cano B, Rovira L, Morales J, et al. The erector spinae plane block: a narrative review. Korean J Anesthesiol. 2019 Jun;72(3)(1):209–20.
14. Ivanusic J, Konishi Y, Barrington MJ. A Cadaveric Study Investigating the Mechanism of Action of Erector Spinae Blockade. Reg Anesth Pain Med. 2018 Aug 1;43(6):567–71.
15. Adhikary S, Das, Bernard S, Lopez H, Chin KJ. Erector Spinae Plane Block Versus Retrolaminar Block: A Magnetic Resonance Imaging and Anatomical Study. Reg Anesth Pain Med. 2018 Oct;1(7):756–62. 43(.
16. Restrepo-Garces CE, Asenjo JF, Gomez CM, Jaramillo S, Acosta N, Ramirez LJ, et al. Subcostal Transversus Abdominis Plane Phenol Injection for Abdominal Wall Cancer Pain. Pain Pract. 2014;14(3):278–82.
17. Smyth CE, Jarvis V, Poulin P. Brief review: Neuraxial analgesia in refractory malignant pain. Can J Anesth. 2014;61(2):141–53.

18. Superville-Sovak B, Rasminsky M, Finlayson MH. Complications of Phenol Neurolysis. Arch Neurol. 1975;32(4):226–8.
19. Kowalewski R, Schurch B, Hodler J, Borgeat A. Persistent paraplegia after an aqueous 7.5% phenol solution to the anterior motor root for intercostal neurolysis: A case report. Arch Phys Med Rehabil. 2002;83(2):283–5.
20. Gollapalli L, Muppuri R. Paraplegia after intercostal neurolysis with phenol. J Pain Res. 2014;7:665–8.

Figures

Figure 1

Right side infiltrating thoracic wall lesion.

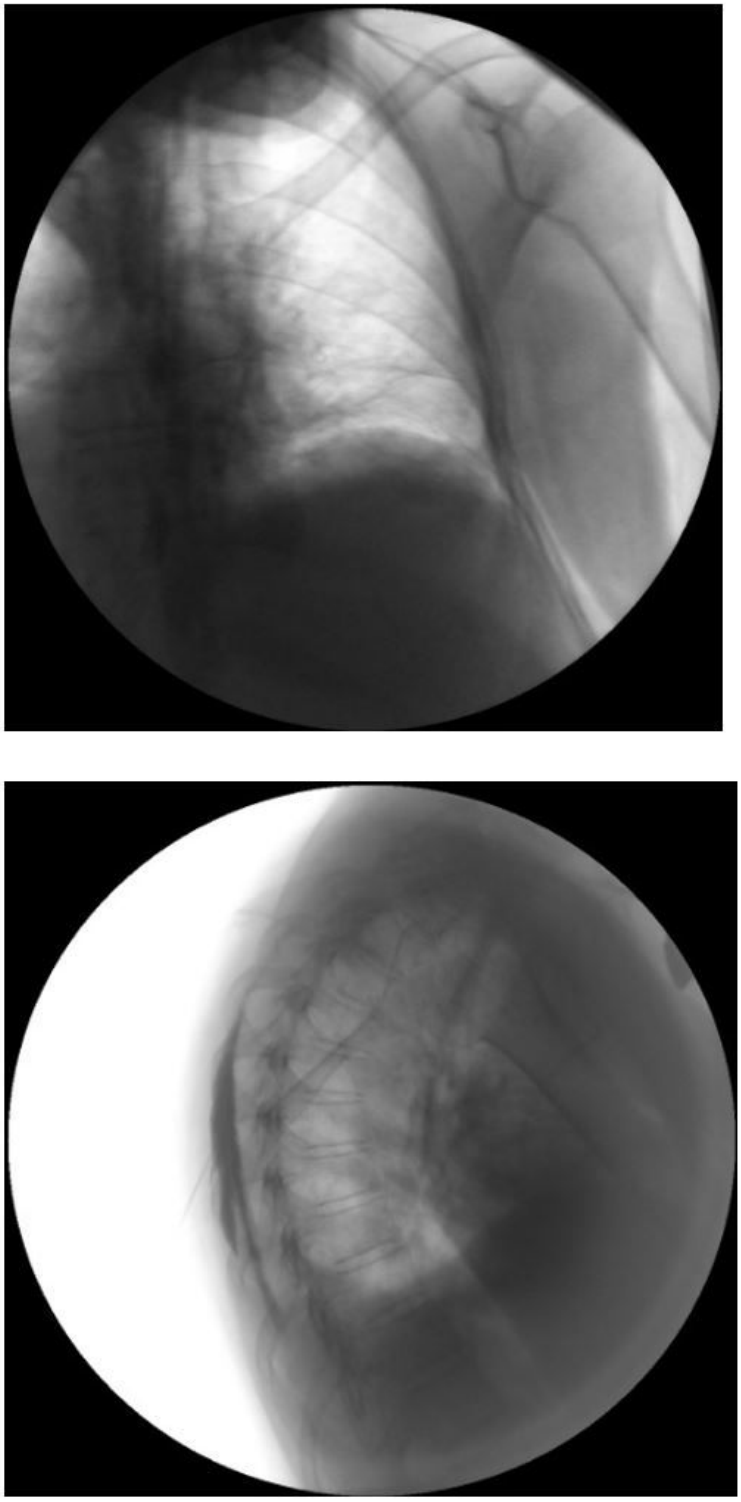

Figure 2

A-B: Dispersion of Injected iodinated contrast

Supplementary Files

This is a list of supplementary files associated with this preprint. Click to download.

- CARE checklist English1.docx