Research Square

Preprints are preliminary reports that have not undergone peer review. They should not be considered conclusive, used to inform clinical practice, or referenced by the media as validated information.

True Mycotic Aneurysms: A Report of Three Patients with Internal Carotid Artery Aneurysm and Mucormycosis, and Literature Review

Mahtab Rostamihosseinkhani
Shiraz University of Medical Sciences
Etrat Hooshmandi
Shiraz University of Medical Sciences
Masoud Janipour
Shiraz University of Medical Sciences
Nima Fadakar
Shiraz University of Medical Sciences
Vahid Reza Ostovan
Shiraz University of Medical Sciences
Hanieh Bazrafshan
Shiraz University of Medical Sciences
Zahra Bahrami
Shiraz University of Medical Sciences
Sadegh Izadi
Shiraz University of Medical Sciences
Abbas Rahimi-Jaberi
Shiraz University of Medical Sciences
Maryam Poursadeghfard
Shiraz University of Medical Sciences
Masoumeh Nazeri
Shiraz University of Medical Sciences
Peyman Petramfar
Shiraz University of Medical Sciences
Razieh Shafaei
Shiraz University of Medical Sciences
Fatemeh KianiAra
Shiraz University of Medical Sciences
Marzieh Basir
Shiraz University of Medical Sciences
Mehrdad Estakhr
Shiraz University of Medical Sciences
Zahra Ghotbi
Shiraz University of Medical Sciences
Behzad Khademi
Shiraz University of Medical Sciences
Mahsa Kohandel-Shirazi
Shiraz University of Medical Sciences
Mohammad Saied Salehi
Shiraz University of Medical Sciences
Pariya Kouhi
Shiraz University of Medical Sciences
Anahid Safari
Shiraz University of Medical Sciences
Amir Rudgari
Shiraz University of Medical Sciences
Nahid Ashjazadeh
Shiraz University of Medical Sciences
Bijan Khademi
Shiraz University of Medical Sciences
Mohammad Javad Ashraf

Shiraz University of Medical Sciences
Owrang Eilami
Shiraz University of Medical Sciences
Mohsen Moghaddami
Shiraz University of Medical Sciences
Kamiar Zomorodian
Shiraz University of Medical Sciences
Carlos Garcia Esperson
University of Newcastle
Neil Spratt
University of Newcastle
Christopher Levi
University of Newcastle
Afshin Borhani-Haghighi (neuro.ab@gmail.com)
Shiraz University of Medical Sciences

Research Article

Keywords: Aneurysm, Mucormycosis, Internal Carotid Artery, Rhino-cerebral mucormycosis

Posted Date: August 31st, 2021

DOI: https://doi.org/10.21203/rs.3.rs-853134/v1

License: This work is licensed under a Creative Commons Attribution 4.0 International License. Read Full License

---

Abstract

Background

Aneurysm formation of internal carotid arteries (ICA) in patients with mucormycosis is a scarce phenomenon. However, the prevalence of rhino-cerebral mucormycosis has been reported to increase after the coronavirus disease 2019 (COVID-19) pandemic.

Methods

Three patients with stroke and subarachnoid hemorrhage due to ICA aneurysm after the involvement of adjacent paranasal sinuses with mucormycosis were presented. All patients were recruited from Namazi and Khalili hospitals affiliated with Shiraz University of Medical Sciences in Iran from April 2021 to May 2021.

Results

They had a history of diabetes and corticosteroid use. Also, one of them was treated with imatinib. Two out of three patients were infected with SARS-CoV-2 infection before developing mucormycosis. Two patients had diagnostic angiography before endovascular intervention. One patient did not undergo any therapeutic intervention due to total artery occlusion, whereas the other patient experienced a successful parent artery occlusion by coiling, and only this patient survived. Although all patients received antifungal treatment and surgical debridement, two of them died.

Conclusions

In the patients with rhino-cerebral mucormycosis evolving of aneurysm should be promptly and meticulously investigated by magnetic resonance angiography (MRA) and computed tomography angiography (CTA). As this type of aneurysms was very fast-growing, as soon as the involvement of sphenoid sinus was detected, the possibility of ICA aneurysm formation should always be kept in mind. If the patient developed an aneurysm, prompt intensive antifungal therapy and therapeutic endovascular interventions such as stenting, coiling, or sacrificing should be considered as soon as possible to optimize outcomes.

Background

Aneurysm formation of internal carotid arteries (ICA) in patients with mucormycosis is a scarce phenomenon [1–11]. Meanwhile, the prevalence of rhino-cerebral mucormycosis has been reported to increase after the coronavirus disease 2019 (COVID-19) pandemic [12–18].

Herein, we presented three patients with stroke and subarachnoid hemorrhage due to ICA aneurysm after the involvement of adjacent paranasal sinuses with mucormycosis. Two of them had a history of severe acute respiratory syndrome coronavirus 2 (SARS-CoV-2) infection. All patients were recruited from Namazi and Khalili hospitals affiliated with Shiraz University of Medical Sciences in Iran from April 2021 to May 2021. These are high-volume referral centers for stroke and COVID-19 in southern Iran. Table 1 summarized the clinical and radiological characteristics and outcomes of the patients. This study was approved by the ethics committee and institutional review board of Shiraz University of Medical Sciences (IR.SUMS.REC.1400.270). Written informed consent was obtained from the patient or next of kin.

Table 1
The clinical and radiologic features and outcomes of 3 patients with mycotic

Case no.	Age (years) /Sex	Time of Disease (Month of 2021)	Mucormycosis Clinical Syndrome[1]	Confirmatory Test for Mucormycosis	Mucormycosis Tempo[2]	Corticosteroid Use	Radiological Features of Brain	Radiological Features of PNS	Mucormycosis Predisposing Factors	Tre Str
1	40/M	April	Rhinocerebral	Histopathology	Subacute	Yes (DEX)	**CT**: extensive SAH.	**CT**: opacification of the left spheniod sinus and the left ethmoidal air cell. **MRI**: mucosal thickening of all paranasal sinuses	DM, cirrhosis	FES Lip am
2	47/M	April	Rhinocerebral	Histopathology	Subacute	Yes (DEX)	**MRI**: right sided watershed infarct .	**MRI**: pan sinusitis	DM	FES Lip am
3	54/M	April	Rhinocerebral	Histopathology	Subacute	Yes (DEX)	**MRI**: left MCA territory massive infarction	**CT**: mucosal thickening of the left maxillary sinus and ethmoidal air cells. **MRI**: mucosal thickening of the left frontal sinuses and sphenoid sinuses and ethmoidal air cells,	DM, GIST, using imatinib	FES Lip am

DM: diabetes mellitus; **GIST**: gastrointestinal stromal tumor; **FESS**: Functional endoscopic sinus surgery; **DEX**: Dexamethasone; **ICA**: Internal carotid artery; **M** dehydrogenase; **ALT**: Alanine transaminase; **AST**: Aspartate transaminase

1. Mucormycosis Clinical Syndrome: rhinocerebral, pulmonary, Cutaneous, gastrointestinal, Disseminated.

2. Mucormycosis Tempo: acute (< 48 hours); subacute (48 hours to 30 days); chronic (> One month).

3. Interval between the clinical suspicion to mucormycosis and the diagnosis of aneurysm (days).

Case Presentation

Patient-1

A 40-year-old male with a past medical history of unexplained thrombocytopenia and smoking was admitted to outside hospital following a four-day history of cough, fever, and shortness of breath. In the initial evaluation, the real-time reverse transcription-polymerase chain reaction (RT-PCR) of nasopharyngeal and oropharyngeal for SARS-CoV-2 was positive, blood sugar level: 343 mg (normal: 74–99 mg), platelet count: $43*10^{3}/mm^{3}$, and he was treated with intravenous (IV) remdesivir (200 mg IV on day one and 100 mg daily for four days), dexamethasone (8mg IV daily for seven days) and IV insulin. Abdominal sonography was consistent with liver cirrhosis. On day fourth of admission, he developed headache, binocular diplopia, left eye ptosis, and decreased vision in the left eye. Computed tomography (CT) of the brain was normal, and the paranasal sinuses (PNS) CT indicated thickening of the mucosa in the left sphenoid and ethmoidal sinuses. Because of the clinical suspicion of mucormycosis rhinosinusitis, amphotericin B deoxycholate (1 mg/kg/day IV) has been added to the treatment regimen. The patient was transferred to our facility eight days after his admission.

At arrival to our center, the patient has normal vital signs but mild tachycardia and tachypnea. He had left eye ptosis, mild proptosis, and swelling, associated with a mild chemosis in the left eye and a mild conjunctival injection in the right eye. Complete ophthalmoplegia of the left eye (III, IV, and VI nerve palsy) and partial ophthalmoplegia of the right eye (III and IV nerve palsy) were present. Both pupils were dilated and fixed, and there was no light perception on both sides. He had hypoesthesia involving the first and second branches of the left trigeminal nerve (V1, V2). Tenderness was observed on the frontal sinus. No significant findings were found on the oral and nasal cavity assessment.

A chest high-resolution computed tomography (HRCT) revealed an opacity in the upper lobe of the left lung with a central ground-glass opacity, compatible with COVID-19 infection. The brain Magnetic resonance imaging (MRI) showed no abnormalities on the brain parenchyma but identified mucosal thickening of all paranasal sinuses, mild proptosis, periorbital edema, and extraconal fat stranding, which was more prominent on the left side. Additionally, the MR venogram showed thrombosis of the left cavernous sinus and prominence of the posterior aspect of the left superior ophthalmic vein. MR angiography (MRA) showed no ICA aneurysm.

The patient was diagnosed with invasive mucormycosis rhinosinusitis and cavernous sinus thrombosis and treated with Vancomycin, Meropenem, liposomal amphotericin B (5 mg/kg/day IV), and therapeutic heparin. Abdominal ultrasound and gastrointestinal endoscopy were performed later, which confirmed splenomegaly and esophageal varices. An additional diagnosis of liver cirrhosis was performed then. Therefore, albumin was added, and anticoagulation therapy was discontinued.

He underwent Functional Endoscopic Sinus Surgery (FESS) and debulking on the second day of admission with histological findings compatible with mucormycosis infection. On the sixth day of admission, the patient developed a sudden loss of consciousness. The urgent brain CT showed a disseminated subarachnoid hemorrhage (Fisher Grading Scale:4, Hunt and Hess scale:5).

Brain CT angiography (CTA) revealed a 10x7x11mm irregularly-shaped globoid aneurysm in the clinoid portion of the left ICA (Fig. 1A).

On the eighth day of admission, he developed hypotension, electrocardiographic abnormalities, and a rise of troponins, all consistent with myocardial infarction. Unfortunately, the patient passed away on day ten after admission.

Patient-2

A 47-year-old male with a 6-year history of diabetes mellitus (DM) on metformin and glibenclamide came to our hospital with right eye ptosis and right ocular pain. He complained of body pain and cough twenty-one days before admission. Four days later, he experienced a severe throbbing headache in the bilateral frontotemporal area associated with nausea and numbness on the right side of his face and palate for ten days. He was treated with dexamethasone 8 mg IV daily for two days in an outpatient clinic. Three days PTA, he developed right eye ptosis, proptosis, blurred vision, and periorbital pain irradiated to the right ear.

At his admission, his vital signs were normal. On physical examination, he had right eye ptosis associated with proptosis and severe chemosis (mild on the left eye), with mydriatic and non-reactive pupils. The cranial nerve examination showed a right frozen eye (III, IV, and VI cranial nerves palsy), right face hypoesthesia (V1 and V2 branches of trigeminal nerve).

Initial blood sugar was 398 mg (normal: 74–99 mg), and the chest HRCT was negative for SARS-CoV-2 infection. The brain MRI didn't show any parenchymal abnormalities but confirmed right exophthalmos with extraconal fat stranding and indicated mucosal thickness in all sinuses. The brain MRA revealed no aneurysm. The chest HRCT was normal. The sinus biopsy confirmed mucormycosis (Fig. 2), and liposomal amphotericin B 300 mg daily was started, followed by FESS and debulking surgery.

On the 21st day of his admission, he experienced right peripheral facial palsy associated with mild left-sided weakness. The brain MRI revealed multiple foci of diffusion restrictions in the right side cortical-subcortical and deep white matter, suggesting anterior and posterior watershed ischemia. The brain MRA showed a fusiform aneurysm measuring approximately 15x10x9mm in the terminal portion of the right ICA (Fig. 1B). Caspofungin 50 mg IV was added to amphotericin B daily.

The day after, he developed a generalized tonic-clonic seizure. The urgent brain CT confirmed a subarachnoid hemorrhage in the right Sylvian fissure and inferior to the right frontal lobe. The patient underwent digital subtraction angiography three days later, showing a mild increase in size on the aneurysm.

He had a competent and complete circle of Willis; therefore, a parent artery occlusion was considered. A balloon occlusion test was conducted, occluding the cervical portion of the right ICA for 20 minutes using an 8 Fr Cello balloon catheter (EV3 Endovascular, Inc., Plymouth, USA), developing no neurological deficits during the procedure. As the patient had no change in these examinations, the aneurysm and parent artery coiling was done without complications. The patient was discharged home 45 days after. In the last follow-up, performed 4 months after onset, he has a normal neurological assessment (Modified Rankin Scale = 1), but the visual acuity (VA) was counting fingers at one meter in the right eye and 5 meters in the left eye.

Patient-3

A 54-year-old male with a medical history of a gastrointestinal stromal tumor (GIST) on imatinib and had high blood glucose readings (no treatment) was admitted to our facility with a painful oral cavity lesion, nasal hemorrhage, periorbital edema, and binuclear diplopia, as well as left facial paresthesia. He had respiratory symptoms fourteen days before, and a COVID-19 infection was confirmed by a PCR test, and his blood sugar was 398 mg (normal: 74–99 mg). Insulin, remdisivir, and corticosteroids (Dexamethasone 8mg three times a day for 2 days, followed by 250mg methylprednisolone pulse daily for 6 days) were administered in an outside hospital.

On arrival, he was tachypneic and his oxygen saturation level was 84% on room air. The physical assessment showed left periorbital edema, ptosis, proptosis, and chemosis of the left eye. There was a left sixth nerve palsy associated with left face hypoesthesia (V1 and V2 branches of trigeminal nerve). There was a

painful white lesion in the oral cavity and necrotic tissue in the left nasal cavity. The chest HRCT demonstrated bilaterally diffuse ground-glass opacity, and the PNS CT was consistent with mucosal thickening of the left maxillary sinuses and ethmoidal air cells.

A biopsy sample of nasal turbinates confirmed mucormycosis, and the nasal cavity was debrided; consequently, the patient was treated with liposomal amphotericin B (5 mg/kg/day IV). On the seventh day of admission, the patient underwent FESS and debulking surgery.

On day nine from admission, he suffered a sudden onset of aphasia, right-sided weakness, and a frozen left eye. The brain MRI demonstrated several foci of left parietooccipital diffusion restriction suggestive of an acute ischemic infarct. Additionally, the frontal, ethmoid, and sphenoidal sinuses exhibited opacification and mucosal thickening. The brain MRA revealed a 15x8x9mm irregularly-shaped fusiform aneurysm in the cavernous portion of the left ICA with severe narrowing of supraclinoid portion just after aneurysm (Fig. 1C). Two days later, the patient underwent DSA, which showed complete occlusion of the left ICA. He developed a decreased level of consciousness and left-sided weakness on the thirteenth day of hospitalization. A second brain MRI indicated several high-intensity T2 FLAIR signals with diffusion restriction in the left temporoparietal lobe and basal ganglia, consistent with acute infarction. The patient's condition deteriorated, and he developed vasogenic edema secondary to the ischemic stroke associated with a 4 mm midline shift. He underwent a hemicraniotomy; unfortunately, he did not improve clinically and was deceased 55 days after the initial diagnosis.

Discussion

Herein, we presented three patients with mucormycosis and ICA aneurysm. All of them had a history of uncontrolled diabetes and corticosteroid use, and one of them was treated with a tyrosine kinase inhibitor, imatinib. Two patients were infected with SARS-CoV-2 infection before developing mucormycosis. The progression of mucormycosis vasculopathy to aneurysm formation or complete occlusion was very rapid. Although all three patients had received antifungal treatment and surgical debridement and controlled their diabetes and COVID-19 infection, unfortunately, two out of three patients died. Although one of our patients could not have endovascular intervention due to unstable conditions, the other two had diagnostic angiography before endovascular intervention. One patient did not undergo any therapeutic intervention due to total artery occlusion, whereas the other patient experienced a successful parent artery occlusion by coiling. Interestingly only this patient survived. Patient 2 had a normal brain MRA in the early course of mucormycosis. However, 15 days after, a second brain MRI revealed a large carotid aneurysm. This indicates the rapidly-growing nature of mucormycosis-associated internal carotid aneurysms. Configuration of ICA aneurysm in current series is mostly irregularly-shaped and fusiform aneurysm which is more similar to dissecting aneurysm rather than saccular aneurysm.

Bacterial pathogens cause most infection-associated mycotic aneurysms in the context of endocarditis. An aneurysm develops in the setting of antecedent systemic infections with bacteremia or through the direct local invasion of the vessel wall (e.g., IV drug users) in the pre-existing aneurysm or atheromatous plaques [19]. The bacterial infection causes the release of pro-inflammatory cytokines, polymorphonuclear (PMN) leukocytes infiltration, and activation of matrix metalloproteinases, resulting in the focal vessel wall disintegration [20].

Although fungal germs are a relatively uncommon cause of cerebral aneurysms, they can occur in immunocompromised patients due to diabetes, hematological malignancy, systemic chemotherapy, HIV (human immunodeficiency virus) infection, or fungal dissemination [21]. Fungal agents that can cause mycotic aneurysms mainly include *Candida* species and *Aspergillus* species [22].

Fungal aneurysms of carotid arteries are extremely rare [9]. Fungal aneurysms pose challenges for diagnosis and management because they are rare, unpredictable, and often occur in a clinical context that is neither specific nor alarming. The treatment strategy is controversial owing to the risk of complications associated with surgery of the cavernous sinus. Pathologic investigations demonstrate that fungal aneurysms typically impact the circle of Willis and the proximal arterial tree. They tend to develop and expand, moving long segments of the vascular wall, and they are friable and poorly defined. As a result, endovascular or surgical therapy is challenging, if not impossible, and has a very high mortality rate [23, 24].

An increase in mucormycosis cases has been reported since the outbreak of the COVID-19 pandemic. There are several reports of mycotic associated with COVID-19 infection [12–18] in patients with a history of diabetes and other risk factors. Diabetes, even without diabetic ketoacidosis, is known to be the most critical risk factor for mycotic aneurysms. Additionally, new studies have found that poorly controlled DM is also a predictor of complications such as COVID-19 infection severity and hospitalization. On the other hand, it has been reported that SARS-CoV-1 could result in acute diabetes and diabetic ketoacidosis [25]. Besides, high expression of angiotensin-converting enzyme 2 receptors in pancreatic islets, along with increased insulin resistance because of cytokine storm [26], may explain the diabetogenic possibility of SARS-CoV-2 infection. While current guidelines recommend using corticosteroids to treat severe or critical COVID-19, the evidence suggests that the frequent use of steroids exacerbates glucose homeostasis and makes susceptible patients to mucormycosis [27, 28]. Hence, in the COVID-19 pandemic period, the use of corticosteroids in diabetic patients should be prescribed with extreme caution. Also, the physicians should be highly suspicious of COVID-19-associated mucormycosis, as the convergence of SARS-CoV-2 infection and uncontrolled DM can cause a mucormycosis storm.

A review of cases of mucormycosis associated with an intracranial aneurysm was performed, and it was shown that mucormycosis has a high mortality (11 out of 14 patients (78.6%)) (Table 2). The mean age was 48 years. Aneurysm formation after the involvement of adjacent paranasal sinuses with mucormycosis occurs in a matter of days. The most common predisposing factors were DM, using steroids, hematopoietic and GI cancer, chemotherapy, and transsphenoidal surgery. The most common sites of aneurysm were internal carotid artery which occurred in about half of the patients. Aneurysm caused complications via rupture and subarachnoid hemorrhage in 8 patients and artery to artery embolism and ischemic infarction in 4 patients. In 2 patients, aneurysms were found in imaging workups done in patients who developed cavernous sinus syndromes. These aneurysms were very rapidly growing as they develop between 10 to 68 days after the evolution of mucormycosis.

Table 2
An overview of clinical features and outcomes of the published cases diagnosed with mycotic aneu

Case no.	Age (years) /Sex	Mucormycosis Clinical Syndrome[1]	Confirmatory Test for Fungal Infection	Mucormycosis Tempo[2]	Corticosteroid Use (type)	Radiological Features	Mucormycosis Predisposing Factors	Tre Stu
Price D, et al [1]	38/M	Rhino-orbito cerebral	Histopathology (mucor)	chronic	No	**Sinus radiography**: gross opacification of the right ethmoid and sphenoid sinuses and moderate opacification of the left ethmoid and sphenoid sinuses, bone destruction of the right side of the sphenoid body. **DSA**: irregular narrowing of the right ICA over a distance of 1.5 cm.	DM with DKA	An pa su de
Glass EC, et al [2]	4/ F	cerebral	Autopsy Phycomycetes (Mucor)	acute	Yes (NM)	**Brain scan using 99TC-pertechnetate**: clearly visualized of the ventricles, the left lateral ventricle appearing larger.	Prolonged steroid use	NA
Ho K-L [3]	48 / F	Rhinocerebral	Histopathology (mucor)	subacute	No	**DSA**: a large avascular space on the right side, compatible with subdural hematoma.	Early DM with DKA	pe po ch ny Int am
Kikuchi K, et al [4]	61/ M	cerebral	Autopsy Phycomycetes (Mucor)	subacute	Yes (HC)	**DSA**: four aneurysms originating from the left pericallosal artery and complete disappearance of the right ACA and MCA	Craniotomy, Prolonged steroid use	NA
Thajeb P, et al [5]	62/M	Rhino-orbito cerebral	Histopathology (mucor)	Subacute	No	**MRI**: lesions in the left orbital apex and the inferior part of the left cavernous sinus **CT**: severe SAH with hydrocephalus and cerebral infarctions in the left frontal lobe, left pontomesencephalon, left cerebellum, and bilateral thalami.	DM, spontaneous infection of left orbital apex and cavernous sinus	am pa su de
Kasliwal MK, et al [6]	61/M	cerebral	Histopathology (mucor)	NM	NO	**MRI**: postoperative changes with a small amount of residual tumor and a left basal ganglia infarct. **CT**: SAH. **DSA**: bilateral, almost mirror image-like, fusiform aneurysms of the right ACA.	DM, non-functional pituitary macroadenoma, transsphenoidal surgery, prolonged administration of antibiotics	am lip am Su su de

ACA: anterior cerebral artery; **CT**: computed tomography; **MCA**: middle cerebral artery; **MRI**: magnetic resonance imaging; **DSA**: digital subtraction angiograph leukemia; **ICA**: internal carotid artery; **ESRD**: end stage renal disease; **SCA**: superior cerebellar artery; **NM**: Not mentioned; **NA**: Not Applicable

1. Mucormycosis Clinical Syndrome: Rhinocerebral, Pulmonary, Cutaneous, Gastrointestinal, Disseminated.

2. Mucormycosis Tempo: acute (< 48 hours); subacute (48 hours to 30 days); chronic (> One month).

3. Interval between the clinical suspicion to mucormycosis and the diagnosis of aneurysm (days).

Case no.	Age (years) /Sex	Mucormycosis Clinical Syndrome[1]	Confirmatory Test for Fungal Infection	Mucormycosis Tempo[2]	Corticosteroid Use (type)	Radiological Features	Mucormycosis Predisposing Factors	Tre Stu
Alvernia JE, et al [7]	38 /M	Rhino cerebral	Histopathology (mucor)	subacute	No	**CT**: Inflammatory process involving the paranasal sinuses with extension into the left cavernous sinus and left petrous bone **DSA**: 50% stenosis of the left ICA at its petrous portion as well as a bilobulate pseudoaneurysm originated at the same level.	DM	top clo pa lip am hy ox pa su de ato
Dusart A, et al [8]	64/M	Rhinocerebral	Autopsy (mucor)	chronic	Yes (HC)	**MRI**: an extensive sphenoid sinusopathy, a huge fusiform aneurysmal dilatation of the right intracavernous ICA, a suprasellar extension of the mass, spontaneous thrombosis, right thalamic infarction. **CT**: inflammatory-induced bone modifications, bone defects between sphenoid and cavernous sinuses	somatotropic macroadenoma (treated by transsphenoidal surgery and radiotherapy 21 years ago)	No tre

ACA: anterior cerebral artery; **CT**: computed tomography; **MCA**: middle cerebral artery; **MRI**: magnetic resonance imaging; **DSA**: digital subtraction angiograph leukemia; **ICA**: internal carotid artery; **ESRD**: end stage renal disease; **SCA**: superior cerebellar artery; **NM**: Not mentioned; **NA**: Not Applicable

1. Mucormycosis Clinical Syndrome: Rhinocerebral, Pulmonary, Cutaneous, Gastrointestinal, Disseminated.

2. Mucormycosis Tempo: acute (< 48 hours); subacute (48 hours to 30 days); chronic (> One month).

3. Interval between the clinical suspicion to mucormycosis and the diagnosis of aneurysm (days).

Case no.	Age (years) /Sex	Mucormycosis Clinical Syndrome[1]	Confirmatory Test for Fungal Infection	Mucormycosis Tempo[2]	Corticosteroid Use (type)	Radiological Features	Mucormycosis Predisposing Factors	Tre Stu
Azar MM, et al [9]	71/F	Rhinocerebral	Histopathology (mucor)	Subacute	No	**CT**: extensive right frontal, sphenoid, ethmoid, and maxillary sinusitis with extraosseous spread into the orbital area and pterygopalatine fossa, and possibly a cavernous sinus thrombosis. **MRI**: enlargement of the signal void at the distal cavernous segment of the right ICA.	DM, AML, using chemotherapy	lip an me va vo mo pa su de
Sasannejad P, et al [10]	57/M	Rhinocerebral	histopathology (mucor)	subacute	NO	**CT**: extensive SAH. **CTA**: two consecutive fusiform aneurysms in a SCA. **MRI**: infarction of the cerebellum in the territory superior cerebellar artery.	DM	An wi an Na de
Rangwala SD, et al [11]	27/F	primary pulmonary mucormycosisdeveloped with cerebral mucormycosis	Histopathology (mucor)	Subacute	Yes (NM)	**CT & CTA**: intraparenchymal hemorrhage of the left temporoparietal lobe measuring 2.6 × 2.6 × 3.7 cm, with an underlying multilobulated aneurysm of the distal left MCA.	systemic lupus, erythematous, using steroid	am

ACA: anterior cerebral artery; **CT**: computed tomography; **MCA**: middle cerebral artery; **MRI**: magnetic resonance imaging; **DSA**: digital subtraction angiograph leukemia; **ICA**: internal carotid artery; **ESRD**: end stage renal disease; **SCA**: superior cerebellar artery; **NM**: Not mentioned; **NA**: Not Applicable

1. Mucormycosis Clinical Syndrome: Rhinocerebral, Pulmonary, Cutaneous, Gastrointestinal, Disseminated.

2. Mucormycosis Tempo: acute (< 48 hours); subacute (48 hours to 30 days); chronic (> One month).

3. Interval between the clinical suspicion to mucormycosis and the diagnosis of aneurysm (days).

Conclusion

In conclusion, in the patients with rhino-cerebral mucormycosis evolving of aneurysm should be promptly and meticulously investigated by MRA and CTA. Unlike other types of mycotic aneurysms, these aneurysms occur in more proximal portions, and their configuration resembles dissecting aneurysms rather than saccular ones. As this type of aneurysms was very fast-growing, as soon as the involvement of sphenoid sinus was detected, the possibility of ICA aneurysm formation should always be kept in mind. If the patient developed an aneurysm, prompt intensive antifungal therapy and therapeutic endovascular interventions such as stenting, coiling, or sacrificing should be considered as soon as possible to optimize outcomes.

Abbreviations

ICA: Internal carotid arteries; COVID-19: Coronavirus disease 2019; SARS-CoV-2: Severe acute respiratory syndrome coronavirus 2; MRA: Magnetic resonance angiography; CTA: Computed tomography angiography; MRI: Magnetic resonance imaging; RT-PCR: Real-time reverse transcription-polymerase chain reaction; PNS: Paranasal sinuses; HRCT: High-resolution computed tomography; FESS: Functional Endoscopic Sinus Surgery; GIST: Gastrointestinal stromal tumor; DM: Diabetes mellitus.

Declarations

Acknowledgements

We gratefully acknowledge the partnership with the Namazi and Khalili hospitals' staff.

Authors' Contributions

All authors contributed to the study conception and design. Material preparation and data collection were performed by MR, EH, MJ, NF, VRO, HB, ZB, SI, ARJ, MP, MN, PP, RS, FK, MB, ME, ZG, BK, MKS, MSS, PK, AS, AR, NA, BK, MJA, OE, MM, and KZ. The first draft of the manuscript was written by MR, EH, ABH, and all authors commented on previous versions of the manuscript. All authors read and approved the final manuscript.

Funding

None.

Availability of data and materials

The datasets used in the current study are available from the corresponding author on reasonable request.

Declarations

Ethics approval and consent to participate

All protocols and consent forms were approved by the ethics committee and institutional review board of Shiraz University of Medical Sciences (IR.SUMS.REC.1400.270). All written consent forms were signed by the research participants or next of kin.

Consent for publication

Written informed consent was obtained from the patient for publication of this case report and any accompanying images.

Competing interests

The authors declare that they have no competing interests.

References

1. Price D, Wolpow E, Richardson Jr E. Intracranial phycomycosis: a clinicopathological and radiological study. J Neurol Sci. 1971;14(3):359–75.
2. Glass EC, Stadalnik RC, Barnett CA. Ventricular visualization on brain scan with intracranial hemorrhage in disseminated phycomycosis. Clin Nucl Med. 1978;3(11):429–31.
3. Ho K-L. Acute subdural hematoma and intracerebral hemorrhage: Rare complications of rhinocerebral mucormycosis. Arch Otolaryngol. 1979;105(5):279–81.
4. Kikuchi K, Watanabe K, Sugawara A, Kowada M. Multiple fungal aneurysms: report of a rare case implicating steroid as predisposing factor. Surg Neurol. 1985;24(3):253–9.
5. Thajeb P, Thajeb T, Dai D. Fatal strokes in patients with rhino-orbito-cerebral mucormycosis and associated vasculopathy. Scand J Infect Dis. 2004;36(9):643–8.
6. Kasliwal MK, Reddy VSK, Sinha S, Sharma BS, Das P, Suri V. Bilateral anterior cerebral artery aneurysm due to mucormycosis. J Clin Neurosci. 2009;16(1):156–9.
7. Alvernia JE, Patel RN, Cai DZ, Dang N, Anderson DW, Melgar M. A successful combined endovascular and surgical treatment of a cranial base mucormycosis with an associated internal carotid artery pseudoaneurysm. Neurosurgery. 2009;65(4):733–40.
8. Dusart A, Duprez T, Van Snick S, Godfraind C, Sindic C. Fatal rhinocerebral mucormycosis with intracavernous carotid aneurysm and thrombosis: a late complication of transsphenoidal surgery? Acta Neurol Belg. 2013;113(2):179–84.
9. Azar MM, Assi R, Patel N, Malinis MF. Fungal mycotic aneurysm of the internal carotid artery associated with sphenoid sinusitis in an immunocompromised patient: a case report and review of the literature. Mycopathologia. 2016;181(5–6):425–33.
10. Sasannejad P, Ghabeli-Juibary A, Aminzadeh S, Olfati N. Cerebellar infarction and aneurysmal subarachnoid hemorrhage: An unusual presentation and rare complications of rhinocerebral mucormycosis. Iran J Neurol. 2015;14(4):222–4.
11. Rangwala SD, Strickland BA, Rennert RC, Ravina K, Bakhsheshian J, Hurth K, et al. Ruptured Mycotic Aneurysm of the Distal Circulation in a Patient with Mucormycosis Without Direct Skull Base Extension: Case Report. Oper Neurosurg. 2019;16(3):E101-E7.
12. Sharma S, Grover M, Bhargava S, Samdani S, Kataria T. Post coronavirus disease mucormycosis: a deadly addition to the pandemic spectrum. J Laryngol Otol. 2021;135(5):442–7.
13. Song G, Liang G, Liu W. Fungal co-infections associated with global COVID-19 pandemic: a clinical and diagnostic perspective from China. Mycopathologia. 2020;185(4):599–606.
14. Nehara HR, Puri I, Singhal V, Sunil I, Bishnoi BR, Sirohi P. Rhinocerebral mucormycosis in COVID-19 patient with diabetes a deadly trio: Case series from the north-western part of India. Indian J Med Microbiol. 2021;39(3):380–383.
15. Awal SS, Biswas SS, Awal SK. Rhino-orbital mucormycosis in COVID-19 patients—a new threat? EJRNM. 2021;52(1):1–6.
16. Sethi HS, Sen KK, Mohanty SS, Panda S, Krishna KR, Mali C. COVID-19-associated rhino-orbital mucormycosis (CAROM)—a case report. EJRNM. 2021;52(1):1–6.
17. Revannavar SM, Supriya P, Samaga L, Vineeth V. COVID-19 triggering mucormycosis in a susceptible patient: a new phenomenon in the developing world? BMJ Case Rep. 2021;14(4):e241663.

18. Ostovan VR, Rezapanah S, Behzadi Z, Hosseini L, Jahangiri R, Anbardar MH, et al. Coronavirus disease (COVID-19) complicated by rhino-orbital-cerebral mucormycosis presenting with neurovascular thrombosis: a case report and review of literature. J Neurovirol. 2021;1–6. Online ahead of print.
19. Stone JR, Bruneval P, Angelini A, Bartoloni G, Basso C, Batoroeva L, et al. Consensus statement on surgical pathology of the aorta from the Society for Cardiovascular Pathology and the Association for European Cardiovascular Pathology: I. Inflammatory diseases. Cardiovasc Pathol. 2015;24(5):267–78.
20. De Caridi G, Massara M, Spinelli F, Grande R, Butrico L, Rende P, et al. An uncommon case of arterial aneurysms association with high plasma levels of Matrix Metalloproteinase-9 and Neutrophil Gelatinase-Associated Lipocalin. Open Med (Wars). 2015;10(1):492–497.
21. Wu SJ, Huddin JC, Wanger A, Estrera AL, Buja LM. A case of Brucella aortitis associated with development of thoracic aortic aneurysm and aortobronchial fistula. Cardiovasc Pathol. 2019;39:5–7.
22. Roach MR, Drake C. Ruptured cerebral aneurysms caused by micro-organisms. New Engl J Med. 1965;273(5):240–4.
23. Watson JC, Myseros JS, Bullock MR. True fungal mycotic aneurysm of the basilar artery: a clinical and surgical dilemma. Cerebrovasc Dis. 1999;9(1):50–3.
24. Hurst RW, Judkins A, Bolger W, Chu A, Loevner LA. Mycotic aneurysm and cerebral infarction resulting from fungal sinusitis: imaging and pathologic correlation. AJNR Am J Neuroradiol. 2001;22(5):858–63.
25. Yang J-K, Lin S-S, Ji X-J, Guo L-M. Binding of SARS coronavirus to its receptor damages islets and causes acute diabetes. Acta Diabetol. 2010;47(3):193–9.
26. Kothandaraman N, Rengaraj A, Xue B, Yew WS, Velan SS, Karnani N, et al. COVID-19 endocrinopathy with hindsight from SARS. Am J Physiol Endocrinol Metab. 2021;320(1):E139-E50.
27. Lionakis MS, Kontoyiannis DP. Glucocorticoids and invasive fungal infections. Lancet. 2003;362(9398):1828–38.
28. Verma DK, Bali RK. COVID-19 and Mucormycosis of the Craniofacial skeleton: Causal, Contributory or Coincidental? J Maxillofac Oral Surg. 2021;20(2):1–2.

Figures

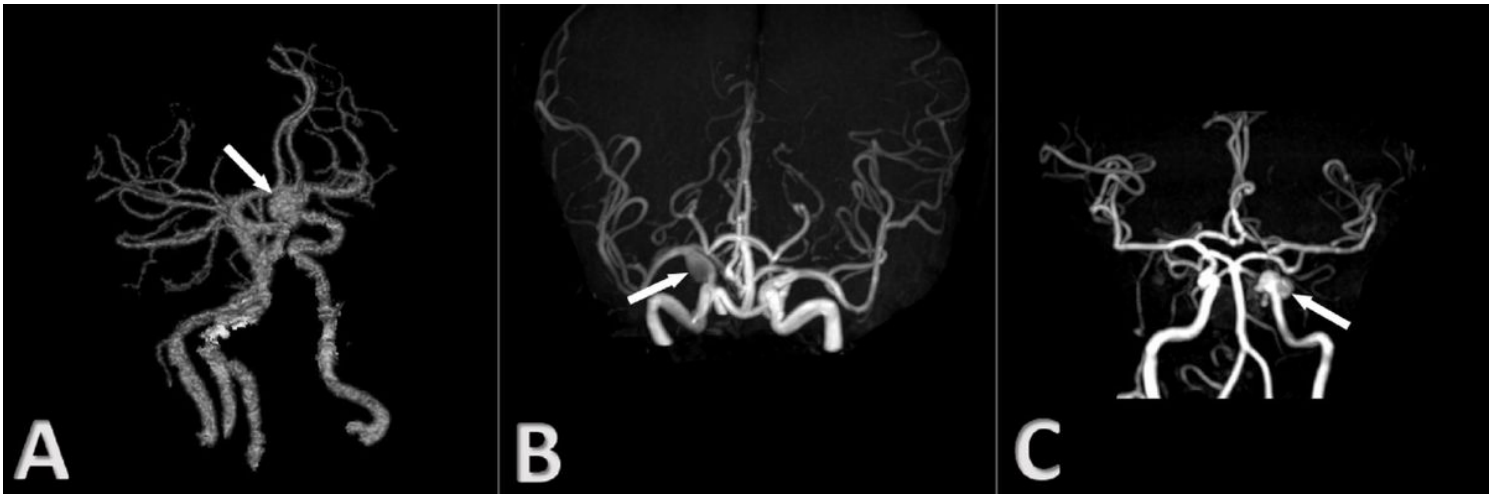

Figure 1

(A) Brain CTA shows a left ICA aneurysm in a patient presented with SAH (white arrow). (B) Brain MRA shows a right ICA aneurysm in a patient presented with ischemic stroke (white arrow). (C) Brain MRA shows left ICA aneurysm in a patient presented with ischemic stroke (white arrow).

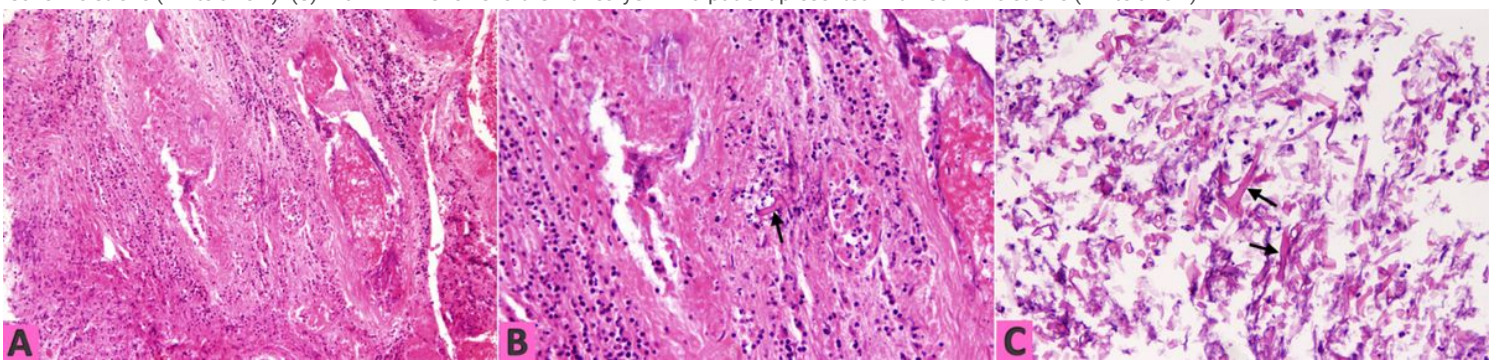

Figure 2

(A) Necrosis with severe acute inflammation and vasculitis, H&E stain (x100). (B) Thrombosed vessels and fungal hypha in the vessel wall (black arrow), H&E stain (x250). (C) Ribbon-like broad non-septate hyphae (black arrow), H&E stain (x250).