Modified Vein Clamping Technique for Renal Cell Carcinoma Complicated With Level I-II IVC Thrombus: A Study At A Single Center

Jiaxing Ma
the Second Affiliated Hospital of Anhui Medical University
Wei Sun
the Second Affiliated Hospital of Anhui Medical University
Weiwei Qian
the Second Affiliated Hospital of Anhui Medical University
Jie Min
the Second Affiliated Hospital of Anhui Medical University
Tao Zhang
the Second Affiliated Hospital of Anhui Medical University
Dexin Yu (yudx_urology@126.com)
the Second Affiliated Hospital of Anhui Medical University

Research Article

Keywords: Renal cell carcinoma, Tumor thrombus, Laparoscopy, Modified vein clamping technique

Posted Date: September 20th, 2021

DOI: https://doi.org/10.21203/rs.3.rs-855915/v1

Abstract

Objectives

To share our initial experience with modified vein clamping technique for the treatment of renal cell carcinoma complicated with the level I-II IVC thrombus

Methods

From March 2018 to April 2021, 11 patients with renal cell carcinoma (RCC) involving the IVC tumor thrombus were admitted to our hospital. Then, they all underwent laparoscopic radical nephrectomy and IVC thrombectomy (LRN-IVCTE) using modified vein clamping technique.

Results

All procedures were successfully completed without conversion to open surgery. The median operative time was 185 min (range 125–229 min); the median estimated blood loss was 200 ml (range 150–300 ml), and four patients received an intraoperative transfusion. Besides, the median IVC clamping time was 18 min (range 10–24 min); the median postoperative hospital stay was 6 days (range 4–8 days), while the median follow-up period was 28 months (range 2–36 months).

Conclusions

Modified vein clamping technique for the treatment of renal cell carcinoma complicated with the level I-II IVC thrombus may be a safe and technically feasible alternative technic.

Introduction

Tumor thrombus can be found in many cases of renal cell carcinoma (RCC). Most of tumor thrombus are located in renal vein and inferior vena cava, accounting for about 10%, while a few are located in heart, accounting for about 1%.[1] Compared with other treatments, nephrectomy with IVC thrombectomy is becoming a more popular option because it provides a better prognosis.[2] For the treatment of RCC, patients who underwent radical nephrectomy with any level of IVC thrombectomy have a satisfactory 5-year survival rate of 64%.[3]In fact, with the introduction of novel therapeutic agents, the survival rate has been significantly improved recently. Regardless of the thrombus level, early surgical resection is still the classic treatment in non-metastatic RCC patients with the IVC thrombus.[4] Besides, in RCC metastatic patients, the treatment of the primary tumor may be indicated in cytoreductive setting, as it ensures a lower level of circulating tumor-derived immunosuppressive factors and a better prognosis.[5] Furthermore, the open approach has previously been considered the standard when performing radical nephrectomy with IVC thrombectomy. More recently, the focus has shifted towards the minimally-invasive

techniques (laparoscopy and robotic assistance) whose feasibility for performing extremely complex surgeries has been proven.[6] In this case, how to ensure maximal oncologic control with minimal morbidity for the patient is the current challenge for the surgical treatment of RCC with the IVC thrombus. Since Varkarakis et al.[7] first reported their experience with LRN-VCTE in 2004, several reports have been published.[8–11] Recently, robot-assisted surgery has also been reported.[12–14] Considering that, it can be seen that all these reports just described their major surgical procedure and oncologic results, whereas there is no relevant research on the technique of vein clamping.

Now, in this study, our initial experience with modified vein clamping technique for the treatment of renal cell carcinoma with the level I-II IVC thrombus in our single medical center is presented.

Patients And Methods

Patients

We retrospectively evaluated the records of 11 patients with RCC involving the IVC tumor thrombus (level I-II) who underwent laparoscopic radical nephrectomy and IVC thrombectomy (LRN-IVCTE) at our hospital from March 2018 to April 2021. However, patients in whom the primary tumor was invading adjacent organs, who had multiple distant metastases, or in whom the IVC was extensively infiltrated by the thrombus were excluded from laparoscopic IVC thrombectomy, except the single metastatic lesion. Apart from that, patients with a history of upper abdominal surgery and those with an unacceptable anesthetic risk and cardiopulmonary insufficiency were also not involved. Then, patient characteristics (age, sex, body mass index, ASA score, clinical stage, size of renal tumor, IVC thrombus classification, and thrombus length) were assessed. In total, eight cases had RCC on the right side and three on the left. All patients underwent abdominal magnetic resonance imaging (MRI), abdominal enhanced computed tomography (CT), and chest CT before the operation, so that tumor size (cm) and thrombus length (cm) were measured from CT or MRI. Apart from that, through renal emission computed tomography (ECT), it was found out that all patients had a normal kidney on the contralateral side, whereas Mayo classification was used to evaluate the position of the IVC thrombus,[15] with the levels defined as follows: level 0, the thrombus limited to the renal vein; level I, a tumor thrombus extending ≤2 cm above the renal vein; level II, an extension of >2 cm above the renal vein, but below the hepatic vein; level III, the thrombus at the level of or above the hepatic vein but below the diaphragm; and level IV, extension above the diaphragm or into the right atrium. Here, it should be mentioned that two patients with single metastasis in the lung were administered preoperative neo-adjuvant targeted therapy for 3 months. As for the RCC, it was classified according to the American Joint Committee on Cancer 2010 TNM staging criteria.[16]

Perioperative data (median operative time, estimated blood loss, IVC clamping time, blood transfusion, preoperative and postoperative serum creatinine, preoperative and postoperative alanine aminotransferase (ALT) and aspartate aminotransferase (AST), preoperative and postoperative

hemoglobin, and perioperative complications) were assessed. Other than that, perioperative complications were graded according to the Clavien-Dindo classification.[17]

All procedures were performed by a single surgeon (Dexin Yu) with LRN-IVCTE using modified vein clamping technique.

This study was carried out in accordance with *the Helsinki Declaration* and was approved by the Research Ethics Committee at the Second Affiliated Hospital of Anhui Medical University. Besides, written informed consent was obtained from all participants prior to their inclusion within this study.

Preoperative preparation

Following the enhanced recovery after surgery (ERAS) protocol, general preoperative preparation included preoperative skin preparation, fasting for 6h and water-deprivation for 2h, except water enema and placement of an indwelling gastric tube. The anticoagulation therapy used in these patients was 1 mg/kg enoxaparin subcutaneously twice a day, from the moment of diagnosis and paused 12 hours before surgery. Then, twelve hours after the procedure, the anticoagulation therapy was resumed and continued up to 21 days.[18-19] Moreover, special preoperative preparation contained renal artery embolization on the related side 1-2 h before operation in 3 patients who were diagnosed as RCC on left side with the IVC tumor thrombus.

Surgical procedure

The pure LRN-IVCTE was performed in all cases. All procedures were followed by a single surgical team with experience in open surgery and laparoscopic surgery, and besides, the transperitoneal approach was adopted in all patients. Furthermore, transesophageal echocardiography was used to monitor the extent and stability of the thrombus and to ensure that the tumor thrombus was removed completely during surgical manipulation.

For right RCC, no patient accepted preoperative right renal artery embolization. After general anesthesia and Foley catheter placement, patients were placed in the 70°flank position on a flat bed, when four laparoscopic ports were in the right lumbar area (Figure 1). In addition, insufflation with CO2 having a pressure of 15 mmHg was conducted, and the hepatocolic ligament was incised, while the liver was retracted cephalically. After mobilization of the colon and duodenum, the IVC was frontally exposed. Then, the surfaces of the right and left renal veins were isolated. The IVC was mobilized above and below the renal vein for a length of 3–5cm by the length of the thrombus, and the lumbar veins were transected. For the level II IVC thrombus, the gonadal vein and accessory hepatic veins were also clipped and divided for circumferential dissection of the IVC. After that, the right artery was exposed and ligated between the IVC and aorta ventralis. Apart from that, the vessel loops were placed under the IVC above and below the thrombus and around the left renal vein, which was secured with a Hem-o-lok clip prepared for clamping, followed by the caudal IVC, left renal vein, and cephalic IVC being sequentially clamped with laparoscopic bulldog clamps. Here, it should be noted that laparoscopic bulldog clamps rather than the vessel loops

directly with Hem-o-lok clips were used to clamp the veins by moderately pulling the vessel loops and narrowing the venous wall. After occlusion of the above vessels, the IVC wall was incised at the right renal vein ostium to avoid stenosis after suturing the inferior vena cava.(Figure 2) Then the thrombus was removed and fully covered with a specimen bag to prevent tumor dissemination. After the IVC lumen was irrigated with heparinized saline, the IVC was repaired with a continuous suture using the 5-0 polypropylene suture. Before the IVC was closed, the IVC tourniquet was loosened to remove any clot in the IVC. After that, the right kidney was subsequently mobilized, excised, and placed with the main body of the thrombus into the specimen bag, followed by being removed through the abdominal incision. Besides that, for the level I IVC thrombus, first of all, the caudal IVC was clamped; then, just one laparoscopic bulldog clamp was employed to clamp the left renal vein and the cephalic IVC simultaneously (Figure 3).

For left RCC, all three patients underwent preoperative left renal artery embolization so that the IVC thrombus could be directly handled, when the position and placement of ports were the same as that for the right RCC (Figure 1). The IVC combined with right and left renal veins was isolated sequentially. Beyond that, the caudal IVC, right renal vein, and cephalic IVC were sequentially clamped using laparoscopic bulldog clamps, while the IVC wall was incised at the left renal vein ostium. In the same way, a specimen bag was used to cover the thrombus to avoid tumor dissemination. In general, the specimen bag was seamed with silk thread. After this procedure, the placement of patients was converted to a right lateral decubitus position, and left LRN was performed.

Result

As shown in Table 1, the median age was 52 years (range 42–77 years); ten of eleven patients were men; the median tumor size was 8.13 ± 2.57 cm, and eight of eleven patients were on the right side; the median thrombus length was 2.86 ± 1.36 cm. Six patients had a level I thrombus, while five had a level II thrombus. No patient was converted to open surgery.

Table 1
Baseline characteristics of all 11 patients

Characteristics	Value
Patients, n	11
Gender, n (%)	
Male	10 (90.9)
Female	1 (9.1)
Age, median (range), years	57 (42–77)
BMI, median (range), kg/m²	21.4(19.14–28.04)
ASA score, n (%)	
II	7 (63.6)
III	4 (36.4)
Affected side, n (%)	
Left	3 (27.3)
Right	8 (72.7)
Tumor size, mean ± SD, cm	8.13 ± 2.57
Clinical stage, n (%)	
T3bN0M0	9(81.8)
T3bN1M0	0(0)
T3bN0M1	2(18.2)
IVC thrombus level, n (%)	
I	6
II	5
IVC thrombus length, mean ± SD,cm	2.86 ± 1.36
Preoperative embolization, n (%)	
Yes	3 (27.3)
No	8 (72.7)
Continuous data are reported as median (range).	
BMI = body mass index; ASA = American Society of Anesthesiologists; IVC = inferior vena cava.	

The perioperative data were shown in Table 2. The median operative time was 185 min (range 125–229 min); the median estimated blood loss was 200 ml (range 150–300 ml). Four patients received an intraoperative transfusion. The median IVC clamping time was 18 min (range 10–24 min), while the median postoperative hospital stay was 6 days (range 4–8 days). Moreover, histological analysis revealed clear cell carcinoma in all patients. Surgical margins were negative in all cases, and no major complication was noted (Clavien-Dindo grade ≥ 3). All cases were pathologically confirmed to be renal clear cell carcinoma with regional lymph node metastasis.

Table 2
Perioperative data

Characteristics	Value
Operative time, median (IQR), min	185(125–229)
IVC clamping time, median (IQR), min	18(10–24)
Estimated blood loss, median (IQR), ml	200(150–300)
Patients receiving transfusion, n (%)	4 (36.4)
Day to surgical drain removal, mean (range), day	5(3–7)
Day to full ambulation, mean (range), day	2(1–3)
Day to oral feeding, mean (range), day	2(1–3)
Postoperative hospital stay, mean (range), day	6(4–8)
Perioperative complications, n (%)	
Low grade Clavien I-II	4(36.4)
High grade Clavien III-IV	0(0)
Preoperative serum creatinine, mean ± SD, umol/l	83.45 ± 12.23
Postoperative serum creatinine, mean ± SD, umol/l	115.81 ± 40.53
Preoperative hemoglobin, mean ± SD, g/l	115.72 ± 23.30
Postoperative hemoglobin, mean ± SD, g/l	100.09 ± 10.26
Preoperative AST, mean ± SD, u/l	24.91 ± 8.97
Postoperative AST, mean ± SD, u/l	26.91 ± 8.76
Preoperative ALT, mean ± SD, u/l	20.64 ± 11.30
Postoperative ALT, mean ± SD, u/l	31.27 ± 22.93
Follow-up, median (range), month	28(2–36)
Continuous data are reported as median (range).	
IVC = inferior vena cava; IQR = interquartile range; AST = aspartate aminotransferase; ALT = alanine aminotransferase	

All cases suffered mild renal insufficience. No significant statistical difference was found in hemoglobin, ALT and AST between preoperation and postoperation. The median follow-up period was 28 months (range 2–36 months). In addition, pulmonary metastasis was identified before operation in two patients, who are alive with it and treated with targeted therapy (Pazopanib), whereas the remaining nine patients had no local recurrence or distant metastasis during follow-up.

Discussion

Traditionally, the classic surgical approach of radical nephrectomy and IVC thrombectomy is open surgery. For RCC patients with the IVC thrombus, radical nephrectomy with thrombectomy can provide a better prognosis compared to nonaggressive surgical treatment.[2] Therefore, surgery is a priority for patients with suitable physical conditions. Moreover, with the development of surgical techniques and perioperative management, pure laparoscopic and robotic-assisted thrombectomy has become safe and feasible[9]. Nowadays, in most reports, the vessel loops are used to clamp veins[20, 21], but we think vein injury would occur if you pulling the vessel loops toughly, and this procedure cannot insure clamping the vein one-time successfully. Besides, the vessel should be wrapped twice which may prolong operation time. Furthermore, they used the Hem-O-lok to tight the vessel loops, indicating they need to cut off the Hem-O-lok when loosening the blocking, which is less convenient than the laparoscopic bulldog clamp. Shao et al[9] showed their experience by using open bulldog clamps to clamp renal veins and the IVC in laparoscopic surgery successfully, but it is known to all that using the laparoscopic instrument to control open bulldog clamps is not convenient and the bulldog clamps can slide out of the laparoscopic instrument during the clamping procedure. In our single medical center, the vessel loops were combined with the laparoscopic bulldog clamps to clamp veins as was described.

During minimal access surgery, small tricks may provide important gains. In this report, the application of laparoscopic bulldog clamps in laparoscopic urologic surgery was presented. In fact, the use of bulldog clamps during laparoscopic or robotic procedures especially in urology surgery is common, such as being used in laparoscopic or robotic partial nephrectomy. To be specific, the bulldog clamps were used to clamp the renal artery before cutting off the renal mass. Then, it was proved that the clamp can clamp the renal artery absolutely. In this report, laparoscopic bulldog clamps combined with vessel loops were used to clamp the caudal IVC, left renal vein and cephalic IVC. By moderately pulling the vessel loops and narrowing the venous wall, the veins could be clamped using laparoscopic bulldog clamps easily and conveniently. After early control of the renal artery and the lumbar veins to reduce hemorrhagic complications, it is believed that the use of laparoscopic bulldog clamps for the occlusion of the vessels during IVC thrombectomy may be preferable to the tourniquets or vessel loops, since the slow retrograde bleeding up to the end of the IVC suturing was experienced. Just using the vessel loops is time-consuming, and may be complicated with caval injury if inequitable application of force to block veins. However, laparoscopic bulldog clamps were easy to use by the aid of an applicator. Besides, it was safe, quick and reproducible, while providing good surgical exposure in a limited surgical field without interfering laparoscopic instrument and blocking any trocar access during operation. Moreover, the bulldog clip always exerts the same defined pressure, minimizing the damage to the veins. Otherwise, in the cases of the level I IVC thrombus, the milking was performed down of the thrombus, followed by the caudal IVC being clamped. Then, the vessel loops combined with contralateral renal veins and the cephalic IVC were moderately pulled to narrow the venous wall. After that, one laparoscopic bulldog clamp was adopted to clamp the left renal vein and cephalic IVC at the same time, thus saving operative time.

The reported operative time when performing IVC thrombectomy ranged between 100 and 275 minutes, while the IVC clamping time varied between 12 and 25 minutes, and mean blood loss changed between 150–320 ml[9, 20], which was similar to those in our experience. Besides, none of the authors pointed out significant intra-operative or post-operative complications or conversions to open surgery, and the patients were discharged 9 days after operation[9], which is alike to our figures to some extent.

In addition, in order to ensure that the laparoscopic thrombectomy can be performed safely, the patient needs to be carefully selected. The criteria for a qualified patient need to meet the following conditions: 1. the primary tumor is localized; 2. the intraluminal thrombus is free floating, without extensive involvement of the peripheral tissue or vascular wall[9]. Open surgery may be considered if the thrombus appears to be fixed or the IVC wall is extensively involved.[22].

Early control of the renal artery before renal vein manipulation and kidney mobilization is essential to minimize surgical risks, as this helps to decrease intraoperative bleeding and prevent thrombus detachment caused by venous blood flow. Besides, it can also reduce blood flow, with the kidney shrinks, allowing for easier handling, while the thrombus may also shrink. Wang et al[20] reported they underwent special preoperative preparation including renal artery embolization on the related side 1–2 hours before operation. However, we think renal artery embolization is unnecessary for right RCC, because the right artery can be easily exposed and ligated between IVC and aorta ventralis. As the surgery procedure was described, when the IVC and the left renal vein were exposed, the right renal artery in the interaortocaval space could be easily found before clamping the IVC. For left RCC, it is believed here that renal artery embolization is necessary. Chopra et al. held carrying out renal artery embolism before surgery in 80.3% of their patients[14]. It is difficult to expose the left renal artery when the IVC thrombus is handled in the left decubitus position. For left-side tumor cases, the procedures for pedicle control and kidney mobilization require operation from the left side, while major vessel control and thrombectomy should be operated from the right side, which is more complex than right-side cases. Thus, left renal artery embolization before surgery leads to decompression of venous collaterals and decreased blood loss[23]. In this case, this technology can reduce the difficulty of surgery.

To prevent the risk of pulmonary embolism as a result of thrombosis during the procedures is one of the most important tips. Chopra et al. proposed the “IVC-first, kidney-last” technique for robot-assisted IVC thrombectomy[14]. He detached the tumor thrombus using a stapler to separate the part of the tumor thrombus from that of nephrectomy, but the tumor thrombus may scatter to the cephalad side at the moment when the pressure with the stapler is applied to the renal vein. In addition, the vein wall might collapse and the tumor thrombus might be seeded into the peritoneal cavity. Yoichiro T et al. adopted a method of “en bloc” nephrectomy with IVC thrombectomy, where detaching the tumor thrombus is unnecessary[24]. However, that method is also featured with two main disadvantages. To be specific, one is that a twisting force is applied to the renal vein (containing the tumor) during kidney mobilization which may cause the tumor thrombus to unexpectedly break and scatter, while the other is difficulty in mobilizing the kidney in cases where the tumor is large, particularly when the renal vein is not detached and adheres to the IVC. In our single center, for right RCC, the modified “IVC-first, kidney-last” technique as

proposed. After artery control, the IVC tumor thrombus still attached to the renal vein was removed, and then, the tumor thrombus was placed in a picking bag that was closed immediately by using 2 – 0 silk. After kidney mobilization, the kidney combined with the tumor thrombus was placed in a bigger picking bag.

The present study had several limitations. First, it is a single-center study with a small patient population. Second, there are few reports on long-term oncological outcomes and further study is required. Third, further animal studies are required to verify the difference between laparoscopic bulldog clamps and vessel loops that block veins. However, given the lack of studies on using laparoscopic bulldog clamps in the IVC tumor thrombus, it is believed that the present study has clinical significance.

Conclusions

Modified vein clamping technique for the treatment of renal cell carcinoma complicated with the level I-II IVC thrombus is a valid alternative. However, larger patient samples and longer follow-up times are required to further define the role of modified laparoscopic surgery for the high-level IVC thrombus in RCC patients.

Declarations

Acknowledgements

Not applicable.

Authors' Contributions

Each author has participated sufciently in the work and takes public responsibility for appropriate portions of the content. The authors have agreed to be accountable for all aspects of the work and ensure that questions related to the accuracy or integrity of any part of the work are appropriately investigated and resolved. Dexin Yu created the design and concept of the study together with Jiaxing Ma and Tao Zhang. Supported by Tao Zhang and Jie Min they acquired the data and implemented the clinical trial. Literature research was conducted by Wei Sun and Weiwei Qian. The manuscript was prepared by Jiaxing Ma. Statistical analysis was carried out by Jiaxing Ma and Tao Zhang. All authors reviewed and edited the manuscript.

Funding

Clinical Research Cultivation Program of The Second Affiliated Hospital of Anhui Medical University (2020LCYB20)

Anhui Medical University Natural Science Foundation (2020xkj194)

Availability of data and materials

The datasets used and/or analysed during the current study are available from the corresponding author on reasonable request.

Ethics approval and consent to participate

This study was carried out in accordance with the Helsinki Declaration and was approved by the Research Ethics Committee at Second Affiliated of Anhui Medical University. Written informed consent was obtained from all participants prior to their inclusion within this study.

Conflict of Interest

The authors declare that they have no competing interests.

Consent for publication

Not applicable.

References

1. Blute ML, Leibovich BC, Lohse CM, Cheville JC, Zincke H. The Mayo Clinic experience with surgical management, complications and outcome for patients with renal cell carcinoma and venous tumour thrombus. BJU Int. 2004;94:33–41.
2. Skinner DG, Pritchett TR, Lieskovsky G, et al. Vena caval involvement by renal cell carcinoma.Surgical resection provides meaningful long-term survival. Ann Surg. 1989;210:387–392.
3. Ciancio G, Manoharan M, Katkoori D, De Los Santos R, Soloway MS. Long-term survival in patients undergoing radical nephrectomy and inferior vena cava thrombectomy: single-center experience.Eur Urol. 2010;57:667–672.
4. Ljungberg B, Albiges L, Abu-Ghanem Y, Bensalah K, Dabestani S,Fernández-Pello S, et al. European Association of Urology Guidelines on renal cell carcinoma: the 2019 update. Eur Urol. 2019;75:799–810.
5. Russo P. Multi-modal treatment for metastatic renal cancer: the role of surgery. World J Urol. 2010;28:295–301.
6. Bansal RK, Tu HY, Drachenberg D, et al. Laparoscopic management of advanced renal cell carcinoma with renal vein and inferior vena cava thrombus. Urology. 2014;83:812–816.
7. Varkarakis IM, Bhayani SB, Allaf ME, Inagaki T, Gonzalgo ML, Jarrett TW. Laparoscopic-assisted nephrectomy with inferior vena cava tumor thrombectomy: preliminary results. Urology. 2004; 64: 925–929.
8. Bansal RK, Tu HY, Drachenberg D et al. Laparoscopic management of advanced renal cell carcinoma with renal vein and inferior vena cava thrombus. Urology. 2014; 83: 812–817.
9. Shao P, Li J, Qin C et al. Laparoscopic radical nephrectomy and inferior vena cava thrombectomy in the treatment of renal cell carcinoma. Eur. Urol. 2015; 68: 115–122.

10. Wang W, Wang L, Xu J, Adams TS, Tian Y, Lv W. Pure retroperitoneal laparoscopic radical nephrectomy for right renal masses with renal vein and inferior vena cava thrombus. J. Endurol. 2014; 28: 819–824.
11. Ghareeb GM, Kenleigh DA, Brown JA. Left hand-assisted laparoscopic nephrectomy with renal vein thrombectomy for stage T3b renal cell carcinoma. Urology. 2016; 90: e3-4.
12. Abaza R, Shabsigh A, Castle E et al. Multi-institutional experience with robotic nephrectomy with inferior vena cava tumor thrombectomy. J Urol. 2016; 195(4 Pt 1): 865–871.
13. Kundavaram C, Abreu AL, Chopra S et al. Advances in robotic vena cava tumor thrombectomy: Intracaval balloon occlusion, patch grafting, and vena cavoscopy. Eur Urol. 2016; 70(5): 884–90.
14. Chopra S, Simone G, Metcalfe C et al. Robot-assisted level II–III inferior vena cava tumor thrombectomy: Step-by-step technique and 1-year outcomes. Eur Urol. 2017; 72(2): 267–274.
15. Neves RJ, Zincke H. Surgical treatment of renal cancer with vena cava extension. Br. J. Urol. 1987; 59: 390–395.
16. Edge SB, Compton CC. The American Joint Committee on Cancer: the 7th edition of the AJCC cancer staging manual and the future of TNM.Ann Surg Oncol. 2010;17:1471–1474.
17. Dindo D, Demartines N, Clavien PA. Classifification of surgical complications:a new proposal with evaluation in a cohort of 6336 patients and results of a survey. Ann. Surg. 2004; 240: 205–213.
18. Tang B, Dong HY, Shao PF et al: The clinical application of enhanced recovery after surgery protocol in perioperative period of laparoscopic nephron sparing surgery. Transl Androl Urol. 2020 Aug; 9(4): 1566–1571.
19. Nicolae C, Lulia A, Doru-Lucian G et al: Dual Combined Laparoscopic Approach for Renal-Cell Carcinoma with Renal Vein and Level I-II Inferior Vena Cava Thrombus: Our Technique and Initial Results. J Endourol. 2018 Sep 12;32(9):837–842.
20. Wang B, Li H, Ma X, et al. Robot-assisted Laparoscopic Inferior Vena Cava Thrombectomy:Different Sides Require Different Techniques. Eur Urol, 2016 Jun;69(6):1112–1119.
21. Christopher M, Ronney A, Complex robotic nephrectomy and inferior vena cava tumor thrombectomy: an evolving landscape. Robotic surgery in urology. 2019; 30 (1):83–89.
22. Pouliot F, Shuch B, LaRochelle JC, et al. Contemporary management of renal tumors with venous tumor thrombus.J Urol. 2010;184:833–841.
23. Chopra S, Simone G, Metcalfe C, et al. Robot-assisted level II-III inferior vena cava tumor thrombectomy: step-by-step technique and 1-year outcomes. Eur Urol. 2017;72:267–274.
24. Yoichiro T, Noriyuki M, Issei S, et al. En bloc laparoscopic radical nephrectomy with inferior vena cava thrombectomy: A single-institution experience. Int J Urol. 2019;26(3):363–368.

Figures

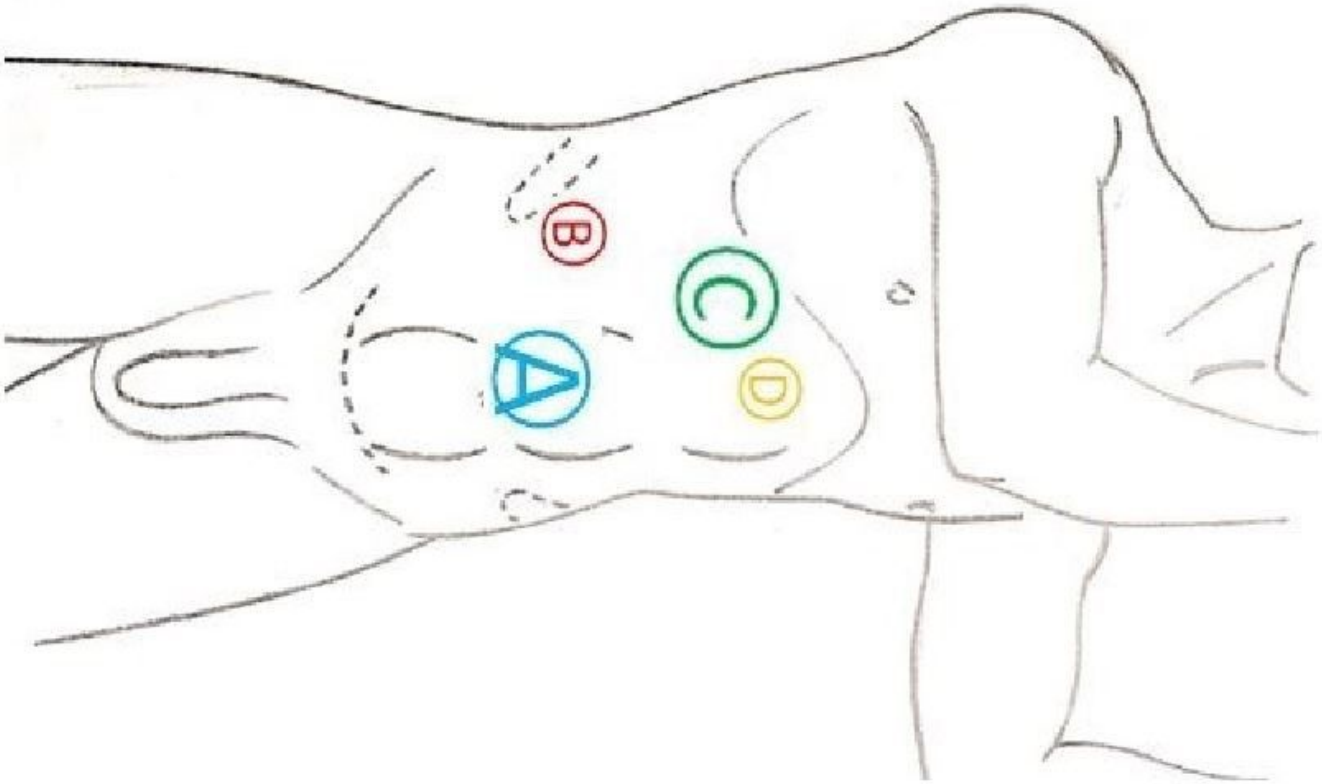

Figure 1

The positioning of the trocars for the transperitoneal approach: the optic trocar (10 mm) lateral to the umbilicus, at the lateral border of the abdominal rectus muscle(A); the trocar for the left hand instrument on the axillary line parallelling to the navel(B); the trocar for the right hand instrument (12 mm) on the perpendicular line from the umbilicus to the costal margin, 2 cm below the costal margin(C); a 4th trocar (5 mm) for the assistant for liver retraction and suction in the epigastric region(D).

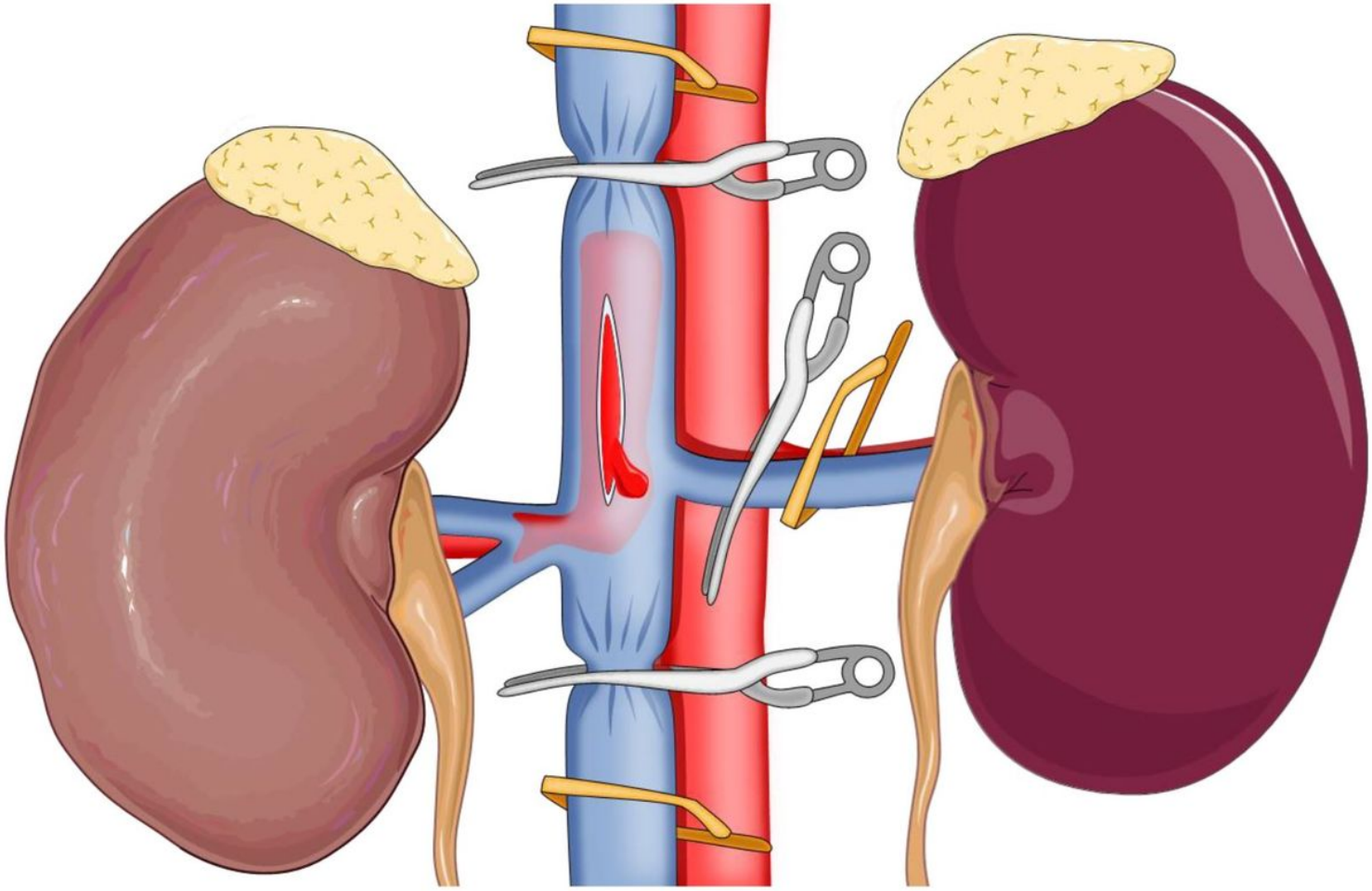

Figure 2

The caudal IVC, left renal vein, and cephalic IVC were sequentially clamped using laparoscopic bulldog clamps. We used laparoscopic bulldog clamps to clamp the veins by moderately pulling the vessel loops and narrowing the venous wall.

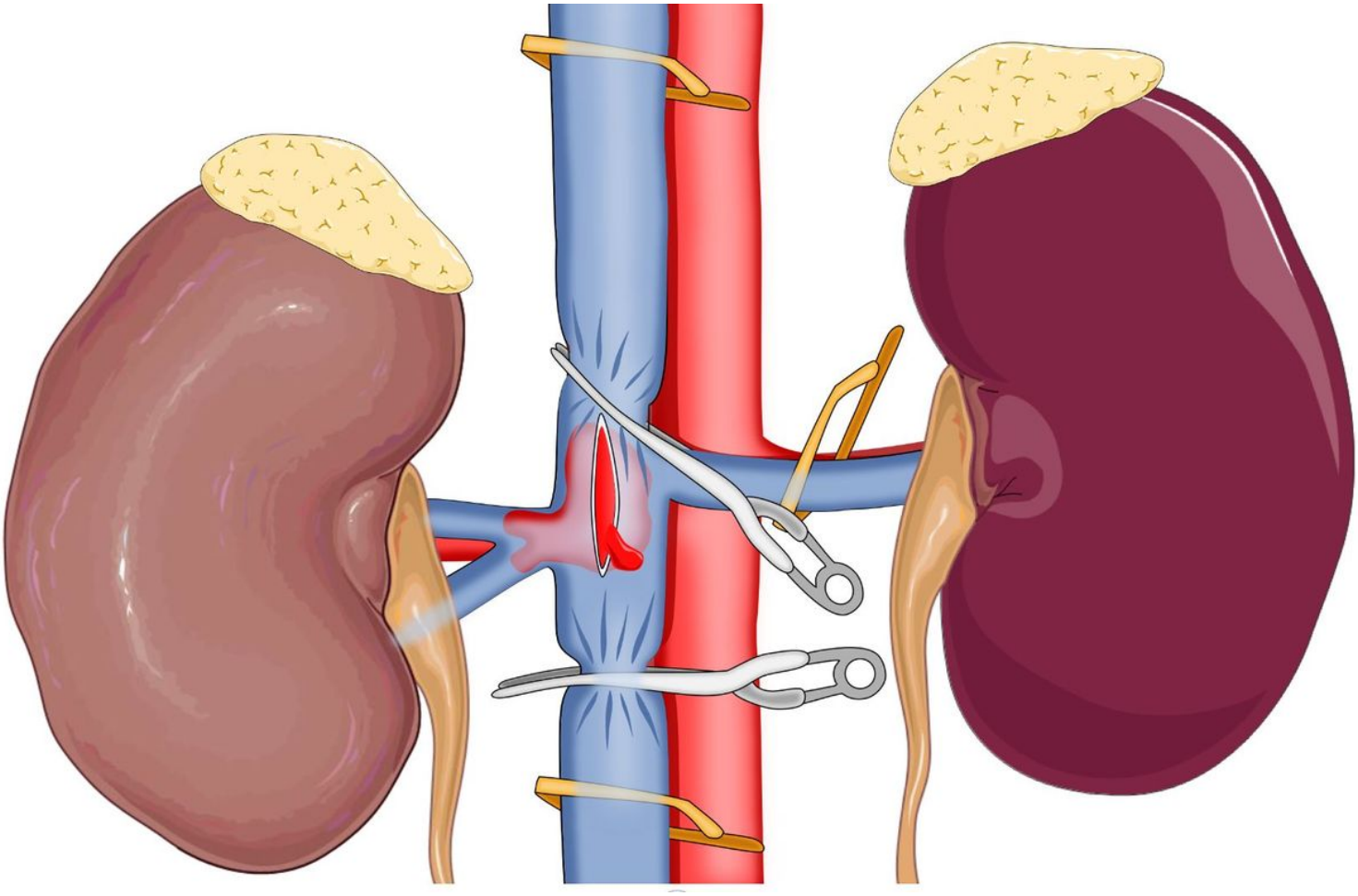

Figure 3

For level I IVC thrombus, the caudal IVC was clamped first of all, then we used just one laparoscopic bulldog clamps to clamp left renal vein and cephalic IVC at the same time.