Unilateral Pedicle Fracture Accompanying Spondylolisthesis and Contralateral Spondylolysis: A Case Report

Xiaofeng Liu
First Affiliated Hospital of Soochow University
Palihati Baiketuerxun
First Affiliated Hospital of Soochow University
Junxin Zhang
First Affiliated Hospital of Soochow University
Tao Liu (sudalt@126.com)
First Affiliated Hospital of Soochow University

Research article

Keywords: pedicle fracture, contralateral spondylolysis, spondylolisthesis, instability, TLIF

Posted Date: October 8th, 2020

DOI: https://doi.org/10.21203/rs.3.rs-86539/v1

Abstract

Study design Case report

Objective To report a rare case with unilateral pedicle stress fracture accompanying spondylolytic spondylolisthesis.

Summary of Background Data Unilateral pedicle stress fracture accompanying spondylolytic spondylolisthesis is rare. Most are association with major trauma, previous spine surgery, osteopetrosis or stress-related activities.

Methods We report a patient with spontaneous pedicle fracture associated with contralateral spondylolysis and spondylolisthesis at the L5 level, complaining severe back pain, radicular lower limb pain and intermittent claudication. The pathophysiological mechanism is discussed, and a review of relevant literature is included.

Results This patient was successfully treated by decompression laminectomy with transforaminal lumbar interbody fusion (TLIF) and pedicle screw fixation. To our knowledge, cases like this have rarely been reported in the literature.

Conclusions Unilateral pedicle stress fracture in patients with spondylolytic spondylolisthesis is rare. It may be related to redistribution of forces in an unstable neural arch resulting from defect in the contralateral pars interarticularis. Our experience suggests that limited decompression and instrumented fusion surgery led to a successful outcome.

Introduction

Vertebral pedicle fractures are uncommon. Most cases have been reported in associated with a history of spinal surgery[1–4], osteopetrosis[5–8] or strenuous activities[9–11]. Unilateral pedicle fracture accompanying isthmic spondylolisthesis is extremely rare[12]. Here, we report a rare case of unilateral pedicle fracture accompanying contralateral spondylolytic defects with spondylolisthesis in the absence of any major trauma, previous spinal surgery, or stress-related activity.

Case Report

This 48-year-old woman had suffered no earlier trauma, accidents, or spinal surgery but had mild low back pain for several years. The pain exacerbated progressively without any inducement in resent 3 years, accompanying with left leg pain and intermittent claudication. Bending and twisting commonly aggravated the symptoms, and resting resulted in improvement temporarily. Before surgery, she could only walked fewer than 100 m due to severe lower extremity pain.

A neurological examination revealed grade 4 muscle weakness in the left extensor hallucis longus, and marked tenderness in the low back area with reduced back motion, especially in backward extension. No

sensory change, bowel or bladder symptom was found.

The plain radiographs showed grade I spondylolisthesis at the L5 level, and dynamic radiographs illustrated segmental instability (Fig. 1). The computed tomography (CT) demonstrated right side spondylolysis at the L5 vertebra and contralateral pedicle fracture. The callus overgrew along the fracture margin, and bony spur encroached on the spinal canal (Fig. 2). The magnetic resonance imaging reveals herniation of the intervertebral disc and spinal canal stenosis at L5/S1. No edema signal can be seen on the fat-suppression sequence, indicating that the pedicular fracture might be of old (Fig. 3).

This patient was treated with decompression laminectomy with transforaminal lumbar interbody fusion (TLIF) and pedicle screw fixation (Fig. 4). At the 9-month follow-up assessment, she had completely returned to normal activities. No residual low back pain or radiating pain was complained. The CT revealed successful fusion of L5/S1 and good maintenance of reduction, along with advanced healing of the pedicle fracture (Fig. 5).

Discussion

Spontaneous pedicle fracture of the lumbar spine without trauma is rare. Its etiology is unknown but may be explicable analogous to stress fracture. Unilateral spondylolysis accompanying sclerosis and hypertrophy of the contralateral neural arch is well described in the literature[13-14]. The sclerosis is believed to occur as a compensatory mechanism secondary to redistribution of forces in an unstable neural arch which is resulted from the defect in the pars interarticularis[15]. Physiological hypertrophy is a response of the pedicle to abnormal stress due to instability of the neural arch, well known as sclerotic pedicle in the literature[16]. One support for such theory comes from the fact that pedicular sclerosis usually decreases after treatment with fusion and fixation that supports sufficient stabilities[16]. Cadaver studies revealed that the pars interarticularis is most prone to stress fracture, and the pedicle is the second-weakest vertebral area[17]. The pedicle has greater intrinsic strength and shorter moment arm from the vertebral body. Such structure helps resist greater cyclic shear forces, particularly resist shear stress and twisting stress forces[18].

Unilateral spondylolysis occurs in 15% to 30% of spondylolysis cases, L5 is the most commonly affected vertebra[19]. Lowe et al. found that approximately 20% patients with unilateral spondylolysis had structural changes or anomalies including pars hypertrophy, sclerosis and deformity in the opposite pars interarticularis[20]. Finite element analysis also indicated that unilateral pars defect induced greater stress on the contralateral pars, and the opposite pars interarticularis in the unilateral spondylolysis experienced greater stress on torsion[21-22]. As a result, spontaneous lumbar pedicle fracture occurs less often in the neural arch than spondylolysis[23]. This theory has been proved in study using unilateral spondylolysis model, whereby Sairyo et al. demonstrated that the risk of the pedicular fatigue stresses increased in axial rotation to the contralateral side of unilateral pars defect[23].

Therefore, we speculate that unilateral spondylolysis can alter the normal biomechanics of the neural arch, resulting in increased stress on the contralateral pedicle, and led to stress fracture.

The sensitivity of plain radiography is limited in diagnosis of pedicular fractures. Computed tomography is widely regarded as the choice for the diagnosis of such lesions because of clear display of the stress fracture. Bone scintigraphy and MR images are useful in detecting early fractures[24-26].

Pedicle fracture with spondylolisthesis can be managed conservatively or surgically depending on the grade of the spondylolisthesis and the impact on the patient's daily activities. Conservative management consists of rest, pain control, and bracing. For patients with incomplete, complete, and juvenile stress fractures of the lumbar pedicle without nerve root irritation, the majority of claims preferred conservative treatment[27]. In most cases, conservative treatment allows for spontaneous healing of the early-stage fracture even in older individuals, providing a satisfactory healing rate[28].

Surgical treatment is recommended for patients who do not respond to conservative treatment[29]. Besides, surgical treatment is considered as first choice for patients with radicular pain and/or neurogenic claudication that limits the time one can stand and/or the distance one can walk. Especially for patients who present with bowel or bladder dysfunction or with progressive weakness, segmental lumber instability finding in radiological examination, surgical treatment is instant[29].

Surgical management consists of decompression, instrumented and non-instrumented fusion[30]. ·As the gold standard for internal fixation, pedicle screw technique is preferred because of high success rate, low hardware failure, no postoperative bracing, and sufficient maintenance of reduction during flexion, extension, torsion, and side bending[30].

In this case, the patient was treated by decompression laminectomy with TLIF and pedicle screw fixation. Anterior interbody fusion procedure was performed, using a vertical mesh cage filled with allograft. At the 9-month follow-up, she had completely returned to normal activities. No residual low back pain or radiating pain was complained.

In conclusion, unilateral pedicle stress fracture in patients with spondylolytic spondylolisthesis is rare. It may be related to redistribution of forces in an unstable neural arch resulting from defect in the contralateral pars interarticularis. Our experience suggests that limited decompression and instrumented fusion surgery led to a successful outcome.

Abbreviations

computed tomography (CT), transforaminal lumbar interbody fusion (TLIF), magnetic resonance imaging (MRI).

Declarations

Ethics approval and consent to participate: The study was approved by the ethical committee of The Friendship Hospital of Yili Kazakh Autonomous Prefecture, and informed consent was obtained from the patient.

Consent for publication: All the authors have approved the final version and agree to publish.

Availability of data and materials: N/A.

Competing interests: All the authors state that there is no conflict of interest.

Funding: There is no funding source.

Authors' contributions: Xiaofeng Liu and Tao Liu conceived the study. Xiaofeng Liu and Palihati Baiketuerxun completed the collection and assembly of data. Xiaofeng Liu and Junxin Zhang undertook the statistical analysis. Xiaofeng Liu and Palihati Baiketuerxun produced the initial draft manuscript. Junxin Zhang, Tao Liu critically revised the article for important intellectual content. Tao Liu gave final approval of the article. All authors read the final manuscript.

Acknowledgements: Thanks to the patient involved in this study.

References

[1] Maurer SG, Wright KE, Bendo JA. Iatrogenic spondylolysis leading to contralateral pedicular stress fracture and unstable spondylolisthesis. Spine 2000 Apr;25(7):895–898.

[2] K.-Y. Ha and Y.-H. Kim. Bilateral pedicle stress fracture after instrumented posterolateral lumbar fusion: a case report. Spine 2003 Apr; 28(8): E158–E160.

[3] J. P. Sheehan, G. A. Helm, J. M. Sheehan. Stress fracture of the pedicle after extensive decompression and contralateral posterior fusion for lumbar stenosis. Report of three cases. Neurosurgical Focus 2002 Aug;13(2): E9

[4] S. J. Macdessi, A. K. Leong, J. E. C. Bentivoglio. Pedicle fracture after instrumented posterolateral lumbar fusion: a case report. Spine 2001 Mar;26(5): 580–582.

[5] M. Doita, Y. Ando, S. Hirata. Bilateral pedicle stress fracture in a patient with osteoporotic compression fracture. European Spine Journal 2009 Jul;18(2):S206–S209.

[6] A. Hajjioui, H. Khazzani, S. Sbihi, R Bahiri, B Benchekroune, N Hajjaj-Hassouni. Spondylolisthesis on bilateral pedicle stress fracture in the lumbar spine: a case study. Annals of Physical and Rehabilitation Medicine 2011 Feb;54(1): 53–58.

[7] H. S. Kim, C. I. Ju, S. W. Kim. Bilateral pedicle stress fracture accompanying spondylolysis in a patient with ankylosing spondylitis. Journal of Korean Neurosurgical Society 2010 Jul;48(1): 70–72.

[8] Bibhudendu Mohapatra, Thomas Kishen, Ashish D. Diwan. Multiple Lumbar Pedicle Fractures in Osteopetrosis: A Case Report. Spine 2010 Apr; 35(8): E311–E315.

[9] Hari K. Parvataneni, Stephen J. Nicholas, Sean E. McCance. Bilateral Pedicle Stress Fractures in a Female Athlete Case Report and Review of the Literature. Spine 2004 Jan; 29(2): E19–E21.

[10] Eran Kessous, Tracy Borsinger, Ayesha Rahman, Pierre A d'Hemecourt. Contralateral Spondylolysis and Fracture of the Lumbar Pedicle in a Young Athlete. Spine 2017 Sep; 42(18):E1087–E1091.

[11] Yannick Guillodo, Estelle Botton, Alain Saraux, P Le Goff. Contralateral Spondylolysis and Fracture of the Lumbar Pedicle in an Elite Female Gymnast. Spine 2000 Oct; 25(19): 2541–2543.

[12] In-Ho Jeong, Eai-Hong Hwang, Weon-Tae Bae. Contralateral Pedicular Fracture with Unilateral Spondylolysis. J Korean Neurosurg Soc 2009 Dec; 46(6) : 584-587.

[13] Maurer SG, Wright KE, Bendo JA. Iatrogenic spondylolysis leading to contralateral pedicular stress fracture and unstable spondylolisthesis. Spine 2000 Apr;25(7):895–8.

[14] İnceoğlu S1, Mageswaran P, Modic MT, Edward C Benzel. Adaptive remodeling at the pedicle due to pars fracture: a finite element analysis study. J Neurosurg Spine.2014 Sep; 21(3):475-80.

[15] Weatherley CR, Mehdian H, Berghe LV. Low back pain with fracture of the pedicle and contralateral spondylolysis. A technique of surgical management. J Bone Joint Surg Br 1991 Nov; 73:990–993.

[16] Mustafa Sirvanci, Levent Ulusoy, Cihan Du ran. Pedicular stress fracture in lumbar spine. Journal of Clinical Imaging 2002 May-Jun; (26) 187 – 193.

[17] Cyron BM, Hutton WC. The fatigue strength of the lumbar neural arch in spondylolysis. J Bone Jt Surg Br 1978 May;60(2):234 – 8.

[18] Garber JE, Wright AM. Unilateral spondylolysis and contralateral pedicle fracture. Spine 1986 Jan-Feb;(11) : 63-66.

[19] Sagi H, James G, Jarvis M. Histomorphic analysis of the pars interarticularis and its association with isthmic spondylolysis. Spine 1998 Aug; 23:1635–40.

[20] J. Lowe, E. Libson, I. Ziv, M Nyska, Y Floman, R A Bloom, G C Robin. Spondylolysis in the upper lumbar spine. A study of 32 patients. J. Bone Joint Surg Br. 1987 Aug; 69(4) :582–586.

[21] Jung-Pin Wang , Zheng-Cheng Zhong , Cheng-Kung Cheng, Chen-Sheng Chen, Chung-hung Yu, Ting-Kuo Chang, Shun-Hwa Wei. Finite element analysis of the pondylolysis in lumbar spine. Bio-Medical Materials and Engineering 2006: (16): 301–308.

[22] İnceoğlu S, Mageswaran P, Modic MT, Edward C Benzel. Adaptive remodeling at the pedicle due to pars fracture: a finite element analysis study. J Neurosurg Spine. 2014 Sep;21(3):475-480.

[23] Sairyo K, Katoh S, Sasa T, Natsuo Yasui, Vijay K Goel, Sasidhar Vadapalli, Akiyoshi Masuda, Ashok Biyani, Nabil Ebraheim. Athletes with unilateral spondylolysis are at risk of stress fracture at the contralateral pedicle and pars interarticularis : a clinical and biomechanical study. Am J Sports Med 2005 Apr;33(4) : 583-590.

[24] Elif Evrim Ekin, Muhittin Emre Altunrende. Pedicle Stress Injury in Children and Adolescents With Low Back Pain. Spine 2019 Sep; 44(17): E1038–E1044.

[25] Hans Van der Wall, Geoffrey Storey, John Magnussen, Clayton J Frater, Rodney Pattinson, John Pereira, John Stephen.Distinguishing Scintigraphic Features of Spondylolysis. Journal of Pediatric Orthopaedics 2002 May-Jun;22(3):308–311.

[26] Toshinori Sakai,, Koichi Sairyo, Seiichi Mima, Natsuo Yasui. Signifificance of Magnetic Resonance Imaging Signal Change in the Pedicle in the Management of Pediatric Lumbar Spondylolysis. Spine 2010 Jun;35(14): E641–E645.

[27] Raphae Vialle ,Pierre Mary, Antonio de Carvalho, Hubert Ducou le Pointe, Jean-Paul Damsin, Georges Filipe. Acute L5 pedicle fracture and contralateral spondylolysis in a 12-year-old boy: a case report. Eur Spine J. 2007 Dec; 16(3):S316–S317.

[28] Kyongsong Kim, Toyohiko Isu, Daijiro Morimoto, Rinko Kokubo, Naotaka Iwamoto, Akio Morita.Incidental Idiopathic Bilateral Pedicle Fracture - Case Report and Literature Review. NMC Case Report Journal 2018 Dec; 6(1): 35–37.

[29] Frank J. Eismont, Robert P. Norton, Brandon P. Hirsch, Surgical Management of Lumbar Degenerative Spondylolisthesis. J Am Acad Orthop Surg 2014 Apr;22:203-213.

[30] Paul Gagnet , Kent Kern, Kyle Andrews, Hossein Elgafy, Nabil Ebraheim. Spondylolysis and spondylolisthesis: A review of the literature Journal of Orthopaedics 2018 Mar; 15: 404–407

Figures

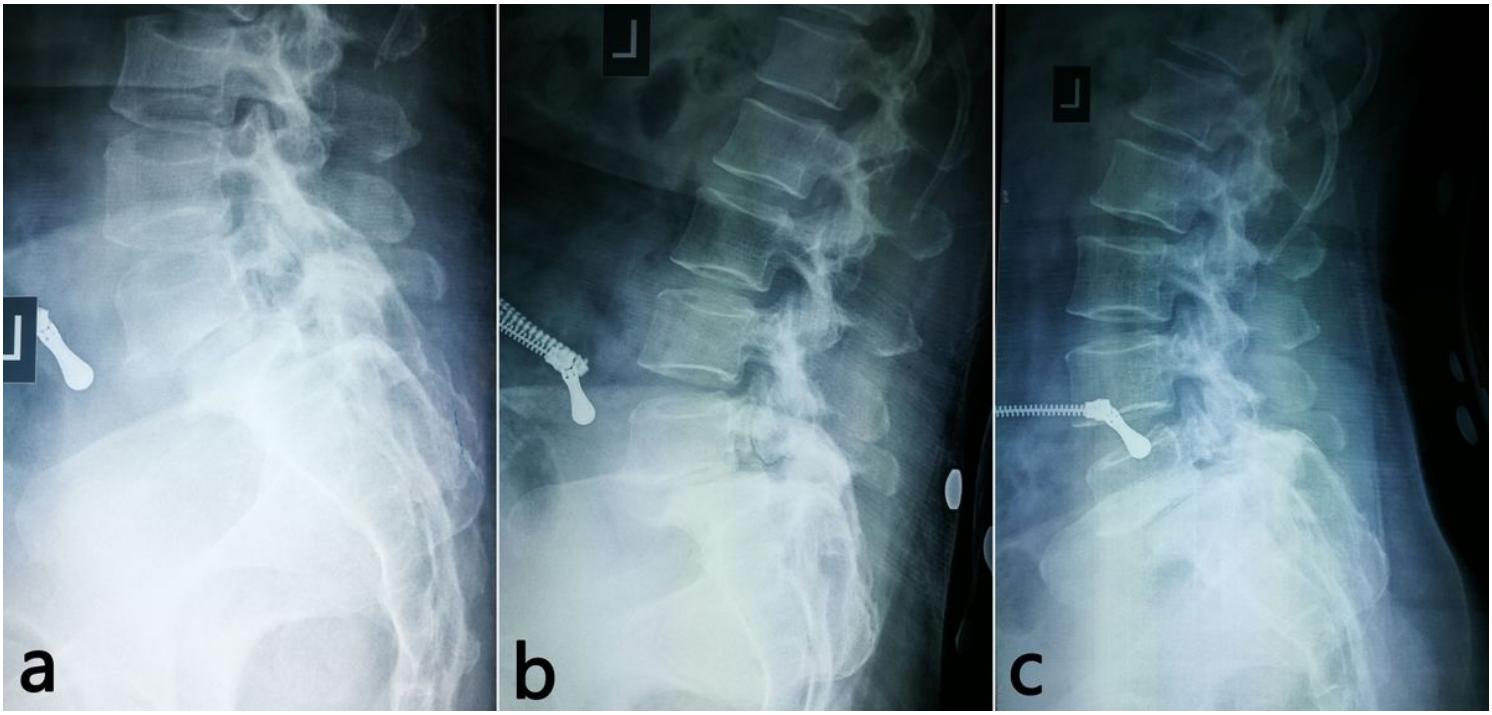

Figure 1

The lateral plain radiographs shows grade I spondylolisthesis at the L5 level (a). The dynamic radiographs illustrate segmental instability (b, c).

Figure 2

The computed tomography reveals L5 spondylolisthesis, pedicle fracture and sclerosis on the left side (a), and spondylolysis on the right side (b). The axial image through L5 demonstrates the spondylolytic defect on the right side and the pedicular fracture with sclerotic change of the fracture margin on the contralateral side. A bony spur encroaches on the left spinal canal (c).

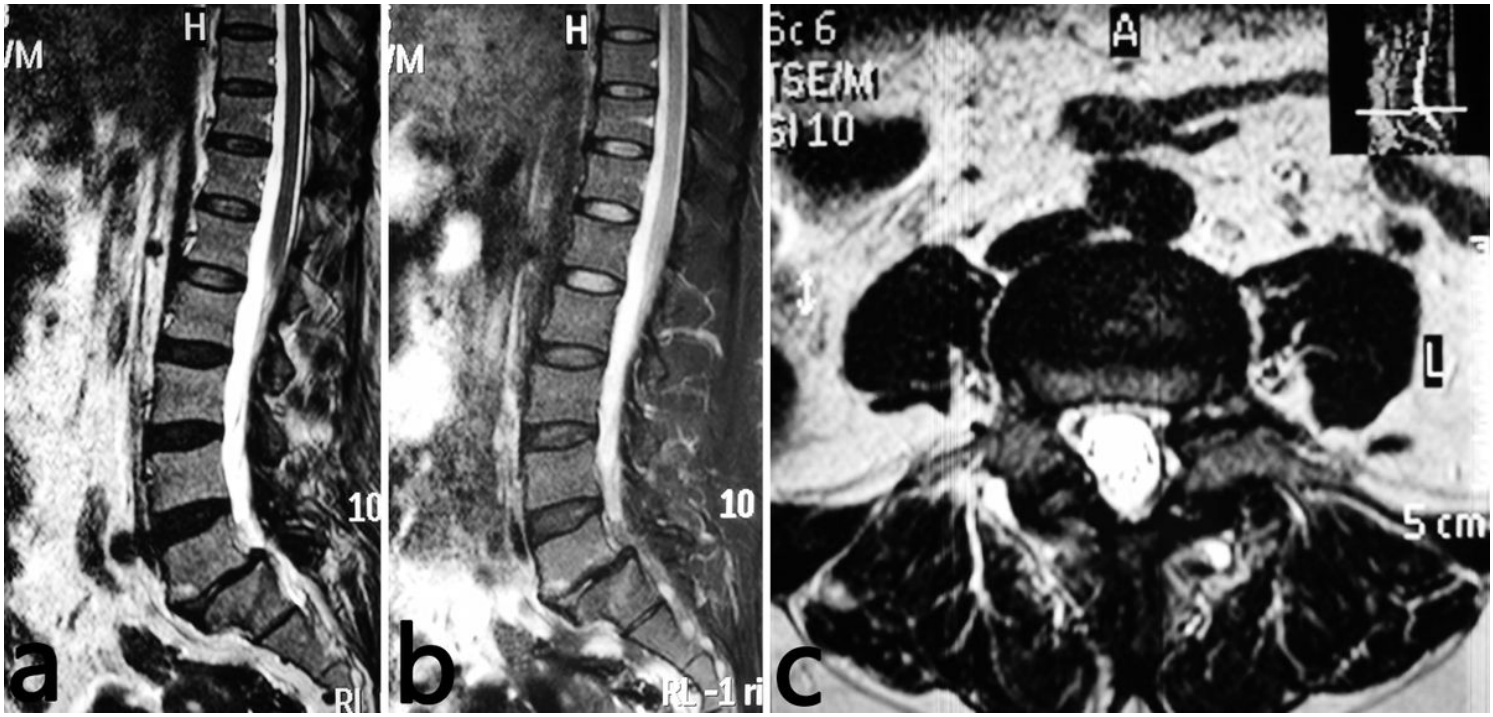

Figure 3

The T2-WI sequence (a) and fat-suppression sequence (b) of magnetic resonance imaging reveals herniation of the intervertebral disc and spinal canal stenosis at L5/S1. No edema signal can be seen on the fat-suppression sequence (b), indicating that the pedicular fracture might be of old.

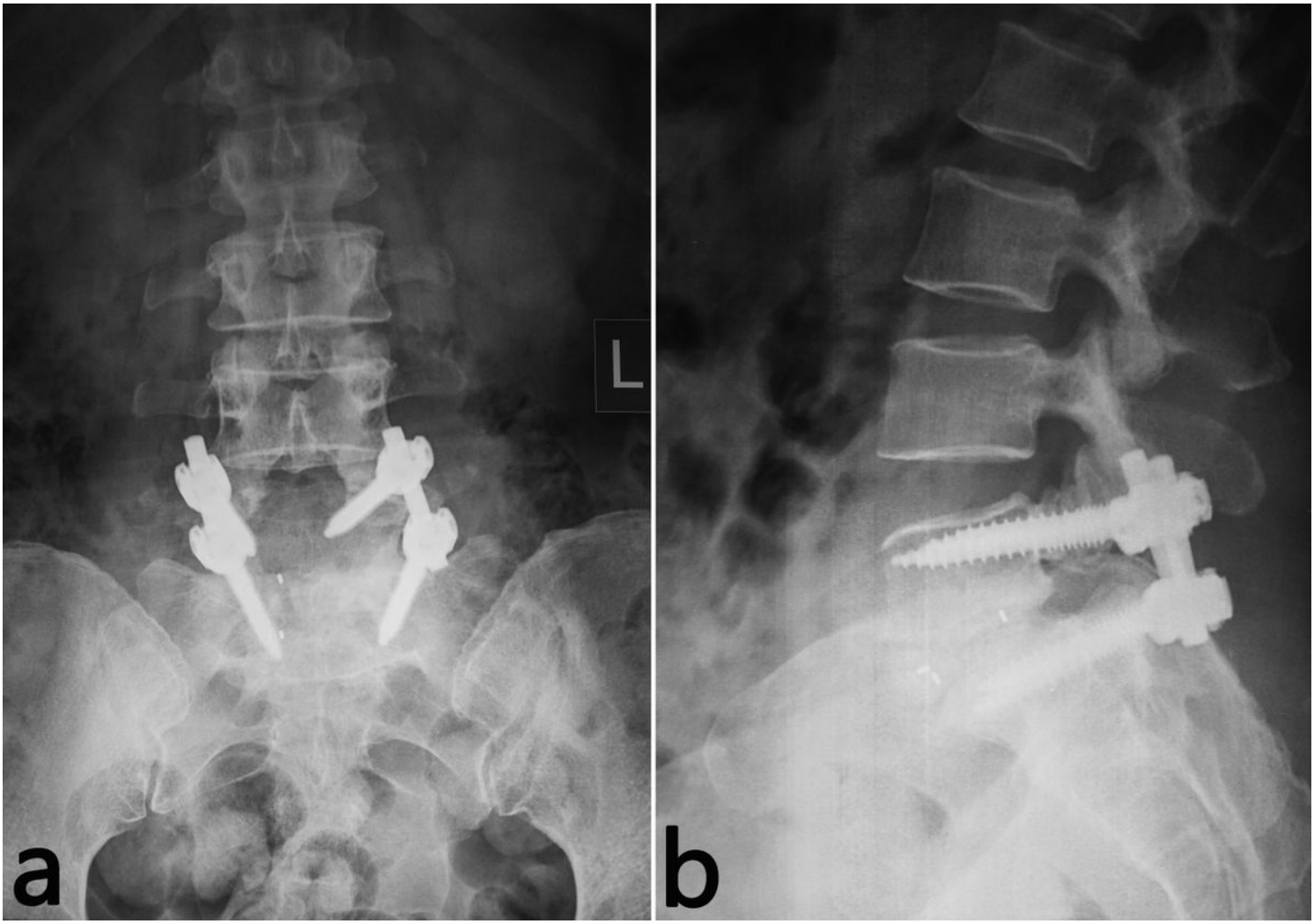

Figure 4

The positive (a) and lateral (b) radiographs after operation shows good reduction and fixation of the lumbar spondylolisthesis.

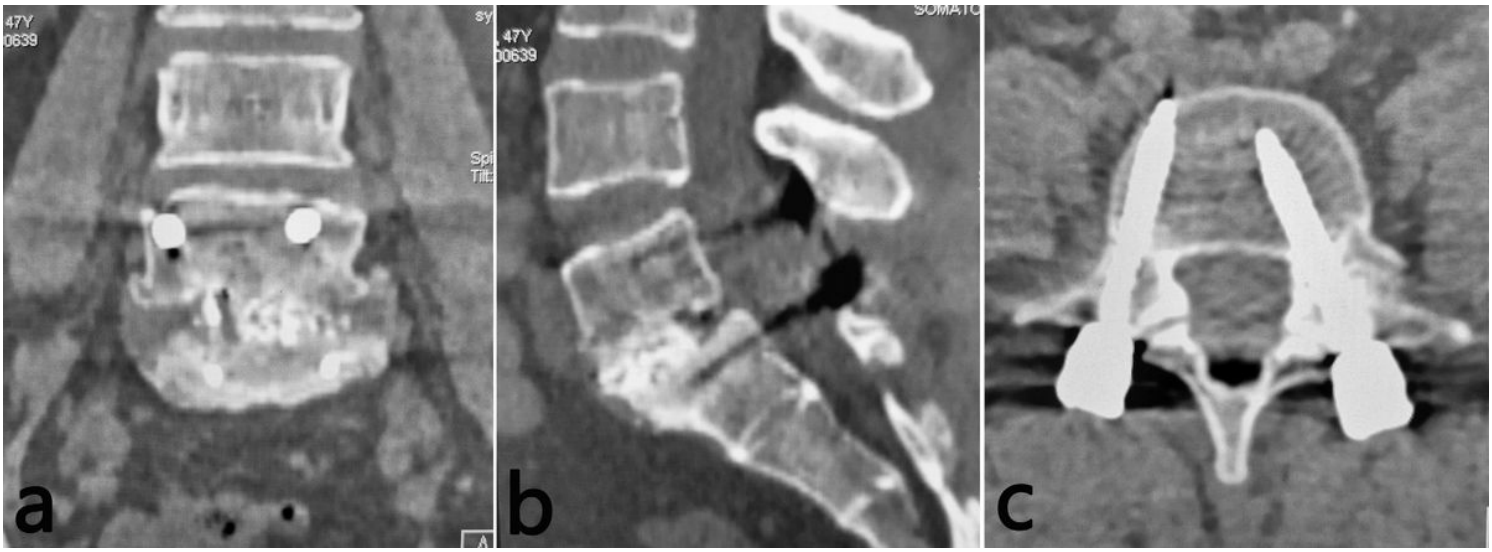

Figure 5

The coronal CT (a) and sagittal CT (b) 9 months after operation reveals successful fusion of L5/S1 and good maintenance of reduction. The axial image shows advanced healing of the pedicle fracture.