

Three-dimensional change of molar position during alignment and leveling with PASS and MBT™: a randomized controlled trial

Hong Su

First Clinical Division, Peking University School and Hospital of Stomatology

Kaiyuan Xu

University of the Pacific, Arthur A. Dugoni School of Dentistry

Tingting Feng

Department of Orthodontics, School of Stomatology, Tongji University

Bing Han

Department of Orthodontics, Peking University School and Hospital of Stomatology

Gui Chen

Department of Orthodontics, Peking University School and Hospital of Stomatology

Tianmin Xu (✉ tmxuortho@163.com)

Department of Orthodontics, Peking University School and Hospital of Stomatology

Research Article

Keywords: MBT™, PASS, Molar anchorage, Alignment and leveling, RCT

Posted Date: October 21st, 2021

DOI: <https://doi.org/10.21203/rs.3.rs-871021/v1>

License:  This work is licensed under a Creative Commons Attribution 4.0 International License. [Read Full License](#)

Abstract

Introduction: Molar tip back bends added on steel wire is a classical anchorage control method used in Tweed Edgewise and Begg technique. With the development of straight wire appliance (SWA), especially the wide use of Nickel-titanium (NiTi) wire makes bending up impractical in the first stage of the treatment. However, mesial movement of molars occurs when fine NiTi wire was engaged into the molar buccal tube with forward tipping prescription. This single-center 2-arm parallel randomized clinical trial aimed to compare the physiologic anchorage spee-wire system (PASS) vs MBT™ straight-wire system with regards to their capacity of anchorage control during alignment and leveling.

Method: The sample consisted of 64 CL I/ CL II orthodontic patients who underwent maxillary first premolar extraction. Minimal randomization was used to select the sample. Two bracket systems were used—PASS and MBT™. The digital study models included three time points: pre-treatment(T0), the first 3 months during treatment(T1), and the first 6 months during treatment(T2). Study models of different time point were superimposed and movements of maxillary first molar, canine, and central incisor were evaluated.

Results: In the first 6 months of the treatment, the maxillary first molars were tipped distally ($2.67\pm 4.59^\circ$) and moved distally ($0.03\pm 1.02\text{mm}$) in the PASS group; They were tipped mesially ($1.95\pm 3.04^\circ$) and moved mesially ($0.67\pm 0.79\text{mm}$) in the MBT™ group. Vertically, the maxillary first molars were slightly extruded in the PASS group – the mesial cusp $0.50\pm 0.73\text{mm}$ and the distal cusp $0.18\pm 0.67\text{mm}$; however, they were intruded in the MBT™ group – the mesial cusp $0.19\pm 0.52\text{mm}$ and the distal cusp $0.05\pm 0.56\text{mm}$. Besides molars, the maxillary canines also exhibited treatment difference– the inter-canine width was increased by $1.31\pm 2.00\text{mm}$ in the PASS group in contrast to $2.37\pm 1.72\text{mm}$ in the MBT™ group. No other difference was found.

Conclusion: Compared with MBT™, PASS was better at preserving maxillary anchorage during alignment and leveling.

Background

Well-aligned teeth, ideal occlusion, and harmonious profile are goals of orthodontic treatment. In the Caucasian population, due to the well-developed nose and chin, its extraction rate is relatively low [1, 2]. It is renowned that Angle was an advocator of non-extraction treatment. When Andrews developed the SWA, its dataset was based on normal occlusion without extraction [3]; thus, many orthodontists believed the SWA was ideal for non-extraction or in the stage of finishing and detailing after the space closure. In other words, the SWA was prone to anchorage loss for extraction cases.

In the consideration of patients' profiles and post-treatment stability, Tweed believed that the extraction treatment is necessary in many cases [4]. In Asian countries like China, Korea, and Japan, where the dominant race is Mongolian, the extraction rate is significantly higher than that in Western countries due to the prevailing protrusive profile [5]. To address both protrusion and crowding, orthodontists who treated patients with SWA have used various auxiliary devices to reinforce anchorage: headgear, transpalatal arch, Nance appliance, and TADs [6], as well as all kind of measures such as laceback ligatures [7, 8] and interarch elastics.

Some research focused on studying what causes anchorage loss to prevent it from happening. Geron [9] believed the causes of anchorage loss were multifactorial; its deciding factors included crowding, mechanics, age, extraction site, and overjet; Su [10] reported the distal tipping of the maxillary molar was not uncommon pre-treatment and anchorage loss could result from mesial tipping and mesialization during alignment and leveling. Xu [11] reported that the anchorage loss in extraction cases consisted of two parts: mechanical force and physiological force. From there, Xu conceptualized physiological anchorage loss and developed PASS to preserve anchorage by manipulating both mechanical force and physiological force. Chen's RCT study [12] showed PASS group without additional anchorage devices could attain well anchorage control by considering the dentoalveolar compensation of anchor teeth, which evaluated the final stage of the system. However, anchorage control is not easy in the early stage of treatment-leveling and alignment, when fine NiTi wires are widely used and the anchorage molar can move freely. Al-Awadhi EA [13] found that the majority of anchorage loss occurred during the initial stage even with the aid of Nance appliance. The question is: whether PASS is capable of handling anchorage loss during alignment and leveling?

Specific Objectives Or Hypotheses

This study was aimed to compare the PASS vs MBT™ straight-wire system with regards to their capacity of anchorage control during alignment and leveling. The null hypothesis tested was that both PASS vs MBT™ systems had similar capacity of anchorage control.

Methods

Trial design and any changes after trial commencement

This was a prospective randomized clinical controlled trial (RCT), which followed the Consolidated Standards of Reporting Trials statement and guidelines [14] and did not require changes in methods after trial commencement. The methods were described in detail in our previous research [12].

Participants, eligibility criteria, and settings

The protocol of this study (PKUSSIRB-2013050) was approved by the Biomedical Ethics Committee of the School and Hospital of Stomatology, Peking University (Beijing, China) and registered at the Chinese Clinical Trial Registry (Chictr.org.cn) with the identifier ChiCTR-TRC-13003260 (15/06/2013).

This study was a serial study and its sample and methods could refer to our previous RCT study [12]. The sample consisted of 64 patients who started treatment from June 2013 to July 2014 in the orthodontic department of Peking University School and Hospital of Stomatology. The eligibility criteria for inclusion in this study were patients (1) had all erupted permanent teeth, (2) had Angle's Class I or II malocclusion whose treatment required medium or maximum anchorage control, (3) had two upper 1st bicuspid or four 1st bicuspid extracted (4) were in good health with no chronic disease or disability. Informed consent was obtained from the patients and their parents or legal guardians before recruitment.

Interventions

The appliance and treatment philosophy used in PASS and MBT are different [15]. PASS is a modified straight wire system based on physiologic characteristics of individual patient and classical anchorage control strategy and it aims at reduction of maxillary dentoalveolar compensation and shares the similar goal of Tweed when keeping the upper curve of Spee is concerned. The appliance used in PASS is mainly composed of cross-buccal tube (XBT) and multi-level low-friction (MLF) brackets (Fig 1). The first stage of the treatment in PASS is alignment of the anterior teeth. The basic treatment procedure: bond canine to canine MLF brackets and first molar XBT. Upper and lower 0.014-inch NiTi archwires engage in -25° auxiliary tube on the upper molar and -20° virtual tube on lower molar (Fig 2A). After aligning the anterior teeth, premolar and second molar would be bonded to align posterior teeth. In the meantime, the main tube would be used for the rest of the treatment. Patients in the PASS were treated according to PASS procedure.

Patients in the MBT™ group were treated according to the MBT™ technique. 0.022-inch slot-size preadjusted brackets and buccal tubes were bonded [7] (Fig 2B). Canine lacebacks were used to assist in control of canine crown during leveling and alignment. Any auxiliary anchorage device could be used in the MBT group for patients who needed extra anchorage control

Outcomes (primary and secondary) and any changes after trial commencement

Three-dimensional change of maxillary first molar was considered as the primary outcome measurement.

Secondary outcome measurements included the 3D changes of maxillary canines, and maxillary central incisors, including tip, torque, vertical and antero-posterior movement of maxillary canine; torque, vertical and antero-posterior movement of maxillary central incisor (Table I).

All measurements were performed using Rapidform 2006 (Inus Technology Inc., Seoul, Korea) on digital dental models at pre-treatment (T0), 3 months (T1), and 6 months (T2). Maxillary digital models of different time points were superimposed according

to Chen's method [16] (Fig 3A). The reference coordinate system was established on the digital model of T2. The three coordinate planes included the occlusal plane, the mid-sagittal plane, and the coronal plane. The occlusal plane was formed using the mesial buccal cusps of the bilateral maxillary first molars and the midpoint of the edge of the central incisor; the mid-sagittal plane was formed using two points (P1 and P2) along the mid-palatal suture and their projections on the occlusal plane (P1' and P2'); the coronal plane was determined by the plane passing through P1 and perpendicular to both occlusal plane and mid-sagittal plane. The angles of upper first molar-canine and central incisor were measured on digital dental model using Andrews' method [3] (Fig 3B,C). Single tooth superimposition was used to transfer the landmark located on T0 model to T1 and T2 to minimize the error from landmark identification (Fig 3D, E).

Sample size calculation

The calculation of the sample size was based on the known variability of the mesial displacement of upper molars measured by Xu et al. [11] and was described in detail in our previous article [12].

Interim analyses and stopping guidelines

Not applicable.

Randomization (random number generation, allocation concealment, implementation)

Patients were stratified by age, sex and molar anchorage strength. Then they were allocated into the PASS or MBT™ group randomly at a 1:1 ratio with a minimization method [12,17].

Blinding

The bracket system of PASS and MBT™ was quite similar to each other, so patients were blind. However, blinding of orthodontist was impossible because the appearance and treatment procedure were different between the two systems. The judges who did the measurements and analyzed the data were blinded.

Statistical analyses (primary and secondary outcomes, subgroup analyses)

All 192 study models were measured by three orthodontic residents. SPSS 16.0 (SPSS, Chicago, IL, USA) was used for statistical analysis. The significance level was set at $P < 0.05$.

ICC was calculated to evaluate inter-rater consistency. Every model was measured three times by the three residents and their average was used for the final measurement. The independent T-test was performed to detect any difference between the PASS group and the MBT™ group. Except for the inter-canine width and the inter-molar width, all other measurements had right and left. After comparing the right and the left measurement, no significant difference was found; thus, we combined every bilateral measurement into one measurement.

Results

Participant flow

Sixty-four patients were recruited and allocated randomly into the PASS group and MBT group. No patient was lost to follow-up in the first 3 and 6 months (Fig 4).

Baseline data

We used minimal stratified randomization and incorporated age, sex, and anchorage requirement (moderate or maximum) as variables in stratification. So the baseline of the two groups was similar to each other. (Table II).

Number analyzed for each outcome, estimation, and precision

During treatments, miniscrews were used in 12 patients in the MBT group. In the PASS group, no auxiliary device was not used to enhance molar anchorage. Before analyses, the distribution of sex, age groups, and anchorage requirements were compared between the two groups and no significant difference was found.

Twenty sets of digital casts among samples were chosen randomly to assess the repeatability of the 3D measurement. Both superimposition and measurements were repeated 1 month apart. The ICC (Intraclass correlation coefficient) showed a high level of linear measurements (0.985) and angular measurements (0.886) [10].

The results showed many differences in the PASS and the MBT™ groups. The most significant difference was the tip of the maxillary first molar. The molars in the PASS group exhibited continuous distal tipping: -0.88° from T0 to T1, -1.79° from T1 to T2, with a total of -2.67° from T0 to T2; the molars in the MBT™ group first showed mesial tipping and then slight distal tipping: 2.38° from T0 to T1, -0.43° from T1-T2, with a total of 1.95° from T0 to T2. The differences were statistically significant. The antero-posterior and vertical change of the first molars also showed some statistical difference (Table III).

The 3D movement of the maxillary canines and central incisors in the PASS and the MBT™ groups were similar except for the inter-canine width, which increased 1.31 mm in the PASS group and 2.37 mm in the MBT™ group, and it was statistically significant (Table III).

Harms

No adverse event was observed in any patient in either group

Discussion

Main findings in the context of the existing evidence and interpretation

Traditionally, anchorage loss is believed to be caused by reaction of orthodontic force in correcting malocclusion. In extraction cases treated with SWA, molar mesialization along with mesial tipping will occur throughout the entire treatment and will cause anchorage loss. From the mechanical point of view, three elements mainly contribute to anchorage loss: the built-in prescription in the molar tube; the protraction force of molar generated by anterior segment during anterior aligning; the counteracting force during anterior retraction. At the beginning of the treatment, anchorage loss is mainly attributable to the first two elements, especially the wide spread of NiTi wire that makes bending tip backs impractical if not impossible.

However, some non-mechanical factors also play important roles in anchorage loss secretly. From the perspective of craniofacial growth and development, many studies reported mesialization of the maxillary molars, especially in adolescence [18, 19]. It is common to overlook a slow and gradual molar mesialization during orthodontic treatment. From the cross-sectional study [10], adolescent and CL II patients on average presented with the most distal tipping of maxillary molars, which were predisposed to iatrogenic anchorage loss during alignment and leveling. "Physiological drift of the teeth" or "Physiological drift", named by Bourdet [20], is another important factor. Clinical studies on physiological drift after extraction focused on lower dentition mainly [21–25]. Teng [26] assessed the three-dimensional pattern of the physiologic drift of the remaining adjacent teeth after premolar extraction. They found maxillary first molars and canines tended to drift into the spaces at a similar speed, indicating that the mesial drift of molars after premolar extraction may cause molar anchorage loss and should be prevented as soon as possible after premolar extraction in maximal anchorage case. Xu's study [11] showed that the conventional headgear can't prevent upper molar from forward tipping on straight wire technique and found that anchorage loss related to physiologic characteristics such as: age, sex, etc. So, he conceptualized physiological anchorage loss and developed PASS to preserve anchorage.

PASS is a new technique based on the physiological characteristics of the jaws. It makes use of the natural anchorage preservation of molars and designs a differential moment from canine to molar to allow distal migration of canine as well as preventing molar from mesialization. Therefore, it not only avoids iatrogenic anchorage loss but also encourages early distal migration of the anterior segment of the dentition.

From table 3, the maxillary first molar in the PASS group tipped distally of 2.67° in the first 6 months, and the mesial buccal cusp distalized of 0.03 mm. This result supported that PASS could preserve anchorage in early treatment. By staging the maxillary molar movement, we appreciated that it distally tipped about 1° with 0.2mm mesialization in the PASS group in the first 3 months, which showed a significant difference in comparison to the molars in the MBT™ group (mesial tipping of 2.4° with 0.6mm mesialization). We found, during this period, the maxillary molars in the MBT™ group rapidly lost anchorage, and it was accountable for the major anchorage loss in the first 6 month. Though molars in the PASS group tipped distally, it mesialized 0.2mm. It could be that the initial wire insertion involved thin NiTi wire (0.012~0.014”), and it might not be strong enough to counteract the tendency of molar mesialization; rather, the -25° molar tube mainly prevented mesial tipping of the maxillary molars. After 3 months in treatment, stronger NiTi became the choice of treatment (0.016-0.018”); therefore, the maxillary molars were distalized and distally tipped. It showed a significant difference compared to the MBT™ group in the 3-6 month period.

There was not much research studying PASS. However, Chen [12] found PASS could be used in cases that required maximum anchorage. The XBT consists of a -7° main tube and a -25° tip-back auxiliary tube. The initial archwire will be inserted into the tip-back tube, thereby creating a protection moment for molar anchorage from the very beginning of the treatment. With this design, it is therefore expected that crown distal tipping can be reinforced even with the use of very light NiTi wire and without any wire bending. Though it may not be strong enough to distally tip molars, it maintains the original angulation of molars and further avoids physiological anchorage loss during growth and development. The -25° tip-back auxiliary tube create a mechanic similar to situation when V bend located very close to first molar, which will create a clockwise moment on both first molar and canine. PASS use the differential moment [27] rather than laceback to move canine. We learned this from Burstone’s six classes of two-toothforce system [28].

Vertically, the mesial and distal buccal cusps of the maxillary molars extruded in the PASS group in the first 6 months, while they were intruded in the MBT™ group with a significant difference. This can be explained by the moment of force in their systems: the first molars in the PASS group had a clockwise moment while it had a counterclockwise moment in the MBT™ group. To further study PASS, more research should be done to study the positional change of molars after 6 months – the question to be asked is whether this extrusion last throughout or after the treatment? Or it diminishes during the use of the main tube or during space closure?

As to the change of canine in the two groups ,inter-canine width change showed a statistically significant difference: in the first 3 months, the width increased 1.04 mm in the PASS group while 2.10 mm in the MBT™ group; in the first 6 months, the width increased 1.31 mm in the PASS group while 2.37 mm in the MBT™ group. This is mainly caused by the different treatment procedure. MBT™ bonds second premolars in the very beginning, while PASS does not.

Usually, the displacement of the first molar is enough to evaluate the anchorage loss. However, situation is different when we compare the anchorage control during alignment and leveling, since the extraction space has not been closed in most situation. The retraction amount of central amount matters. There is no statistically significant difference in the movement of central incisors between the two groups, which means we can evaluate the anchorage control by comparing the change of first molar in MBT™ and PASS group.

Limitations

This was a single-center study. Although the inclusion of an untreated control group would be ideal to compare treatment and normal growth changes, it was not plausible because of the drift of the anchorage molar would happen during the observational time.

This study only compared the 3D change of the maxillary first molars, canines and central incisors. The story would be more intact if we could have evaluated the mandibular teeth. However, it is still a problem to superimpose mandibular models of different time point accurately without the aid of X-ray films.

Conclusion

1. In the MBT™ group, upper first molars tip forward significantly during alignment and leveling, especially in the first 3 months, which means anchorage loss happens at the beginning of the treatment.
2. In the PASS group, upper first molars exhibit continuous distal tipping during alignment and leveling and molar anchorage is well protected. The null hypothesis that PASS and MBT™ have similar capacity of anchorage control in the initial stage of treatment was rejected. PASS is better at reducing molar mesialization and mesial tipping during alignment and leveling and therefore better preserve anchorage.

Abbreviations

PASS: Physiologic anchorage spee-wire system; RCT: Randomized controlled trial; TAD: Temporary anchorage device; 3D: Three-dimensional; XBT: cross-buccal tube; MLF: multi-level low-friction; SWA: Straight wire appliance

References

1. Peck S, Peck H. Frequency of tooth extraction in orthodontic treatment. *Am J Orthod.* 1979 Nov;76(5):491–6.
2. Jackson TH, Guez C, Lin FC, Proffit WR, Ko CC. Extraction frequencies at a university orthodontic clinic in the 21st century: Demographic and diagnostic factors affecting the likelihood of extraction. *Am J Orthod Dentofacial Orthop.* 2017 Mar;151(3):456–462.
3. Andrews LF. The six keys to normal occlusion. *Am J Orthod.* 1972 Sep;62(3):296–309.
4. Tweed CH. Indications for the extraction of teeth in orthodontic procedure. *Am J Orthod.* 1944;30(8):405–428.
5. Soejima U, Motegi E, Nomura M, Yamazaki M, Sueishi K. Change in proportion of extraction and non-extraction in orthodontic patients. *Bull Tokyo Dent Coll.* 2014;55(4):225–31.
6. Alharbi F, Almuzian M, Bearn D. Anchorage effectiveness of orthodontic miniscrews compared to headgear and transpalatal arches: a systematic review and meta-analysis. *Acta Odontol Scand.* 2019;77(2):88–98.
7. McLaughlin, R.P., Bennett, J.C. and Trevisi, H.J. (2001) Systemized orthodontic treatment mechanics. In McLaughlin, R.P., Bennett, J.C., Trevisi, H.J. (eds), *Anterior-Posterior Anchorage Support During Tooth Leveling and Aligning*. Mosby, St. Louis, MO.
8. Fleming PS, Johal A, Pandis N. The effectiveness of laceback ligatures during initial orthodontic alignment: a systematic review and meta-analysis. *Eur J Orthod.* 2013 Aug;35(4):539–46.
9. Geron S, Shpack N, Kandos S, Davidovitch M, Vardimon AD. Anchorage loss—a multifactorial response. *Angle Orthod.* 2003;73:730–737.
10. Su H, Han B, Li S, Na B, Ma W, Xu TM. Factors predisposing to maxillary anchorage loss: a retrospective study of 1403 cases. *PLoS one.* 2014;9(10):e109561
11. Xu TM, Zhang X, Oh HS, Boyd RL, Korn EL, Baumrind S. Randomized clinical trial comparing control of maxillary anchorage with 2 retraction techniques. *Am J Orthod Dentofacial Orthop.* 2010 Nov;138(5):544.e1-9
12. Chen H, Han B, Jiang R, Su H, Feng T, Teng F, Xu T. PASS versus MBT™ for evaluation of anchorage control in three-dimensional measurements: a randomized controlled trial. *Eur J Orthod.* 2021 Jan 29;43(1):113–119.
13. Al-Awadhi EA, Garvey TM, Alhag M, Claffey NM, O'Connell B. Efficacy of the Nance appliance as an anchorage-reinforcement method. *Am J Orthod Dentofacial Orthop.* 2015 Mar;147(3):330–8.
14. D. Moher, S. Hopewell, K.F. Schulz, V. Montori, P.C. Gøtzsche, P.J. Devereaux, et al. CONSORT 2010 Explanation and Elaboration: updated guidelines for reporting parallel group randomised trials. *J Clin Epidemiol*, 63 (2010), pp. e1-37.
15. Xu, T.M. (2017) Paradigm shift by straight wire appliance and its impact on anchorage control. In Xu, T.M. (ed.), *Physiologic Anchorage Control: A New Orthodontic Concept and its Clinical Application*. Springer, Cham, Switzerland.
16. Chen, G., Chen, S., Zhang, X.Y., Jiang, R.P., Liu, Y., Shi, F.H. and Xu, T.M. (2011) Stable region for maxillary dental cast superimposition in adults, studied with the aid of stable miniscrews. *Orthodontics & Craniofacial Research*, 14, 70–79.
17. Taves, D.R. (1974) Minimization: a new method of assigning patients to treatment and control groups. *Clinical Pharmacology and Therapeutics*, 15, 443–453.

18. Iseri H, Solow B. Continued eruption of maxillary incisors and first molars in girls from 9 to 25 years, studied by the implant method. *Eur J Orthod.* 1996 Jun;18(3):245–56.
19. Zhang X, Baumrind S, Chen G, Chen H, Liang Y, Xu T. Longitudinal eruptive and posteruptive tooth movements, studied on oblique and lateral cephalograms with implants. *Am J Orthod Dentofacial Orthop.* 2018;153:673–684.
20. Bourdet, M. *Researches et Observations. Sur toutes les parties de l'art du Dentiste*, Paris 1957.
21. Stephens, C. D. The Rate of Spontaneous Closure at the Site of Extracted Mandibular First Premolars. *Br. J. Orthod.* 10, 93–97 (1983).
22. Stephens, C. D. & Houston, W. J. Facial growth and lower premolar extraction space closure. *Eur. J. Orthod.* 7, 157–162 (1985).
23. Papandreas, S. G., Buschang, P. H., Alexander, R. G., Kennedy, D. B. & Koyama, I. Physiologic drift of the mandibular dentition following first premolar extractions. *Angle Orthod.* 63, 127 (1993).
24. Swessi, D. M. & Stephens, C. D. The spontaneous effects of lower first premolar extraction on the mesio-distal angulation of adjacent teeth and the relationship of this to extraction space closure in the long term. *Eur. J. Orthod.* 15, 503–511 (1993).
25. Gragg, K. L., Shugars, D. A., Bader, J. D., Elter, J. R. & White, B. A. Movement of Teeth Adjacent to Posterior Bounded Edentulous Spaces. *J. Dent. Res.* 80, 2021–2024 (2001). Different amount of molar and canine drifts were observed in different studies.
26. Teng F, Du FY, Chen HZ, Jiang RP, Xu TM. Three-dimensional analysis of the physiologic drift of adjacent teeth following maxillary first premolar extractions. *Sci Rep.* 2019 Oct 10;9(1):14549
27. Mulligan TF (1982) *Common sense mechanics*. 2122 East Kaler Drive, Phoenix, AZ 85020
28. Burstone CJ, Koenig HA. Force systems from an ideal arch. *Am J Orthod.* 1974 Mar;65(3):270–89

Tables

Table 1 Definition of measurements

Measurements	Definition
6-6 width	Distance between the bilateral mesial buccal cusps of maxillary first molar (projected on the occlusal plane)
6 tip	The tip of maxillary first molar mesial tipping “+”
6 tor	The torque of maxillary first molar buccal crown torque “+”
6 MCH	The height of the mesial buccal cusp of maxillary first molar extrusion “+”
6 DCH	The height of the distal buccal cusp of maxillary first molar extrusion “+”
6 AP	The anteroposterior movement of the mesial buccal cusp of maxillary first molar mesialization “+”
3-3 width	Distance between the bilateral cusps of maxillary canines (projected on the occlusal plane)
3 tip	The tip of maxillary canine mesial tipping “+”
3 tor	The torque of maxillary canine buccal crown torque “+”
3 CH	The height of the cusp of maxillary canine extrusion “+”
3 AP	The anteroposterior movement of the cusp of maxillary canines mesialization “+”
1 tor	The torque of maxillary central incisors labial crown torque “+”
1 H	The height of the edge of maxillary central incisor extrusion “+”
1 AP	The anteroposterior movement of the edge of maxillary central incisor mesialization “+”

Table II Baseline characteristics of all patients

Baseline variable	PASS	MBT™	Total
Male	10	11	21
Female	22	21	43
Adolescent	22	22	44
Adult	10	10	20
Maximum anchorage	21	21	42
Moderate anchorage	11	11	22
Total	32	32	64

Table III The 3D movement of the maxillary first molars, canine and central incisor (n=64)

group	T0-T1				T1-T2				T0-T2			
	Mean	SD	T	P	Mean	SD	T	P	Mean	SD	T	P
PASS	-0.88	3.04	-6.492	0.000**	-1.79	3.41	-2.77	0.006**	-2.67	4.59	-6.717	0.000**
MBT	2.38	2.62			-0.43	1.96			1.95	3.04		
PASS	-1.85	6.01	-0.629	0.53	-0.5	5.84	-1.381	0.17	-2.36	5.86	-1.864	0.065
MBT	-1.28	4.19			0.82	4.99			-0.45	5.69		
PASS	0.46	0.52	6.771	0.000**	0.03	0.61	1.204	0.231	0.5	0.73	6.096	0.000**
MBT	-0.11	0.43			-0.08	0.42			-0.19	0.52		
PASS	0.32	0.51	2.718	0.007**	-0.14	0.55	-0.034	0.973	0.18	0.67	2.129	0.035*
MBT	0.09	0.47			-0.14	0.38			-0.05	0.56		
PASS	0.22	0.75	3.422	0.001**	-0.24	0.96	2.063	0.041*	-0.03	1.02	4.283	0.000**
MBT	0.61	0.54			0.06	0.64			0.67	0.79		
PASS	-4.69	7.63	0.812	0.418	0.38	3.45	-0.233	0.816	-4.31	9.68	0.586	0.559
MBT	-5.74	6.92			0.51	2.89			-5.22	7.86		
PASS	-1.56	7.55	-0.557	0.579	-2.08	4.08	-1.344	0.181	-3.64	8.1	-1.146	0.254
MBT	-0.86	6.71			-1.17	3.54			-2.03	7.79		
PASS	0.32	1.44	-1.467	0.145	0.41	0.68	0.178	0.859	0.73	1.68	-1.162	0.247
MBT	0.65	1.12			0.39	0.69			1.04	1.36		
PASS	-2.38	1.5	-0.268	0.789	-1.19	1.43	-1.715	0.089	-3.57	2.08	-1.273	0.205
MBT	-2.3	1.9			-0.8	1.14			-3.09	2.12		
PASS	-3.48	5.78	-1.098	0.274	-3.37	4.78	-1.375	0.172	-6.85	7.38	-1.683	0.095
MBT	-2.41	5.24			-2.39	3.12			-4.8	6.37		
PASS	0.61	1.08	0.448	0.655	0.38	0.59	-1.01	0.314	0.99	1.17	-0.289	0.773
MBT	0.53	1			0.53	1.04			1.06	1.47		
PASS	-1.06	1.31	-1.388	0.168	-0.98	1.27	-0.238	0.813	-2.03	1.81	-1.112	0.268
MBT	-0.75	1.21			-0.92	1.26			-1.67	1.88		

"-": distal tipping, lingual crown torque, intrusion and distalization

Figures

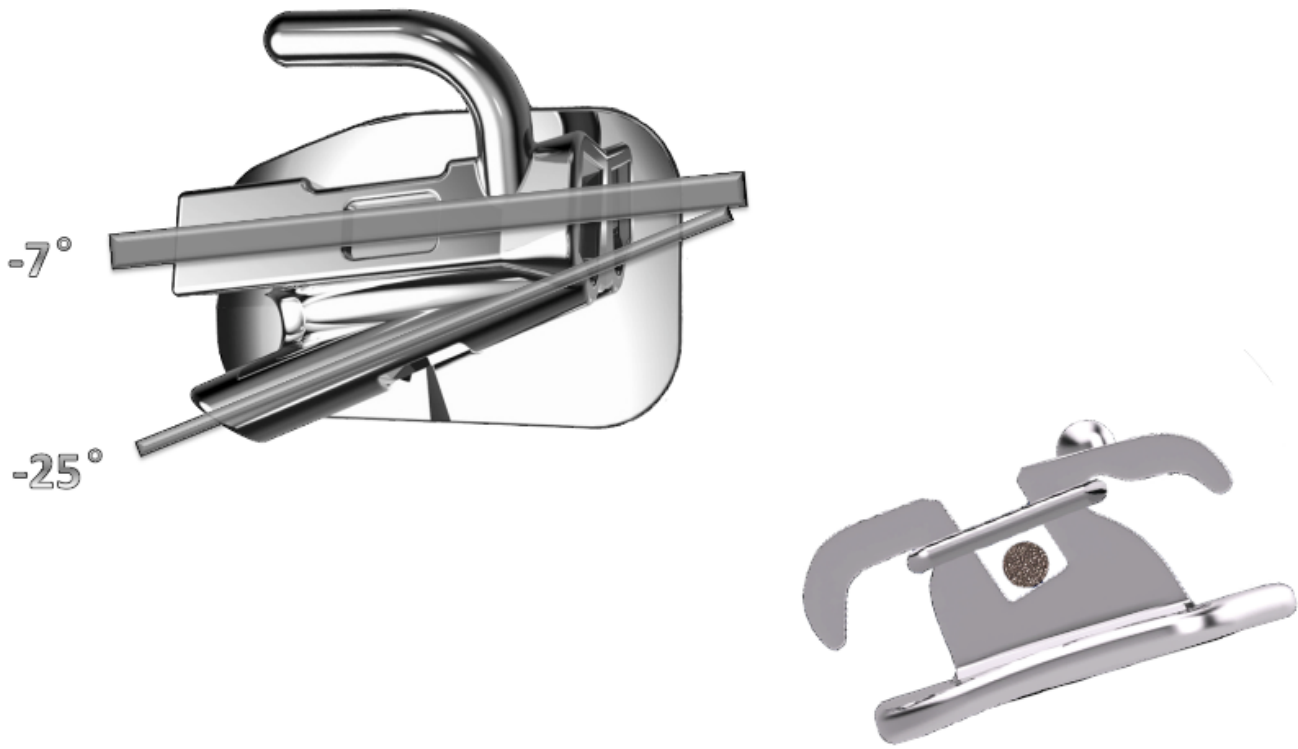


Figure 1

XBT and MLF bracket used in PASS. XBT molar tube consists of two tubes: the distal-tipping tube that prevents NiTi wire from tipping the molar forward; the main tube that prevents anchorage loss during space closure. MLF bracket: The ligature tie can slide underneath the wings of the bracket, creating a self-ligating effect, and orthodontists can adjust the amount of friction for every single tooth as needed.

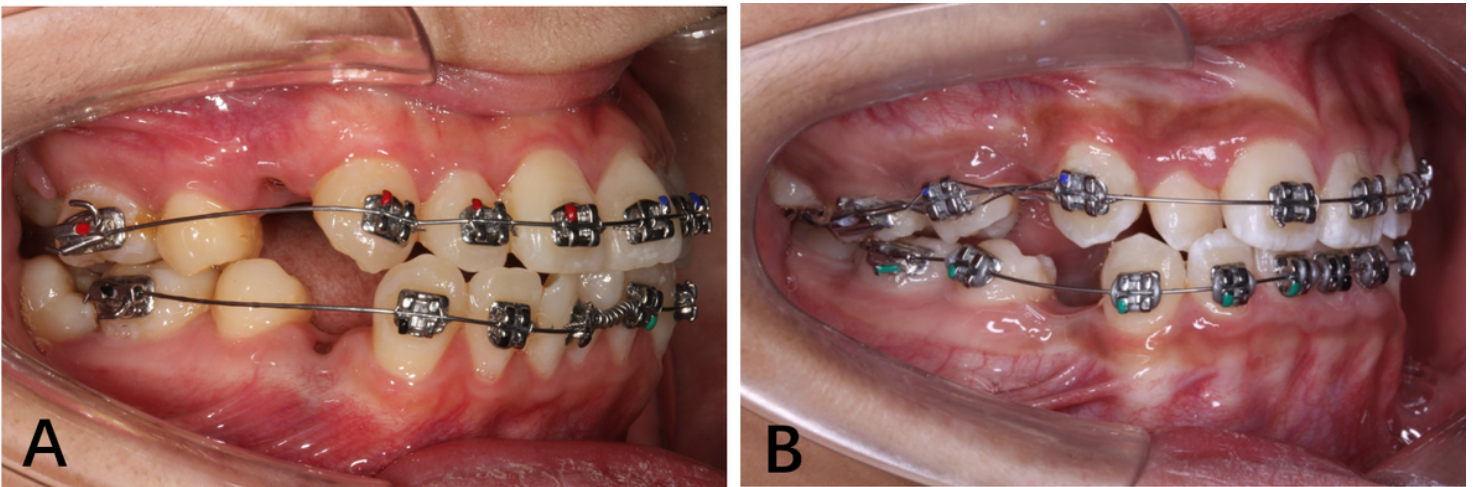


Figure 2

A, Protocol including patients treated with PASS. B, Protocol including patients treated with MBT™.

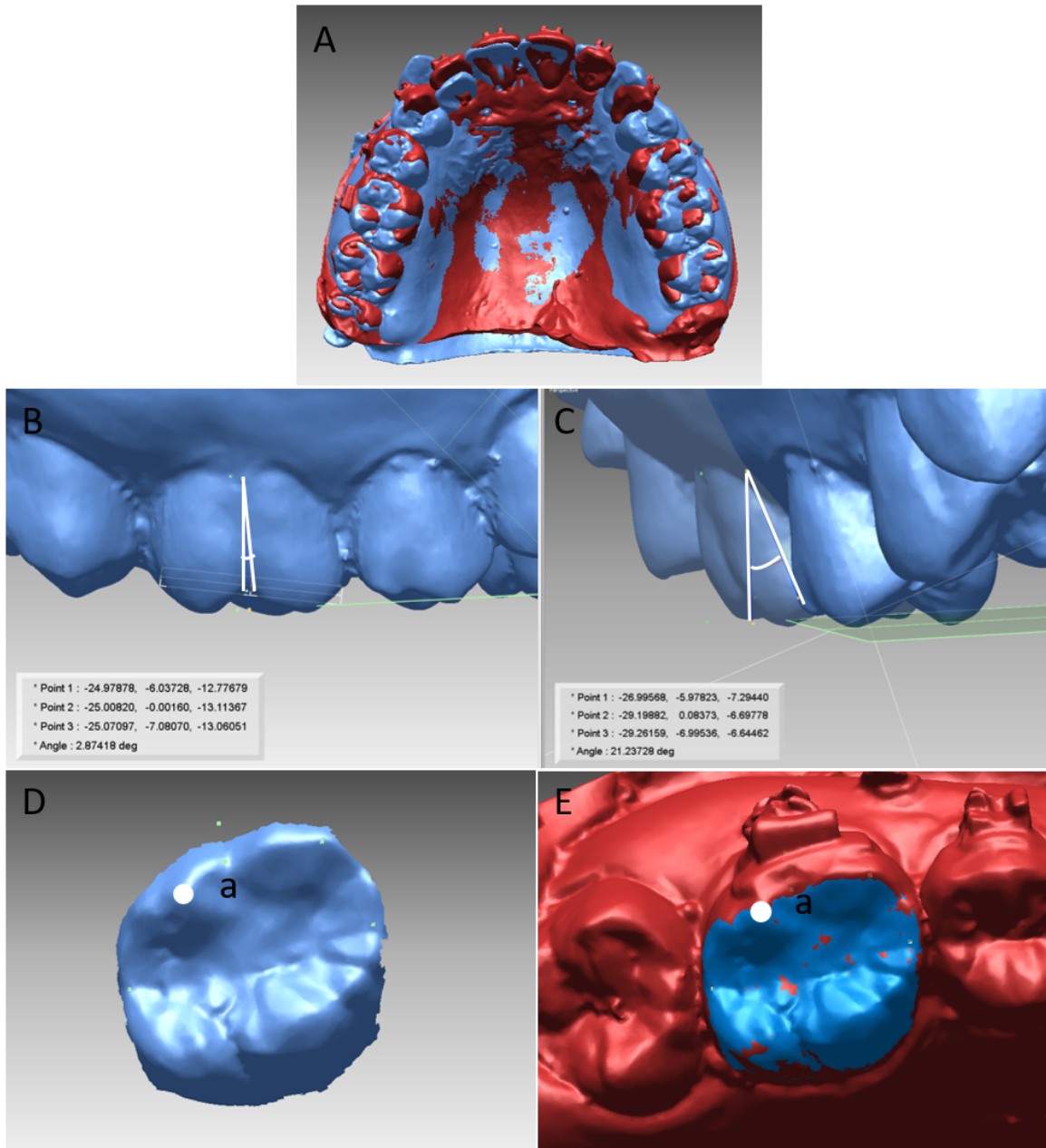


Figure 3

A, Superimposition of maxillary digital models of different time point. B, Tip of maxillary first molar. C, Torque of maxillary first molar. D, landmark a on pre-treatment molar. E, point a was transfer to the same molar on different model using regional superimposition.

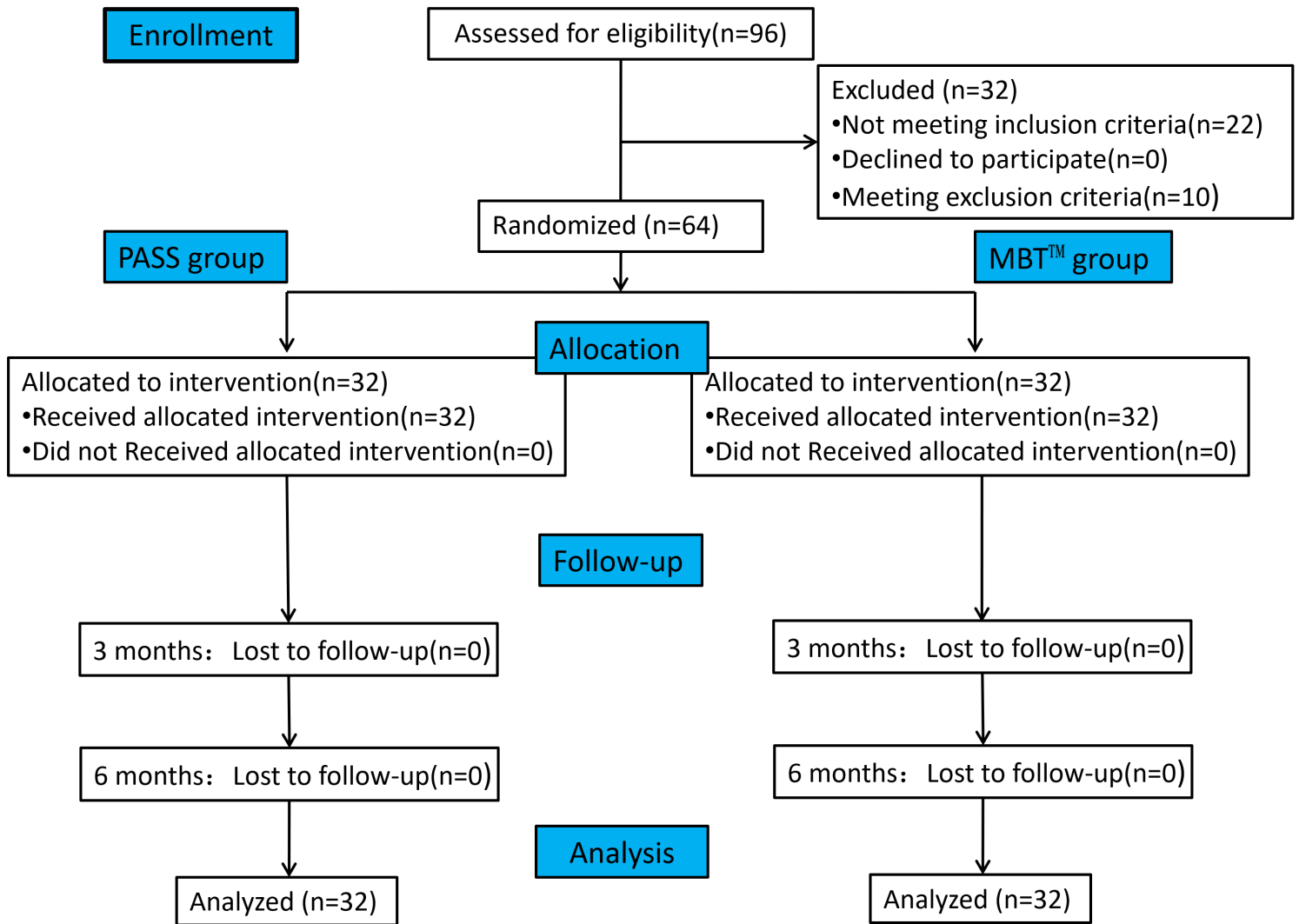


Figure 4

Consolidated Standards of Reporting Trials flow diagram