Autologous osteochondral transplantation method of treatment for recurrent anterior shoulder instability

Mingtao Zhang
Lanzhou University Second Hospital https://orcid.org/0000-0003-3440-011X

Zhitao Yang
Lanzhou University Second Hospital

Jiaxin Liu
Lanzhou University Second Hospital

Yaofei Jia
Lanzhou University Second Hospital

Guangrui Zhang
Lanzhou University Second Hospital

Jianping Zhou
Lanzhou University Second Hospital

Ding Wu
Lanzhou University Second Hospital

xiangdong yun (xiangdongyun@126.com)
Lanzhou University Second Hospital https://orcid.org/0000-0003-2446-1429

Research article

Keywords: Shoulder instability, Glenoid bone lesion, Autologous osteochondral transplantation

Posted Date: September 16th, 2021

DOI: https://doi.org/10.21203/rs.3.rs-885669/v1

Abstract

Background

Generally, the treatment of recurrent anterior shoulder instability is a challenge in the orthopedics with various treatment methods. There is a high recurrence rate for those patients with high activity and glenoid bone lesion less than 20% after Bankart procedure. The authors present a novel surgical technique using autologous osteochondral transplantation (AOT) method for recurrent anterior shoulder instability.

Methods

Between 2019 to 2021, 7 patients (five man and two women; mean age 35.1 years (range 17–55 years)) with recurrent anterior shoulder instability and glenoid bone lesion of 20% or less were treated with AOT method. All patients were available for follow-up at a mean of 25.4 months (range, 16 to 32 months), including Rowe score, Oxford Shoulder Score (OSS), Simple Shoulder Test (SST), and 3-dimensional computed tomography examination.

Results

The mean preoperative and postoperative Rowe score were calculated to be 25.7 ± 6.7 (range, 20–35) and 90.6 ± 2.4 (range, 85–95), respectively ($p < 0.01$). The mean preoperative and postoperative Oxford score were 36.4 ± 5.6 (range, 30–40) and 54.6 ± 2.4 (range, 50–57), respectively ($p < 0.01$). The mean preoperative and postoperative SST score were 6.9 ± 0.7 (range, 6–8) and 11.5 ± 0.7 (range, 11–12), respectively ($p < 0.01$). The average final forward flexion was 176° (affected shoulder), compared with 177° on the non-affected shoulder ($P = 0.81$). The average final abduction in external rotation was 86.6° (affected shoulder), compared with 89° on the non-affected shoulder ($P = 0.31$). Analysis of Computed Tomography (CT) data at an average 1 years postoperative showed that a mean glenoid bony gain of 16.7% was observed (range, 11.2%-19%, SD 3.6).

Conclusion

This technique can be a useful option, particularly in patients with glenoid bone defect less than 20%. In addition, AOT technique may be considered as alternative to the Latarjet procedure. Nonetheless, further biomechanical and clinical studies are needed to determine the effect of this procedure to more commonly utilized techniques.

Level of Evidence

Level IV; Case series

Introduction

The glenohumeral joint is the most common joint of the body to dislocate, and it's incidence is about 1.7% and more common in contact athletes[7, 19]. Anterior shoulder dislocation contributes 90% of all shoulder instability. The stability of the glenohumeral joint is imparted by dynamic and static stabilization. Dynamic stabilization is provided by the rotator cuff, periscapular musculature and long-head of the biceps brachii[31]. Static stabilization is offered by the glenohumeral joint[16, 31]. Glenoid bone defect is known to reduce shoulder instability by decreasing the concavity-compression effect, and has been recognized as one of the most important structural deficiency associated with the success of surgical procedures[29]. Severe glenoid bone defect may be the main cause of recurrent shoulder instability after capsule labrum repair or reconstruction[5]. Therefore, it is important for surgeons to determine the surgical methods based on the amount of glenoid bone defect.

A variety of arthroscopic and open techniques have been introduced to treat glenoid bone defect, including Bankart repair[22], Bristow-Latarjet[8] and bone graft procedures[4, 15]. However, it reported that there is a high incidence of recurrent instability after isolated Bankart repair[18] and Bristow-Latarjet procedure still represent highly techniques with a great number of complications[10].

In generally, when glenoid bone defect in excess of 13–20%, bone graft procedures will recommended to reconstruct shoulder instability, such as distal tibial allograft[21], iliac crest bone grafting[4] and osteoarticular distal clavicle grafting[15]. The advantage of distal tibial allograft is that it has articular cartilage and no donor-site morbidity, but it is an allograft and has an increased cost. The iliac crest bone graft is an autograft and relatively inexpensive; however, it associated with donor-site morbidity and does not have articular cartilage. In addition, the advantage of osteoarticular distal clavicle graft is that it is an autograft and has articular cartilage; however, the disadvantage is that the quality of the bone was concerned and it also associated with donor-site morbidity. Among this, the autologous osteochondral transplantation (AOT) has particularity become popular with the patients with bone loss in recent studies.

The AOT method is an operative option that replaces the osteochondral lesion with autologous cartilage and subchondral bone by transplantation of osteochondral graft from a non-weight-bearing portion of knee[14]. It is commonly used for osteochondral lesions, including patellar osteochondral lesions[1], distal tibial plafond osteochondral lesions[17], talus osteochondral lesions[25]. Many studies have reported that there is a satisfactory clinical outcomes and fewer donor-site morbidity. However, no studies have been conducted by using AOT method to treat glenoid bone lesion.

The goal of our study was to report the clinical outcome and osteochondral graft changes over time after glenoid reconstruction by method of AOT in recurrent anterior shoulder instability cases with glenoid bone defect less than 20%.

Materials And Methods

This prospective study followed 7 consecutive patients with recurrent anterior shoulder instability and glenoid bone lesion of 20% were treated with AOT method at our institution between 2019 to 2021. The study population consisted of 5 men and 2 women with a mean age of 35.1 years (range, 17–55). Five injuries were trauma-related. Six dominant shoulders were affected (Table 1). All patients had no undergone prior surgeries. All patients gave informed consent. All surgery procedures were performed by the same senior surgeon.

Table 1
Demographic data

Case	Sex	Age	Cause	Lesion(%)	Dominant Side	Hill-Sachs lesion	Time of dislocation before operation	BMI (kg/m²)	Duration of follow-up (months)
1	M	55	Traffic accident	18.3	Y	Engaging	> 5	20.9	13
2	F	50	Unknown	17.2	Y	Nonengaging	> 5	22.6	14
3	M	18	Triathlon	16.3	Y	Nonengaging	> 10	23.9	12
4	F	51	Unknown	15.1	Y	Nonengaging	> 5	25.7	15
5	M	17	Triathlon	19.2	Y	Nonengaging	> 10	25	12
6	M	28	Basketball	19	N	Engaging	> 50	26	7
7	M	27	Triathlon	16.4	Y	Nonengaging	> 20	22.3	17

Diagnoses were made by means of preoperative data, including history, physical examination, radiographs, and CT scans with 3-dimensional (3D) reconstructions of the glenoid. All preoperative and postoperative images were assessed by the same senior surgeon. We did not include patients with glenoid bone defect greater than 20%. We did the measurements of the glenoid lesion by the perfect circle way, using the percentage of glenoid lesion relative to the surface area of the glenoid on the 3D reconstruction view (Fig. 1a). All patients showed a glenoid bone lesion less than 20% and normal rotator cuff function and a positive anterior apprehension sign. In addition, preoperative clinical assessments including the Rowe score, Oxford Shoulder Score (OSS) and Simple Shoulder Test (SST) were collected. Intraoperative data, including concomitant pathologies, defect size and articular assessment by the senior surgeon, were collected.

This study was performed in line with the principles of the Declaration of Helsinki. Approval was granted by the Ethics Committee of Lanzhou University Second Hospital.

Surgical Technique

After successful general anesthesia, the patient was placed in a prone position with the right lower extremity in a flexible 90° position, routinely disinfected, and a surgical sheet was placed. The AOT procedures were performed by using the Osteochondral Autograft Transfer System (OATS) system (Arthrex, Naples, FL). The arthroscope was routinely inserted and the anterior and posterior cruciate ligaments of the medial and lateral menisci of the knee were examined to be intact. A longitudinal incision of approximately 3 cm was made at the superior medial edge of the right knee patella, and the soft tissues were sequentially separated and the superior medial edge of the femoral talus was exposed. A large amount of saline was used to flush and thoroughly stop the bleeding, and the surgical instruments were counted and the incisions were closed layer by layer with dressings after the gauze was clean. The patient's position was changed to right lateral recumbency with 6 Kg tension traction on the left upper limb, and the surgical sheet was routinely disinfected and spread. Saline with epinephrine was injected into the joint cavity, and an incision of 1.0 cm in length was made 2 cm downward and 2 cm inward from the posterior lateral angle of the left acromion and 1.0 cm outward for the posterior approach and the posterior superior approach, respectively. The Trocar was inserted into the joint cavity and the arthroscope was inserted to examine the left shoulder cavity in a certain order and to remove the hyperplastic synovial tissue. At the 5 o'clock position of the shoulder joint, a bone tunnel of 15 mm in

length was drilled with a 6mm drill and the cartilage was removed and implanted into the tunnel. The hyperplastic synovial tissue was cleared and the adhesions were fully released. Then, two 3.0 mm wire anchors were implanted in the 5 o'clock and 3 o'clock directions of the glenoid to close the torn glenoid lip, and the shoulder joint was examined for stability and good mobility. After counting the surgical instruments and gauze, the incisions were closed layer by layer and dressings were applied. (Figure 1b.c.d.e)

Postoperative rehabilitation

The arm was immobilized in a sling and swathed after the surgical procedure was complete. For the first postoperative week, the shoulder was maintained in an abduction sling. For the first 2 to 4 weeks, passive and pendulums range of motion in the scapular plane are started. From the 4 weeks, patients were encouraged to begin active-assisted exercises. At 6 to 8 weeks, the patients begin strengthening. Full return to activity is expected at 4 to 6 months postoperatively.

Outcome Measures

Postoperative data, including recurrence dislocation events, complications, physical examination findings, CT scans and clinical outcomes scores were collected and analysis.

Results

All patients underwent clinical follow-up (100%) at an average duration 25.4 months (range, 16 to 32 months) after surgery. 7 patients were diagnosed with anterior shoulder instability with a glenoid bone lesion less than 20%. All patients were conducted a 3D-CT scans after surgery (Fig. 1e). The average preoperative glenoid bone lesion was 17.4% ±1.5 (range, 15.1–19.2%).

The functional scores of the patients are provided in Table 2. The mean preoperative and postoperative Rowe score were calculated to be 25.7 ± 6.7 (range, 20–35) and 90.6 ± 2.4 (range, 85–95), respectively ($p < 0.01$). The mean preoperative and postoperative Oxford score were 36.4 ± 5.6 (range, 30–40) and 54.6 ± 2.4 (range, 50–57), respectively ($p < 0.01$). The mean preoperative and postoperative SST score were 6.9 ± 0.7 (range, 6–8) and 11.5 ± 0.7 (range, 11–12), respectively ($p < 0.01$).

Table 2
Comparison of shoulder function score before and after operation

Time	Rowe score	Oxford score	SST score
Preoperative	25.7 ± 6.7	36.4 ± 5.6	6.9 ± 0.7
Postoperative at 6 months	75 ± 4.0	47.9 ± 2.7	10 ± 0.8
Last follow-up	83.6 ± 2.4	53.6 ± 2.4	11.9 ± 0.7
F	27.36	12.14	32.01
P	0.01	0.01	0.01

At the last follow-up after surgery, all patients showed no sign of instability on clinical examination. None of the patients experienced an intraoperative or postoperative complication, and none underwent revision surgery procedures until the time of follow-up. No complications appeared at the site of graft harvesting at the non-weight-bearing portion of knee. The average final forward flexion was 176° (affected shoulder), compared with 177° on the non-affected

shoulder ($P = 0.81$). The average final abduction in external rotation was 86.6° (affected shoulder), compared with 89° on the non-affected shoulder ($P = 0.31$) (Fig. 2).

Analysis of CT data at an average 1 years postoperative showed that a mean glenoid bony gain of 16.7% was observed (range, 11.2%-19%, SD 3.6) (Fig. 1e). At the final follow-up, 7 patients had no signs of osteoarthritis and no graft fracture or migration was detected.

Discussion

The most important finding of this study was that arthroscopic autologous osteochondral transplantation method was an effective and safe technique in treating anterior shoulder instability in patients with glenoid bone lesion less than 20%. Generally, it is important for surgeons to determine the surgical methods based on the amount of glenoid bone defect. There is a controversy about critical size of the glenoid defect. Lo et al. [5] and Bigliani et al.[3] clinically reported that glenoid bone defect more than 25% of the inferior glenoid width was the critical size that bony augmentation methods should be considered. Also, it has been reported biomechanically that 25% of glenoid bone is a critical size[32]. However, Shaha et al.[26] reported that glenoid bone defect between 13.5% and 20% treated with Bankart procedure alone led to a clinically significant decrease in Western Ontario Shoulder Instability Index (WOSI) scores. A recent report demonstrated that bone defect more than 17.3% related to recurrent instability after surgery should be considered critical size[28]. Therefore, there seems to be a zone of glenoid bone defect below the critical size.

Recurrent anterior shoulder instability is associated with glenoid bone lesion in 90% of patients[13]. A recent meta-analysis reported that there was a high rate of recurrent shoulder instability, with 25% of patients experienced recurrent shoulder instability after Bankart repair, and the glenoid bone defect less than 20% was an important risk factor for recurrence instability follow Bankart procedure[11]. In addition, the Bristow-Latarjet procedure has been proven reliable to treat recurrent shoulder instability with glenoid bone lesion[2]. However, there were concern as to the high incidence of surgical complications associated with Latarjet procedure.

The introduction of the glenoid track concept has drawn interest in functional bone lesion and enlarged the applicability of glenoid bone augmentation means for patients with less pronounced glenoid bone defect[6, 26]. Therefore, bone graft procedure has become another choice for recurrent anterior shoulder instability with glenoid bone lesion less than 20%. An alternative to Latarjet procedure is offered by arthroscopically performed bone block procedures, including iliac crest autografts or other osteochondral allografts. All-arthroscopic iliac crest autografts augmentation techniques have been reported, including those of Jeong et al.[12] using an all-suture anchor, Taverna et al.[30] using EndoButton devices, and Scheibel et al.[23] using bio-compression screws. These minimally invasive procedures have some potential advantages, including preservation of the subscapularis musculotendinous unit[20], and decreasing the risk of hardware complications because of screw-free graft fixation[33]. Although bone graft procedure lack the potential advantages of the “triple stabilization” mechanism compared to the Latarjet procedure, according many studies, they do provide radiological restoration of glenoid area.

The AOT method is commonly used for osteochondral lesions. Seow et al.[1] reported that the AOT procedure for the treatment of patellar osteochondral defect resolves the symptoms of the patients and ensures an apparent functional and clinical improvement. Scranton et al.[24] and Shimozono et al.[27] have reported excellent clinical outcomes in the treatment of the talus osteochondral lesions by using AOT technique. When compared with other bone graft, AOT provide a unique resource capable of replacing the damaged joint surface with hyaline cartilage, which acts in a similar way to the original cartilage. In this study, we found that there were good clinical outcomes in the treatment of recurrent anterior shoulder instability by using AOT technique.

One of the disadvantages of the choosing AOT is the risk of donor site morbidity, which have been reported ranged from 0–50% in the treatment of talar osteochondral lesions. Fraser et al.[9] reported that the donor site morbidity was from 12.5% at the end of 2 years, dropping to 5% at the end of 5 years of observation. In our study, we did not have any complications at the donor sites at the follow-up examinations.

There were some limitations in this study. One of these limitations was the small number of patients. However, to our knowledge, it is the first study to provide clinical outcome about AOT technique in the treatment of recurrent anterior shoulder instability. Other limitation was the short duration of this study and the absence of comparison with a control group. Therefore, we think that there is a need for a study performed in larger number of patients for a longer period of time by comparison with a control group for further determining the effect of AOT in the treatment of recurrent anterior shoulder instability.

Conclusion

In conclusion, this technique can be a useful option, particularly in patients with glenoid bone defect less than 20%. In addition, AOT technique may be considered as alternative to the Latarjet procedure. Nonetheless, further biomechanical and clinical studies are needed to determine the effect of this procedure to more commonly utilized techniques.

Abbreviations

AOT
autologous osteochondral transplantation
OSS
Oxford Shoulder Score
SST
Simple Shoulder Test
CT
Computed Tomography
OATS
Osteochondral Autograft Transfer System
WOSI
Western Ontario Shoulder Instability Index

Declarations

Ethics approval and consent to participate: This study was performed in line with the principles of the Declaration of Helsinki. Approval was granted by the Ethics Committee of Lanzhou University Second Hospital.

Consent for publication: Informed consent was obtained from all individual participants included in the study. Patients signed informed consent regarding publishing their data and photographs.

Availability of data and materials: The datasets generated during and/or analyzed during the current study are available from the corresponding author on reasonable request.

Competing interests: The authors, their immediate families, and any research foundations with which they are affiliated have not received any financial payments or other benefits from any commercial entity related to the subject of this

article.

Institutional review board approval was not required for this study.

Funding: This work was supported by the The Second Hospital of Lanzhou University, "Cuiying Technology Innovation" program, clinical top-notch technology research project, CY2019-BJ04, clinical study of autologous osteochondral transplantation for the treatment of recurrent shoulder dislocation in young adults, and the Gansu Provincial Department of Science and Technology, Natural Science Foundation Project, 20JR10RA723, Study on the mechanism of autologous osteochondral transplantation in the treatment of recurrent shoulder dislocation.

Authors' contributions: Mingtao Zhang and Zhitao Yang collected the literature and wrote the article. Xiangdong Yun revised the article. Jiaxin Liu, Yaofei Jia, and Guangrui Zhang designed the study. Jianping Zhou and Ding Wu prepared figures and tables. All authors contributed toward data analysis, drafting and critically revising the paper and agree to be accountable for all aspects of the work.

Acknowledgements: The authors thank the financial support of the Second Hospital of Lanzhou University, "Cuiying Technology Innovation" program, clinical top-notch technology research project , clinical study of autologous osteochondral transplantation for the treatment of recurrent shoulder dislocation in young adults, and the Gansu Provincial Department of Science and Technology, Natural Science Foundation Project, Study on the mechanism of autologous osteochondral transplantation in the treatment of recurrent shoulder dislocation.

References

1. Akgun E, Akpolat AO. Autologous osteochondral transplantation method of treatment for patellar osteochondral lesions. J Orthop Surg (Hong Kong). 2019;27:2309499019851620.
2. An VV, Sivakumar BS, Phan K, Trantalis J. A systematic review and meta-analysis of clinical and patient-reported outcomes following two procedures for recurrent traumatic anterior instability of the shoulder: Latarjet procedure vs. Bankart repair. J Shoulder Elbow Surg. 2016;25:853–63.
3. Bigliani LU, Newton PM, Steinmann SP, Connor PM, McLlveen SJ. Glenoid rim lesions associated with recurrent anterior dislocation of the shoulder. Am J Sports Med. 1998;26:41–5.
4. Boehm E, Minkus M, Moroder P, Scheibel M. Arthroscopic iliac crest bone grafting in recurrent anterior shoulder instability: minimum 5-year clinical and radiologic follow-up. Knee Surg Sports Traumatol Arthrosc. 2021;29:266–74.
5. Burkhart SS, De Beer JF. Traumatic glenohumeral bone defects and their relationship to failure of arthroscopic Bankart repairs: significance of the inverted-pear glenoid and the humeral engaging Hill-Sachs lesion. Arthroscopy. 2000;16:677–94.
6. Di Giacomo G, Peebles LA, Pugliese M, Dekker TJ, Golijanin P, Sanchez A, et al. Glenoid Track Instability Management Score: Radiographic Modification of the Instability Severity Index Score. Arthroscopy. 2020;36:56–67.
7. Dodson CC, Cordasco FA. Anterior glenohumeral joint dislocations. Orthop Clin North Am. 2008;39:507–18. vii.
8. Dunn ASM, Petterson SC, Plancher KD. The Shoulder Trans-pectoralis Arthroscopic Portal Is a Safe Approach to the Arthroscopic Latarjet Procedure: A Cadaveric Analysis. Arthroscopy. 2021;37:470–6.
9. Fraser EJ, Savage-Elliott I, Yasui Y, Ackermann J, Watson G, Ross KA, et al. Clinical and MRI Donor Site Outcomes Following Autologous Osteochondral Transplantation for Talar Osteochondral Lesions. Foot Ankle Int. 2016;37:968–76.

10. Griesser MJ, Harris JD, McCoy BW, Hussain WM, Jones MH, Bishop JY, et al. Complications and re-operations after Bristow-Latarjet shoulder stabilization: a systematic review. J Shoulder Elbow Surg. 2013;22:286–92.
11. Haskel JD, Wang KH, Hurley ET, Markus DH, Campbell KA, Alaia MJ, et al. (2021) Clinical Outcomes of Revision Arthroscopic Bankart Repair for Anterior Shoulder Instability - A Systematic Review of Studies. J Shoulder Elbow Surg;10.1016/j.jse.2021.06.021.
12. Jeong JY, Yoo YS, Kim T. Arthroscopic Iliac Bone Block Augmentation for Glenoid Reconstruction: Transglenoid Fixation Technique Using an All-Suture Anchor. Arthrosc Tech. 2020;9:e351–6.
13. Kalogrianitis S, Tsouparopoulos V. Arthroscopic Iliac Crest Bone Block for Reconstruction of the Glenoid: A Fixation Technique Using an Adjustable-Length Loop Cortical Suspensory Fixation Device. Arthrosc Tech. 2016;5:e1197–202.
14. Kennedy JG, Murawski CD. The Treatment of Osteochondral Lesions of the Talus with Autologous Osteochondral Transplantation and Bone Marrow Aspirate Concentrate: Surgical Technique. Cartilage. 2011;2:327–36.
15. Larouche M, Knowles N, Ferreira L, Tokish JM, Athwal GS. Osteoarticular distal clavicle autograft for the management of instability-related glenoid bone loss: an anatomic and cadaveric study. J Shoulder Elbow Surg. 2020;29:1615–20.
16. Lugo R, Kung P, Ma CB. Shoulder biomechanics. Eur J Radiol. 2008;68:16–24.
17. Nery C, Prado M, Brauer G, Lemos AV. Retrograde Autologous Osteochondral Transplantation in Treating Osteochondral Lesion of Distal Tibial Plafond: A Case Report and Technical Tips. Foot Ankle Int. 2021;42:1081–92.
18. Ono Y, Davalos Herrera DA, Woodmass JM, Lemmex DB, Carroll MJ, Yamashita S, et al. Long-term outcomes following isolated arthroscopic Bankart repair: a 9- to 12-year follow-up. JSES Open Access. 2019;3:189–93.
19. Owens BD, Dawson L, Burks R, Cameron KL. Incidence of shoulder dislocation in the United States military: demographic considerations from a high-risk population. J Bone Joint Surg Am. 2009;91:791–6.
20. Paladini P, Merolla G, De Santis E, Campi F, Porcellini G. Long-term subscapularis strength assessment after Bristow-Latarjet procedure: isometric study. J Shoulder Elbow Surg. 2012;21:42–7.
21. Provencher MT, Frank RM, Golijanin P, Gross D, Cole BJ, Verma NN, et al. Distal Tibia Allograft Glenoid Reconstruction in Recurrent Anterior Shoulder Instability: Clinical and Radiographic Outcomes. Arthroscopy. 2017;33:891–7.
22. Saper MG, Courson J, Milchteim C, Plummer H, Andrews JR, Ostrander RV 3rd (2021) Successful Outcomes and Return to Sport After Arthroscopic Bankart Repair in National Collegiate Athletic Association and National Football League Football Players. Clin J Sport Med;10.1097/JSM.0000000000000962.
23. Scheibel M, Kraus N, Diederichs G, Haas NP. Arthroscopic reconstruction of chronic anteroinferior glenoid defect using an autologous tricortical iliac crest bone grafting technique. Arch Orthop Trauma Surg. 2008;128:1295–300.
24. Scranton PE Jr, Frey CC, Feder KS. Outcome of osteochondral autograft transplantation for type-V cystic osteochondral lesions of the talus. J Bone Joint Surg Br. 2006;88:614–9.
25. Seow D, Shimozono Y, Gianakos AL, Chiarello E, Mercer N, Hurley ET, et al. Autologous osteochondral transplantation for osteochondral lesions of the talus: high rate of return to play in the athletic population. Knee Surg Sports Traumatol Arthrosc. 2021;29:1554–61.
26. Shaha JS, Cook JB, Song DJ, Rowles DJ, Bottoni CR, Shaha SH, et al. Redefining "Critical" Bone Loss in Shoulder Instability: Functional Outcomes Worsen With "Subcritical" Bone Loss. Am J Sports Med. 2015;43:1719–25.
27. Shimozono Y, Hurley ET, Myerson CL, Kennedy JG. Good clinical and functional outcomes at mid-term following autologous osteochondral transplantation for osteochondral lesions of the talus. Knee Surg Sports Traumatol

Arthrosc. 2018;26:3055–62.
28. Shin SJ, Kim RG, Jeon YS, Kwon TH. Critical Value of Anterior Glenoid Bone Loss That Leads to Recurrent Glenohumeral Instability After Arthroscopic Bankart Repair. Am J Sports Med. 2017;45:1975–81.
29. Sugaya H, Moriishi J, Dohi M, Kon Y, Tsuchiya A. Glenoid rim morphology in recurrent anterior glenohumeral instability. J Bone Joint Surg Am. 2003;85:878–84.
30. Taverna E, D'Ambrosi R, Perfetti C, Garavaglia G. Arthroscopic bone graft procedure for anterior inferior glenohumeral instability. Arthrosc Tech. 2014;3:e653–60.
31. Wilk KE, Arrigo CA, Andrews JR. Current concepts: the stabilizing structures of the glenohumeral joint. J Orthop Sports Phys Ther. 1997;25:364–79.
32. Yamamoto N, Itoi E, Abe H, Kikuchi K, Seki N, Minagawa H, et al. Effect of an anterior glenoid defect on anterior shoulder stability: a cadaveric study. Am J Sports Med. 2009;37:949–54.
33. Zhao J, Huangfu X, Yang X, Xie G, Xu C. Arthroscopic glenoid bone grafting with nonrigid fixation for anterior shoulder instability: 52 patients with 2- to 5-year follow-up. Am J Sports Med. 2014;42:831–9.

Figures

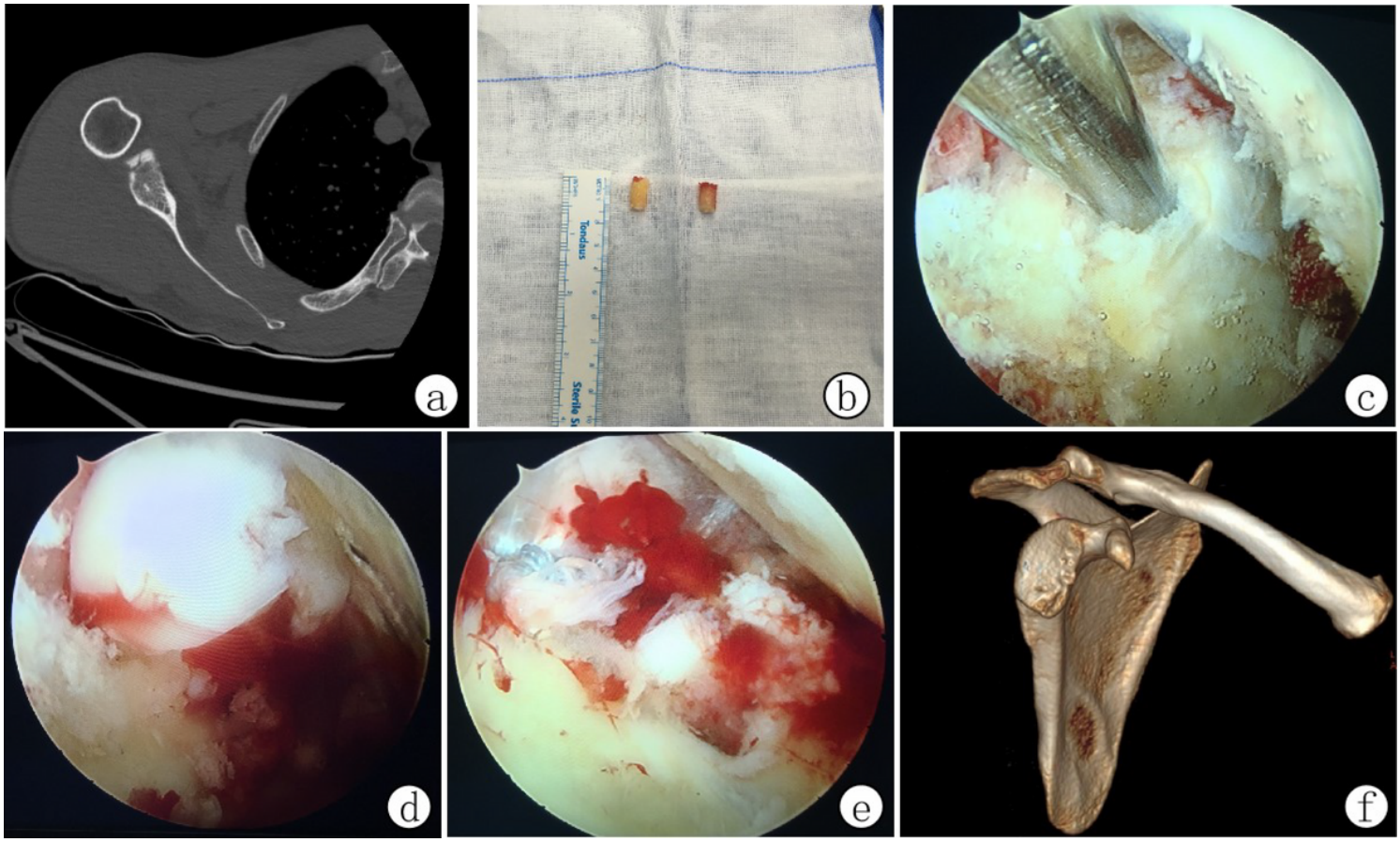

Figure 1

Male, 17 years old, recurrent anterior shoulder dislocation. a. Preoperative CT bone window suggested anterior inferior avulsion fracture of the shoulder glenoid with bone defect. b. Preparation of osteochondral column (6cm*15mm) in the non-weight-bearing area of the knee joint with OATS retriever. c. Preparation of bone tunnel at 5 o'clock position under

the microscope. d. Implantation of osteochondral column into the bone tunnel under the microscope. e. Suture of glenoid lip under the microscope. f. Shoulder glenoid 1 year after surgery 3D-CT.

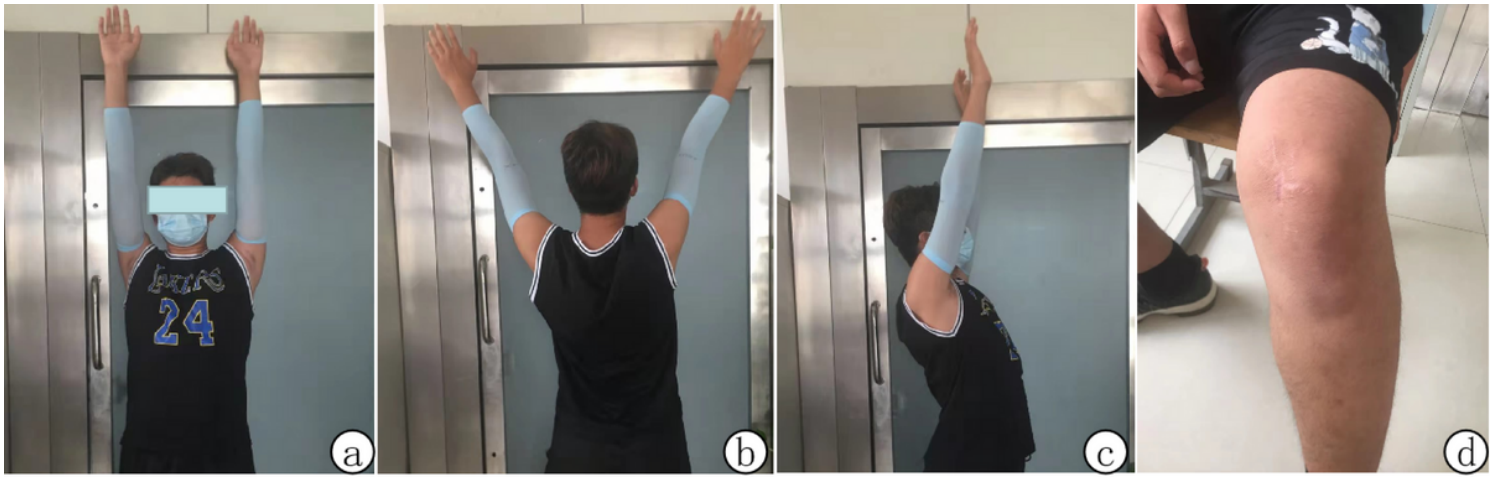

Figure 2

a, b, c. The patient had good mobility of the shoulder joint on the operated side 1 year after recovery, with no significant difference from the mobility of the healthy side. d. The knee joint mobility in the left cartilage column donor area was good 1 year after surgery, with no pain or other discomfort.