The Clinical Manifestation of Straight Back Syndrome in Echocardiogram Performance

Wanqian Yu
Nanchang University Second Affiliated Hospital https://orcid.org/0000-0002-7312-3998
Hongzhou Zhang
Nanchang University Second Affiliated Hospital
Pingping Yang
Nanchang University Second Affiliated Hospital
Lujin Gan
Nanchang University Second Affiliated Hospital
Chenxi Wang
Nanchang University Second Affiliated Hospital
Dan Zhu
Nanchang University Second Affiliated Hospital
Xiongda Yao
Nanchang University Second Affiliated Hospital
Yuanbin Zhao
Nanchang University Second Affiliated Hospital
Tao Wu
Nanchang University Second Affiliated Hospital
Yanna Liu
Nanchang University Second Affiliated Hospital
Qinghua Wu (ncwqh@163.com)
The Second affiliated Hospital of Nanchang University https://orcid.org/0000-0001-8690-2803

Original investigation

Keywords: Straight back syndrome, clinical manifestations, echocardiography

Posted Date: September 27th, 2021

DOI: https://doi.org/10.21203/rs.3.rs-885698/v1

Abstract

Background: There were no studies on the mechanism of clinical manifestations of straight back syndrome. Our aim was to explore the mechanism of clinical symptoms of straight back syndrome.

Methods: From February 2018 to February 2021, we included 4 patients (3 males and 1 female) with straight back syndrome as the experimental group, and 4 normal people matched with sex and BMI as the normal control group. Basic information of patients, laboratory examination, echocardiography in supine and standing position, chest film in positive and lateral position, basic information of control group and echocardiography in supine and standing position were collected. The differences of clinical data between the two groups were compared and analyzed.

Results: There were significant differences in left ventricular outflow tract diameter, right ventricular outflow tract diameter and right ventricular outflow tract velocity in the experimental group (their P values were 0.035, 0.011 and 0.015, respectively), but there was no significant difference in left ventricular outflow tract velocity in the standing and supine position (P=0.638). The left ventricular outflow tract diameter, the right ventricular outflow tract diameter and the right ventricular outflow tract velocity in the experimental group were significantly different (P<0.05). The internal diameters of left ventricular outflow tract in upright position, supine position, right ventricular outflow tract, supine position, right ventricular outflow tract were20.50±1.91mm, 18.75±0.96mm;10.00±6.68mm, 15.45±6.06mm;124.25±40.29cm/s and 91.00±28.93cm/s, respectively, in standing position, recumbent position, right ventricular outflow tract, right ventricular outflow tract, supine position, right ventricular outflow tract, supine position, supine position. The velocity of left ventricular outflow tract in upright position was 82.50±2.01 cm/s, and that in supine position was 83.25±2.06 cm/s. There was no significant difference in left ventricular outflow tract velocity in standing and supine position, which may be related to the compression of right ventricular outflow tract.

Conclusions: In this study, we got the clinical manifestations of direct-back syndrome patients through comparison of straight back syndrome.

Introduction

Due to the congenital abnormal development of the thoracic vertebrae and the lack of physiological curvature, straight back syndrome leads to the shortening of the anterior and posterior diameter of the chest, the compression or displacement of the heart and large vessels and a series of clinical syndromes similar to organic heart disease. However, there are no studies on the mechanism of clinical manifestations of straight back syndrome. This study mainly discussed the mechanism of clinical manifestations in patients with straight back syndrome.

Materials And Methods

Material

From February 2018 to February 2021, we studied four patients-three men and one woman. Each patient had at least one standard 12-lead ECG, and all subjects received echocardiography. Each patient has one or more sets of positive and lateral chest radiographs (**Figure 1**). Echocardiographic evaluation included left ventricular outflow tract diameter in supine position, left ventricular outflow tract velocity in supine position, right ventricular outflow tract diameter in supine position and right ventricular outflow tract velocity in supine position. We adopted the following methods: 1. Collect 4 such patients as the experimental group, obtain the case data, sign the relevant informed consent form, and select 4 normal people with matched age, sex and BMI as the control group, and also sign the relevant informed consent form. 2. Collect the basic information of the patients, the electrogram of the laboratory examination, the color Doppler ultrasound of the recumbent standing heart, the chest film of the anterior and lateral position, collect the basic information of the control group, and the color Doppler ultrasound of the recumbent standing heart. The results of supine echocardiography and orthostatic echocardiography of all subjects were collected, and the results of supine and standing echocardiography of the same subjects were compared and statistically analyzed.

Statistical analysis:

Discrete variables are reported as counts and percentages. Continuous variables in accordance with normal distribution were expressed as mean ±standard deviation. Single factor analysis of variance was used for inter-group comparison, and the least significant difference method was used for intra-group comparison. The classification variable is expressed as an example (%), and the chi-square or Fisher exact test is applied. All statistical analyses were performed using SPSS software, version 23.0. P 0.05 indicated statistical significance.

Results

In the 4 experimental groups included in this study, 3 male patients had clinical manifestations of 2nd-3rd intercostal murmur at the left edge of the sternum and grade 3 systolic ejection murmur at the left edge of the sternum. One female presented with palpitation, as shown in Table 2. The physiological curvature of the spine and thoracic vertebrae disappeared in both positive and lateral chest DR (Figure **1**). The age was 22.50 ±1.30 years old, and the systolic blood pressure difference in standing and recumbent position was 4.00 ±9.93 mmHg. The difference of diastolic blood pressure, heart rate and BMI in standing and lying position were 18.00 ±17.96 and 17.91 ±2.47 kg/m², respectively. See Table

There were 4 normal controls, whose age was 25.50±1.00 years old. The difference of systolic blood pressure, diastolic blood pressure and heart rate in standing and supine position was (7.00±2.58), (5.50±2.52) and (3.50±3.00), respectively, and that in standing and supine position was (25.50±1.00) years, 7.00±2.58mmHg and 3.50±3.00, respectively. BMI was 17.67±2.38 kg/m ². We found that there was a difference in age between the test group and the control group (P<0.01), but there was no significant difference in gender (P=1.000), baseline systolic blood pressure difference in sitting position (P=0.595), baseline diastolic blood pressure difference in sitting position (P=0.708), baseline heart rate

difference in sitting position (P=0.162), and BMI (P=0.893). Among them, the average value and standard deviation of baseline heart rate difference in sitting position in the test group were significantly larger than those in the control group.

There were significant differences in left ventricular outflow tract diameter, right ventricular outflow tract diameter and right ventricular outflow tract velocity in the experimental group (their P values were 0.035, 0.011 and 0.015, respectively), but there was no significant difference in left ventricular outflow tract velocity in the standing and supine position (P=0.638). The left ventricular outflow tract diameter, the right ventricular outflow tract diameter and the right ventricular outflow tract velocity in the experimental group were significantly different (P<0.05). The internal diameters of left ventricular outflow tract in upright position, supine position, right ventricular outflow tract, supine position, right ventricular outflow tract were 20.50±1.91 mm, 18.75±0.96mm;10.00±6.68mm, 15.45±6.06mm; 124.25±40.29cm/s and 91.00±28.93cm/s, respectively, in standing position, recumbent position, right ventricular outflow tract, right ventricular outflow tract, supine position, right ventricular outflow tract, supine position, supine position. The velocity of left ventricular outflow tract in upright position was 82.50±2.01 cm/s, and that in supine position was 83.25±2.06 cm/s. There was no significant difference in left ventricular outflow tract velocity in standing and supine position, which may be related to the compression of right ventricular outflow tract.

By comparing left ventricular outflow tract diameter difference, right ventricular outflow tract diameter difference, left ventricular outflow tract velocity difference and right ventricular outflow tract velocity difference between the experimental group and the control group, we found that there were significant differences in the right ventricular outflow tract inner diameter difference and the right ventricular outflow tract velocity difference between the experimental group and the control group (their P values were 0.012 and 0.003, respectively). This further indicates that the compression of the right ventricle is more significant in patients with straight back syndrome than in normal subjects.

Discussion

Straight back syndrome was first reported by Rawling in 1960. It is rarely seen clinically, and it usually occurs in young, thin individuals. At present, the etiology of straight back syndrome is not clear, which may be mainly related to the anatomical structure of human chest, and it is easy to be misdiagnosed as organic heart disease, of which atrial septal defect is the most common. At present, the reports on straight back syndrome have not discussed the mechanism of its symptoms. In this study, the mechanism of straight back syndrome symptoms was discussed through the results of lying and standing blood pressure and color Doppler echocardiography, and normal people matched with sex and BMI were included as controls.

In this study, we found that the patients with straight back syndrome were mainly compressed by the right ventricle, and the sitting position oppressed the right ventricle more obviously. the second intercostal heart complex at the left edge of the sternum could be heard during auscultation in 3 male patients and

palpitation in 1 female patient. There was no obvious abnormality in their laboratory examination, only that the chest radiographs lost the normal posterior curvature of the thoracic vertebrae (**Figure 1**). These findings suggest that the pathogenesis of straight back syndrome is caused by the reduction of the anterior and posterior diameter of the chest, which oppresses the heart, and its clinical manifestations are different due to different parts of the heart. Heart murmur occurs when it compresses the right ventricular outflow tract, and palpitations occur when it presses the left ventricular outflow tract.

Previous studies have suggested that the mechanism of murmur in patients with straight back syndrome is, on the one hand, due to a decrease in deep inhalation and an increase in deep exhalation [4]. On the other hand, it may be related to the mechanism of the murmur that the spine and sternum lose the normal physiological Radian so that the heart is close to the sternum, the right ventricular outflow tract is squeezed and the aortic root is squeezed. Turbulence or vibration occurs when blood passes through the squeezed site [5], or related to the dislocation of the main pulmonary artery and the murmur is a functional murmur due to increased valvular flow, high output, tachycardia, increased venous reflux, or decreased systemic vascular resistance [6], usually confined to the base [7, 8, 9]. However, our study shows that patients with straight back syndrome oppress both the right ventricle and the left ventricle, mainly the right ventricle.

The results of echocardiography showed that the inner diameter of right ventricular outflow tract in upright position was 10.00 ±6.68mm, while that in supine position was 15.45 ±6.06mm. There was a significant difference in the difference of right ventricular outflow tract diameter in upright position P= 0.011, indicating that the right ventricular compression was more obvious in upright position, which was more consistent with the murmur in sitting position of the 3 male patients we observed. Combined with the internal diameter of left ventricular outflow tract in upright position 20.50 ±1.91 mm, and in supine position 18.75 ±0.96 mm, the difference of internal diameter of left ventricular outflow tract in supine position was significantly different P=0.035 the left ventricular outflow tract of patients on the surface was also oppressed, while the female patients we observed only showed palpitation without cardiac murmur, which may be related to the fact that her right ventricle was not compressed obviously and mainly oppressed the left ventricle. According to the anterior and lateral X-ray films, it is known that the most significant and consistent X-ray manifestation of straight back syndrome is the loss of normal kyphosis of the thoracic vertebrae seen on lateral chest films **Figure 1**. Compared with the normal chest, this change in thoracic shape is obvious, which is also the reason for the narrow distance between the spine and the sternum [10]. In addition, patients with straight back syndrome can cause cardiac compression due to the decrease of chest volume, such as acute myocardial infarction [11], chest tightness, palpitation [12], tachycardia and so on. ECG can show left axis deviation and incomplete right bundle branch block [8].

Limitations

Our study has the following limitations. 1. Our analysis is a study of a relatively small sample size. We can't rule out the possibility that after enlarging the sample, we will find that it is inconsistent with the

current results. 2. There is no genetic exploration of the patient. 3. No intervention-related follow-up results were performed. Prospect: for young patients in the future, we can do positive and lateral chest films directly through physical examination to exclude the disease.

Conclusion

In this study, by comparing the changes of echocardiography in patients with straight back syndrome in standing and recumbent position, we concluded that the clinical manifestations of patients with straight back syndrome were related to the site of cardiac compression.

Declarations

Acknowledgements

The author thanks the teacher of the Imaging Department of the second affiliated Hospital of Nanchang University.

Authors' contributions

Wanqian Yu and Hongzhou Zhang reviewed the articles and wrote the manuscript. Lujin Gan, Pingping Yang, Chenxi Wang and Yuanbin Zhao were responsible for the statistical analysis. Tao Wu and Dan Zhu provided editing assistance, Yanna Liu and Qinghua Wu designed and revised the manuscript. All authors reviewed and agreed on this information before submission.

Funding

This work was supported by the National Natural Science Foundation of China (no. 81860068).

Availability of data and materials

The data used to support the findings of this study are available from the corresponding author upon reasonable request.

Ethics approval and consent to participate

This study was also approved by the Institutional Review Board of the Second affiliated Hospital of Nanchang University, who supervised the study in accordance with the tenets of the Declaration of Helsinki (1975) and its later amendment (2013).

Consent for publication

Not applicable.

Competing interests

The authors declare no conflict of interest.

References

1. Rawlings MS. The "straight back" syndrome, a new cause of pseudoheart disease. Am J Cardiol. 1960 Mar; 5:333-8. doi: 10.1016/0002-9149(60)90080-1. PMID: 14436592.
2. Esser SM, Monroe MH, Littmann L. Straight back syndrome. Eur Heart J. 2009 Jul;30(14):1752. doi: 10.1093/eurheartj/ehp197. PMID: 19454576.
3. Deviggiano A, Carrascosa P, Vallejos J, Bellia-Munzon G, Vina N, Rodríguez-Granillo GA, Martinez-Ferro M. Relationship between cardiac MR compression classification and CT chest wall indexes in patients with pectus excavatum. J Pediatr Surg. 2018 Nov;53(11):2294–8. doi: 10.1016/j.jpedsurg.2018.05.015. Epub 2018 May 23. PMID: 29907314.
4. Matsumoto Y, Nitta M, Nakashima R, Matsumoto K, Sugano T, Ishigami T, Ishikawa T, Tamura K, Kimura K. A mechanism of a cardiac murmur with respiratory variation in a patient with straight back syndrome. J Cardiol Cases. 2020 Aug 6;22(5):230–233. doi: 10.1016/j.jccase.2020.07.008. PMID: 33133316; PMCID: PMC7588483.
5. Ansari A. M-mode echocardiography in supine and standing position in control subjects and patients with auscultatory evidence of mitral valve prolapse but negative supine echocardiography: does sensitivity improve? Clin Cardiol. 1985 Nov;8(11):591-6. doi: 10.1002/clc.4960081108. PMID: 4064383.
6. Warriner D, Michaels J, Morris PD. Cardiac auscultation: normal and abnormal. Br J Hosp Med (Lond). 2019 Feb 2;80(2):C28-C31. doi: 10.12968/hmed.2019.80.2.C28. PMID: 30747003.
7. Matsuo S, Yoshioka M, Yano K, Hashiba K. Straight back syndrome. Clinical and hemodynamic study of 9 cases. Am Heart J. 1973 Dec;86(6):828 – 34. doi: 10.1016/0002-8703(73)90288-3. PMID: 4757794.
8. Soleti P, Wilson B, Vijayakumar AR, Chakravarthi PI, Reddy CG. An interesting case of straight back syndrome and review of the literature. Asian Cardiovasc Thorac Ann. 2016 Jan;24(1):63–5. doi: 10.1177/0218492314539335. Epub 2014 Jun 6. PMID: 24906631.
9. Hasegawa K, Takaya T, Mori S, Ito T, Fujiwara S, Nishii T, K Kono A, Shimoura H, Tanaka H, Hirata KI. Compression of the Right Ventricular Outflow Tract due to Straight Back Syndrome Clarified by Low-dose Dual-source Computed Tomography. Intern Med. 2016;55(22):3279–83. doi: 10.2169/internalmedicine.55.7193. Epub 2016 Nov 15. PMID: 27853069; PMCID: PMC5173494.
10. Twigg HL, De Leon A, Perloff JK, Maid M. The straight-back syndrome: radiographic manifestations. Radiology. 1967 Feb;88(2):274-7. doi: 10.1148/88.2.274. PMID: 6016928.
11. Wang JY, Chen H, Su X. Straight back syndrome manifesting as acute myocardial infarction. Am J Emerg Med. 2016 Sep;34(9):1913.e1-3. doi: 10.1016/j.ajem.2016.02.022. Epub 2016 Feb 12. PMID: 26947366.

12. Almanfi A, Patel SY, Garcia J, Cheong BY. Straight Back Syndrome Masquerading as a Mass, with Near-Syncope. Tex Heart Inst J. 2016 Apr 1;43(2):197-8. doi: 10.14503/THIJ-14-4537. PMID: 27127446; PMCID: PMC4845590.

Tables

Table 1. The manifestations of body, chest X-ray and heart sound in 4 patients with straight back syndrome

Patient	Age and sex	Straight back	Syst.mur	Chest x-ray	Palpitate
1	22□M	+	+	+	-
2	24□F	+	-	+	+
3	21□M	+	+	+	-
4	23□M	+	+	+	-

Abbreviations□M=male□F=female, Syst.mur.=systolic murmur at the left edge of the sternum 2-3.

Table 2. General data of experiment group and control group

	experiment group	control group	P
Age□year□	22.50±1.30	25.50±1.00	0.011
sex□man□	3□75%□	3□75%□	1.000
Baseline systolic blood pressure difference in standing and supine position (mmHg)	4.00±9.93	7.00±2.58	0.595
Baseline diastolic blood pressure difference in upright and supine position (mmHg)	6.50±4.43	5.50±2.52	0.708
Baseline heart rate difference in standing and recumbent position (times / min)	18.00±17.96	3.50±3.00	0.162
BMI (kg/m²)	17.91±2.47	17.67±2.38	0.893

Table 3. Comparison of echocardiographic indexes between standing position and supine position in patients with straight back syndrome

	standing position	supine position	Difference value	p
Left ventricular outflow tract diameter (mm)	20.50±1.91	18.75±0.96	1.75±0.96	0.035
Right ventricular outflow tract diameter (mm)	10.00±6.68	15.45±6.06	-5.45±1.90	0.011
Left ventricular outflow tract velocity (cm/s)	82.50±2.01	83.25±2.06	-0.75±2.87	0.638
Right ventricular outflow tract velocity (cm/s)	124.25±40.29	91.00±28.93	33.25±13.05	0.015

Table 4. Comparison of echocardiographic indexes between experiment group and control group

	experiment group	control group	p
difference of left ventricular outflow tract diameter	1.75±0.96	-0.25±1.50	0.066
difference of inner diameter of right ventricular outflow tract	-5.45±1.90	-0.25±2.22	0.012
Left ventricular outflow tract velocity difference	-0.75±2.87	-0.25±2.87	0.814
Velocity difference of right ventricular outflow tract	33.25±13.05	-1.75±6.90	0.003

Figures

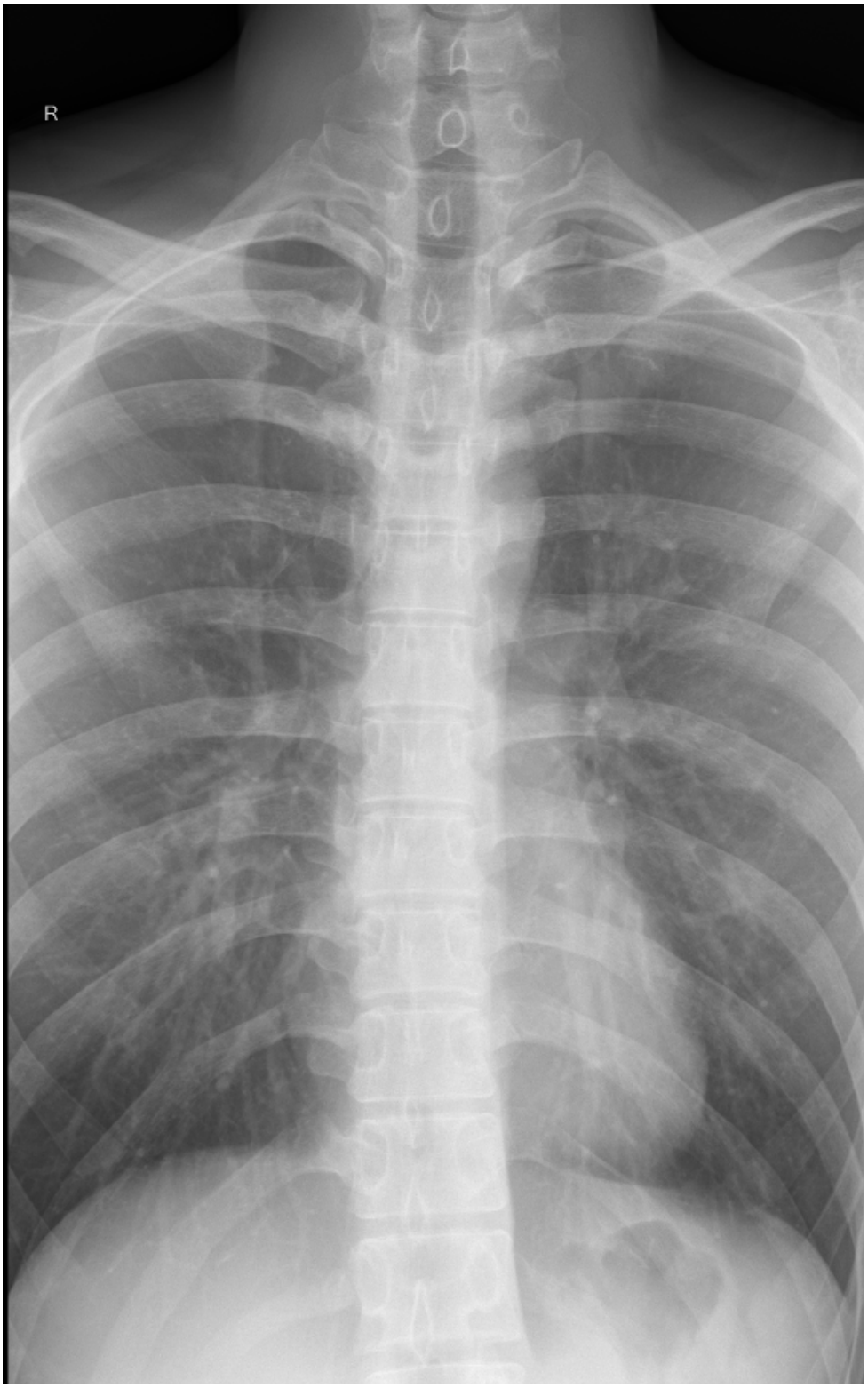

Figure 1

Anteroposterior view of the chest x-ray in Case 1. Lateral view shows a straight dorsal spine and narrow anteroposterior diameter.