Lateral approach for scaphoid excision and capitolunate arthrodesis in the treatment of scapholunate advanced collapse and scaphoid nonunion advanced collapse wrists

Hui-Kuang Huang
Ditmanson Medical Foundation Chiayi Christian Hospital
Yi-Chao Huang
Taipei Veterans General Hospital
Chin-Hsien Wu
E-Da Hospital, I–Shou University
Cheng-Yu Yin
Taipei Veterans General Hospital
Jung-Pan Wang (jpwang@vghtpe.gov.tw)
Taipei Veterans General Hospital

Research Article

Keywords: Arthrodesis, Capitolunate, Partial wrist fusion, Scapho-lunate advanced collapse, Scaphoid nonunion advanced collapse

Posted Date: September 20th, 2021

DOI: https://doi.org/10.21203/rs.3.rs-886215/v1

Abstract

Background

Four-corner arthrodesis (4-CA) is an effective treatment for scapholunate advanced collapse (SLAC) and scaphoid nonunion advanced collapse (SNAC). Capitolunate arthrodesis is an alternative option that limits intercarpal fusion. We propose a lateral approach using a small incision over the scaphoid anatomic snuffbox, which could be a straightforward method for performing scaphoid excision and capitolunate arthrodesis. This approach would be beneficial for shortening the operative time, facilitating bone healing, and improving wrist motion.

Methods

Between 2016 and 2020, eight patients were enrolled retrospectively and underwent the lateral approach for scaphoid excision and capitolunate arthrodesis. We presented the radiographic outcomes, including fusion status, capitolunate angle, and carpal height ratio. The functional outcomes of wrist range of motion, grip strength, pain, Quick Disabilities of the Arm, Shoulder, and Hand (QuickDASH) score, and Mayo wrist score were evaluated.

Results

Fusion could be achieved, without complications, in all eight patients, and the mean follow-up period was 22.4 months (12–38 months). Five operations were completed within 1 h and 30 min. Postoperatively, the mean capitolunate angle and carpal height ratio improved from 19.6^{o} to 2.4^{o} and 0.44–0.51%, respectively. At the final follow-up, the average flexion-extension arc was 76.3^{o}, visual analogue scale for pain was 0.9, QuickDASH score was 26.4, and Mayo wrist score was 72.5.

Conclusions

The lateral approach for scaphoid excision and capitoluante arthrodesis in treating SLAC and SNAC could have several advantages, including easy performance since it is similar to the open method and the lack of need for dorsal wrist opening and closure, which may preserve surrounding circulation, avoid the formation of a dorsal scar, and mimic the advantages of arthroscopic treatment.

Background

The 4-corner arthrodesis (4-CA), a motion-preserving salvage treatment, was first described by Waton and Ballet.[1] It is mainly indicated for the treatment of scapholunate advanced collapse (SLAC) or scaphoid nonunion advanced collapse (SNAC), as it involves the degeneration of the capitate head. 4-CA combined with scaphoid excision has been reported to have long-term reliability.[2, 3] However, limited intercarpal arthrodesis, such as capitolunate arthrodesis, has been proposed to simplify arthrodesis procedures and preserve intercarpal articulations.[4, 5]

In the open method for partial wrist arthrodesis, the dorsal approach is commonly used. The disadvantage of the dorsal open approach mainly includes impaired dorsal circulation due to the peeling off of the dorsal capsule from the carpal bones, as well as compromised wrist motion due to dorsal scarring. In minimally invasive surgery using arthroscopic partial wrist arthrodesis, compromised circulation and problems involving scar formation can be improved. However, it is a much more technically demanding and time-consuming procedure.

We propose a lateral approach with a small incision over the scaphoid anatomic snuffbox, which is a very straightforward method for scaphoid excision and capitolunate arthrodesis. Through this approach, dorsal capsule stripping and dorsal scarring can be avoided. Which would in turn be beneficial for shortening the operative time, facilitating bone healing, and improving wrist motion.

Methods

This was a retrospective study of a consecutive series of patients who underwent capitolunate arthrodesis with scaphoidectomy through the lateral approach between 2016 and 2020.

With the same indication as of 4-CA, patients with stage II or III SLAC or SNAC with midcarpal arthrosis, but radiolunate joint preservation, can undergo capitolunate arthrodesis using the lateral approach. Patients with immunological diseases, such as rheumatoid arthritis, are more suitable for total wrist fusion as the generalised carpal joints would be involved. Patients with severe peripheral vascular occlusive problems which compromise the hand circulation should be avoided because the surgical procedure takes place in close approximation to the radial artery and, therefore, could cause stress to the artery during the opening of the wound for surgery.

In our practice, computed tomography is routinely performed before surgery involving bony structures and alignment evaluation. Magnetic resonance imaging is not a routine procedure and is only performed when the cartilage or ligamentous conditions need to be further verified.

Surgical procedure

Under tourniquet control, a longitudinal or curved incision of approximately 3 to 4 cm was made over the area of the anatomical snuffbox, between the extensor pollicis brevis and extensor pollicis longus. Care should be taken to protect the superficial branch of the radial nerve and the radial artery, which can be found across this operative field. The division of the wrist capsule, which is placed longitudinally underneath, and the scaphoid are then revealed.

After visualisation of the scaphoid, it could be removed, as a whole, with the assistance of a carpal stick or K-wire, or it could be cut into pieces to assist the removal process. Scaphoid excision was followed by radial styloidectomy, which was performed from the scaphoid space under fluoroscopy. If the radial styloid is difficult to remove, the release of part of the corresponding first extensor retinaculum would be helpful.

The arthritic condition of the capitolunate joint could be inspected through the wound. The degenerative articular surface and the subchondral sclerotic bone layer were removed for the preparation of capitolunate arthrodesis. It is important to not remove too much of the subchondral bone because carpal height restoration could then be difficult.

Before fusion of the capitate and lunate, it is important to correct the dorsal intercalated segment instability (DISI). If it is difficult to correct the DISI while simultaneously adjusting the capitate-lunate alignment, the DISI could be corrected first by flexing the patient's wrist to make the lunate position neutral. Then, the lunate position is maintained by transfixing a 1.0-mm or 1.25-mm K-wire from the dorsal cortex of the distal radius to the lunate, with a small incision for protecting the extensor tendons using mosquito forceps.

After correction of the DISI, the capitate-lunate alignment needs to be corrected by translating the capitate ulnarly to sit completely on top of the lunate. A 1.6-mm K-wire is preferred for pushing the capitate on its side from the lateral wound. The capitate was pushed by the K-wire ulnarly, and the capitate-lunate alignment was checked under fluoroscopy to ensure the capitate sitting completely on top of the lunate. Traction of the fingers distally could help increase carpal height. The K-wire was then aimed at the triquetrum and drilled foreword to transfix the capitate-triquetrum. After capitotriquetrum transfixation (Figs. 1 and 2), the relationship between the proximal and distal carpal row could be maintained.

Following this, the bone graft could be stuffed into the capitoluante junction for arthrodesis. The resected scaphoid can be used as a bone graft. If the scaphoid is not sufficient to afford the bone graft, more cancellous bone grafts can be harvested from the bone window of radial styloidectomy or other bone substitutes can also be an option.

During this procedure involving the lateral approach, we suggest that capitoluanate screw fixation should be performed in a retrograde manner, as the entry points are easier to access as compared to those achieved using antegrade screw fixation.

With a small longitudinal incision of approximately 1 to 1.5 cm over the capitometacarpal joint, the extensor tendons were identified and protected. Under fluoroscopy, two guide pins were inserted from the distal-dorsal corner of the capitate retrogradely to the lunate. Two K-wires of larger diameters (1.25 mm or 1.6 mm) could be used; they would be beneficial for direction control or the handling of the capitate while the K-wire(s) was driven into the capitate before the insertion into the lunate. Then, one of the two K-wires having larger diameters was replaced with the guide pin of a headless screw, and the headless screw was fixed thereafter. The second headless screw was set in the same manner (Figs. 1 and 2).

If there is no good entry point for capitoluante fixation, the guide pin(s) could be set to go through the third metacarpal to have a volar entry point of the distal capitate. The endpoint of the headless screw fixation should be located between the middle and anterior halves of the lunate. It is important to ensure sufficient bone purchase by the screws of both the capitate and lunate (Fig. 3).

Postoperative management

After the surgery, the patient was advised a short-arm splint for one month, followed by a removable wrist brace that had to be applied for yet another month. Gentle wrist motion rehabilitation was started after the brace was removed. Strengthening and advanced motion rehabilitation could be started when junctional healing was radiographically confirmed. Weight-bearing work or activities were allowed 3 to 6 months postoperatively depending on the healing condition and functional recovery.

For clinical evaluation of function, wrist range of motion, grip strength, the visual analogue scale (VAS) for pain (where 0 = no pain; 10 = worst pain), the Quick Disabilities of the Arm, Shoulder, and Hand (QuickDASH) questionnaire, and the Mayo wrist score were used as the main evaluations.[6, 7] Radiograph images were taken at every follow-up after postoperative 1 month. The capitolunate angle was measured using the lateral radiographic view, and the carpal height ratio, which was calculated by dividing the carpal height by the length of the third metacarpal, was evaluated using the anteroposterior radiographic view. The radiographic images and functional outcomes were evaluated by two hand surgeons who were not involved in the treatment and follow-up of the patients.

Results

Eight patients (two women, six men) were enrolled in this study. The average age at the time of surgery was 60.0 years (range, 45–80 years) and the follow-up duration was 22.4 months (range, 12–38 months). The dominant hand was involved for four patients. Six patients presented with SLAC and two patients with SNAC.

The clinical outcomes of the patients are presented in Table 1. No additional surgical procedures were required for any of the patients. The operative time for the first three cases was between 1 h 30 min and 2 h 30 min. The latter five cases took less than 1 h 30 min. There were no complications, and all

arthrodesis healed uneventfully. All patients returned to work or routine activities within 6 months after surgery.

Table 1
Patient outcome

Case	Age	Sex	Pathology	side	Follow-Up (mo)	Capitolunate Angle (º) Pre-Op/Post-Op	Carpal Height Ratio Pre-Op/Post-Op	Grip (Kg) Pre-Op / Post-Op	Radio-Ulnar deviation arc (º) Pre-Op / Post-Op	Extension-Flexion arc (º) Pre-Op / Post-Op	Pain (VAS) Pre-Op / Post-Op	QuickDASH Pre-Op / Post-Op	Mayo wrist score Pre-Op / Post-Op
1	76	M	SLAC II	R	13	+ 8 / +2	0.48 / 0.50	23 / 33	45 / 50	80 / 70	5 / 1	54.5 / 31.8	60 / 70
2	80	F	SLAC III	L	30	+ 34 / +4	0.42 / 0.52	8 / 11	40 / 50	100 / 70	6 / 2	79.5 / 36.4	35 / 70
3	57	M	SNAC III	L	38	+ 17 / +5	0.47 / 0.51	21 / 33	35 / 45	50 / 65	7 / 1	54.5 / 25.0	25 / 70
4	62	M	SLAC III	R	35	+ 18 / +3	0.40 / 0.54	18 / 30	35 / 50	50 / 80	7 / 1	47.7 / 31.8	25 / 70
5	52	M	SLAC II	L	16	+ 17 / +3	0.49 / 0.51	31 / 44	55 / 50	110 / 85	5 / 0	40.9 / 18.2	60 / 75
6	45	F	SLAC III	R	20	+ 20 / 0	0.41 / 0.46	13 / 25	50 / 50	90 / 80	6 / 1	61.4 / 27.3	45 / 70
7	60	M	SLAC III	L	12	+ 30 / 0	0.42 / 0.48	21 / 26	40 / 45	75 / 70	5 / 1	43.2 / 18.2	55 / 75
8	48	M	SNAC III	R	15	+ 10 / +2	0.45 / 0.52	35 / 46	45 / 45	80/ 90	6 / 0	59.1 / 22.7	60 / 80
Mean	60.0				22.4	+ 19.6 / +2.4	0.44 / 0.51	21.3 / 31.0	43.1 / 48.1	79.4 / 76.3	5.9 / 0.9	55.1 / 26.4	45.6 / 72.5

Discussion

This lateral approach for scaphoid excision and capitolunate arthrodesis was aimed at facilitating scaphoid removal and capitoluante arthrodesis. Even though it is an open approach, dorsal wrist opening and closure are not required, which may preserve surrounding circulation and avoid the formation of a dorsal scar. Therefore, the advantages of arthroscopic treatment can be mimicked.

4-CA is a reliable long-term procedure for the treatment of SLAC and SNAC wrists. Trail et al. reported the results of 4-CA for 110 patients (116 wrists) from a dorsal approach, with an average follow-up of 9.3 years (range, 3–19 years). The VAS for pain (n = 87) averaged 1.9 (standard deviation = 3.1). Regarding functional outcomes, the average extension/flexion arc (n = 58) was 60° and the median QuickDASH score (n = 87) was 37.4 (standard deviation = 26.3).[8] Traverso et al. reported the results of 4-CA for 12 patients (15 wrists), with an average follow-up of 18 years (range, 11–27). Their results showed that the average extension/flexion arc was 68.6° (0°-96°) and the QuickDASH scores averaged 7.8 (range, 0-32.5).[3] Our results using the lateral approach for capitolunate arthrodesis showed a superior result with the average extension/flexion arc being 76.3º and a comparable result with the average QuickDASH scores being 26.4.

This idea of a lateral approach was derived from peforming arthroscopic capitolunate arthrodesis and scpahoidectomy. As in the arthroscopic approach, scaphoid excision is a time-consuming step. Incorporation of larger-sized arthroscopic burr or direct Rongeur removal from the enlarged portal can be of great help.[9, 10] In addition, the removal of the scaphoid, leaving behind part of the proximal pole, is allowed if the removal of the entire scaphoid is time-consuming.[4, 10] The anatomic snuffbox of the scaphoid indicates that the scaphoid waist is directly underneath the skin. In some cases, when we wanted to save time in removing the scaphoid while performing arthroscopic scaphoid excision and capitoluante arthrodesis of 4-CA, we used an open approach from the anatomical snuffbox to facilitate scaphoid excision. We found that the scaphoid in both the proximal and distal parts could be removed easily using this lateral approach. After the removal of the scaphoid, we found that the capitolunate joint could be visualised. The view of the capitoluante joint from the laterally opened wound can be more convenient compared to the initially aimed arthroscopic portals.

Calandruccio et al. reported that restricting the number of fused carpal joints can lead to less scarring and preserved wrist motion. A shorter operative time could also be achieved.[11] With the compression technique for capitoluante arthrodesis, the union rate can be similar to that of four-corner fusion, and the functional outcomes are even better.[4, 5, 12–14] If surgeons are afraid of the small fusion area with only capitolunate arthrodesis, the failure of healing can be a concern, Wang et al. reported that capitolunate combined with triquetrohamate arthrodesis has good union rates and functional outcomes, with a decrease of only 21% in the mean flexion-extension arc.[15] With our proposed lateral approach method, triquetrohamate fusion, which requires traction for the fingers distally to increase the intercarpal space for articular preparation, can be performed. However, we do not have enough

cases to determine the difference in the outcomes between capitolunate arthrodesis alone or in combination with triquetrohamate arthrodesis using the lateral approach.

For capitolunate arthrodesis with a headless screw, we would prefer to adopt the retrograde approach. This lateral approach would not be suitable for the lunate entry point access for antegrade screw fixation, and we would like to avoid violating the proximal articular surface of the lunate. After scaphoid excision and capitolunate fusion, the load would preferentially transfer to the radiolunate joint.[16] Ferreres et al. and Kitzinger et al. reported that approximately 25–27% incidence of radiolunate joint arthritic changes after either capitolunate or 4-CA, although most were asymptomatic.[13, 17] The injury to the lunate cartilage of the radioluante joint could influence the durability of this joint in the long term.[14, 15, 18]

When performing 4-CA or more limited wrist fusion, the arthroscopic approach is an alternative, which is a minimally invasive procedure. However, arthroscopic management is technically demanding, and the removal of the scaphoid would be a time-consuming step. In addition, realignment of the capitate onto the lunate combined with arthrodesis procedures is not easy. Both of these procedures would be easier to perform using the lateral approach.

With regard to minimally invasive or arthroscopic procedures, there is a learning curve that sometimes hinders surgeons from learning or performing.[10, 19] In our series, the longest recorded operating time using this method was during the first case, which took 2 h 25 min, whereas the shortest recorded time among the later cases was 55 min. No obvious learning curve is needed, and the operative time does not need to be prolonged.

This method of lateral approach may combine the advantages of open and arthroscopic methods. Scaphoid removal, capitoluante realignment, and arthrodesis fixation are as easy as in open procedures. There was no violence to the dorsal capsule as observed during the dorsal open wound approach. In this regard, the lateral approach is similar to the arthroscopic method, which can preserve blood supply to the fused carpal bones, preserve proprioception, and minimise postoperative scarring.[10] The increased speed of bone healing, protection from injury or degeneration, and better postoperative range of motion could be advantages. In addition, there is no need for dorsal repair of the capsule or extensor retinaculum, and the wound is smaller than that in the dorsal open approach, all of which may save operative time.

Conclusions

We propose a lateral open approach for scaphoid excision and capitoluante arthrodesis for the treatment of SLAC and SNAC. The advantages include easy performance, similar to the open method but without the need for dorsal wrist capsule and extensor retinaculum repair. The ability to avoid violence to the dorsal capsule may preserve the surrounding soft tissue and prevent the formation of a dorsal scar. Further investigation to compare open and arthroscopic methods is needed.

Abbreviations

4CA, four-corner arthrodesis; DISI, dorsal intercalated segment instability; QuickDASH, Quick Disabilities of the Arm, Shoulder, and Hand; SLAC, scapholunate advanced collapse; SNAC, scaphoid nonunion advanced collapse; VAS, visual analogue scale

Declarations

Acknowledgements

We thank Fang-Chun Kuo from Ditmanson Medical Foundation Chiayi Christian Hospital for the original artwork in Fig. 1.

Authors' contributions

HKH and JPW performed the operations. HKH and YCH drafted the manuscript. CHW and CYY collected the data and completed the functional evaluations. YCH, CHW, and JPW critically revised the manuscript. All authors have read and approved the manuscript.

Funding

Not applicable.

Availability of data and materials

The datasets used and/or analyzed during the current study are available from the corresponding author upon reasonable request.

Ethics approval and consent to participate

All methods were performed in accordance with the relevant guidelines and regulations. Ethical approval was granted by the Human Research Ethics Committees of Ditmanson Medical Foundation Chiayi Christian Hospital. (No. 2021 (081)). Written informed consent was obtained from individual or guardian participants. **Consent for publication**

Not applicable.

Competing interests

The authors declare that they have no conflict of interests related to this work.

References

1. Watson HK, Ballet FL: The SLAC wrist: scapholunate advanced collapse pattern of degenerative arthritis. J Hand Surg Am. 1984;9(3):358–65.
2. Bain GI, Watts AC: The outcome of scaphoid excision and four-corner arthrodesis for advanced carpal collapse at a minimum of ten years. J Hand Surg Am. 2010;35(5):719–25.
3. Traverso P, Wong A, Wollstein R, Carlson L, Ashmead D, Watson HK: Ten-Year Minimum Follow-Up of 4-Corner Fusion for SLAC and SNAC Wrist. Hand (N Y). 2017;12(6):568–72.
4. Giannikas D, Karageorgos A, Karabasi A, Syggelos S: Capitolunate arthrodesis maintaining carpal height for the treatment of SNAC wrist. J Hand Surg Eur Vol. 2010;35(3):198–201.
5. Goubier JN, Teboul F: Capitolunate arthrodesis with compression screws. Tech Hand Up Extrem Surg. 2007;11(1):24–8.
6. Gummesson C, Ward MM, Atroshi I: The shortened disabilities of the arm, shoulder and hand questionnaire (QuickDASH): validity and reliability based on responses within the full-length DASH. BMC Musculoskelet Disord. 2006, 7:44.
7. Amadio PC, Berquist TH, Smith DK, Ilstrup DM, Cooney WP, 3rd, Linscheid RL: Scaphoid malunion. J Hand Surg Am. 1989;14(4):679–87.
8. Trail IA, Murali R, Stanley JK, Hayton MJ, Talwalkar S, Sreekumar R, Birch A: The long-term outcome of four-corner fusion. J Wrist Surg. 2015;4(2):128–33.
9. Ho PC: Arthroscopic partial wrist fusion. Tech Hand Up Extrem Surg. 2008;12(4):242–65.
10. del Pinal F, Klausmeyer M, Thams C, Moraleda E, Galindo C: Early experience with (dry) arthroscopic 4-corner arthrodesis: from a 4-hour operation to a tourniquet time. J Hand Surg Am. 2012;37(11):2389–99.
11. Calandruccio JH, Gelberman RH, Duncan SF, Goldfarb CA, Pae R, Gramig W: Capitolunate arthrodesis with scaphoid and triquetrum excision. J Hand Surg Am. 2000;25(5):824–32.
12. Delclaux S, Rongieres M, Apredoaei C, Bonnevialle N, Bonnevialle P, Mansat P: [Capitolunate arthrodesis: 12 patients followed-up an average of 10 years]. Chir Main. 2013;32(5):310–6.
13. Ferreres A, Garcia-Elias M, Plaza R: Long-term results of lunocapitate arthrodesis with scaphoid excision for SLAC and SNAC wrists. J Hand Surg Eur Vol. 2009;34(5):603–8.
14. Gaston RG, Greenberg JA, Baltera RM, Mih A, Hastings H: Clinical outcomes of scaphoid and triquetral excision with capitolunate arthrodesis versus scaphoid excision and four-corner arthrodesis. J Hand Surg Am. 2009;34(8):1407–12.
15. Wang ML, Bednar JM: Lunatocapitate and triquetrohamate arthrodeses for degenerative arthritis of the wrist. J Hand Surg Am. 2012;37(6):1136–41.
16. Skie M, Grothaus M, Ciocanel D, Goel V: Scaphoid excision with four-corner fusion: a biomechanical study. Hand (N Y). 2007;2(4):194–8.
17. Kitzinger HB, Low S, Karle B, Lanz U, Krimmer H: [The posttraumatic carpal collapse–long-term results after midcarpal fusion]. Handchir Mikrochir Plast Chir. 2003;35(5):282–7.
18. Ball B, Bergman JW: Scaphoid excision and 4-corner fusion using retrograde headless compression screws. Tech Hand Up Extrem Surg. 2012;16(4):204–9.
19. Vihanto A, Kotkansalo T, Paakkonen M: The Learning Curve and Pitfalls of Arthroscopic Four-Corner Arthrodesis. J Wrist Surg. 2019;8(3):202–8.

Figures

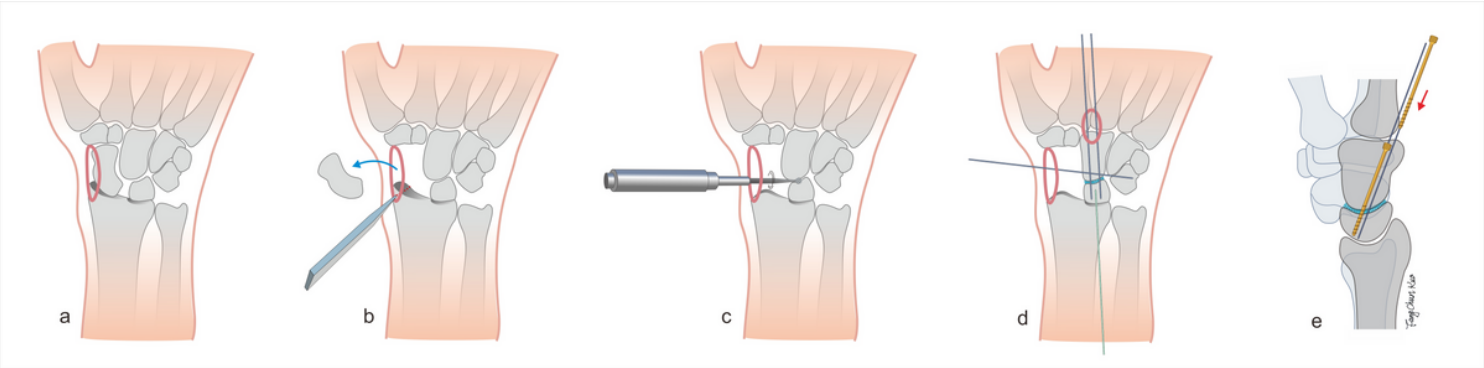

Figure 1

(a) Lateral approach wound over the anatomic snuffbox. (b) Scaphoid excision and radial styloidectomy. (c) Remove the articular surface of the capitate and lunate. (d) Reduce the dorsal intercalated segment instability (DISI) and radiolunate transfixation if needed (light-colored K-wire). Align the capitate

on the lunate and retrogradely set the K-wires from the capitate to the lunate. Fill the bone graft into the capitolunate space. (e) Set the headless screws via the guide pins.

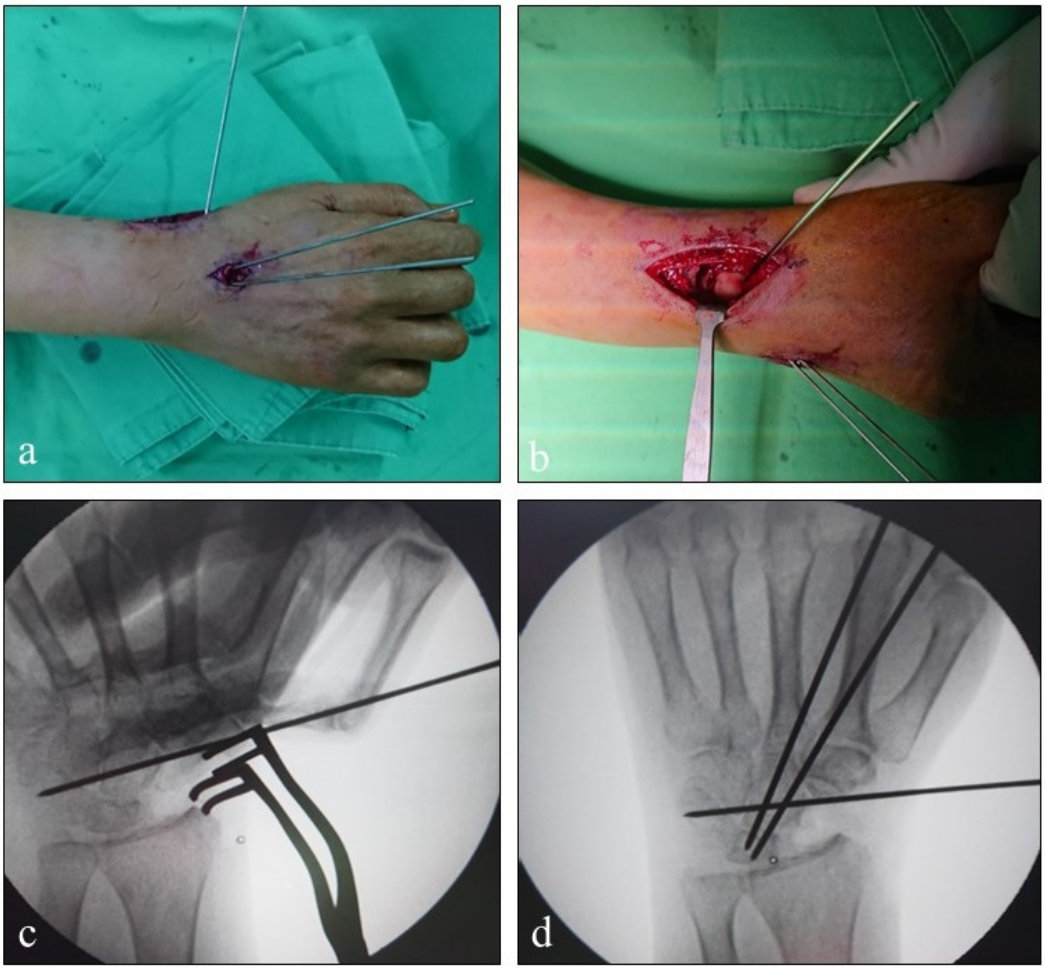

Figure 2

Photographs showing the (a) the lateral approach wound and the dorsal wound for capitolunate arthrodesis. (b) Bone graft was stuffed in the capitolunate junction. (c) Radiographs showing temporary capitate-triquetrum transfixation to maintain the reduced relationship of the capitate and lunate. (d) Transfixatin of the capitate and lunate.

Figure 3

A 80-year-old female. Radiograph showing (a) and (b) stage III SLAC of her left wrist; (c) and (d) 1 month after lateral approach for scaphoid excision and capitolunate arthrodesis.