Safety and feasibility of laparoendoscopic single-site surgery in the management of giant ovarian cysts

Shuzhen Chang
Zhengzhou University First Affiliated Hospital
Wei Zhang
Zhengzhou University First Affiliated Hospital
Linyv Peng
Zhengzhou University First Affiliated Hospital
Haiyan Zhou
Zhengzhou University First Affiliated Hospital
HAN Li-ping (hanliping0825@163.com)
Zhengzhou University First Affiliated Hospital

Research

Keywords: Laparoendoscopic single-site surgery, Giant Ovarian Cysts, LESS

Posted Date: September 21st, 2021

DOI: https://doi.org/10.21203/rs.3.rs-895668/v1

Abstract

Objective

To investigate the safety and feasibility of laparoendoscopic single-site surgery (LESS) in the treatment of giant ovarian cysts.

Methods

A total of 76 patients with giant ovarian cyst (diameter ≥ 10 cm) who received surgical treatment in our hospital from January 2018 to May 2021 were divided into experimental cohort (single-port laparoscopic cohort) (n = 30) and control cohort (traditional laparoscopic cohort) (n = 46).The operation time, intraoperative blood loss, intraoperative cyst fluid spillage rate, application of postoperative analgesic drugs, postoperative first anus exhaust time, incidence rate of perioperative complications, length of postoperative hospital stay and other clinical indicators were summarized and analyzed between the two cohorts.

Results

The LESS cohorts had an earlier onset of age[(27.6 ± 8.4) ,years of age], shorter of operation time [(82.2 ± 16.0)min], less of intraoperative blood loss [(17.5 (10-22.5) ml)] as compared with traditional laparoscopic cohort[(40.9 ± 15.5)years of age, (102.7 ± 26.2)min, (20 (18.7–35))m,P 0.05]. The first postoperative exhaust time,the rate of postoperative analgesic drugs, incidence rate of perioperative complications and postoperative hospital stay in two cohorts were in the similar line.

Conclusion

After adequate evaluation and screening of patients, the size of ovarian cysts cannot be the reason for refusing LESS surgery. It is safe and feasible for clinical promotion in the management of giant ovarian cysts.

Background

Ovarian cysts are a common disease in gynecological diagnostic and therapeutic activities, which can be successfully treated by laparoscopic surgery in most cases. However, for giant ovarian cysts (≥ 10 cm in diameter) several experts still recommend the laparotomy as their first choice [1].Because the large ovarian cyst hampers adequate visualization of pelvic anatomy and limits the movement of laparoscopic equipment, a more important issue is the greater risk of intraoperative cyst rupture, which is likely to lead to dissemination of tumor [2,3].With the rapid development of microsurgical technique and the continuous improvement of patients' requirements for the aesthetics of scars, natural orifice transluminal

endoscopic surgery (NOTES) has emerged. Natural orifice transluminal endoscopic surgery refers to a new endoscopic technique in which endoscopes and surgical instruments are placed through the natural orifice of the human body (including the oral cavity, esophagus, stomach, colorectum, vagina, bladder, etc.) for various diagnostic and therapeutic procedures [4].Both laparoendoscopic single site surgery (LESS) and transvaginal natural orifice transluminal endoscopic surgery (vNOTES) , which are commonly used in gynecology, are developed based on NOTES[5]. In recent years, obstetricians and gynecologists have also continuously explored the use of LESS technique in the treatment of giant ovarian cysts, and have achieved initial results [6-8].This article retrospectively analyzed the clinical data of 76 patients with giant ovarian cysts who underwent LESS (n=30) or traditional laparoscopic surgery (n=46) in our hospital, and analyzed its feasibility and safety, which are reported as follows.

1 Clinical Data

76 cases of giant ovarian cysts treated by LESS or traditional laparoscopy in our hospital from January 2018 to May 2021 were collected. Inclusion criteria: 1. The minimum diameter of ovarian cysts ≥ 10 cm; 2. US, CT or MRI examination showed that ovarian cysts were consistent with benign tumors; 3. History of abdominal surgery less than or equal to 2 times; 4. Tumor markers were normal or increased less than 2 times the normal value. Exclusion criteria : 1. Patients aged ≤ 70 year; 2. Patients with serious complications; 3. Imaging examination suggests that the tumor has the possibility of malignant tendency (such as ascites, enlarged lymph nodes, etc.); 4. Intraoperative exploration shows severe abdominopelvic adhesion; 5. History of severe umbilical deformity or umbilical hernia.

2 Study Methods

2.1 Skin preparation, clean the umbilicus,bowel preparation should be done before operative. Effective cleaning of the umbilicus can effectively avoid intraoperative and postoperative infections. All patients signed the informed consent form and voluntarily requested LESS surgery or traditional laparoscopic surgery.

2.2 Surgical process Experimental cohort : After general anesthesia, the patient was placed in the dorsal lithotomy position and had an indwelling catheter.A 2.5 cm longitudinal vertical incision was made in the umbilicus, the skin and subcutaneous tissue were incised, the peritoneum was opened into the abdominal cavity, and a single-port laparoscopic incision retractor was placed under direct vision. The device consists of three components: introducer, fixed valve, and cannula. After the completion of the device, a CO_2 tube was connected to maintain the pneumoperitoneum pressure at 12 mmHg, and a laparoscopic lens was carefully placed for abdominal exploration. Ovarian cysts, ovaries, peritoneal surface, greater omentum, appendix, abdominopelvic adhesions, and ascites were explored as can as possible. During exploration, should pay attention to gentle movement to avoid puncturing the cyst. After ruling out the surgical contraindications, the removable port cover of the device was removed and extracorporeal ovarian cystectomy was operated. The inner edge of the wound retractor was covered with sterile gauze, the cyst surface was sutured with purse-string suture and then slowly lifted upwards, the tissue scissors

were used to puncturing the central depression of the tissue, and the cyst fluid was aspirated with vacuum suction system, during which also should to exploring whether the cyst was multilocular, and whether the cyst contained solid components. After cyst reduction, the cyst wall was stripped while pulling it out of the abdominal cavity (Picture A). Part of the dissected tissue was taken and sent for frozen pathology and the results were awaited during surgery. If the pathological results suggested that it was benign, ovarian repair was performed, the ovary was sutured into a long strip to facilitate passage through the small abdominal incision. After the ovary was delivered into the pelvis, the single-port laparoscopic port was reset and the abdominal cavity was carefully observed to determine any bleeding spots and other lesions with under laparoscopic lens. The pelvic and abdominal cavity was irrigated with a large amount of normal saline, and the abdominal wall incision was sutured (Picture B).If the patient required adnexectomy or other operations on the basis of preoperative conversation or intraoperative frozen section diagnosis, the completely collapsed ovarian cyst was returned to the abdominal cavity and other surgical procedure was performed.

Control cohort : Surgery was performed under general anesthesia, as in the LESS surgery all patients were in the dorsal lithotomy position and all had an indwelling catheter. A transverse incision of about 12 mm in length was made at the upper edge of the umbilicus or at the appropriate site of the upper abdomen which depended on the size of the cyst, with a trocar was placed in. Before connecting the CO_2 tube, the laparoscopic lens should be placed into this puncture tube to ensure that tube enters the abdominal cavity, thereby avoiding the formation of subcutaneous emphysema. After the formation of pneumoperitoneum, the abdominal cavity, omentum, and peritoneum were checked under Laparoscopic to exclusion surgical contraindications. After that two 5 mm trocars were placed in the avascular area of the left lower abdomen, and 5 mm and 12 mm trocars were placed in the right. Place the disposable surgical specimen extraction bag under laparoscopic monitoring, moved the ovarian cyst into the bag, pull the opening of the bag with atraumatic forceps to give a certain tension. A monopolar electric hook is used to make an incision on the surface of ovarian cyst. At the same time, the aspirator enters the cyst cavity through the incision to suck the cyst fluid. Ovarian cysts were carefully dissected, in this process, whether the cyst cavity is multilocular and whether there is a solid component should also be checked. The remaining ovarian tissue was sutured with absorbable sutures after complete dissection of the ovarian cyst. Tighten the bag, clamp it with atraumatic forceps, remove the 12 mm trocar in the right lower abdomen, and dragged the opening of the bag to the outside of the abdominal cavity through this puncture hole. Ensure that the opening of the collection bag has been completely pulled out of the abdominal cavity, relax the band and carefully take out the specimen with oval forceps. Pull the collection bag while removing the specimen. Finally, the collection bag is also taken out through the puncture hole. After that, check the integrity of the collection bag again. This process is completed under laparoscopic monitoring to observe whether the bag is damaged. It needed to reduce the CO2 pneumoperitoneum pressure to give a elasticity to the abdominal wall, which adds some difficulties to laparoscopic monitoring. Specimens were sent for frozen pathology, if benign, the pelvis was irrigated with normal saline, and after determining the absence of active bleeding, the procedure was ended routinely. If the patient required adnexectomy or other operations on the basis of preoperative conversation or

intraoperative frozen section diagnosis, after the cysts fluid is absorbed, other surgical procedures were performed directly

2.3 Statistical data

Operation-related indicators were recorded, including operation time (min), intraoperative blood loss (ml), sac fluid spillage rate, postoperative analgesic drug application, postoperative first exhaust time (h), and postoperative hospital stay (d). Perioperative complications were recorded, including fever, poor incision healing, incisional hernia, intestinal obstruction, and pelvic inflammatory disease, ect.

2.4 Statistical Methods

SPSS 23.0 software was applied for statistical analysis. Categorical variable data are expressed as frequency (percentage).Continuous variable data are expressed as median (interquartile range [IQR]) or mean ± standard deviation (X ± SD) after verification that the data are normally distributed. Basic information, surgical results, and postoperative pathology were compared between the two cohorts, using the t-test, Fisher's exact test, χ^2 test, or Mann-Whitney U test. $P < 0.05$ was considered as statistically significant.

3 Results

3.1 Basic information of patients The age composition of the patients in the 2 cohorts was statistically significant ($P < 0.05$), and the age of the patients who underwent LESS surgery (27.6 ± 8.4) tended to be younger compared with those who underwent common laparoscopic surgery (40.9 ± 15.5); the body mass index, menstrual status, leading symptoms, ovarian cyst size, preoperative CA125 level and preoperative CA199 level of the patients in the 2 cohorts were not had statistically significant ($P > 0.05$). (Table 1)

Table 1
 Basic Information of Patients

	Experimental cohorts **(n = 30)**	**Control cohorts** **(n = 46)**	***t / Z / χ2***	***P****
Surgical technique	Less	Conventional laparoscope		
Age, years	27.6 ± 8.4	40.9 ± 15.5	-4.276	0.001
Body mass index, kg/m2	22.7 ± 3.9	22.7 ± 3.2	-0.042	0.274
Menopause			0.661	0.416
No	24 (80.0%)	33 (71.7%)		
Yes	6 (20.0%)	13 (28.3%)		
Leading symptoms			1.707	0.749
Abdominal pain	7 (23.3%)	19 (41.3%)		
Urinary retention and fullness	1 (3.3%)	1 (2.2%)		
Vaginal bleeding	3 (10 %)	1 (2.2%)		
Asymptomatic	19 (63.3%)	25 (54.3%)		
Minimum diameter of cyst,mm	158.1 ± 40.7	145.1 ± 40.7	1.609	0.051
CA125, IU/ml	16.5 (11.4–26.3)	14.2 (10.5–33.8)	-0.133	0.894
CA19-9, IU/ml	11.7 (7.1–21.5)	13.2 (7.7–24.3)	-0.404	0.686
*All reported p values were two-sided.				

3.2 Surgery-related data The differences in the operation time, intraoperative blood loss and intracystic fluid spillage between the two cohorts had statistical significance ($P < 0.05$).The *P value in the* extent of surgical resection, postoperative evacuation time, intraoperative complications, postoperative complications, the application of postoperative analgesic drugs, and the length of postoperative hospital stay between the two cohorts was bigger than 0.05. There was no significant difference in the use of postoperative analgesic drugs between the two groups ($P = 0.980$), indicating that the postoperative pain of LESS surgery was not severe than that of the traditional laparoscopic group. Two patients had intraoperative change of surgical methods. One patient in the LESS cohort underwent fertility-sparing staged surgery with the addition of an auxiliary puncture port due to the possibility of borderline tumors suggested by intraoperative pathological findings. One patient in traditional laparoscope cohort was transferred to laparotomy due to severe abdominal adhesion. One of the patients who underwent

conventional laparoscopy accepted re-suture due to poor healing of the abdominal puncture site. (Table 2)

Table 2
 Operation Related data

	Experimental cohorts (n = 30)	Control cohorts (n = 46)	*t / Z / χ2*	*P**
Type of surgery			0.633	0.888
Ovarian cystectomy	24 (80.0%)	35 (76.1%)		
Adnexectomy	5 (16.7%)	10 (21.7%)		
Staging for borderline/malignant tumor	1 (3.3%)	1 (2.2%)		
Conversion (failure)	1 (3.3%)	1 (2.2%)		0.999
Use of additional ports	1	0		
Conversion to open surgery	0	1		
Operation time, min	82.2 ± 16	102.7 ± 26.2	-3.789	0.004
Estimated blood loss, ml	17.5 (10-22.5)	20 (18.7–35)	-2.019	0.043
Spillage of cyst contents	0	7 (15.2%)		0.038
Postoperative analgesic drug application			0.001	0.980
No	19 (63.3%)	29 (63%)		
Yes	11 (36.7%)	17 (37.0%)		
Exhaust time	11.1 ± 4.0	15.3 ± 4.4	-4.132	0.411
Intraoperative complications	0	0		
Postoperative complications	0	1 (2.2%)		0.999
Wound problem	0	1 (2.2%)		
Others	0	0		
Postoperative hospital stay			1.253	0.263
≤3	22 (73.3%)	28 (60.9%)		
3	8 (26.7%)	18 (39.1%)		
*All reported p values were two-sided.				

3.3 Pathological types There were no significant differences in postoperative routine pathological results between the two cohorts. One patient in the LESS cohort had intraoperative pathological findings suggestive of borderline mucinous adenoma, and fertility-sparing staged surgery was performed intraoperatively based on this finding. The intraoperative pathological results of 2 patients with traditional laparoscopy suggested borderline mucinous adenoma, of which 1 patient underwent staged surgery, and the other one patient's families strongly requested waiting for the confirmation of routine pathological results.This patient underwent staged surgery after the pathological findings were clear. (Table 3)

Table 3
Pathological types

	Experimental cohorts (n = 30)	**Control cohorts (n = 46)**	***t / Z / χ2***	***P***
Frozen section diagnosis				0.999
Benign tumo	29 (96.7%)	44 (95.7%)		
Borderline tumor	1 (3.3%)	2 (4.3%)		
Malignant tumor	0	0		
Final histology diagnosis			4.180	0.541
Benign mucinous tumor	6(20.0%)	6 (13%)		
Benign serous tumor	10 (33.3%)	13 (28.3%)		
Benign teratoma cyst	11 (36.7%)	15 (32.6%)		
Benign dermoid cyst	1 (3.3%)	2 (4.3%)		
Benign endometriosis	1 (3.3%)	8 (17.4%)		
Borderline mucinous tumor	1 (3.3%)	2 (4.3%)		
Malignant mucinous tumor	0	0		
*All reported p values were two-sided.				

3.4 Postoperative follow-up After discharge, the patients whose final histology diagnosis was benign visited the outpatient department once a month for reexamination for 3 consecutive times. During the follow-up, the well abdominal incision healed was observed. The menstruation of the patients of childbearing age who underwent ovarian cystectomy alone was the same as that before the operation, without other complications. The vaginal ultrasound showed no abnormality of the ovary. Postoperative follow-up for 6 months for the patient whose final histology diagnosis was borderline, and relevant examination results didn’t show any abnormal signal or disease progression.

4 Discussion

For giant ovarian cysts, there are some experts who believe that cysts larger than 10 mm in diameter are contraindications for laparoscopic surgery.Because the pelvic cavity is occupied by cysts ,the operable space is narrow and the anatomical position of the abdominopelvic cavity cannot be fully exposed, it is easy to lead to surrounding organ injury and cyst rupture[9].In order to solve the problem many obstetricians and gynecologists have explored. For example, ultrasound-guided technique was applied preoperatively for cyst fluid aspiration, or a second ,third trocar was used to puncture the cyst wall into the cyst cavity to aspirate the fluid [10, 11] .Relevant literature reports have demonstrated that the size of ovarian cysts is not an absolute contraindication for laparoscopic surgery[12].However, such reports showed that there was spillage of cyst fluid into the abdominal cavity[9, 12].

Relevant studies have shown that large-diameter cysts are closely related to the occurrence of malignant tumors, and the rupture of malignant tumors will reduce the long-term survival rate of patients, which indicates that it is essential to effectively ensure the integrity of cysts during surgery [13].Compared to conventional laparoscopy, the LESS surgery can enter the abdominal cavity under direct vision.And using sterile gauze wraps around inner edge of wound distractor .This two methods can effectively prevent ovarian cyst rupture as well as cyst spillage. None of the 30 patients who underwent LESS in this study had intraoperative cystic fluid spillage, which confirmed the safety of LESS surgery in this area compared with the spillage rate of 19.6% in the traditional laparoscopic cohort. In recent years, the application of local skin adhesive in LESS surgery for large ovarian cysts has emerged as a leak-proof technique, and relevant studies have also suggested significant effect [14], which providing more ideas and methods for LESS surgery in giant ovarian cyst surgery in the future.

Surgical procedures in the general laparoscopic group required prolonged maintenance of pneumoperitoneum ,which could increases the risk of tumor dissemination If the ovarian tumor is borderline or malignant[15, 16].At the same time, specimen removal is also a difficult pace under traditional laparoscopic surgery with the smaller puncture which usually from 5mm to 12mm.The length of abdominal incision in LESS surgery is about 2–3 cm, which is longer than that of traditional laparoscopic. Under LESS, the ovarian cyst wall can be gradually lifted to the outside of the abdominal cavity to complete ovarian cystectomy and ovarian repair under direct vision, reducing the time of operation exposed to pneumoperitoneum, not only reducing the electrolyte imbalance of patients caused by CO_2 diffusion into the blood[17], but also reducing the possibility of tumor dissemination due to the chimney effect. A Meta-analysis showed that electrocoagulation hemostasis had a negative effect on ovarian reserve and the effect can lasted for a long time[18].Operative performed outside the abdominal cavity in LESS reduced the use of electrical devices can better protects the ovarian reserve [19, 20, 21].

Conventional laparoscopy should have 3–5 puncture holes upon to the surgical operation needs. LESS surgery is performed using the umbilicus of the human body, and the special physiological conditions can largely cover the surgical incision scar ,which is more in line with the pursuit of minimally invasive [7, 23] .In this study, patients in both cohorts voluntarily chose the surgical method. The statistical results

showed that there was statistical significant in the age composition of the two cohorts ($P < 0.05$), suggesting that in the selection of surgical approach for giant ovarian cyst, younger women were more likely to choose LESS, which may be related to they pay more attention to their own image[23].And there was no significant difference between the two cohorts in terms of basic information and pathological type except for age.

A prospective analysis of 21 patients with ovarian cysts ≥ 15 cm in diameter who underwent LESS showed that the median operation time was 79.8 min (39–155 min), blood loss was 60 mL (10–180 mL); postoperative hospital stay was (2.7 ± 0.6) d (2–4 d); 1 patient (5%) had postoperative scar hematoma; more than 71% of patients were satisfied with the occult scar after logarithm [24].In contrast, in this study, the operation time of LESS surgery was 80 min (55–135 min), which may be because all patients were not operated by the same surgeon and it included the intraoperative waiting time for frozen pathology. The intraoperative blood loss was 17.5ml (10-22.5ml).one patient(2.2%) in control cohorts exhibited wound problem. The length of hospital stay 3 days (2-5d) after surgery may be related to the health insurance system in China, cause patients tend to wait for routine pathological results before discharge.

Combined with relevant reports and this study, the results demonstrated that LESS surgery in the treatment of giant ovarian cyst has the characteristics of save operation time, less bleeding, shorter exhaust time, less postoperative complications, high scar aesthetics satisfaction, etc. Therefore, after adequate evaluation and screening of patients, the size of ovarian cyst cannot be used as the reason for rejecting LESS surgery, which is safe and feasible for clinical promotion in the treatment of giant ovarian cyst. However, the sample size of relevant studies in this study is small and there is a lack of large-sample data analysis, and more prospective studies are needed in order to obtain more definite conclusions.

Abbreviations

NOTES : atural orifice transluminal endoscopic surgery

vNOTES : transvaginal natural orifice transluminal endoscopic surgery

LESS : laparoendoscopic single site surgery

Declarations

Disclosure Statement

These authors declare no competing interests.

Ethics approval and consent to participate: Not Applicable.

Consent for publication: Not Applicable.

Availability of data and materials: The datasets generated during and/or analysed during the current study are available from the corresponding author on reasonable request.

Competing interests: The authors declare that they have no competing interests.

Funding: No Funding.

Authors' contributions: SZC is the primary author of this manuscript, designed experiments, performed, data analysis and wrote the manuscript. LPH contributed to design experiments and modified article; WZ , LYP , HYZ collected clinical data. All authors read and approved the final manuscript.

Acknowledgements: Not Applicable.

Author details

[1]Shuzhen Chang, Department of Obstetrics and Gynecology,The First Affiliated Hospital of Zhengzhou University, Zhengzhou China E-mail: csz818@163.com

[2]Wei Zhang, Department of Obstetrics and Gynecology,The First Affiliated Hospital of Zhengzhou University, Zhengzhou China E-mail: zw1431247405@163.com

[3] Linyv Peng, Department of Obstetrics and Gynecology,The First Affiliated Hospital of Zhengzhou University, Zhengzhou China E-mail: 952188271@qq.com

[4]Haiyan Zhou, Department of Obstetrics and Gynecology,The First Affiliated Hospital of Zhengzhou University, Zhengzhou China E-mail: 1653676895@qq.com

[5] Corresponding Author :Professor Liping Han female (1969-), department of Obstetrics and Gynecology,The First Affiliated Hospital of Zhengzhou University, Zhengzhou China,E-mail: hanliping0825@163.com

She is good at hysteroscopic and laparoscopic minimally invasive surgery and the diagnosis and treatment of benign and malignant gynecological tumors, and took the lead in carrying out pneumoperitoneum free ovarian cancer surgery and single-incision mid-urethral tension-free suspension and other surgeries. She has been engaged in the clinical, teaching and scientific research of obstetrics and gynecology for more than 20 years, and has undertaken the theoretical and clinical teaching tasks of obstetrics and gynecology for graduate students, undergraduate students and international students. Scientific research experience: she graduated from the Department of Clinical Medicine in 1992, from the Master of Obstetrics and Gynecology in 2002, and received her PhD in medicine in 2005. She was selected to study minimally invasive treatment (including robotic surgery) for gynecological endocrine and gynecological tumors at the Oslo University Cancer Hospital and Harvard Medical School in Norway in 2004 and 2008-2009, respectively.Main achievements: In recent years, she has participated in 12

national and provincial scientific research projects,published more than 40 papers in SCI and Chinese series of journal journals, and published three monographs.

References

1. Baradwan S，Sendy F，Sendy S， Complete laparoscopic extirpation of a giant ovarian cyst in an adolescent， Case Rep Obstet Gynecol，2017， 8(3) : 1 － 3， doi: 10， 1155 /2017 /7632989，
2. Goudge CS, Li Z, Downs LS Jr. The influence of intraoperative tumor rupture on recurrence risk in Stage Ic epithelial ovarian cancer. European Journal of Gynaecological Oncology.2009. 30:25–28.
3. Kim HS, Ahn JH, Chung HH, Kim JW, Park NH, Song YS, et al. Impact of intraoperative rupture of the ovarian capsule on prognosis in patients with early-stage epithelial ovarian cancer: a meta-analysis. European Journal of Surgical Oncology (EJSO) 2013.39:279–289
4. Li CB, Hua KQ. Transvaginal natural orifice transluminal endoscopic surgery (vNOTES) in gynecologic surgeries: A systematic review. Asian J Surg. 2020 Jan;43(1):44-51. doi: 10.1016/j.asjsur.2019.07.014. Epub 2019 Aug 20. PMID: 31444108.
5. Palanivelu C，Rajan PS，Rangarajan M，et al.Transvaginal endo， scopic appendectomy in humans，a unique approach to NOTES–world's first report. Surg Endosc2008，22，5，， 1343-1347.
6. Fatema N，Mubarak MB， A postmenopausal woman with giant ovarian serous cyst adenoma: a case report with brief literature review， Case Rep Obstet Gynecol，2018，2018 (3) : 1 － 4， doi: 10， 1155 /2018 / 5478328，
7. Liu Xiu, Wenmengke, Liu Haiyuan, et al. Controlled clinical study of single-port laparoscopic and multi-port laparoscopic ovarian cystectomy . Chinese Journal of Obstetrics and Gynecology, 2017, 52 (10): 675-678.doi: 10.3760/cma.j.issn.0529-567X.2017.10.006.
8. Song T, Kim MK, Kim ML, Yoon BS, Seong SJ. Laparoendoscopic single-site surgery for extremely large ovarian cysts: a feasibility, safety, and patient satisfaction study. Gynecol Obstet Invest. 2014;78(2):81-7. doi: 10.1159/000363237. Epub 2014 Jun 20. PMID: 24969078.
9. Panici PB，Muzii L, Palaia I, etal. Minilaparotomy versus laparoscopy in the treatment of ，Benign adnexal cysts: arandomized clinical study. Eur J Obstet Gynecol Reprod Biol,2007, 133(2) :218-222.
10. Nagele F, Magos AL. Combined ultrasonographically guided drainage and laparoscopic excision of a large ovarian cyst. Am J Obstet Gynecol 1996;175:1377–8.
11. Garzetti GG, Ciavattini A, Tirduzzi M. Combined ultrasonographically guided drainage and laparoscopic excision of large endometriomas: a pilot study. Gynecol Obset Investig 1998;45:266–8.
12. Eltabbakh GH, Charboneau AM, Eltabbakh NG. Laparoscopic surgery for large benign ovarian cysts. Gynecol Oncol. 2008 Jan;108(1):72-6. doi: 10.1016/j.ygyno.2007.08.085. Epub 2007 Oct 18. PMID: 17949797.
13. Vergote I，De Brabanter J，Fyles A ，et al， Prognostic importance of degree of differentiation and cyst rupture in stage I invasive epithelial ovarian carcinoma.Lancet，2001，357(9251) : 176-182.

14. Song T, Sung JH. Leak-proof technique in laparoscopic surgery for large ovarian cysts. J Obstet Gynaecol. 2021 Jan;41(1):106-111. doi: 10.1080/01443615.2020.1718626. Epub 2020 Mar 9. PMID: 32148121.
15. Ki EY，Park EK，Jeong IC，et al． Laparoendoscopic single site surgery for the treatment of huge ovarian cysts using an angiocatheter needle． Yonsei Med J，2019，60 (9) : 864 － 869． doi: 10． 3349 /ymj． 2019． 60． 9． 864.
16. J0cabi CA , Sabat R , Hm B , et al. Pneumoperitoneum with carbon dioxide stimulates growth of malignant colonic cancer cells. Surgery , 1997 ,121 :72-78.
17. Krishnamoorthy B, Critchley WR, Nair J, et al.Randomized study comparing the effect of carbon dioxide insufflation on veins using 2 types of endoscopic and open vein harvesting. Innovations(Phila), 2017, 12(5):320-328. DOI: 10.1097/imi. 0000000000000405.
18. Xiao Chao, Xiao Xue, Ogimin, et al. Meta-analysis on the effect of electrocoagulation hemostasis and suture hemostasis on ovarian reserve in laparoscopic ovarian cystectomy. Journal of Practical Obstetrics and Gynecology, 2015, 31 (8): 618-622.
19. Goodman LR, Goldberg JM, Flyckt RL, et al. Effect of surgery on ovarian reserve in women with endometriomas, endometrio- sis and controls. Am J Obstet Gynecol, 2016, 215 (5): 589. DOI: 10.1016/j.ajog.2016.05.029.
20. Song T, Lee SH, Kim WY. Additional benefifit of hemostatic seal- ant in preservation of ovarian reserve during laparoscopic ovar- ian cystectomy: A multi-center, randomized controlled trial. Hum Reprod, 2014, 29(8): 1659-1665. DOI : 10.1093/humrep/ deu125.
21. Fagotti A，Bottoni C，Vizzielli G，et al． Postoperative pain after conventional laparoscopy and laparoendoscopic single site surgery (LESS) for benign adnexal disease: A randomized trial..Fertil Steril，2011，96(1) :255-259．
22. Chong GO，Hong DG，Lee YS． Single-port (octoport) assisted extracorporeal ovarian cystectomy for the treatment of large ovarian cysts: compare to conventional laparoscopy and laparotomy.J Minim Invasive Gynecol，2015，22(1) : 45 － 49． doi: 10． 1016 /j． jmig． 2014． 06． 003．
23. Ross S, Bourdeau T, Luberice K, Crespo K, Faustin V, Sucandy I, Rosemurgy A. Laparo-Endoscopic Single Site (LESS) cosmesis: Patients perception of body image distortion after LESS surgery. Am J Surg. 2021 Jan;221(1):187-194. doi: 10.1016/j.amjsurg.2020.06.002. Epub 2020 Jul 8. PMID: 32782079.
24. Song T, Kim MK, Kim ML, Yoon BS, Seong SJ. Laparoendoscopic single-site surgery for extremely large ovarian cysts: a feasibility, safety, and patient satisfaction study. Gynecol Obstet Invest. 2014;78(2):81-7. doi: 10.1159/000363237. Epub 2014 Jun 20. PMID: 24969078.

Figures

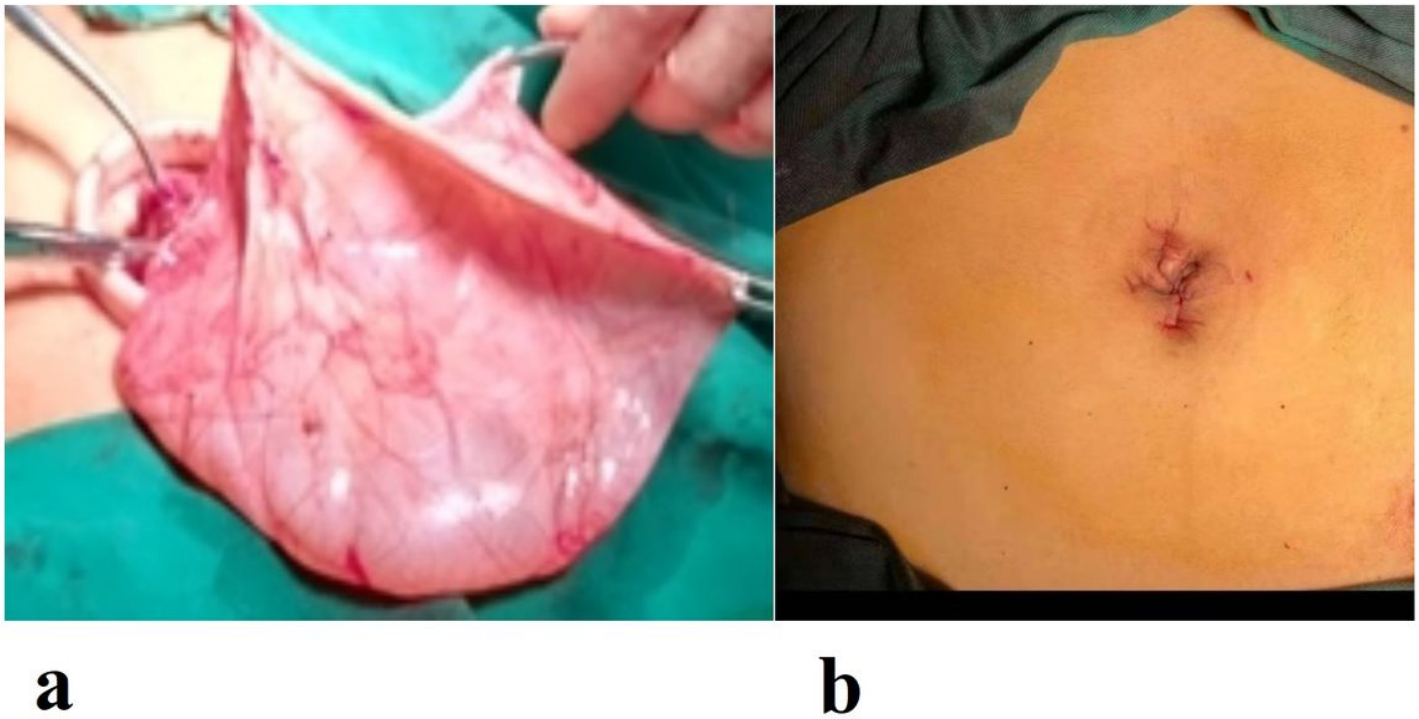

Figure 1

Picture A and Picture B