Research Square

Preprints are preliminary reports that have not undergone peer review. They should not be considered conclusive, used to inform clinical practice, or referenced by the media as validated information.

The Results of Modified Hang Back Recession Surgery in Infantile Esotropia

Diğdem BEĞENDİ
İstanbul Bilim Üniversitesi: TC Demiroglu Bilim Universitesi

Burçin KAYA
Yozgat State Hospital: Yozgat Devlet Hastanesi

Yaşar DURANOĞLU (yduranoglu@hotmail.com)
Retired https://orcid.org/0000-0002-2159-8780

Research Article

Keywords: Hang-Back, Recession, Overcorrection, Infantile Esotropia

Posted Date: September 15th, 2021

DOI: https://doi.org/10.21203/rs.3.rs-905652/v1

License: This work is licensed under a Creative Commons Attribution 4.0 International License.
Read Full License

Abstract

PURPOSE:

Bimedial rectus recession is one of the surgical treatment options for infantile esotropia. It is mainly performed with the Hang-Back technique, which has undesirable side effects. In this study, this technique has been modified, and its results are discussed.

METHODS:

The files of 120 patients followed with the diagnosis of infantile esotropia and treated bimedial rectus muscle recession using the modified Hang-Back technique were reviewed retrospectively. Cases were evaluated by the time of surgery, coexistence with inferior oblique muscle weakening surgery, and presence of refractive error. The factors investigated on the results of surgical treatment were determined as age, gender, amount of hyperopic refractive error, application age, amount of horizontal deviation, amount of recession, stereopsis, fusion, age of surgery.

RESULTS:

When the cases were divided into subgroups which were the time of surgery, the operation performed with inferior oblique weakening surgery and presence of refractive error; the difference between preoperative and postoperative 1st month, 6th month, and 1st-year angle of deviation was statistically significant in all three groups ($p < 0.001$).

CONCLUSION:

This novel technique aims to prevent unwanted movement of the muscle in the horizontal and vertical axis and a gap in the middle of the recessed muscle, seen in the classical Hang-Back technique. The difference between the preoperative and postoperative angle of deviation was statistically significant. Also, over and under-correction and the development of alphabetic pattern deviation were less common in our modified technique.

Introduction

Infantile esotropia is the most common form of strabismus and is estimated to show a 1% prevalence. [1,2] Despite all additional treatment options, the treatment of infantile esotropia is surgery. It is aimed to achieve equal visual acuity, retinal adjustment, binocular monovision, and bifoveal motor fusion in both eyes. [3,4,5]

In our study, the Hang-Back technique for bimedial recession surgery, one of the surgical treatment options in cases diagnosed with infantile esotropia, was modified. The results were discussed in various aspects..

Subjects And Methods

One hundred twenty patients who were followed up and underwent surgical treatment with infantile esotropia were included in this study. After local ethics committee approval, informed consent was obtained from participants or their parents after a full explanation of the procedures. All procedures were conducted following the Declaration of Helsinki.

The study included cases diagnosed with infantile esotropia based on examination findings and family history. Patients with prematurity, previous eye surgery, neurological abnormalities, nystagmus, developmental retardation, and examination difficulties were not included in this study.

The outpatient examination records of the cases were reviewed retrospectively, and their demographic characteristics, strabismus type, routine eye examination findings, amblyopia treatment, surgical information performed, and postoperative examination findings were obtained.

The age of operation, preoperative and postoperative degree of deviation and eye movements, abnormal head position, binocular vision, and operation technique were noted.

Visual acuity was evaluated with a Snellen chart or Lea symbols. 1% cyclopentolate was used for the measurement of refraction. Fixation and object tracking features were examined in patients who could not cooperate. The fundus examination was performed from the dilated pupil. Patients with posterior segment pathologies that could cause deviation were excluded from the study.

Eye movements were evaluated in nine cardinal gaze positions. Muscle over or underaction was recorded if it existed. Deviation degree measurements were performed with the prism cover test at a far, near, and medium distance. The Krimsky test was used to determine the amount of near deviation in cases where this evaluation could not be made due to their age and fixation was poor.

The factors investigated on the results of surgical treatment were determined as age, gender, amount of hyperopic refractive error, the age of surgery, the degree of horizontal deviation, amount of recession, stereopsis, fusion, age of surgery. The amount of surgery performed was calculated by taking into account the degree of deviation and the clinical features of the patients.

Surgical Technique

The operations were performed under general anesthesia. After holding the conjunctiva with toothless forceps at 6 and 12 o'clock, the presence of a mechanical factor of the medial rectus was checked by performing a forced duction test. The conjunctiva was held at the limbus level by forceps, and the eye deviated laterally. Blunt dissection was carefully performed in the conjunctiva and was cut to the medial fornix. Apposition sutures were placed in each of the incision corners with a 7/0 vicryl (polyglactin 910, Ethicon) suture. After the medial rectus was found with crochet, it was cleaned with a cotton swab without touching the surrounding intermuscular membrane and check ligaments. The muscle was disinserted by scissors after the fixation suture, which was placed with 7/0 vicryl throughout the muscle.

The amount of the recession was measured. Both ends of the suture were passed through the sclera the upper and lower point of the muscle's new attachment site. These sutures were applied perpendicular to the axis of the muscle. Eachof the sutures is knotted by passing through the middle of the end of the muscle. The suture ends were hung, passing through the top and bottom of the original insertion. After checking the amount of recession, the wound was closed using interrupted 7/0 vicryl suture (Fig. 1–4).

Antibiotic pomade was put in the eye, and no closure was applied.

Postoperatively, 1% dexamethasone drop 3 × 1 and moxifloxacin drop 4 × 1 and tobramycin ophthalmic pomade 3 × 1 was applied to the eyes for two weeks.

The deviation was re-evaluated in the postoperative period. Patients with esotropia or exotropia up to 10PD after surgery was considered to be successful. More than 10PD esotropia was considered to be under correction, and more than 10PD to exotropia was considered to be overcorrection.

Statistical Analysis

The results were evaluated with SPSS 20.0 (Statistical Package for Social Sciences) software.

Continuous variables were expressed as median (25th-75th percentile) to define the sample, and categorical variables were indicated by numbers and percentages. The consistency of continuous variables to normal distribution were examined with the Shapiro Wilk test. Due to the lack of parametric test assumptions, the Friedman test was used to compare more than two dependent variables, and the Wilcoxon test was used for postoperative comparisons. The relationship between deviation degree and age of surgery variable group was determined by binary logistic regression analysis. The alpha significance level was taken as 0.05.

Results

One hundred twenty patients diagnosed with infantile esotropia and followed up regularly were included in the study. The median age of the application and the age of surgery according to the distribution were found to be 2.5 years.

Sixty- two (51.7%) of the cases were female, and 58 (% 48.3) were male.

Cases were evaluated according to the age of surgery, combining with the surgical weakening of the inferior oblique and finding a refractive error.

When it was classified according to the time of surgery, it was observed that 80 (67%) of the cases were operated early, and 40 (33.3%) were operated late.

There were 40 (33.3%) cases in which surgery was performed with an inferior oblique muscle tenotomy surgery and 80 (66.7%) cases underwent bimedial recession surgery only. While the presence of refraction error was observed in 27 (22.5%) cases; it was not found in 93 (77.5%) cases.

Deviation degrees were measured preoperatively and one month, six months, one year after surgery. The preoperative deviation degree median value was 45 (30–80) PD. In postoperative follow-ups, deviation degree was found a maximum of 25PD and a median value of 0 PD in the first month. In the sixth month, a maximum of 20PD and a median value of 0 PD, and In the first year, a maximum of 30PD and a median value of 0 PD were found. There was a statistically significant difference compared to the preoperative deviation degree in the postoperative first and 6th month, first-year (Table 1).

Table 1
Deviation in the preoperative and postoperative 1st month, 6th month, and 1st year of cases (median (25.-75. percentile)).

		p-value
Preoperative deviation (PD)	45 (40–50)	< 0,001*
Postoperative first month deviation degree(PD)	0 (0–0)	
Postoperative sixth month deviation degree (PD)	0 (0–5)	
Postoperative first year deviation degree (PD)	0 (0–5)	
*Statistically significant result (p < 0,001)		

When the cases were evaluated separately according to their classifications, it was found that there was a statistically significant difference in the postoperative first and 6th month and first year compared to the preoperative deviation degrees (Table 2–3,4).

Table 2
Deviation degrees according to the time of surgery (median (25.-75. percentile).

Surgical time			p-value
	Early n:80	Late n:40	
Pre-operative Deviation Degree (PD)	50 (40–50)	40 (38–50)	<0,001*
Postoperative first month deviation Degree (PD)	0 (0–0)	0 (0–0)	
Postoperative sixth month deviation degree (PD)	0 (0–5)	0 (0–0)	
Postoperative first year deviation degree (PD)	0 (0–5)	0 (0–0)	
• Statistically significant result (p < 0,001)			

Table 3
Deviation degrees of the cases according to the association with Inferior oblique muscle surgery (median (25.-75. percentile)).

	Inferior oblique weakening surgery		p-value
	Present n:40	Absent n:80	
Pre-operative deviation Degree (PD)	45 (40–50)	50 (40–50)	<0,001*
Postoperative first month Deviation Degree (PD)	0 (0–0)	0 (0–0)	
Postoperative sixth month Deviation Degree (PD)	0 (0–5)	0 (0–5)	
Postoperative first year Deviation Degree (PD)	0 (0–5)	0 (0–5)	
* Statistically significant result (p < 0,001)			

Table 4
Deviation Degree according to refractive error (median (25.-75. percentile)).

	Refractive Error		p-value
	Present n:27	Absent n.93	
Preoperative deviation degree (PD)	50 (40–50)	45 (40–50)	<0,001*
Postoperative first month deviation degree (PD)	0 (0–5)	0 (0–0)	
Postoperative sixth month deviation degree (PD)	0 (0–5)	0 (0–5)	
Postoperative first year deviation degree	0 (0–5)	0 (0–5)	
• Statistically significant result (p < 0,001)			

Discussion

The amount of deviation observed in infantile esotropia is more than 30PD, as shown in many series. In our study, the amount of deviation, on average 45 PD, is compatible with the literature.

Vertical deviations often accompany infantile esotropia. In particular, primary inferior oblique muscle hyperfunction has been reported between 36–78% .[6] In our study, the coexistence of 33% inferior oblique hyperfunction was found.

Surgical techniques performed in the treatment of infantile esotropia were bimedial recession and recession and resection procedures in the same eye. Bimedial recession surgery is recommended for these patients in the development age.[7,8]

Recession is performed by the fixed suture or Hang-Back recession technique with or without adjustable suture. The disadvantages of the hang-back recession are overcorrection of the deviation that occurs especially after the collapse of the center of the muscle. The alphabetic pattern deviation by the upward and downward displacement of the muscle, and the stretched scar formation that occurs in the late period. [9,10,11]

Capo et al. published more overcorrection in the Hang-Back recession group in the results they obtained a year after the surgery. They also reported that the overcorrection was caused by the gap formed in the middle of the muscle after recession. [12]

In animal experiments with Hang-Back recession surgery, it was observed that the muscle was displaced in the horizontal and vertical axis before adhering to the surgical field. On the other hand, Lee et al. observed no change in four of the ten muscles in their animal experiments, while displacement was observed in four muscles upwards and two muscles downwards. Many explanations have been made to support these results. These are bleeding during surgery and the growth of muscle fibers forward.

Ohtsuki et al. reported that in the Hang-Back recession process, there was more fibrous tissue production around the new adhesion site, which helped the muscle advance forward. [13,14,15] For this reason, a special effort was made to control bleeding in the cases where we performed surgery, and the surgical field was kept clean.

In their animal experiments, Park et al. used fibrin glue as an adjuvant to prevent the horizontal and vertical displacement of the muscle seen in the classical Hang-Back technique. As a result, in the group where fibrin glue was applied, the muscle was more stable in the new insertion site, and less displacement was observed. On the other hand, Chung et al. tried to prevent the movement of the muscle by placing the sutures parallel to the muscle in the modified Hang-Back technique. Their success was 67.4%, and similar to the results of the cases, they performed Hang-Back. [16,17]

Ameri et al. reported that they did not see a statistically significant difference in their one-year surgical results in cases where they applied modified and classical Hang-Back recession surgery.[18] Unlike the technique of Ameri et al., the sutures we put on the sclera in the new insertion localization are perpendicular, not parallel to the axis of the muscle. In addition, the sutures were placed on the front surface of the muscle, knotted and hung on the original insertion.

Agrawal et al. compared the surgeries performed with the modified Hang-Back technique with adjustable suture to those with classical Hang-Back surgery. They reported that as a result, less adjustment is required, and it is effective for a larger angle of deviation. There was less secondary surgery required

during the follow-up and no complications other than the complications seen with the classical Hang-Back technique. [19]

In our study, more than 10PD esotropia was observed in nine cases (0.75%) at the end of the first year. Their mean values were 21 (16–35) PD. Small-angle (10PD and below) esotropia was found in 24 cases (20%). Only one case (0.83%) had increased efficacy. According to these results, our success rate is 91.6%, and it is higher than similar study rates in the literature.

It was reported that more stable results were obtained in patients who were operated late period of the life due to the slowing of the growth in the globe.[20] In our study, when the preoperative and postoperative deviation degrees of the cases which were operated early and late period of the life were compared. The difference was found to be statistically significant. This result suggests that our technique can be performed safely in cases in both groups. In addition, in our study, the age of surgery was statistically effective on the degree of final deviation (p: 0.037).

According to Kushner et al., there are reverse interactions between axial length and surgical outcome. Surgical doses created by taking into account the axial length may cause different results. In such cases, an increased amount of surgery is recommended. [21] In our study, when the preoperative and postoperative deviation degrees were compared in normal and high hyperopia cases, the difference was statistically significant ($p < 0.001$). This result shows that the surgical technique we performed is effective independently of the short axial length. The reason for this success is to maintain the contact between the globe and the muscle and to comply with the anatomy. Thus, the effectiveness of the changes in the axial length has been reduced. Also, the effect of refractive error on the final deviation degree was statistically significant (p: 0.039).

Nabie et al. modified the hang-back technique by placing additional scleral sutures parallel to the muscle and compared the results with the classical Hang-Back technique. They did not observe any significant difference between the two techniques in terms of muscle shift, backward movement, pseudotendon formation, and scleral perforation. [22] Similar results were obtained in our study.

The development of exotropia after esotropia surgery is a very common complication. [23–27] In our study, only one patient (0.83%) had orthotropia in the first and sixth months, while 30PD exotropia developed in the first-year follow-up. In the secondary surgery, it was observed that there was a stretched scar syndrome, and orthotropia was achieved due to the advancement of the muscle with scar resection.

Chung et al. compared the classical hang-back technique and the modified techniques in their recession surgery to the medial rectus. In this study, overcorrection was observed significantly in the group applied in the Hang-Back technique. As a result, they showed the continuous friction and movement of the muscle to the sclera. Also, the hematoma developing on the lower surface of the muscle affects the healing process and causes the development of a slipped muscle or pseudotendon. In our modified technique, the intermuscular and check ligaments and the tenon and muscle sheath on the back of the

muscle were not touched. According to Repka and Guyton, the backward bending of the middle part of the muscle causes increased effectiveness in the Hang-Back regression technique. In modified techniques, the development of the central cavity and pseudotendon is less frequent. These authors suggested adding 0.5 mm to the standard dose table for recession surgery performed with the Hang-Back technique. [28,29]

In our study, only one case (0.83%) had overcorrection. The reason for this low rate is that after placing the vertical suture on the sclera at both ends of the muscle, the same sutures are passed under the muscle again, knotted on the upper surface and suspended in the form of a hammock to the original insertion, thus preventing the muscle from sliding backward. Also, the 0.5 mm overdose recommendation stated in the literature was not followed in these cases.In the traditionally Hang-Back recession surgeries, slipped muscle is seen more frequently due to improper muscle fixing suturation, delayed healing of the muscle, slipping over the globe. This pathology usually occurs in the first few weeks after surgery. One of the aims of our study is to avoid this complication. For this reason, the slipped muscle was not encountered due to the suture we put on the front side of the muscle and hanging from the center of the muscle to the original insertion site.

Studies conducted in the past report that only surgeries applied to oblique muscles cause an insignificant horizontal shift. [30] In our study, it was determined that the surgery applied to the inferior oblique muscle did not have a statistically significant effect on the degree of final deviation (p: 0.566). However, when the patients were examined in the subgroup as those with and without inferior oblique muscle surgery, a statistically significant result was obtained between the preoperative and postoperative deviation degrees in both groups ($p < 0.001$).

Declarations

This study was approved by Akdeniz University School of Medicine Ethics Committee in 28.08.2019 /780

Informed consent statement; General consent was obtained in which the patient agrees with the research use of residual body parts and clinical records and data with anonymization.

Declaration of conflicting interests The author(s) declared no potential conflicts of interest with respect to the research, authorship, and/or publication of this paper.

Funding The author(s) received no financial support for the research, authorship, and/or publication of this article.

References

1. Nixon RB, Helveston EM, Miller K, Archer SM, Ellis FD (1985) Incidence of strabismus in neonates. Am J Ophthalmol 100:798–801
2. Hug D (2015) Management of infantile esotropia. Curr Opin Ophthalmol 26(5):371–374

3. Simonsz HJ, Kolling GH (2011 May) Best age for surgery for infantile esotropia. Eur J Paediatr Neurol 15(3):205–208
4. Chiu MJ, Wan Shah H, Hunter AS (2018 May) DG. Long-term Surgical Outcomes for Large-angle Infantile Esotropia. Am J Ophthalmol 189:155–159
5. von Noorden GK (1990) Binocular vision and ocular motility, 4th edn. CV Mosby Co, St. Louis, pp 51–285
6. Von Noorden GK. A reassessment of infantile esotropia. XLIV. Edward Jackson Memorial lecture. Am J Ophthalmol 1988; 1051–60
7. Kim E, Choi DG (2019 Apr) Comparison of surgical outcomes between bilateral medial rectus recession and unilateral recess-resect for infantile esotropia. Ophthalmic Epidemiol 26(2):102–108
8. Ansons AM, Davis H (eds). Infantile strabismus. In: Diagnosis and management of ocular motility disorders. 3rd ed, Manchester. Blackwell Science 2001; 286 – 93
9. Rajavi Z, Ghadim HM, Nikkhoo M, Dehsarvi B (2001) Comparison of hang-back and conventional recession surgery for horizontal strabismus. J Pediatr Ophthalmol Strabismus 38:273–277
10. Chung AK, Rehman SU, Bradbury JA (2005) Comparison of modified anchored hang-back technique (HBT) with conventional HBT in bimedial rectus recession. J AAPOS 9:234–239
11. Hemmerdinger C, Rowe N, Baker L, Lloyd IC (2005) Bimedial hang-back recession-outcomes and surgical response. Eye 19:1178–1181
12. Capó H, Repka MX, Guyton DL. Hang-Back lateral rectus recession for exotropia.J. Pediatr Ophthalmol Strabismus. 1989 Jan-Feb;26(1):31–4
13. Ingram RM (1966) Wound healing after operations on the extra-ocular muscles of monkeys. Br J Ophthalmol 50:186–208
14. Lee J, Kim S (1996) The alteration of extraocular muscle arc after hang-back recession in animal experiments. Eur J Ophthalmol 6:331–335
15. Ohtsuki H, Oshima K, Hasebe S, Kobashi R, Okano M, Ruruse T (1994) Extraocular muscle surgery in a rabbit model: site of reattachment following hang-back and conventional recession. Graefe's Arch Clin Exp Ophthalmol 232:689–694
16. Park et al (2012) Effect of fibrin glue as an adjuvant to hang-back surgery. BMC Ophthalmology 12:14
17. Chung AK, Rehman SU (2005) J.A. Bradbury Comparison of modified anchored “hang-back technique (HBT)” with conventional HBT in bimedial rectus recession. J AAPOS 9:234–239
18. Ameri A, Jafari AK, Anvari F, Ahadzadeghan I, Rajabi MT (2010) A new modified anchored suspension-recession (so-called "hang-back" technique for high risk strabismus surgery. Binocul Vis Strabismus Q 25(1):21–30
19. Agrawal et al (2017 Nov) Modified adjustable suture hang-back recession: Description of technique and comparison with conventional adjustable hang-back recession. Indian J Ophthalmol 65(11):1183–1186

20. Simonsz HJ, Kolling GH, Unnebrink K (2005) Final Report of the Early vs. Late Infantile Strabismus Surgery Study (ELISSS), a Controlled, Prospective. Multicenter StudyStrabismus 13:169–199
21. Kushner BJ, Lucchese NJ, Morton GV (1989) The influence of axial length on the response to strabismus surgery. Arch Ophthalmol 107:1616–1618
22. Nabie Reza M, Azadeh (2011) Dima Andalip et all. Anchored versus conventional hang-back bilateral lateral rectus recession for exotropia. J AAPOS 15:532–535
23. Chatzistefanou KI, Brouzas D, Droutsas KD, Koutsandrea C, Chimonidou E (2018) Unilateral recession-resection surgery for infantile esotropia: Survival of motor outcomes and postoperative drifts. Semin Ophthalmol 33(4):498–505
24. Li B, Sharan S. Postopererative analysis of pediatric esotropia associated with high hypermetropia. BMC Ophthalmol. 2019 Jul 1; 19(1):140
25. Vronman DT, Hutchinson AK, Saunders RA (2000) M.E. WilsonTwo-muscle surgery for congenital esotropia: Rate of reoperation in patients with small versus large angles of deviation. J AAPOS 4:267–270
26. Stager DR, Weakley DR Jr, Moody E, Everett M (1994) E.E. Birch.Delayed consecutive exotropia following 7-millimeter medial rectus recession for congenital esotropia. J Pediatr Ophthalmol Strabismus 31:147–150
27. Bryselbout S, Promelle V, Pracca F, Milazzo S (2019 Jan) Clinical and surgical risk factors for consecutive exotropia. Eur J Ophthalmol 29(1):33–37
28. Capo H, Repka MX (1989) D.L. Guyton.Hang-back lateral rectus recessions for exotropia. J Pediatr Ophthalmol Strabismus 26:31–34
29. Breckenridge AL, Dickman DM, Nelson LB, Attia M (2003) D. Ceyhan Long-term results of hang-back medial rectus recession. J Pediatr Ophthalmol Strabismus 40:81–84
30. Urist MJ (1952) Surgical treatment of esotropia with bilateral elevation in adduction. AMA Arch Ophthalmol 47(2):220–247

Figures

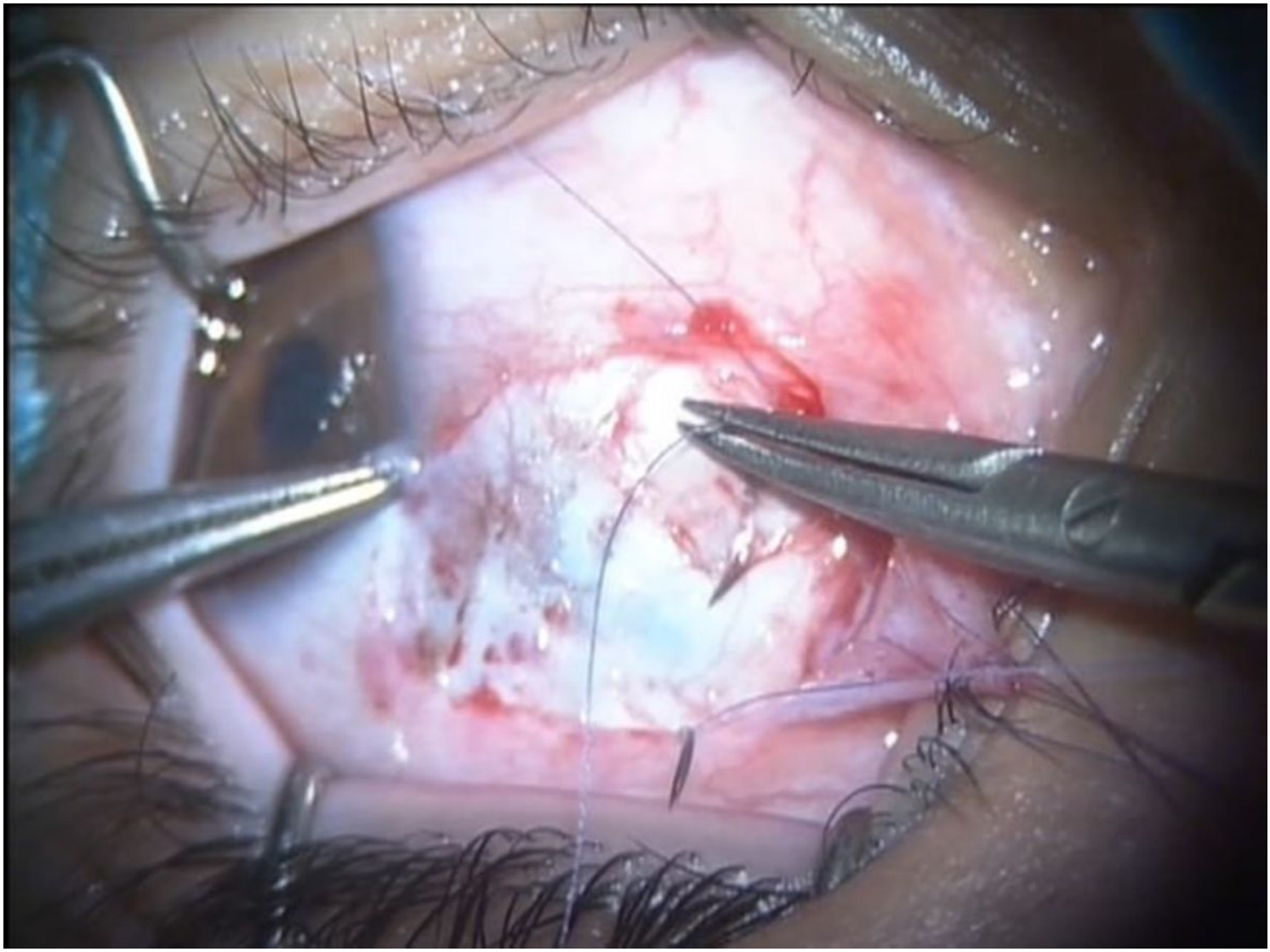

Figure 1

Suturing at the lower and top end of the new insertion line

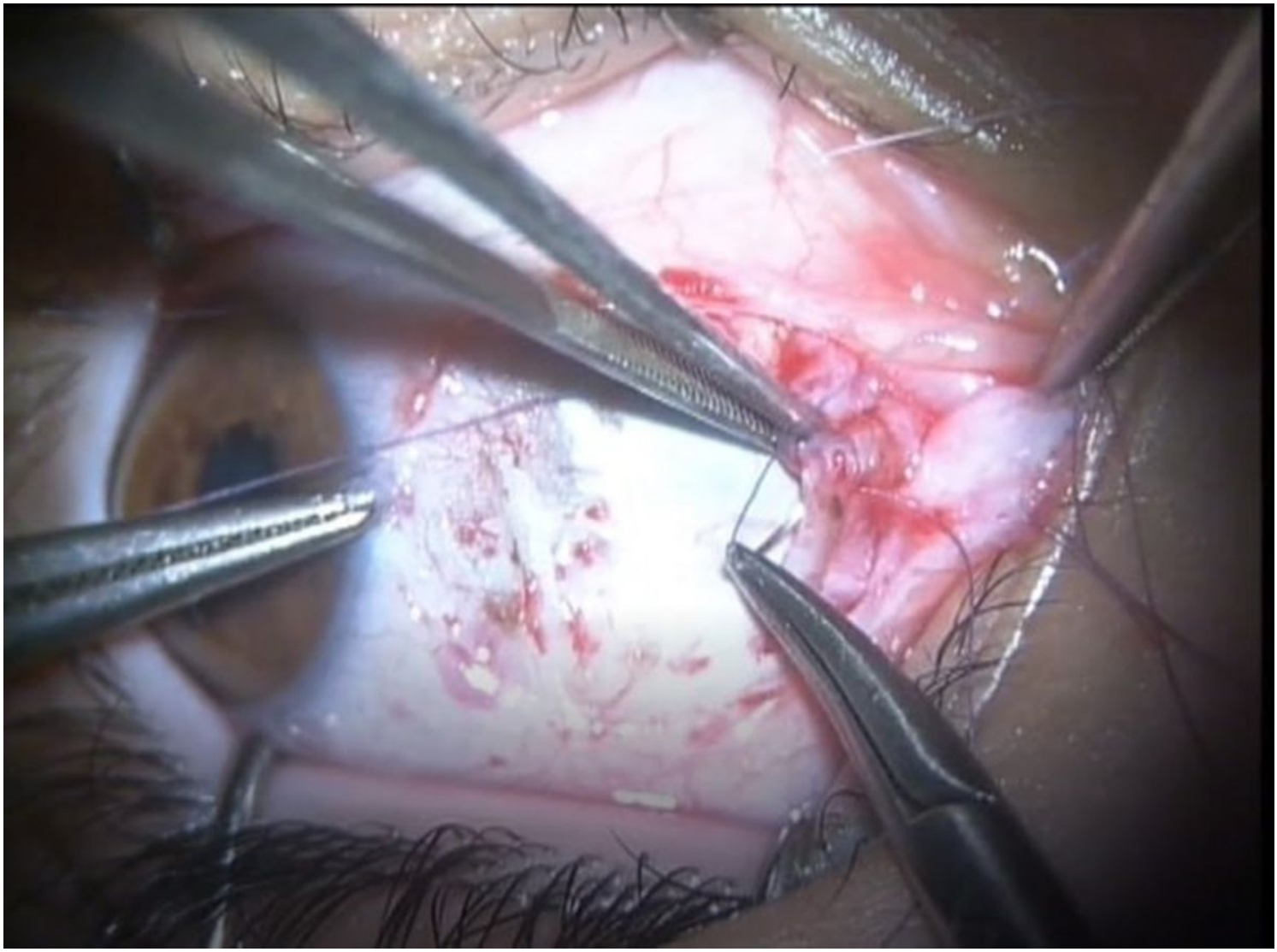

Figure 2

Suturing from the back surface of the muscle to the front surface

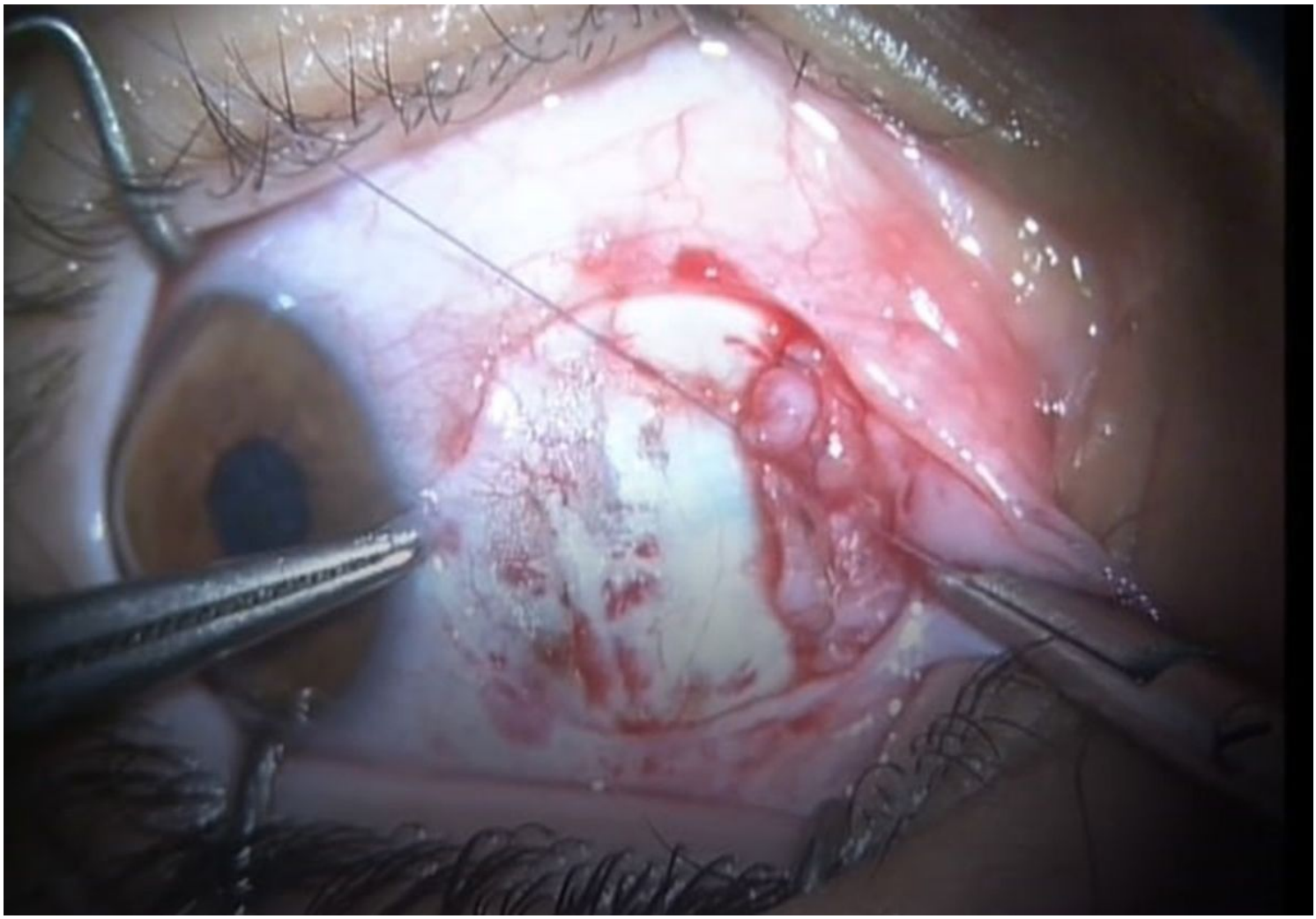

Figure 3

The knotting of the sutures on the anterior surface of the muscle

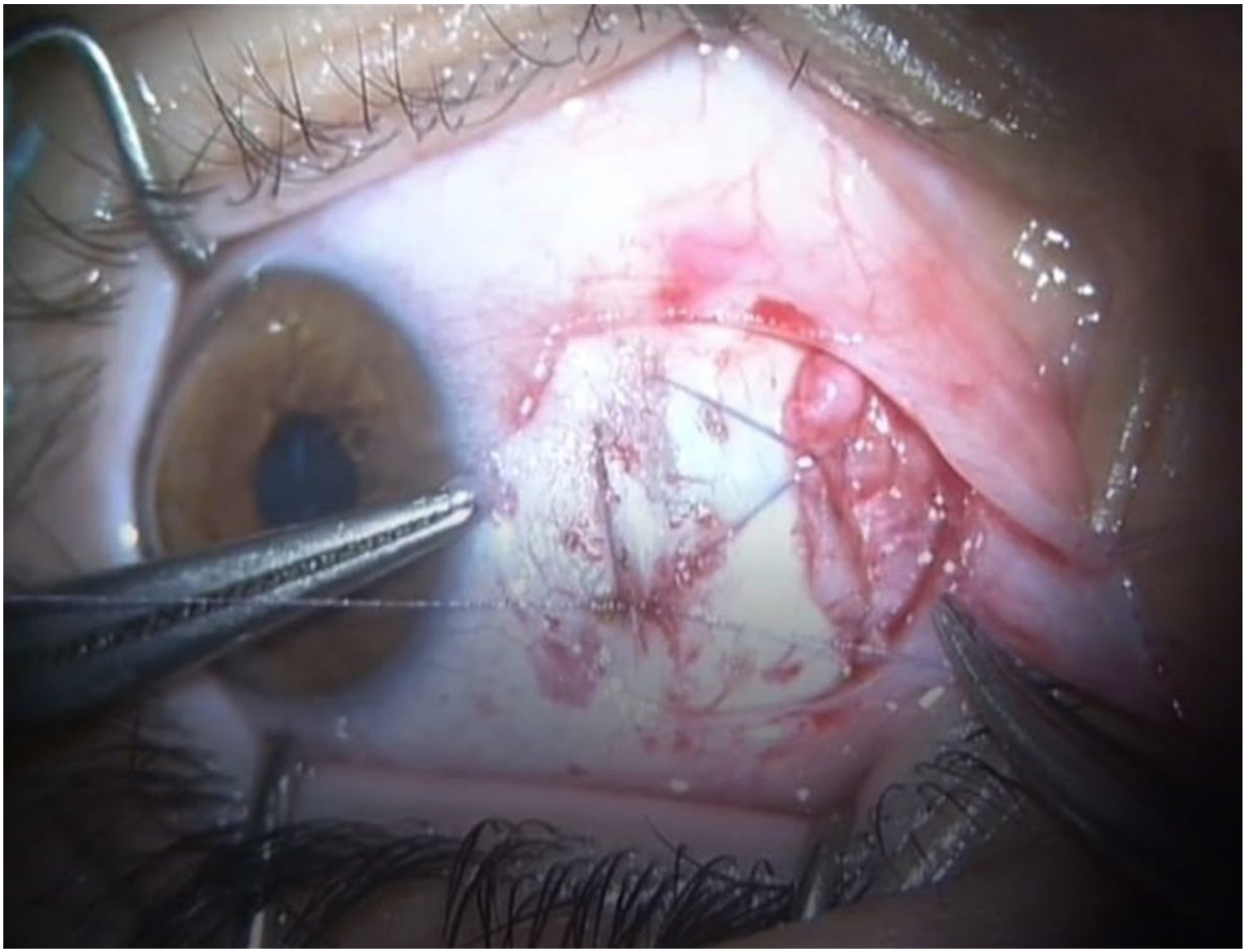

Figure 4

Hanging the muscle on the original insertion line