Modified Superior Inverted Internal Limiting Membrane Flap Technique With Vitrectomy Versus Vitrectomy With Internal Limiting Membrane Peeling For Retinal Detachment With Myopic Macular Hole

María José Crespo Carballés
Hospital Universitario Infanta Leonor

Marina Sastre-Ibáñez (marinasastre@yahoo.es)
Hospital Universitario Infanta Leonor https://orcid.org/0000-0003-0640-894X

Mar Prieto del Cura
Hospital Universitario Infanta Leonor

Laura Jimeno Anaya
Hospital Universitario Infanta Leonor

Natalia Pastora Salvador
Hospital Universitario Infanta Leonor

Simon Quijada Angelini
Hospital Universitario Infanta Leonor

Guadalupe Garrido Garrido Ceca
Hospital Universitario la Princesa

Maria Carmen García Saénz
Hospital Universitario Fundación Alcorcón

Research Article

Keywords: Macular hole, pathologic myopia, retinal detachment, pars plana vitrectomy, myopic macular hole

Posted Date: October 18th, 2021

DOI: https://doi.org/10.21203/rs.3.rs-913390/v1

Abstract

Purpose: To evaluate the efficacy of the modified superior inverted internal limiting (ILM) membrane flap technique in retinal reattachment, macular hole closure and external retinal layers restoration in macular hole associated retinal detachment compared to ILM peeling.

Methods: Retrospective case series of 10 patients that required pars plana vitrectomy for retinal detachment with macular hole followed for more than 12 months. Data from medical records were retrospectively collected and patients were divided into the superior inverted flap (5 patients) and ILM peeling group (5 patients). We compared best corrected visual acuity (BCVA) before and after surgery, retinal attachment, macular hole closure rate and external retinal layer restoration between groups.

Results: There were significant improvements in BCVA in both groups before and after surgery, with no differences between the two groups at 12 months after surgery (p = 0.9). The macular hole closed in 100% of cases in the inverted flap group and 80% of the ILM peeling group with no significant differences between groups. The retina was reattached in 100% of cases in both groups. Only 2 patients in the inverted flap group (40%) had external retinal layer restoration and none in ILM peeling group (p=0,62).

Conclusions: ILM peeling and superior inverted flap techniques are useful for treating retinal detachment with macular hole in myopic eyes.

Introduction

Macular hole with retinal detachment (MHRD) normally occurs in highly myopic eyes with posterior staphyloma [1,2]. It causes substantial visual impairment, and it is a challenging disease for vitreoretinal surgeons. Closure rates for MHRD after pars plana vitrectomy (PPV) are lower than for idiopathic MHs[3].

Different surgical approaches have been attempted to improve the success rate of surgery such as macular buckling4 and PPV with internal limiting membrane (ILM) peeling[5,6].

PPV with inverted ILM flap technique was first described by Michalewska et al. to treat idiopathic large MHs[7] and myopic MHs[8]. This technique for MHRD in myopic patients was associated with higher MH closure rates [3,9] and retinal re-attachment than ILM peeling but visual improvement is limited[9].

In this report, we describe in detail a modified ILM flap technique. We reviewed cases of highly myopic eyes with MHRD treated with this technique and those after vitrectomy with ILM peeling to determine anatomical and functional results.

Methods

We retrospectively reviewed patients' medical records who underwent PPV due to MHRD between 2014 and 2019 at Infanta Leonor University Hospital in Madrid.

The hospital's Institutional Review Board approved, and it adhered to the tenets of the Declaration of Helsinki. All patients provided written informed consent not only for the surgery but also for the use of data for future research studies.

High myopia was defined as axial length > 25mm. MHRD was diagnosed with a dilated slit-lamp binocular ophthalmoscopy and spectral domain optical coherence tomography (OCT) when possible.

The inclusion criteria were clinical presentation of MHRD, macular hole being the primary cause of the detachment, 18 years or older, and follow up period more than 12 months after surgery. Exclusion criteria were presence of choroidal neovascularization, proliferative vitreoretinopathy changes or trauma before the surgery.

Clinical information was collected from medical records. It included, age, sex, axial length, preoperative lens status, preoperative and postoperative best-corrected visual acuity (BCVA), lens status, operative variables including type of technique and type of tamponade, presence or absence of retina reattachment, MH closure (absence of neurosensory defect over the retina) and external retina preservation (EZ (ellipsoid zone) and external limiting membrane (ELM)).

BCVA was measured in decimal unit and converted to a of minimal angle of resolution (logMAR) logarithm for statistical analysis. Axial length was determined with A-scan ultrasonography (OPKO instrumentation, OTI-Scan 3000). In cases where the axial length measurement was artifactiously low, the error was corrected using a caliper to evaluate the distance from the cornea to the surface of the retinal pigment epithelium. Slit lamp examination of the posterior segment and OCT examinations centred on the fovea were performed at least 6 months after surgery in all patients.

Experienced vitreoretinal surgeons conducted all procedures. Standard phacoemulsification was performed before vitrectomy in those patients with associated cataract. All patients underwent 23-gauge vitrectomy with posterior vitreous detachment. The surgical posterior hyaloid detachment was performed with triamcinolone (2.5mh/ml) when needed. Membrane dual-blue was used in all cases for staining around the MH. If an epiretinal membrane was present, it was peeled. In all patients, air-fluid exchange was done, and the air was then replaced with non-expansive gas, either perfluoropropane (C3F8) or sulfur hexafluoride (SF6), or silicone oil (for patients who could not keep a prone position or severe cases).

To evaluate functional and anatomical results between the two techniques, the patients were divided into two groups based on the surgical procedure: PPV and ILM peeling, 5 eyes (group 1), and the superior inverted ILM flap and capsulorhexis technique,4 eyes (group 2).

Techniques:

Group 1: ILM within the arcades was completely removed after membrane staining. Group 2: after membrane staining a 360º ILM macular rhexis was done, leaving just a central flap about 2-disc diameters in size, attached to the retina. The flap was inverted to cover the MH from its superior margin. A small amount of PFC was introduced to keep the flap in position (Fig. 1).

Subretinal fluid was drained through an iatrogenic break outside the staphyloma. Slow fluid-air exchange and laser photocoagulation around the break was performed.

The statistical analysis was performed using SPSS (version 21.0) to analyse the differences in baseline characteristics, anatomical and functional outcomes between groups.

Two-sample t tests were used to calculate differences in age, axial length, pre and post logMAR visual acuity and improvement in logMAR VA between the 2 groups. The chi-square test (Fisher exact test if n < 5) was used to calculate differences between sex, lens status, MH closure rates and external retina preservation. A p-value of 0.05 was considered to represent a statistically significant difference.

Results

The study examined 10 eyes of 10 patients, 5 eyes in group 1 and 5 in group 2. Enrolled patients' characteristics are summarized in Table 1. The baseline characteristics between both groups were not significantly different between groups. The patient's characteristics are shown in Table 2 for both groups.

Table 1
Demographic, baseline characteristics and postoperative results.

	ILM FLAP/ group 1 (n = 4)	ILM peeling/group 2 (n = 5)	p
Age (± SD), years	64 ± 18,22	68,20 ± 10,35	0,66
Gender(%)	3 (60%)	1 (20%)	0,52
Male	2 (40%)	4 (80%)	
Female			
Mean axial length mm	28,722 ± 4,2	27,1 ± 2,3	0,47
Lens status (phakic/pseudophakic)	4/1	2/3	0,52
Pre-operative BCVA	2,1 ± 0,57	1.84 ± 0.63	0,516
LogMAR	0.015 ± 0.2	0.03 ± 0.04	0,417
Decimal			
BCVA 12months	0,98 ± 0,84	0.96 ± 0,65	0,968
LogMAR	0.21 ± 0,18	0,21 ± 0,23	0,991
Decimal			
Retina reattachment	100%	100%	
Macular hole closure, 12 months (n)	100% (5/5)	80% (4/5)	1
External retina preservation	40% (2/5)	0	0,44
BCVA improvement	-1,12 ± 0,74	-0,88 ± 0,73	0,62
**Data expressed as a number (%) of eyes.			
BCVA, best corrected visual acuity			
logMAR, logarithm of minimal angle of resolution.			

Table 2
Patient's characteristics for both groups

Patient No.	Age (years)	ILM flap	Axial length (mm)	Lens status	Preop BCVA Decimal	Surgical technique	Tamponade	Postop BCVA	MH closure 1 year
1	85	yes	27.49	Phakic	HM	Phaco + Vitrectomy	Silicone oil	HM	yes
2	77	yes	30.17	Phakic	CF	Phaco + Vitrectomy	SF6	0,2	yes
3	67	yes	25.2	Pseudophakic	0.05	Vitrectomy	SF6	0.4	yes
4	42	yes	35.38	Phakic	LP	Phaco + Vitrectomy	SF6	0,05	yes
5	49	yes	25.37	Phakic	HM	Vitrectomy	SF6	0,4	yes
6	74	no	25.17	Pseudophakic	HM	Vitrectomy	C3F8	CF	no
7	51	no	26.35	Phakic	HM	Phaco + Vitrectomy	SF6	0.6	yes
8	74	no	28.12	Phakic	0,1	Phaco + Vitrectomy	Silicone oil	0,2	yes
9	66	no	30.74	Phakic	HM	Phaco + Vitrectomy	Silicone oil	0,05	yes
10	76	no	25.15	Pseudophakic	0,05	Vitrectomy	C3F8	0.2	yes

HM:Hand motion; LP: Light perception; CF: Counting fingers; logMAR, logarithm of minimal angle of resolution.

BCVA improved after surgery in both groups but with no significant difference, p = 0.28 group 1 and p = 0.055 group 2 (paired t test).

Table 1 summarizes the anatomical postoperative outcomes. Postoperative OCT images are represented in Fig. 2 (group 1) and 3 (group 2). No holes re-opened during the follow-up period in cases with sealed MH after surgery in either group at 12 months.

Discussion

In this study, we describe a modified ILM flap and maculorhexis technique and compared it with ILM peeling for MHRD. Our study counts with limited number of patients and is difficult to draw conclusions. There were no significant differences between techniques in MH closure rate, RD attachment, external retina restoration or BCVA improvement.

MHRD have poor visual outcomes and anatomic prognosis, but an open MH poses the risk of retinal re-detachments, so we find it necessary to treat in many cases. ILM peeling releases some macular traction which may promote MH closure and retina re-attachment in MHRD. However, this technique achieves poor MH closure rates and visual outcomes [5,9]. For cases of MHRD in high myopia, ILM peeling might not release enough retinal tension for MH closure and ILM tucked in the MH may act as filler and scaffold. Kuriyama et al. [3] and Michalewska[10] reported that PPV with the inverted ILM flap technique for MHRD in myopic eyes achieved a high closure rate and successful anatomical outcome compared to ILM peeling. Most studies using this technique find that there is anatomical improvement, but functional results are limited for MHRD. [3,11,12,13] Iwasaki et al.[14] suggest that the inverted ILM flap

technique may impair the reconstruction of the outer retinal layer structures as the flap is placed in the MH and it could mechanically obstruct the recovery of the ELM and EZ during MH repair. ILM tissue plugging, used for ILM flap technique, entails a risk of excessive gliosis that may interrupt retinal microstructure restoration but may also have cytotoxic effects on retina.[15] Also, the cytotoxicity of vital dyes while introducing the dye-stained ILM tissue into the subretinal space could also be a limiting factor as it can damage retinal pigment epithelium (RPE) and the neurosensory retina.[16]

We propose another flap technique that may be more physiological for MH closure. It directly avoids insertion of the ILM inside the MH but places it on top; it can serve as scaffold limiting possible excessive gliosis. Also, the 360º maculorhexis releases tangential macular tractions completely. We used membrane dual-blue staining that causes less negative effect in the recovery of macular morphology and visual acuity after MH surgery. [17] Also, minimal manipulation in and around the hole that limits the possible RPE, retina and choroidal damage compared to conventional tucking of the ILM flap.

Restoration of ELM and EZ have better visual outcomes after surgery in normal eyes [18,19,20,21]. However, BCVA improvement is limited in myopic patients as it often coexists with, RPE and choroidal atrophy, which are irreversible. Also, in posterior staphylomas, macular hole develops without subjective symptoms and persists for a long time undetected until RD develops, and irreversible damage has already occurred before surgery. We found visual improvement in both groups after surgery without significant differences between them. Many studies don't find differences in postoperative BCVA between eyes with or without MH closure in MHRD [22,23]. The influence of the ILM flap technique on the ELM and EZ layer is still unknown. Hayashi et al. [24] performed PPV with inverted ILM flap technique for MHRD in myopic eyes and found that the procedure restores the inner segment and outer segment junction and ELM on OCT in only 17% of the eyes. This suggests that the foveal photoreceptor layer may not be recoverable although the retina is reattached after surgery with ILM flap. Our results support this idea as only one patient (25%) with the superior inverted flap technique and no one in the ILM peeling group had external retina restoration. This technique in MHRD may be helpful for MH and prevent retinal re-detachment rather than to improve visual outcomes.

This modified ILM flap technique has a concern, the potential flap displacement. An irregular retina with uneven surface contours such as myopic ones may facilitate the inverted ILM flap to move away from the hole during subsequent manipulations during fluid-air exchange. To avoid this possible complication, we use liquid perfluorocarbon on top of the superior inverted ILM flap before fluid-air exchange to ensure proper covering of the hole. Shin et al. [25] described this technique for large MHs. Moreover, we created a large-sized circular ILM flap which is normally more stable than small ones. We only lifted the superior hemicircle to position it on top of the MH; this position rather than the temporal one facilitates the intraoperative positioning of the flap after placing the perfluorocarbon. It lies in “favour to gravity” when the head is in the upright position postoperatively. This technique may be technically more difficult than conventional ILM flap and increases surgery time about 10 minutes.

There are several limitations to this stud; the main ones are the retrospective nature and the small number of cases.

Conclusion

In conclusion, this study showed that PPV with superior inverted ILM flap technique can be as useful as ILM peeling in MHRD. However, no advantage in the functional outcome was found in this study. To determine the actual benefits for postoperative outcomes, further prospective studies with a larger number of patients should be conducted.

Declarations

Funding

This research did not receive any specific grant from funding agencies in the public, commercial, or not-for-profit sectors.

Conflicts of interest/Competing interests: none

Availability of data and material : YES

Code availability : statistical analysis was performed using SPSS (version 21.0)

The manuscript has been read and approved by all authors

References

1. Morita H, Ideta H, Ito K, Yonemoto J, Sasaki T, Tanaka S (99) Causative factors of retinal detachment in macular holes. Retina :28-4
2. Akiba J, Konno S, Yoshida A (99) Retinal detachment associated with a macular hoe in severely myopic eyes. Am J Ophthalmol 28:654-5.
3. Kuriyama S, Hayashi H, Jingami Y, Kuramoto N, Akita J, Matsumoto M (203) Efficacy of Inverted Internal Limiting Membrane Flap Technique for the Treatment of Macular Hole in High Myopia. Am J Ophthalmol 56:25±3.
4. Ando F, Ohba N, Touura K, Hirose H (2007) Anatomical and visual outcomes after episcleral macular buckling compared with pars plana vitrectomy caused by macular hole in highly myopic eyes. Retina 27():37–44.
5. Ichibe M, Yoshizawa T, Murakami K, et al (2003) Surgical management of retinal detachment associated with myopic macular hole: anatomic and functional status of the macula. Am J Ophthalmol 36:277–84.
6. Uemoto R, Yamamoto S, Tsukahara I, Takeuchi S (2004) Efficacy of internal limiting membrane removal for retinal detachments resulting from a myopic macular hole. Retina 24:560–6.
7. Michalewska Z, Michalewski J, Adelman RA, Nawrocki J (200) Inverted internal limiting membrane flap technique for large macular holes. Ophthalmology 7:208–25.
8. Michalewska Z, Michalewski J, Dulczewska-Cichecka K, Nawrocki J (204) Inverted internal limiting membrane flap technique for surgical repair of myopic macular holes. Retina 34(4):664–669.
9. Matsumura T, Takamura Y, Tomomatsu T, Arimura S, Gozawa M, Kobori A, et al (206) Comparison of the Inverted Internal Limiting Membrane Flap Technique and the Internal Limiting Membrane Peeling for Macular Hole with Retinal Detachment. PLoS ONE (0): e065068.
10. Michalewska Z, Michalewska J, Dulczewska-Cichecha K, Nawrocki J (204) Inverted internal limiting membrane flap technique for surgical repair of myopic macular holes. Retina 34: 664–669.
11. Sasaki H, Shiono A, Kogo J, Yomoda R, Munemasa Y, Syoda M, Otake H, Kurihara H, Kitaoka Y, Takagi H (207) Inverted internal limiting membrane flap technique as a useful procedure for macular hole-associated retinal detachment in highly myopic eyes. Eye 3:545–550.
12. Baba R, Wakabayashi Y, Umazume K, Ishikawa T, Yagi H, Muramatsu D, Goto H (207) Efficacy of the inverted internal limiting membrane flap technique with vitrectomy for retinal detachment associated with myopic macular holes. Retina 37:466– 47.

13. Chen SN, Yang CM (206) Inverted Internal Limiting Membrane Insertion for Macular Hole–Associated Retinal Detachment in High Myopia. Am J Ophthalmol 62:99–06.
14. Iwasaki M, Kinoshita T, Miyamoto H, Imaizumi H (209) Influence of inverted internal limiting membrane flap technique on the outer retinal layer structures after a large macular hole surgery. Retina 39:470-577.
15. Bringmann A, Iandiev I, Pannicke T, Wurm A, Hollborn M, Wiedemann P, Osborne NN, Reichenbach A (2009) Cellular signaling and factors involved in Muller cell gliosis: neuroprotective and detrimental effects. Prog Retin Eye Res 28:423–45.
16. Sakamoto T, Itaya K, Noda Y, Ishibashi T (2002) Retinal pigment epithelial changes after indocyanine green-assisted vitrectomy. Retina 22: 794–796.
17. Baba T, Hagiwara A, Sato E, Arai M, Oshitari T, Yamamoto S (202) Comparison of vitrectomy with brilliant blue G or indocyanine green on retinal microstructure and function of eyes with macular hole. Ophthalmology 9: 2609–265.
18. Sano S, Shimada Y, Hashimoto H, et al (2009) Restored photoreceptor outer segment and visual recovery after macular hole closure. Am J Ophthalmol 47:33–38.
19. Inoue M, Watanabe Y, Arakawa A, et al (2009) Spectral domain optical coherence tomography images of inner outer segment junctions and macular hole surgery outcomes. Graefes Arch Clin Exp Ophthalmol 247:325–330.
20. Wakabayashi T, Fujiwara M, Sakaguchi H, et al (200)Foveal microstructure and visual acuity in surgically closed macular holes. Ophthalmology 7:85–824.
21. Oh J, Smiddy WE, Flynn HW, et al (200) Photoreceptor inner outer segment defect imaging by spectral domain OCT and visual prognosis after macular hole surgery. Invest Ophthalmol Vis Sci 5:65–658.
22. Nishimura A, Kimura M, Saito Y, et al (20) Efficacy of primary silicon oil tamponade for the treatment of retinal detachment caused by macular hole in high myopia. Am J Ophthalmol 5:48–55.
23. Nadal J, Verdaguer P, Maria I, et al (202) Treatment of retinal detachment secondary to macular hole in high myopia: vitrectomy with dissection of the internal limiting membrane to the edge of the staphyloma and long-term tamponade. Retina 92:525–530.
24. Hayashi H, Kuriyama S (204) Foveal microstructure in macular holes surgically closed by inverted internal limiting membrane flap technique. Retina 34:2444–2450.
25. Shin MK, Park KH, Park SW, Byon IS, Lee JE (204) Perfluoro-noctane- assisted single-layered inverted internal limiting membrane flap technique for macular hole surgery. Retina 34(9):905–90.

Figures

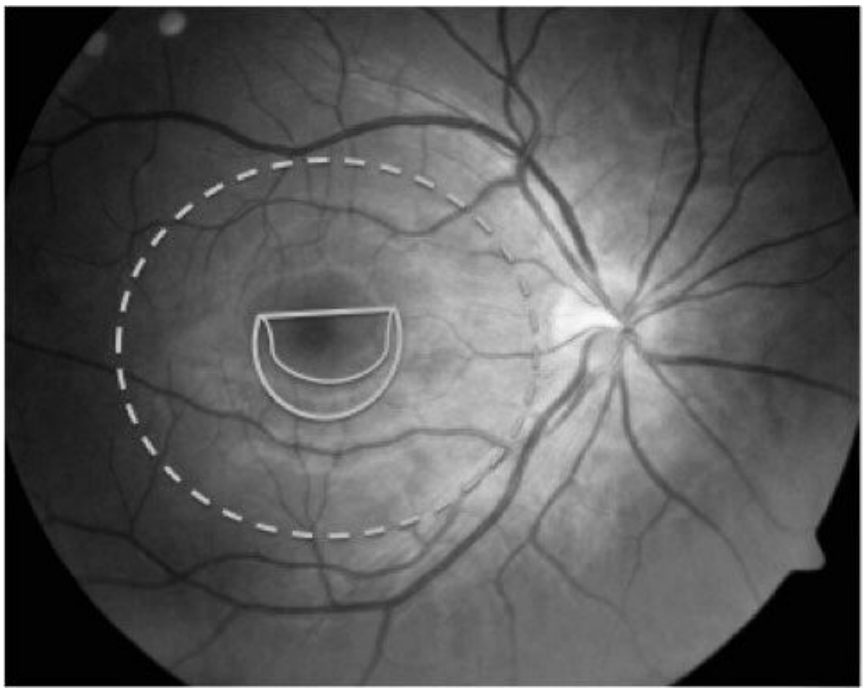

Figure 1

Schematic inverted superior flap technique.

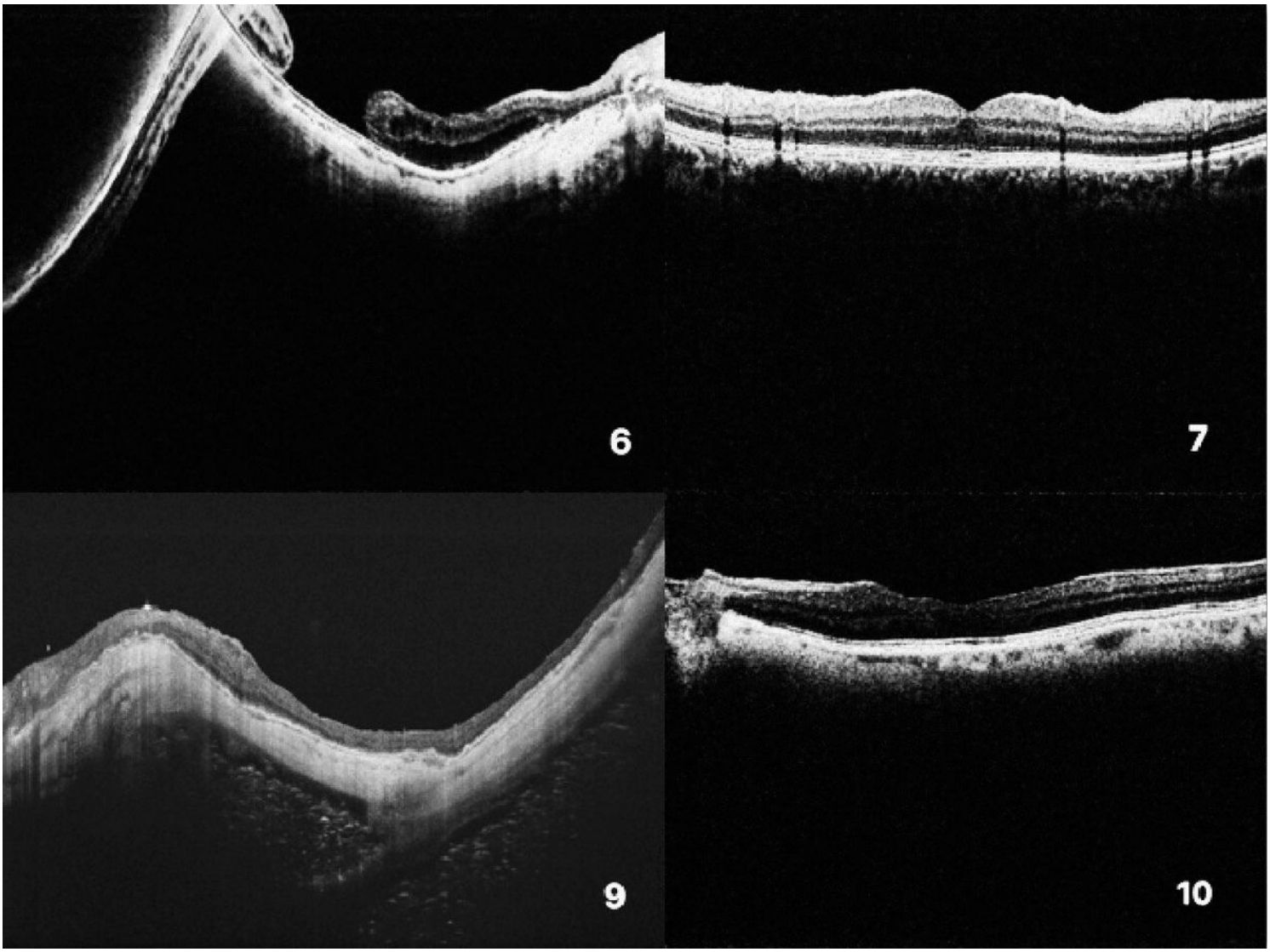

Figure 2

OCT images for patients in group 1/ ILM peeling (patient nº 6,7,9,10)

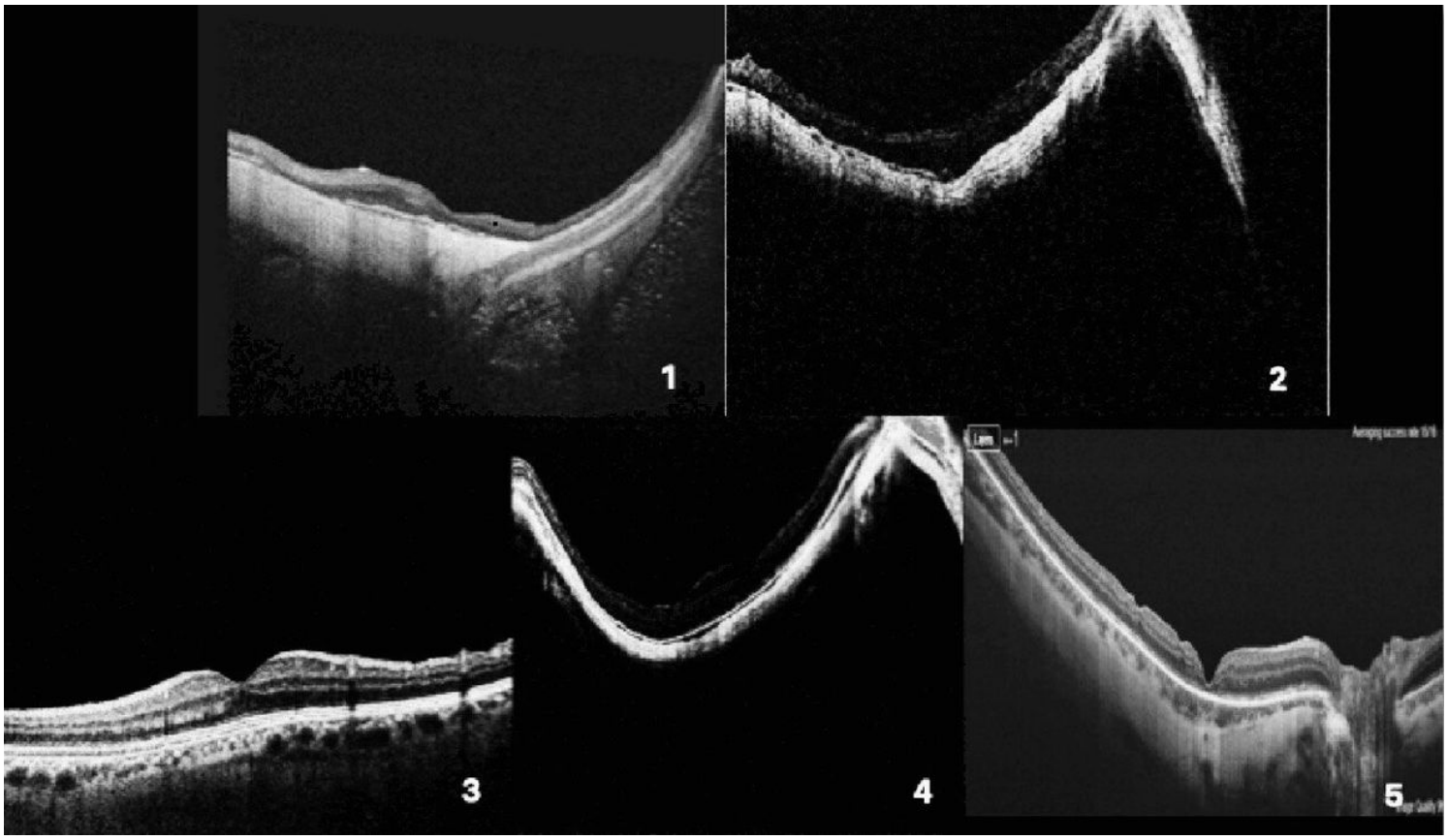

Figure 3

OCT images for patients in group 2/ ILM inverted superior flap (patient n°1,2,3,4,5)