Safety and Feasibility of the Transoral Endoscopic Thyroidectomy Vestibular Approach With Neuroprotection Techniques for Papillary Thyroid Carcinoma

Zhen-Xin Chen
The Second Affiliated Hospital of Guangzhou University of Chinese Medicine (Guangdong Provincial Hospital of TCM)

Ya-Min Song
The Second Affiliated Hospital of Guangzhou University of Chinese Medicine (Guangdong Provincial Hospital of TCM)

Jing-Bao Chen
The Second Affiliated Hospital of Guangzhou University of Chinese Medicine (Guangdong Provincial Hospital of TCM)

Xiao-Bo Zhang
The Second Affiliated Hospital of Guangzhou University of Chinese Medicine (Guangdong Provincial Hospital of TCM)

Feng-Shun Pang
The Second Affiliated Hospital of Guangzhou University of Chinese Medicine (Guangdong Provincial Hospital of TCM)

Zhan-Hong Lin
The Second Affiliated Hospital of Guangzhou University of Chinese Medicine (Guangdong Provincial Hospital of TCM)

Li-Ming Yang
The Second Affiliated Hospital of Guangzhou University of Chinese Medicine (Guangdong Provincial Hospital of TCM)

Bei-Yuan Cai
The Second Affiliated Hospital of Guangzhou University of Chinese Medicine (Guangdong Provincial Hospital of TCM)

You Qin (gzqinyou@163.com)
The Second Affiliated Hospital of Guangzhou University of Chinese Medicine (Guangdong Provincial Hospital of TCM)

Research Article

Keywords: TOETVA, PTC, Neuroprotection techniques, Safety, Feasibility

Posted Date: October 13th, 2021

DOI: https://doi.org/10.21203/rs.3.rs-916512/v1

Abstract

Background: This study aimed to evaluate the feasibility and safety of the trans-oral endoscopic thyroidectomy vestibular approach (TOETVA) with neuroprotection techniques for the surgical management of papillary thyroid carcinoma (PTC).

Methods: Patients with PTC who underwent TOETVA between December 2016 and July 2020 were included in this study, and their relevant clinical characteristics, operational details, and surgical outcomes were reviewed and extracted from their medical records for further analysis.

Results: A total of 75 patients successfully underwent TOETVA with zero conversions. Unilateral lobectomy with isthmectomy and total thyroidectomy were completed for 58 and 17 patients, respectively, all using our unique neuroprotective procedure and ipsilateral central neck dissection (CND). The mean number of retrieved lymph nodes versus positive lymph nodes was 6.8 ± 3.7 vs. 1.5 ± 2.3. Postoperative complications included three cases of transient superior laryngeal nerve (SLN) palsy (4.0%), five cases of transient recurrent laryngeal nerve (RLN) palsy (6.7%), 14 cases of transient hypoparathyroidism (18.7%), and two cases of lap perforation (2.7%). The follow-up period for patients with PTC lasted for 15.6 ± 10.9 months, during which no other complications or tumor recurrence were observed.

Conclusion: TOETVA can be safely performed for patients with PTC with satisfactory results during the short-term follow-up period. Our neuroprotection techniques can be integrated into TOETVA, which is worth recommending for PTC patients who desire better cosmetic surgical outcomes.

Introduction

The incidence rate of thyroid carcinoma has been increasing in recent years and the disease ranks fifth in malignancies among women [1]. Thyroidectomy with or without neck lymph node dissection is the preferred treatment for thyroid carcinoma. However, one of the biggest complaints about thyroidectomy, especially from female patients, is the significant scar along the lower neck. Thus, efforts to develop a better operational approach with better cosmetic outcomes remain active.

Since endoscopic surgery for the thyroid was first reported by Huscher et al in 1997 [2], several cosmesis-driven approaches have been applied in thyroidectomies to avoid neck scarring, including axillary, breast, and retroauricular approaches [3–5]. However, these remote-access approaches still leave scars and require extensive flap dissection before the thyroidectomy. More recently, with the zeal for natural origin transluminal endoscopic surgery [6], the first transoral endoscopic thyroidectomy was performed in living pigs in Germany in 2008 [7]. The technique was subsequently offered to patients as a trans-oral endoscopic thyroidectomy vestibular approach (TOETVA) procedure for thyroid disease with fewer complications. Since then, TOETVA has been highlighted as a non-scar minimally invasive surgery (MIS) among patients and surgeons because of no scar and less trauma [8].

Different groups have reported that compared to traditional surgery, TOETVA results in an insignificant difference in procedure-related complications but achieves outstanding cosmesis [9–12]. However, the procedure is limited to the treatment of benign thyroid tumors or Graves' disease in early practice [13–16]. Although a few sporadic studies on the application of TOETVA in papillary thyroid carcinoma (PTC) can be found in the literature [10, 11, 17–22], these studies included a relatively small number of patients. Thus, the promotion of TOETVA for the treatment of PTC requires more reliable data from more centers and practical methods to reduce complications.

As one of the most dreadful complications related to thyroid surgery, nerve injury seriously harms patients and reduces their quality of life. During the TOETVA procedure, the narrow operating space and difficulty exposing the superior thyroid increase the likelihood of nerve damage, which raises an urgent need for a standard method for neuroprotection during the procedure. Therefore, we designed the present study to evaluate the safety and feasibility of TOETVA for the treatment of patients with PTC and to provide information regarding our neuroprotection techniques during this novel thyroid resection procedure.

Materials And Methods

Patients

The clinical data for 75 patients with PTC who underwent TOETVA at our hospital from December 2016 to July 2020 were retrieved from the medical records of the patients and retrospectively assessed. The study protocol was approved by our Institutional Review Board for ethics. The inclusion criteria were as follows: (1) PTC was confirmed with fine needle aspiration or intra-operative exploration; and (2) the patient chose TOETVA willingly. The exclusion criteria were as follows: (1) evidence of distant metastasis; (2) lateral lymph nodes metastasis; (3) invasion of the surrounding tissues; (4) patient previously had surgery or radiation on the neck; (5) patient could not tolerate anesthesia or surgery; and (6) body mass index (BMI) greater than 40 kg/m^2.

Preoperative preparation for TOETVA

Patients were admitted to our hospital the day before surgery. Preoperative neck ultrasound and CT scans were performed to evaluate the tumor in the thyroid gland and the neck lymph node status. Gargle was provided to the patients the day before surgery, and prophylactic antibiotics (1st generation cephalosporin, Cefazolin sodium 2 g) were administered 30 min before surgery.

Surgical procedures

The TOETVA surgical standard technique was previously described by Wang and Anuwong [13, 16, 23, 24]. Three trocars (a 10-mm trocar at midline and two 5-mm trocars at the level of the first premolars) were inserted under the lower lip in the oral vestibular area (Fig. 1). After the operating space was created, the linea alba cervicalis was divided to expose the thyroid for dissection and resection. Following

thyroidectomy, central neck dissection (CND) was performed with forward dissection to the sternum and lateral dissection to the carotid artery (Fig. 2).

Some operational insights for neuroprotection during TOETVA are as follows: Firstly, enough operation space should be created using the sternocleidomastoid as the landmark for the lateral edge and the sternum as the landmark for the superior edge (Fig. 2). Secondly, before cutting off the superior pole of the thyroid, part of the sternothyroid should be routinely amputated to increase the visibility of the superior pole of the thyroid, and a nerve monitor should be used to monitor and protect the superior laryngeal nerve (SLN) (Fig. 3). To protect the recurrent laryngeal nerve (RLN), besides the use of a nerve monitor, we also recommend "tunnel" exploration at the larynx entry point using separating pliers (Fig. 4–5). In addition, a bipolar coagulation device is recommended for the resection of the thyroid at the larynx entry point, which may completely remove the thyroid and protect the RLN (Fig. 6).

Postoperative management and follow-up

A single additional intravenous dose of antibiotic was administered after surgery (1st generation cephalosporin, Cefazolin sodium 2 g) and the patients return to a normal diet 6 hours after surgery. The drainage tubes were removed when the post-operative drainage volume was less than 30 mL/day and the patient was discharged a day later. In addition, postoperative follow-up visits were scheduled at 1, 3, and 6 months, and annually thereafter. Hoarseness, low voice, cough, vocal cord function, parathyroid hormone (PTH) concentration, and other complications were assessed or measured as indications of the safety outcomes of TOETVA. The total number of lymph nodes removed, the number of positive central lymph nodes, and tumor recurrence were used as indicators for the feasibility and effectiveness of TOETVA. In this study, hypoparathyroidism was defined when the level of PTH was lower than the lower limit (11 pg/mL) of the normal range of the hormone [4]. Low voice and choking while drinking water were used as indicators for SLN injury, while hoarseness and vocal cord function reflected the status of RLN injury. If the injured nerve and parathyroid gland did not recover to preoperative normality after more than half a year, the injury was considered permanent.

Results

A total of 75 patients were included in this study and their detailed information is shown in Table 1. All 75 cases were overseen by one surgeon. The surgeon also performed TOETVA on a small number of patients with other diseases, but the data for these patients were incomplete and were not included in the statistics.

Table 1
Demographic characteristics of patients with PTC who underwent TOETVA.

Variables	Value
Age	36.8 ± 10.5 (20–65)
Sex (female/male)	66/9
BMI	22.3 ± 3.5 (15.8–34.3)
BMI ≥ 25	13
Operation type, n (%)	
Total thyroidectomy with CND	17 (22.7)
Lobectomy with CND	58 (77.3)
Tumor size (cm)	0.83 ± 0.66 (0.1–3.5)
Hospital stay (days)	3.8 ± 1.1 (2–8)
Drainage time (days)	2.8 ± 1.1 (1–7)
Blood loss (mL)	21.1 ± 17.3 (5-100)
Operation time (min)	140.1 ± 48.4 (65–295)
Retrieved lymph nodes	6.8 ± 3.9 (0–17)
Positive lymph nodes	1.5 ± 2.3 (0–11)

* PTC: papillary thyroid carcinoma, TOETVA: trans-oral endoscopic thyroidectomy vestibular approach, CND: central neck dissection.

Of 75 patients with PTC who underwent TOETVA, 66 patients were women and only nine were men. The mean age of the patients was 36.8 ± 10.5 years, with an age range from 20 to 65 years old and four patients over the age of 55 years. All patients successfully underwent TOETVA with zero conversions to open thyroidectomy. Moreover, 58 patients had unilateral lobectomy plus isthmectomy, and total thyroidectomies were performed for 17 patients. Ipsilateral CND was performed routinely.

Intraoperatively, the size of the resected tumor was 0.83 ± 0.66 cm with 6.8 ± 3.9 retrieved lymph nodes and 1.5 ± 2.3 positive lymph nodes. The mean operating time was 140.1 min, ranging from 65 to 295 min. The operating time for TOETVA for individual patients plotted in chronological sequence is shown in Fig. 7 as an indicator for the learning course. Blood loss ranged from 5 to 100 mL, with a mean volume of 21.1 mL.

Postoperatively, the mean length of hospital stay after the operation was 3.8 ± 1.1 days with a range of 2 to 8 days (Table 1). Transient SLN palsy and transient RLN palsy were found in three patients (4.0%) and

five patients (6.7%), respectively. Fourteen patients (18.7%) had transient hypoparathyroidism, and two patients (2.7%) had flap perforation. There was no case of permanent RLN palsy, permanent SLN palsy, or permanent hypoparathyroidism. Moreover, none of the patients had surgical site infection, aeroembolism, mental nerve injury, or secondary operation due to postoperative events. The mean follow-up period for the patients was 15.6 ± 10.9 months. During the follow-up visits, no other complications or tumor recurrence were found (Table 2).

Table 2
Postoperative complications of patients with PTC who underwent TOETVA.

Variables	Value
Transient superior laryngeal nerve palsy	3 (4%)
Transient recurrent laryngeal nerve palsy	5 (6.7%)
Transient hypoparathyroidism	14 (18.7%)
Flap perforation	2 (2.7%)
Permanent superior laryngeal nerve palsy	0
Permanent recurrent laryngeal nerve palsy	0
Permanent hypoparathyroidism	0
Surgical site infection	0
Aeroembolism	0
Lip tearing	0
Postoperative bleeding	0
Other complications[a]	0
[a] including carotid artery injury, lymphatic leakage, lip tearing, hematoma, tracheal injury, and esophageal injury.	
* PTC: papillary thyroid carcinoma, TOETVA: trans-oral endoscopic thyroidectomy vestibular approach	

Discussion

Endoscopic thyroidectomy (ESTC) has evolved steadily over the last 20 years, and the improvements in cosmesis and quality of life make it a popular choice for young patients. With the emergence of TOETVA, the cosmetic effects of thyroid surgery have been further optimized and the disadvantages of large trauma in ESTC have been minimized. However, the promotion of TOETVA for the treatment of PTC requires more clinical data and operational experience sharing. In this study, we evaluated the safety and feasibility of TOETVA for PTC.

Regarding the safety of TOETVA, the main concern for surgeons is the protection of nerves. To better protect the nerves during the dissection of the thyroid gland, some technical points need to be addressed. During TOETVA, difficulties are routinely encountered in exposing the superior pole of the thyroid, increasing the probability of SLN injury. Partial sternothyroid amputation does not normally affect the quality of life of patients but is conducive to the successful exposure and protection of the SLN. Additionally, the RLN is usually located at the larynx entry point; therefore, "tunnel" exploration is recommended at the larynx entry point through the use of separating pliers for quick and accurate identification of the RLN. Furthermore, the thyroid closely approximates the RLN at the larynx entry point; thus, bipolar electrocoagulation is recommended for complete resection of the thyroid at the larynx entry point and to protect the RLN. Using these neuroprotection techniques, transient SLN palsy and transient RLN palsy only occurred in three (4.0%) and five patients (6.7%) in this study, respectively. The probability of temporary nerve injury in this study was similar to that in other reports on open surgery [25–29]. More importantly, permanent nerve injury did not occur in the present study.

We used the extent of CND to evaluate the feasibility of TOETVA for the treatment of PTC. The boundary for CND was marked with forward dissection to the sternum and lateral dissection to the carotid artery. The number of lymph nodes removed with TOETVA in this study was 6.8 ± 3.9, which was no less than that in open surgery [10], and no tumor recurrence was found during the follow-up period, suggesting that TOETVA is effective for CND. As another parameter, the operating time for TOETVA, which was reported in previous studies to be significantly longer than that in open surgery [9], was used to judge the feasibility of the procedure. In this study, although the average operating time was 140 minutes, the time gradually decreased with consecutive TOETVA operations (Fig. 7), demonstrating that the operating time can be reduced with the improvement of surgical proficiency through more experience.

In this study, the average tumor size removed with TOETVA was only 0.83 ± 0.66 cm, mainly because TOETVA was offered to patients with tumors smaller than 2 cm during the preoperative imaging workup. Four patients who had tumors larger than 2 cm in this study demanded TOETVA despite dissuasion from the surgeon. Factually, the tumor size determined with postoperative pathology is often smaller than that determined with preoperative ultrasound in our center.

There are several caveats related to the TOETVA procedure. Firstly, the operating space for TOETVA is quite narrow at the beginning of the operation and may suitably accommodate the electric hook due to its small size and flexibility. We believe that reasonable use of an electric hook, especially the electric cutting function, will help expedite the process of initial space establishment in TOETVA. Secondly, carbon nanoparticles can be injected into the inferior pole of the thyroid in order to solve the problem of finding the inferior parathyroid gland. Thirdly, because of the surgical difficulties and complications, TOETVA should be performed by a surgeon with extensive experience in ESTC. Beginners should strictly follow the standard operating procedures and be familiar with neuroprotection techniques. Despite the fact that our surgeon had completed more than 1000 cases of ESTC over a period of more than 10 years, the mean operating time for TOETVA was around 140 min, which is still much longer than that of open surgery.

The limitations of the study are as follows: First, the clinical data for the patients who underwent open surgery were not included in this study as a comparable reference to improve the level of evidence. Secondly, the mean follow-up period for patients with PTC was only 15.6 ± 10.9 months, which is too short to draw conclusions regarding the effectiveness of TOETVA in the treatment of PTC.

In summary, based on our operational savvy on neuroprotection, we believe that the safety and short-term clinical outcomes for TOETVA are comparable to those of open surgery in our hands. However, whether TOETVA can be upheld as one of the choices for PTC should be further tested and verified with well-designed clinical trials. For now, the TOETVA procedure should be performed on carefully selected patients by experienced surgical endoscopists.

List Of Abbreviations

transoral endoscopic thyroidectomy vestibular approach (TOETVA)

papillary thyroid cancer (PTC)

central neck dissection (CND)

endoscopic thyroidectomy (ESTC)

recurrent laryngeal nerve (RLN)

superior laryngeal nerve (SLN)

parathyroid hormone (PTH)

Declarations

Ethics approval and consent to participate

The study protocol was approved by the Institutional Review Board for ethics at the Guangdong Provincial Hospital of Traditional Chinese Medicine. The research reported in this paper was in compliance with the Helsinki Declaration. Consent to participate was given by all patients.

Consent for publication

Written consent to participate included permission to access specimens and clinical details, and to publish findings.

Availability of data and materials

The datasets used and/or analysed during the current study are available from the corresponding author on reasonable request.

Competing interests

The authors declare no competing interest.

Funding

None.

Contributions

ZXC, YMS and YQ designed the concept of this study. JBC, XBZ, FSP, ZHL, LMY and BYC collected the datasets. ZXC and YMS analyzed the data and wrote the manuscript. YQ revised the manuscript. All authors have read and approved the manuscript.

Acknowledgments

The authors thank Medjaden Bioscience Limited for linguistic revision of the manuscript.

References

1. Bray F, Ferlay J, Soerjomataram I, Siegel RL, Torre LA, Jemal A: **Global cancer statistics 2018: GLOBOCAN estimates of incidence and mortality worldwide for 36 cancers in 185 countries**. *CA Cancer J Clin* 2018, **68**(6):394-424.
2. Huscher CS, Chiodini S, Napolitano C, Recher A: **Endoscopic right thyroid lobectomy**. *Surg Endosc* 1997, **11**(8):877.
3. Ikeda Y, Takami H, Sasaki Y, Kan S, Niimi M: **Endoscopic resection of thyroid tumors by the axillary approach**. *J Cardiovasc Surg (Torino)* 2000, **41**(5):791-792.
4. Byeon HK, Holsinger FC, Tufano RP, Chung HJ, Kim WS, Koh YW, Choi EC: **Robotic total thyroidectomy with modified radical neck dissection via unilateral retroauricular approach**. *Ann Surg Oncol* 2014, **21**(12):3872-3875.
5. Ohgami M, Ishii S, Arisawa Y, Ohmori T, Noga K, Furukawa T, Kitajima M: **Scarless endoscopic thyroidectomy: breast approach for better cosmesis**. *Surg Laparosc Endosc Percutan Tech* 2000, **10**(1):1-4.
6. Kalloo AN, Singh VK, Jagannath SB, Niiyama H, Hill SL, Vaughn CA, Magee CA, Kantsevoy SV: **Flexible transgastric peritoneoscopy: a novel approach to diagnostic and therapeutic interventions in the peritoneal cavity**. *Gastrointest Endosc* 2004, **60**(1):114-117.
7. Witzel K, von Rahden BH, Kaminski C, Stein HJ: **Transoral access for endoscopic thyroid resection**. *Surg Endosc* 2008, **22**(8):1871-1875.
8. Jongekkasit I, Jitpratoom P, Sasanakietkul T, Anuwong A: **Transoral Endoscopic Thyroidectomy for Thyroid Cancer**. *Endocrinol Metab Clin North Am* 2019, **48**(1):165-180.

9. Wang Y, Zhou S, Liu X, Rui S, Li Z, Zhu J, Wei T: **Transoral endoscopic thyroidectomy vestibular approach vs conventional open thyroidectomy: Meta-analysis**. *Head Neck* 2021, **43**(1):345-353.
10. Sun H, Zheng H, Wang X, Zeng Q, Wang P, Wang Y: **Comparison of transoral endoscopic thyroidectomy vestibular approach, total endoscopic thyroidectomy via areola approach, and conventional open thyroidectomy: a retrospective analysis of safety, trauma, and feasibility of central neck dissection in the treatment of papillary thyroid carcinoma**. *Surg Endosc* 2020, **34**(1):268-274.
11. Liu ZD, Li YJ, Yu X, Xiang C, Wang P, Wang Y: **[A comparative study on the efficacy of transoral vestibular approach, via bilateral areola approach endoscopic and open thyroidectomy on stage T1b papillary thyroid carcinoma]**. *Zhonghua Er Bi Yan Hou Tou Jing Wai Ke Za Zhi* 2020, **55**(10):905-912.
12. Jitpratoom P, Ketwong K, Sasanakietkul T, Anuwong A: **Transoral endoscopic thyroidectomy vestibular approach (TOETVA) for Graves' disease: a comparison of surgical results with open thyroidectomy**. *Gland Surg* 2016, **5**(6):546-552.
13. Anuwong A: **Transoral Endoscopic Thyroidectomy Vestibular Approach: A Series of the First 60 Human Cases**. *World J Surg* 2016, **40**(3):491-497.
14. Udelsman R, Anuwong A, Oprea AD, Rhodes A, Prasad M, Sansone M, Brooks C, Donovan PI, Jannitto C, Carling T: **Trans-oral Vestibular Endocrine Surgery: A New Technique in the United States**. *Ann Surg* 2016, **264**(6):e13-e16.
15. Wang Y, Yu X, Wang P, Miao C, Xie Q, Yan H, Zhao Q, Zhang M, Xiang C: **Implementation of Intraoperative Neuromonitoring for Transoral Endoscopic Thyroid Surgery: A Preliminary Report**. *J Laparoendosc Adv Surg Tech A* 2016, **26**(12):965-971.
16. Anuwong A, Ketwong K, Jitpratoom P, Sasanakietkul T, Duh QY: **Safety and Outcomes of the Transoral Endoscopic Thyroidectomy Vestibular Approach**. *JAMA Surg* 2018, **153**(1):21-27.
17. Nguyen HX, Nguyen HX, Nguyen HV, Nguyen LT, Nguyen TTP, Le QV: **Transoral Endoscopic Thyroidectomy by Vestibular Approach with Central Lymph Node Dissection for Thyroid Microcarcinoma**. *J Laparoendosc Adv Surg Tech A* 2020.
18. Luna-Ortiz K, Gomez-Pedraza A, Anuwong A: **Lessons Learned from the Transoral Endoscopic Thyroidectomy with Vestibular Approach (TOETVA) for the Treatment of Thyroid Carcinoma**. *Ann Surg Oncol* 2020, **27**(5):1356-1360.
19. Kim SY, Kim SM, Makay O, Chang H, Kim BW, Lee YS, Park CS, Chang HS: **Transoral endoscopic thyroidectomy using the vestibular approach with an endoscopic retractor in thyroid cancer: experience with the first 132 patients**. *Surg Endosc* 2020, **34**(12):5414-5420.
20. Ahn JH, Yi JW: **Transoral endoscopic thyroidectomy for thyroid carcinoma: outcomes and surgical completeness in 150 single-surgeon cases**. *Surg Endosc* 2020, **34**(2):861-867.
21. Xu Z, Song J, Wang Y, Tan L, Sun S, Meng Y: **A comparison of transoral vestibular and bilateral areolar endoscopic thyroidectomy approaches for unilateral papillary thyroid microcarcinomas**. *Wideochir Inne Tech Maloinwazyjne* 2019, **14**(4):501-508.

22. Chai YJ, Chung JK, Anuwong A, Dionigi G, Kim HY, Hwang KT, Heo SC, Yi KH, Lee KE: **Transoral endoscopic thyroidectomy for papillary thyroid microcarcinoma: initial experience of a single surgeon**. *Ann Surg Treat Res* 2017, **93**(2):70-75.
23. Wang C, Zhai H, Liu W, Li J, Yang J, Hu Y, Huang J, Yang W, Pan Y, Ding H: **Thyroidectomy: a novel endoscopic oral vestibular approach**. *Surgery* 2014, **155**(1):33-38.
24. Anuwong A, Sasanakietkul T, Jitpratoom P, Ketwong K, Kim HY, Dionigi G, Richmon JD: **Transoral endoscopic thyroidectomy vestibular approach (TOETVA): indications, techniques and results**. *Surg Endosc* 2018, **32**(1):456-465.
25. Ravikumar K, Sadacharan D, Muthukumar S, Mohanpriya G, Hussain Z, Suresh RV: **EBSLN and Factors Influencing its Identification and its Safety in Patients Undergoing Total Thyroidectomy: A Study of 456 Cases**. *World J Surg* 2016, **40**(3):545-550.
26. Barczynski M, Konturek A, Stopa M, Honowska A, Nowak W: **Randomized controlled trial of visualization versus neuromonitoring of the external branch of the superior laryngeal nerve during thyroidectomy**. *World J Surg* 2012, **36**(6):1340-1347.
27. Barczynski M, Randolph GW, Cernea CR, Dralle H, Dionigi G, Alesina PF, Mihai R, Finck C, Lombardi D, Hartl DM *et al*: **External branch of the superior laryngeal nerve monitoring during thyroid and parathyroid surgery: International Neural Monitoring Study Group standards guideline statement**. *Laryngoscope* 2013, **123 Suppl 4**:S1-14.
28. Jeannon JP, Orabi AA, Bruch GA, Abdalsalam HA, Simo R: **Diagnosis of recurrent laryngeal nerve palsy after thyroidectomy: a systematic review**. *Int J Clin Pract* 2009, **63**(4):624-629.
29. Lo CY, Kwok KF, Yuen PW: **A prospective evaluation of recurrent laryngeal nerve paralysis during thyroidectomy**. *Arch Surg* 2000, **135**(2):204-207.

Figures

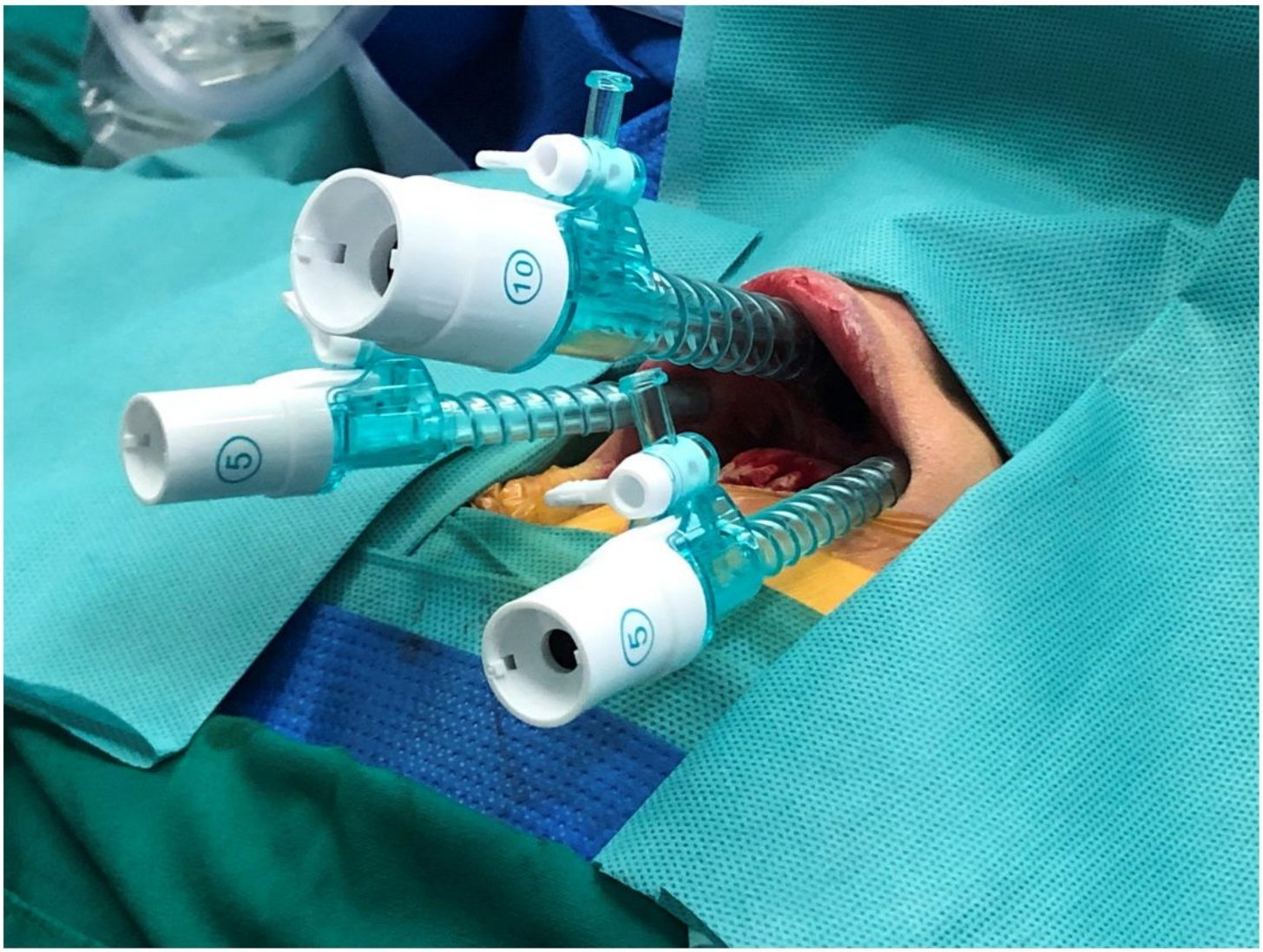

Figure 1

Trocar placement for TOETVA

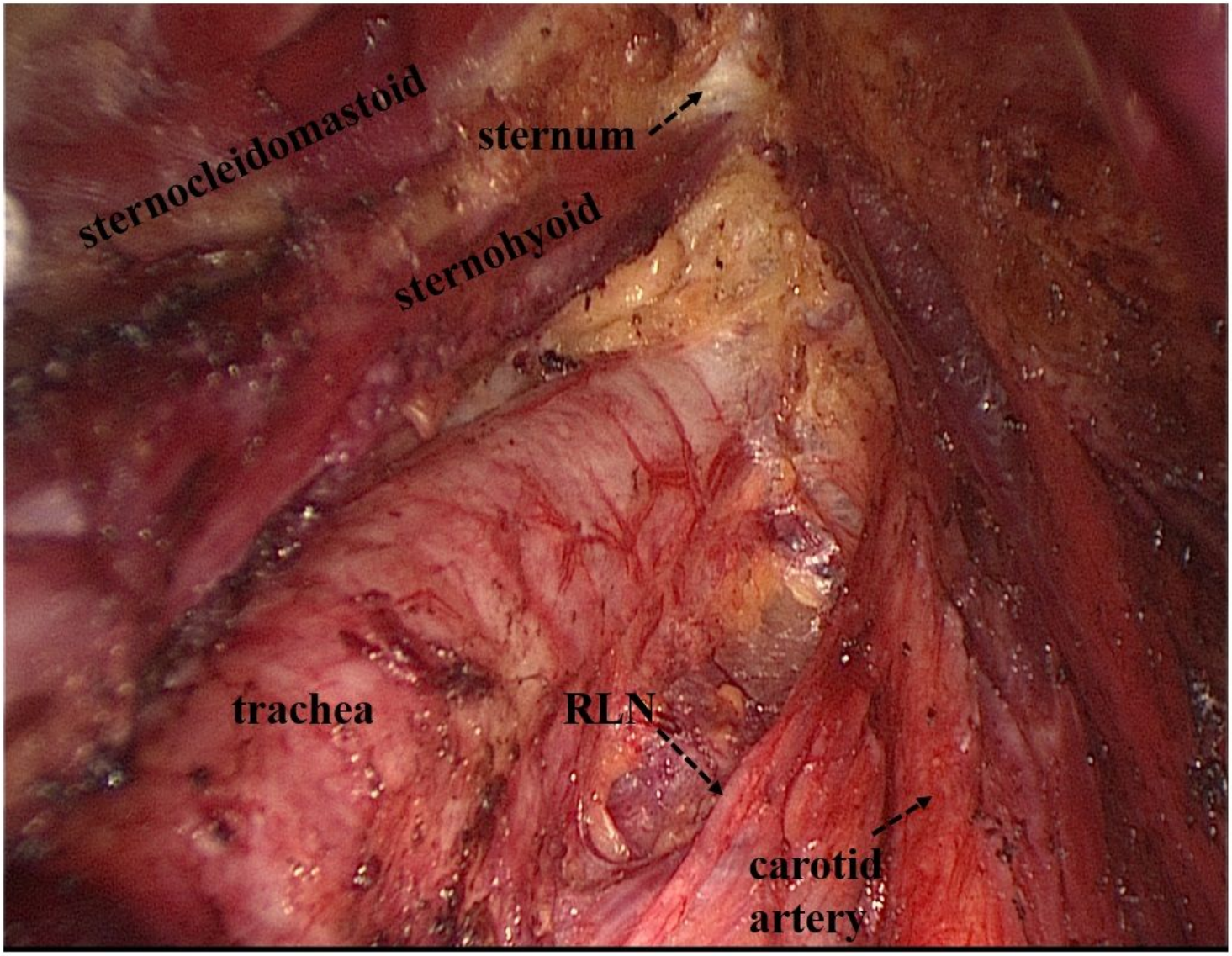

Figure 2

Boundaries of operating space for central neck dissection.

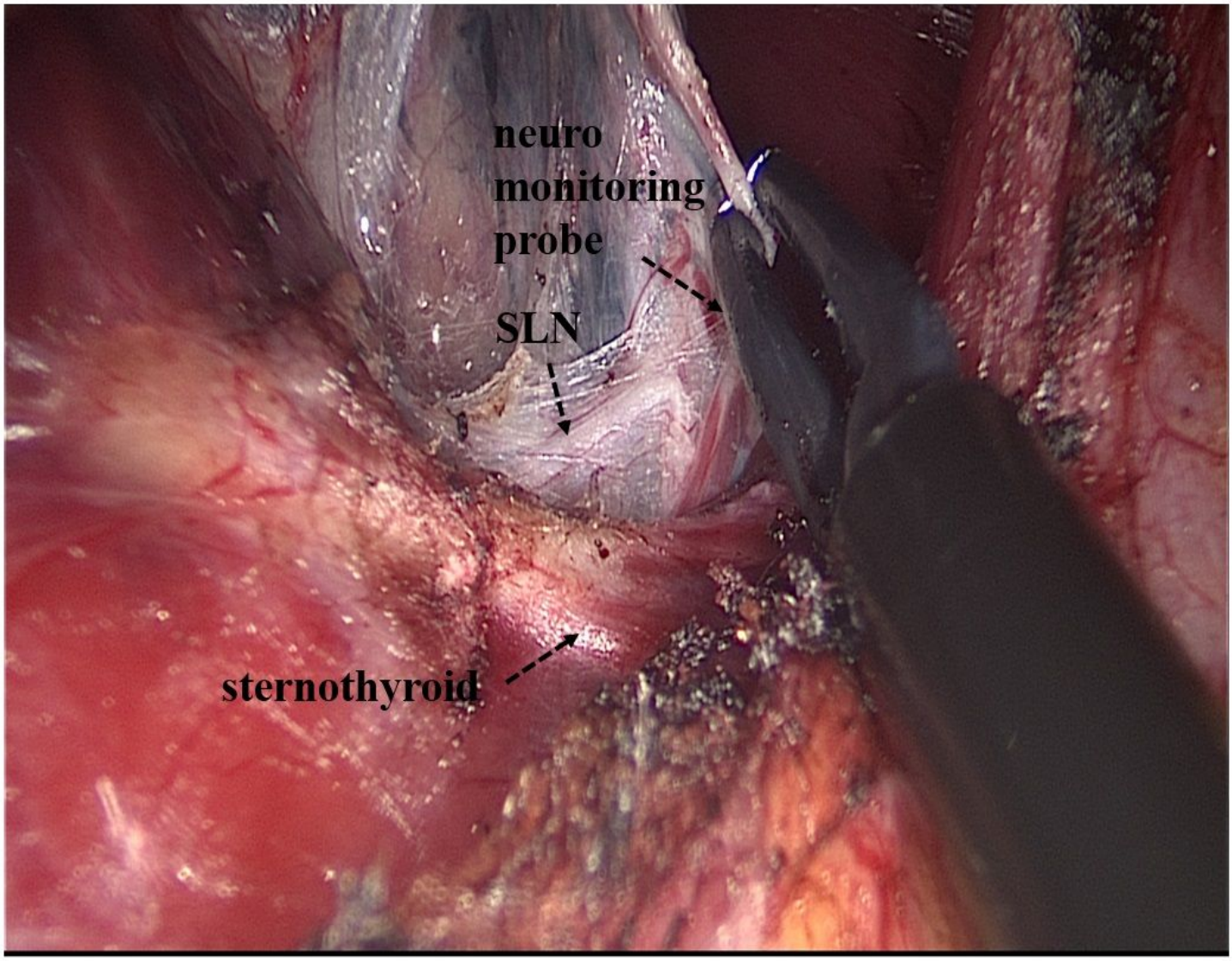

Figure 3

Amputation of sternothyroid to expose superior laryngeal nerve.

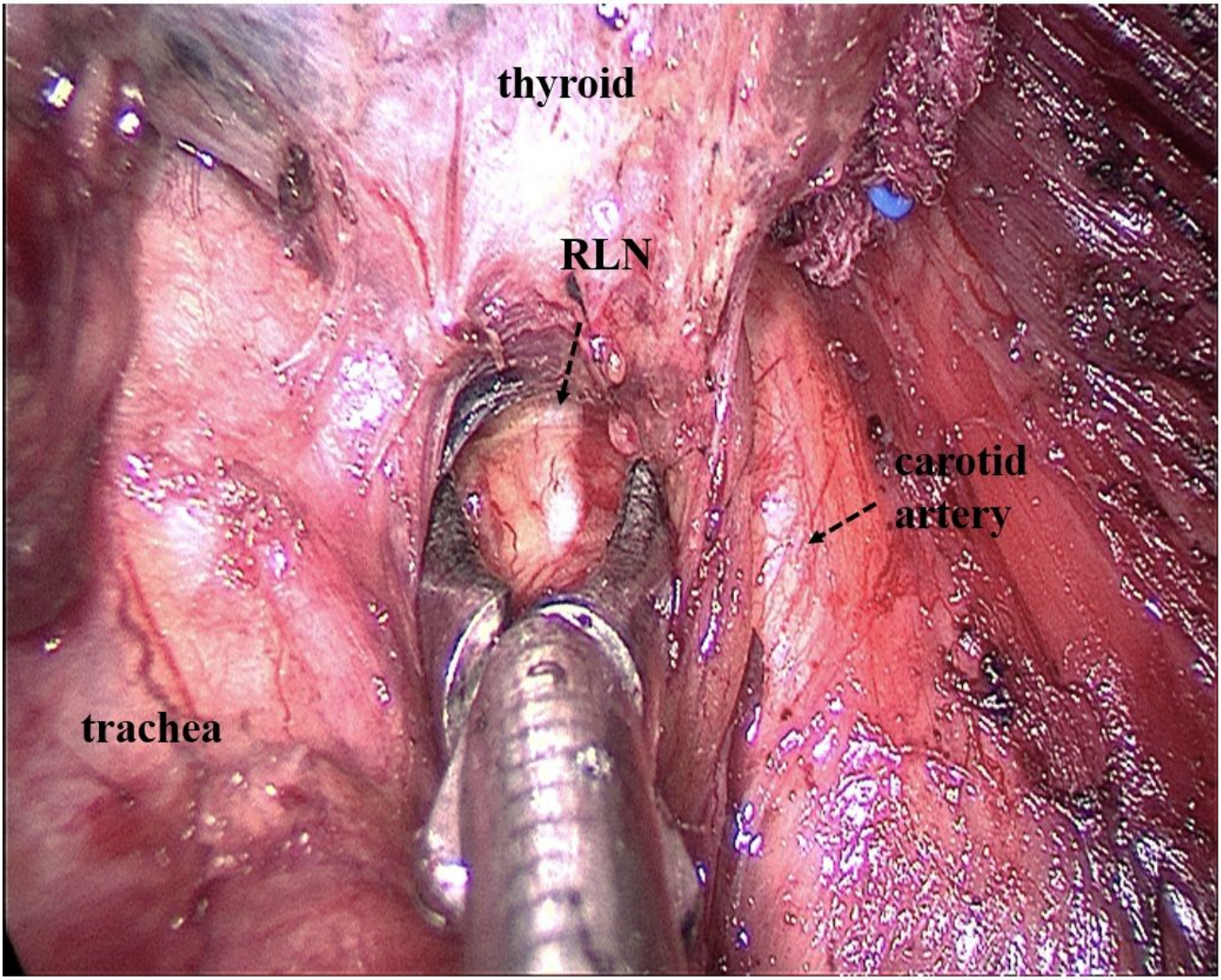

Figure 4

Using "tunnel" exploration at the larynx entry point to protect the recurrent laryngeal nerve.

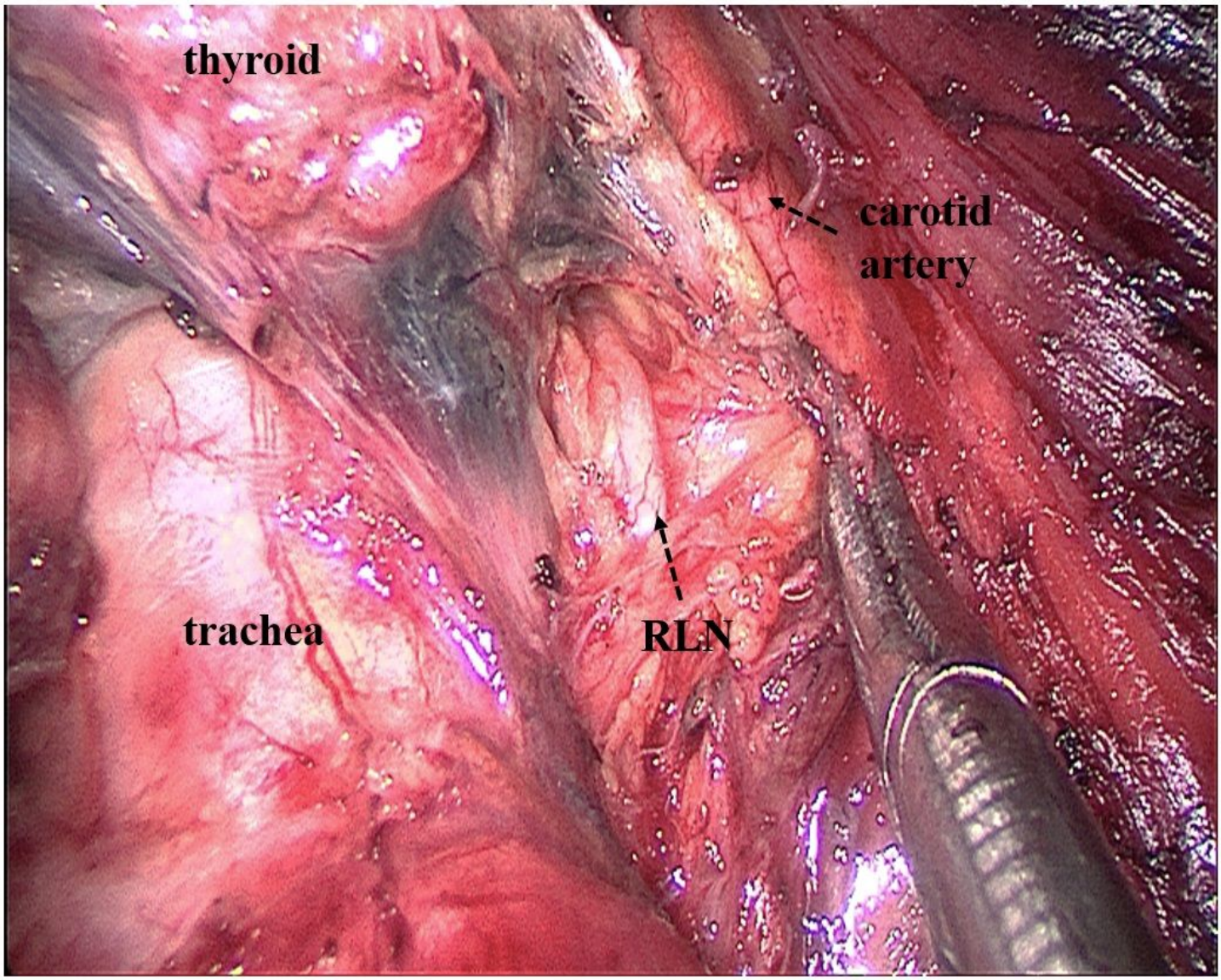

Figure 5

Exposing the recurrent laryngeal nerve from top to bottom.

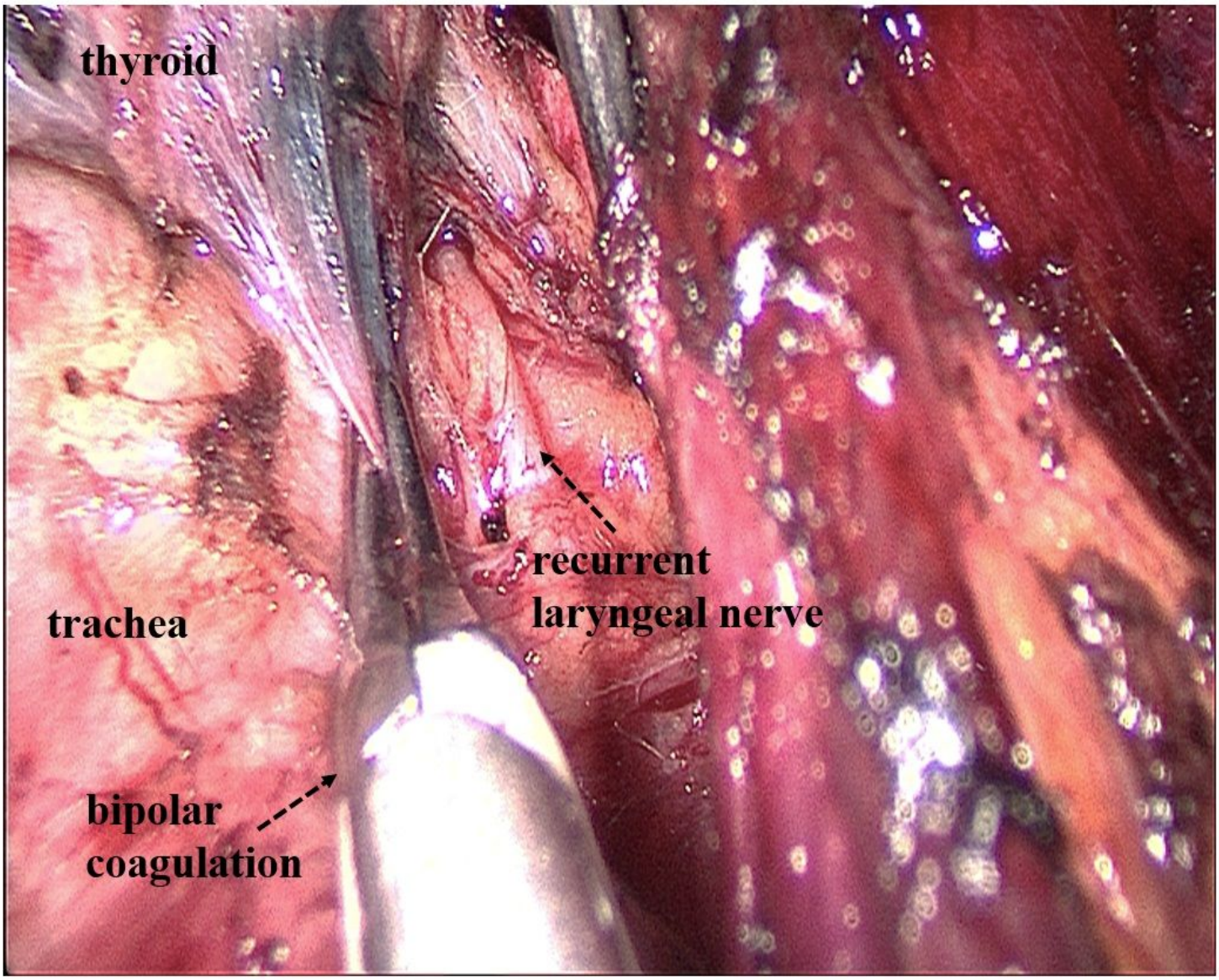

Figure 6

Using bipolar coagulation to resect the thyroid at the larynx entry point.

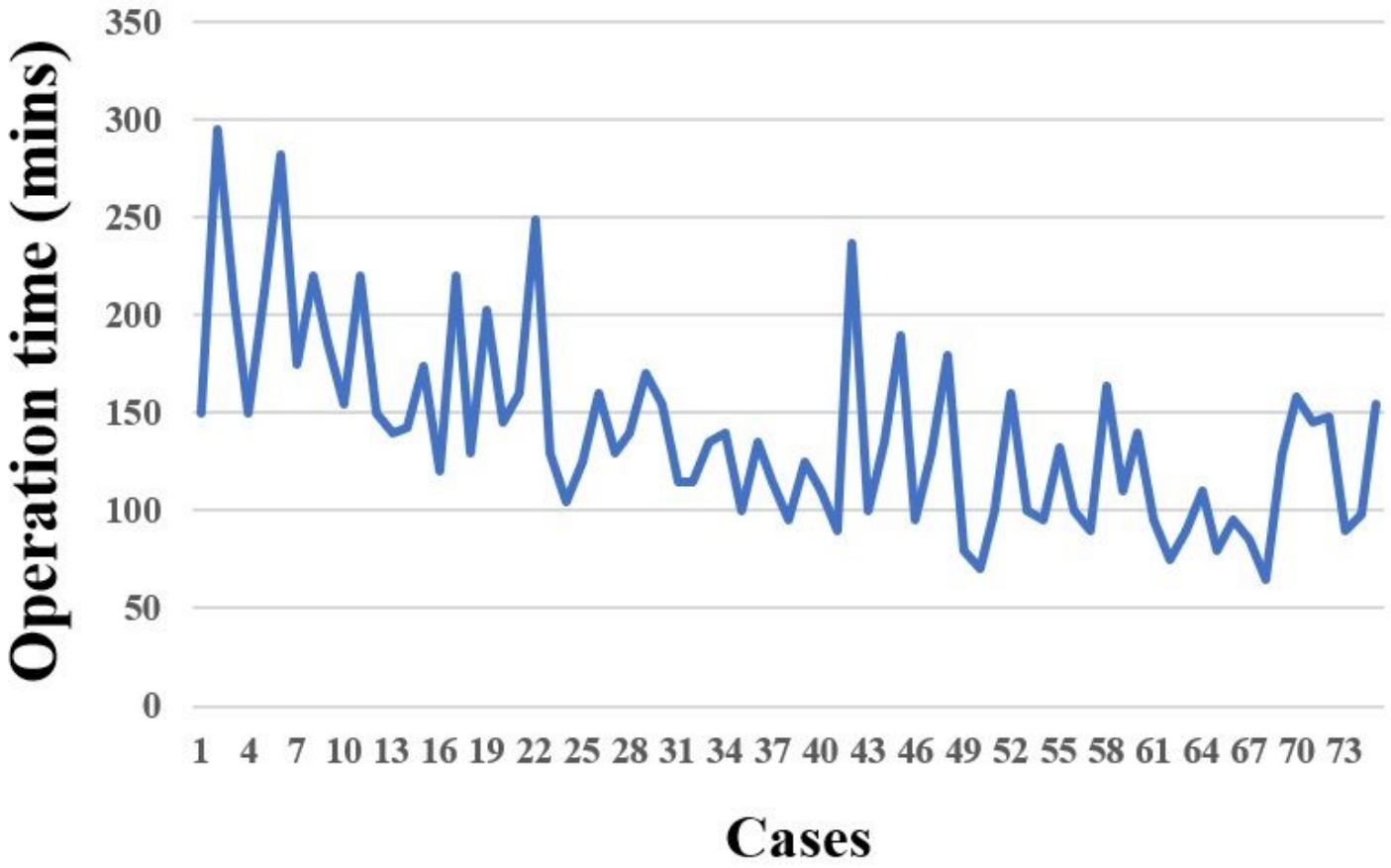

Figure 7

Changes in operating time (mins) for each case. Note: A total of 75 patients in this study, including 17 patients who underwent total thyroidectomy, and the operation time of these patients was longer than the patients who underwent unilateral lobectomy with isthmectomy.