The modified cross-suture technique for unilateral pulled-out anchor during all-inside meniscal repair

Jianlong Ni
Xi'an Jiaotong University
Zhibin Shi
Xi'an Jiaotong University
Lihong Fan
Xi'an Jiaotong University
Ning Guo
Xi'an Jiaotong University
Haoyu Wang
Xi'an Jiaotong University
Xiaoqian Dang
Xi'an Jiaotong University
Dichen Li (nijianlong11@163.com)
Xi'an Jiaotong University

Research article

Keywords: meniscus injury, arthroscopy, all-inside repair, cross-suture

Posted Date: December 12th, 2019

DOI: https://doi.org/10.21203/rs.2.18592/v1

Version of Record: A version of this preprint was published on July 22nd, 2020. See the published version at https://doi.org/10.1186/s12891-020-03502-z.

Abstract

Background: In consideration of meniscal repair has received increasingly more attention, but for inexperienced doctors, various technical errors may occur when meniscal suture repair is performed, particularly during all-inside meniscal suture repairing. When the errors is happened intraoperatively, how to minimize the loss under the effectiveness of treatment is a topic worth studying.

Methods: From May 2014 to May 2017, 28 cases diagnosed with injures of meniscus and anterior cruciate ligaments were enrolled in the study as observation group. All cases underwent anterior cruciate ligament (ACL) reconstruction concurrently. All meniscus injuries were repaired with an all-inside meniscal repair technique, and 1-3 needles of unilateral suture anchor pulling out occurred intraoperatively. The method of modified cross-suture was used to remedy the error of anchor pulling out and to eventually complete the effective repair. During postoperative follow-up, the range of motion, Lachman test and pivot shift test were confirmed by physical examination. The clinical healing of meniscus was evaluated according to the Barrett standard. Meniscus healing status was also confirmed with magnetic resonance imaging (MRI). The function of the knee joint was evaluated with the IKDC, Lysholm and Tegner scores.

Results: 25 cases of observation group and 28 cases of control group received complete follow-up with an average follow-up of 18.4±5.2 months. All operations were finished by the same surgeon. At the follow-up one year after operation, the average knee ROM of two groups were 125.2±4.3 degrees and 124.7±3.8 degrees, the clinical healing rate of the meniscus of two groups were 92.0% (23/25) and 92.9% (26/28), the MRI healing rate of the menniscus of two groups were 72.0% (18/25) and 71.4% (20/28), the IKDC, Lysholm and Tegner scores of two groups were 90.52±2.8, 89.17±3.1, 6.81±1.7 and 91.42±1.9, 90.32±3.4, 7.02±1.4, the differences were not statistically significant (P>0.05).

Conclusions: The method of modified cross-suture is effective for arthroscopic remediation for unilateral suture anchor pulling out of an all-inside meniscal repair system.

Background

Meniscus injury is a kind of common and frequent sports injury, and its treatment should maintain the integrity of the meniscal structure and function as much as possible; therefore, meniscal repair has received increasingly more attention[1–4]. With the development of the arthroscopic technique and the popularity of the concept of preserving meniscal function, a growing number of doctors began to carry out arthroscopic meniscal suture repair operation[5–7]; however, as a result of inadequate experience, inadequate operation reveal and unskillful operation cooperation of assistants, various technical errors may occur when meniscal suture repair is performed, particularly during all-inside meniscal suture repairing. For instance, improper suture pattern used, iatrogenic meniscal or chondral injury, improper tensioning of the suture and pulling out of suture anchor[8]. Once unilateral suture anchor of the all-inside meniscal repair system is pulled out, the suture will fail, and the treatment will be affected[8–10].

Therefore, we have explored a method of modified cross-suture to remedy the unilateral suture anchor pulling out of the meniscal repair system during the all-inside meniscal suture repair. The purpose of this study is to explore the feasibility and effectiveness of the method of modified cross-suture for arthroscopic remediation for unilateral suture anchor pulling out of an all-inside meniscal repair system.

Methods

General Information

From May 2014 to May 2017, the clinical data of patients with meniscus injury, who were treated in the First Department of Orthopaedics of the Second Affiliated Hospital of Xi'an Jiaotong University, were analyzed retrospectively. The inclusion criteria of observation group were as follows: the patients whose unilateral suture anchor was pulled-out during all-inside meniscal repair at time of ACL reconstructions; the full-thickness vertical longitudinal tear of the meniscus was more than 10 mm in length; the tear was in the red zone or red-white zone of the body or posterior angle of the meniscus, where the distance from the tear to the meniscal synovial margin was generally less than 6 mm; no previous history of joint surgery; the arthroscopic cartilage damage was Outerbridge II degree and below. The inclusion criteria of control group were same as observation group except unilateral suture anchor pulling out during all-inside meniscal repair.

A total of 28 cases were enrolled as observation group and 30 cases were enrolled as control group in this study. All cases had a combination of ACL rupture and underwent all-inside meniscal suture repair and ACL anatomic single-bundle reconstruction concurrently. The observation group had an average number of 1.3 ± 0.2 needles (range 1–3 needles) of unilateral suture anchor pulling out during all-inside meniscal suture repair intraoperatively. The method of modified cross-suture was used to remedy the error of unilateral suture anchor pulling out and to eventually complete an effective repair. The OMNISPAN™ meniscus repair system was used for all cases (DePuy Mitek, Inc., USA).

Operative Method

The ACL rupture and meniscal injury type were confirmed after anterolateral and anteromedial portals establishment. The location and length of meniscal tear were recorded. ACL anatomic single-bundle reconstruction was performed with autologous semitendinosus and gracilis tendons. Meniscal suture was performed when ACL reconstruction was completed, but the tibial interference screw was not screwed down. The meniscal torn edge was freshened with a meniscal file, and the meniscal suture repair was finished with the OMNISPAN™ meniscus repair system.

If unilateral anchor pulling out occurred, the suture knot was pushed to the implanted place of the other anchor at the synovial edge, the free end of the suture was left for standby (Fig. 1-a). The new OMNISPAN™ device was implanted and the suture knot was placed at the opposite side of the first device (Fig. 1-c). The two free sutures were pulled out through the same portal and knotted with the shoulder arthroscopic knotting technique. The “cross-suture” type fixation was finished after the knot was

tightened (Fig. 1-e,f). If there were two anchor implants pulling out at the same time (Fig. 1-b), a "double cross-suture" type fixation was finished (Fig. 1-d).

Postoperative management

The procedure is performed on an outpatient basis. Oral NSAIDs were used for 1 week. The normal full weight-bearing activities is allowed while wearing a knee extension brace for 6 weeks. Active and passive flexion is encouraged but limited to 90°. Walking and jogging is permitted at 3 months, and resumption of all sports activities and deep squatting at 6 months after operation.

Postoperative follow-up and evaluation

The outpatient follow-up was conducted conventionally by the appointed surgeon. During the follow-up, the physical examination was performed to confirm knee mobility, Lachman test and pivot shift test. Knee function was evaluated by the International Knee Documentation Committee (IKDC) as well as the Lysholm and Tegner scoring system. Meniscus healing was evaluated according to the Barrett standard[11]. If there was no joint swelling, joint space tenderness, or joint locking, and if the McMurray sign was negative, meniscal clinical healing could be achieved; however, if one of them was positive, the clinical healing requirements could not be met. Meniscus healing status was also confirmed with magnetic resonance imaging (MRI) postoperatively[12, 13]. On MRI, the meniscus was considered unhealed if Grade 3 signals on T2 sequences were seen.

SPSS 20.0 statistical software was used for statistical analysis. The measurement data were expressed as the mean ± standard deviation (SD) or as a percentage of subjects. Differences in the values of variables among groups were assessed using t-test if equal variance or Mann-Whitney U-test if not equal variance. The Pearson's Chi-square test was applied for dichotomous variables if expected frequency was > 5 or Fisher's exact test was applied if not. $P < 0.05$ was considered as statistically significant.

Results

25 cases of observation group and 28 cases of control group received complete follow-up with an average follow-up of 18.4 ± 5.2 months (range 13–34 months). All operations were finished by the same surgeon.

General data of the two groups were summarized in Table 1. There was no significant difference in gender, age, BMI, follow-up time, causes of injury, time from injury to surgery, side of knee injury, side of meniscus injury, tear zone of meniscus, tear length of meniscus, and number of used meniscal repair systems (Table 1). But, the surgery time in the observation group (85.5 ± 10.6 min) is significantly longer than that in the control group (64.8 ± 11.5 min, $t = 3.78$, $P < 0.05$).

Table 1
General data of observation group and control group

General data	Observation group (n = 25)	Control group (n = 28)	Statistics	P
Gender (Male/Female)	16/9	18/10	χ^2 = 3.855	0.327
Age (year)	25.5 ± 2.3	26.3 ± 1.9	t = 0.774	0.513
BMI (kg/m^2)	23.1 ± 1.3	22.8 ± 1.2	t = 1.388	0.139
follow-up time (month)	18.1 ± 4.7	18.5 ± 5.1	t = 0.853	0.402
causes of injury (sport injury/non-sport-related injury)	20/5	24/4	χ^2 = 2.526	0.248
time from injury to surgery (day)	35.5 ± 10.6	38.3 ± 11.4	u = − 1.356	0.185
side of knee injury (right/left)	13/12	15/13	χ^2 = 0.873	0.356
side of meniscus injury (lateral/medial)	7/18	8/20	χ^2 = 0.731	0.704
tear zone of meniscus (red/red-white)	23/2	25/3	χ^2 = 0.774	0.633
tear length of meniscus (cm)	1.8 ± 0.6	1.6 ± 0.8	t = 0.757	0.541
number of used meniscal repair systems	2.1 ± 0.2	2.2 ± 0.3	u = 0.656	0.854
surgery time (min)	85.5 ± 10.6	64.8 ± 11.5	t = 3.78	< 0.05

At the follow-up one year after operation, the knee range of motion (ROM) of two groups were unlimited, with an average ROM of 125.2 ± 4.3 degrees in observation group and 124.7 ± 3.8 degrees in control group. The postoperative pivot shift test of two groups were all negative, the Lachamn test was grade I in 8 cases of observation group and in 10 cases of control group, and the others tests were negative.

According to the standard of Barret, 1 case had knee joint space tenderness and positive McMurray sign, 1 case had slight swelling of the knee joint after activity without obvious pain in observation group, 2 cases had slight swelling of the knee joint after activity without obvious pain in control group, and the others had no positive symptoms. The clinical healing rate of the meniscus was 92% (23/25) in observation group and 92.9% (26/28) in control group. According to the postoperative MRI, the healing rate of the menniscus was 72% (18/25) in observation group and 71.4% (20/28) in control group, 2 cases

had clinical symptoms associated with meniscus in two groups respectively and the others had no relevant clinical symptoms.

At the follow-up one year after operation, the IKDC, Lysholm and Tegner scores of two groups were 90.52 ± 2.8, 89.17 ± 3.1, 6.81 ± 1.7 and 91.42 ± 1.9, 90.32 ± 3.4, 7.02 ± 1.4, the differences were not statistically significant ($P > 0.05$). The comparison of all the postoperative follow-up data between the two groups were in Table 2.

Table 2
Comparison of postoperative follow-up data between the two groups

follow-up data	Observation group (n = 25)	Control group (n = 28)	Statistics	P
Knee ROM	125.2 ± 4.3	124.7 ± 3.8	t = 0.667	0.742
Lachamn test (grade I/negative)	8/17	10/18	$\chi^2 = 2.157$	0.433
clinical healing rate of meniscus (%)	92% (23/25)	92.9% (26/28)	$\chi^2 = 1.364$	0.521
MRI healing rate of menniscus (%)	72% (18/25)	71.4% (20/28)	$\chi^2 = 0.975$	0.292
IKDC score	90.52 ± 2.8	91.42 ± 1.9	t = 1.528	0.095
Lysholm score	89.17 ± 3.1	90.32 ± 3.4	t = 0.973	0.357
Tegner score	6.81 ± 1.7	7.02 ± 1.4	t = 1.224	0.208

The male patient was 33 years old and had ACL rupture as well as medial meniscal tear (fig. a, c) of the right knee. The tear length of meniscus was 2 cm. Two unilateral anchors of the all-inside meniscal repair system were pulled out intraoperatively (fig. d, e, f). The method of modified cross-suture (fig. g) was used to remedy the error of unilateral suture anchor pulling out and to eventually complete an effective repair (fig. h). According to the postoperative MRI 1 year postoperatively, the meniscus healing was good (fig. b).

Discussion

With the understanding of meniscus structure and function, the treatment concept of meniscus injury has changed from "If it is torn, take it out!" to "Save the meniscus!"[6, 14]. Increasingly more studies have suggested[15–17] that meniscus injury or defect will lead to an increase in the incidence of osteoarthritis, and thus meniscal repair has received increasingly more attention. Among the repair methods of meniscus injury[18], meniscal suture repair is the mainstream repair method at present, and includes three types of repair: outside-in repair, inside-out repair and all-inside repair. Although the technique of inside-out repair is the gold standard for the treatment of the body and posterior angle of the meniscal tear, clinical studies have shown[19–22] that the clinical efficacy of all-inside repair is the same as that of

inside-out repair, where all-inside repair has shorter operation time and fewer complications. Therefore, the method of all-inside repair for meniscal tear of the body or posterior angle has seen increasing use[23–25].

The all-inside meniscal suture repair technology was first reported by Professor Craig Morgan in 1991[26]; however, this technology still requires an additional incision, and the operation is relatively complex. With the development of science and technology, a new generation of all-inside meniscal repair system has seen widespread use[27, 28], including the OMNISPAN™ meniscus repair system. The OMNISPAN™ meniscus repair system consists of the OMNISPAN anchor implants and needle, a sterile and disposable deployment gun, a malleable graft retractor, and the arthroscopic pusher/cutter. The OMNISPAN anchor implant is a combination of two molded polyetheretherketone (PEEK) implants, combined with ORTHOCORD® violet braided composite suture with size 2/0. The deployment gun properly introduces the anchor implant into the meniscus and the pusher/cutter facilitates the final suture position flush with the meniscal surface. The molded anchor implants with the suture provide compression across the tear in the meniscus to close the meniscal tear tightly and promote meniscal healing. The biomechanical studies have shown[29] that the all-inside meniscal repair and inside-out meniscal repair can achieve similar biomechanical properties after up to 10,000 cycles of loading.

With increasing popularity of the all-inside meniscal suture repair system, a growing number of doctors have begun to use the system to repair the meniscus; however, it requires arthroscopic operation skill and has a relatively steep learning curve, and thus operational errors may occur during meniscal suture repair if there is inadequate experience, inadequate operation reveal, or unskillful operation cooperation of assistants. When the deployment gun is misemployed or the needle is hindered by the femoral condyle, the two anchor implants may be introduced into the meniscus simultaneously, or one anchor implant may be fell off or pulled out. In these cases, only the unilateral anchor play the role of fixation and the repair system is failed, especially for the repair of the medial meniscus[8–10]. Under these circumstances, the meniscal repair system is usually completely removed and the new repair system is implanted[8].

In clinical practice, some oblique or cross-suture methods have been applied in the treatment of radial tears of the meniscus and have achieved good results[30–32]. Biomechanical studies have shown[33] that oblique sutures have the dual advantage of vertical sutures (superior biomechanical strength) and horizontal sutures (ease of application, longer sutures with a tendency to cover a larger meniscal tissue area). According to such theoretical and practical results, we hypothesize that if it is applied to the remediation of unilateral suture anchor pulling out of an all-inside meniscal repair system, the clinical efficacy of this method may be improved. With the shoulder arthroscopic knotting technique, the suture of the unilateral anchor pulling out and the other suture of normal state were cross-knotted for the formation of an oblique suture, where the optimal fixation effect could be achieved by tension adjustment of the knot. We named this method “modified cross-suture”. At present, we are actively exploring this system. After our short-term follow-up, we found that this method is practicable and effective, and is suitable for the remediation of one or more unilateral anchors pulling out. Compared with the control group, the

operative time of the observation group is longer. However, the clinical efficacy of two groups is similar, and is also comparable to that reported of other conventional suture methods[34, 35]. So, when the tear length of meniscus is longer and unilateral pulled-out anchor is happened during all-inside meniscal repair, this method can reduce the number of newly implanted meniscus repair system.

To achieve better clinical efficacy when exploring new surgical methods, all cases in this study underwent ACL reconstruction concurrently to improve the healing rate of meniscal suture repair. At present, many studies have shown[36–38] that concurrent ACL reconstruction has little influence on the healing rate of meniscal suture repair and that the injured area of the meniscus is a key factor affecting the healing rate. Based on the results of this study, if the clinical efficacy of our method is confirmed in the long-term follow-up, this method can be applied to more cases to obtain better clinical efficacy and medical economic benefits.

Limitations

This study has several limitations. First, the number of cases was relatively small, which limits the overall validity of our results. However, modified cross-suture repair is performed only infrequently and only patients with unilateral suture anchor pulling out were included. Therefore, our study cohort represents a relatively homogenous collective with regard to surgical treatment. Second, the follow-up time was relatively short. Therefore, longer follow-up is needed to determine its long-term effectiveness. Third, further multicenter study and biomechanical study are necessary to evaluate the feasibility and effectiveness of the modified cross-suture technique for meniscal repair.

Conclusion

The method of modified cross-suture is effective for arthroscopic remediation for unilateral suture anchor pulling out of an all-inside meniscal repair system.

List Of Abbreviations

ACL:anterior cruciate ligament; MRI:magnetic resonance imaging; IKDC:International Knee Documentation Committee; ROM:range of motion

Declarations

Ethics approval and consent to participate

This study has been approved by the Institutional Review Broad of the second affiliated hospital of xi’an jiaotong university, and the study was performed in accordance with the Declaration of Helsinki. Informed consent was obtained from all patients.

Consent for publication

Not applicable.

Availability of data and materials

The datasets used and analysed during the current study are available from the corresponding author on reasonable request.

Competing interests

The authors declare that they have no competing interests.

Funding

This study was supported by the general project of key research and development program of Shaanxi provincial (2019SF-113). The role of the funding included design of the study and English editing.

Authors' contributions

J.L.N. participated in the study design, collected data, performed statistical analyses, and drafted the manuscript. Z.B.S. participated in the design and assisted with statistical analyses. L.H.F., N.G. and H.Y.W. collected and interpreted data, helped draft the manuscript. X.Q.D. participated in the design and helped draft the manuscript. D.C.L. conceived the study, participated in the design, and helped draft the manuscript.

Acknowledgment

The authors thank AJE (American Journal Experts) for the help in english language editing of the manuscript.

References

1. Karia M, Ghaly Y, Al-Hadithy N, Mordecai S, Gupte C. Current concepts in the techniques, indications and outcomes of meniscal repairs. Eur J Orthop Surg Traumatol. 2019 Apr;29(3):509-520. doi: 10.1007/s00590-018-2317-5.

2. Vaquero-Picado A, Rodríguez-Merchán EC. Arthroscopic repair of the meniscus: Surgical management and clinical outcomes. EFORT Open Rev. 2018 Nov 8;3(11):584-594. doi: 10.1302/2058-5241.3.170059.
3. Patil SS, Shekhar A, Tapasvi SR. Meniscal Preservation is Important for the Knee Joint. Indian J Orthop. 2017 Sep-Oct;51(5):576-587. doi: 10.4103/ortho.IJOrtho_247_17.
4. Xu C, Zhao J. A meta-analysis comparing meniscal repair with meniscectomy in the treatment of meniscal tears: the more meniscus, the better outcome? Knee Surg Sports Traumatol Arthrosc. 2015 Jan;23(1):164-70. doi: 10.1007/s00167-013-2528-6.
5. Katano H, Koga H, Ozeki N, Otabe K, Mizuno M, Tomita M, et al. Trends in isolated meniscus repair and meniscectomy in Japan, 2011-2016. J Orthop Sci. 2018 Jul;23(4):676-681. doi: 10.1016/j.jos.2018.04.003.
6. Doral MN, Bilge O, Huri G, Turhan E, Verdonk R. Modern treatment of meniscal tears. EFORT Open Rev. 2018 May 21;3(5):260-268. doi: 10.1302/2058-5241.3.170067.
7. Pach M, Horáček F. Suture - the Current Trend of Medial Meniscus Lesion Treatment [Article in Czech]. Acta Chir Orthop Traumatol Cech. 2018;85(1):62-69.
8. Gwathmey FW Jr, Golish SR, Diduch DR. Complications in brief: meniscus repair. Clin Orthop Relat Res. 2012 Jul;470(7):2059-66. doi: 10.1007/s11999-012-2303-x.
9. Bolog NV, Andreisek G. Reporting knee meniscal tears: technical aspects, typical pitfalls and how to avoid them. Insights Imaging. 2016 Jun;7(3):385-98. doi: 10.1007/s13244-016-0472-y.
10. DePhillipo NN, Engebretsen L, LaPrade RF. Current Trends Among US Surgeons in the Identification, Treatment, and Time of Repair for Medial Meniscal Ramp Lesions at the Time of ACL Surgery. Orthop J Sports Med. 2019 Feb 22;7(2):2325967119827267. doi: 10.1177/2325967119827267.
11. Barrett GR, Field MH, Treacy SH, Ruff CG. Clinical results of meniscus repair in patients 40 years and older. Arthroscopy. 1998 Nov-Dec;14(8):824-9.
12. Crues JV 3rd, Mink J, Levy TL, Lotysch M, Stoller DW. Meniscal tears of the knee: accuracy of MR imaging. Radiology. 1987 Aug;164(2):445-8.
13. Buyukkuscu MO, Misir A, Hamrayev AJ, Ozcafer R, Cetinkaya E. Clinical and radiological outcomes following isolated vertical medial meniscal tear repair in patients over 40 years old.J Orthop Surg (Hong Kong). 2019 May-Aug;27(2):2309499019836300. doi: 10.1177/2309499019836300.
14. Beaufils P, Pujol N. Management of traumatic meniscal tear and degenerative meniscal lesions. Save the meniscus. Orthop Traumatol Surg Res. 2017 Dec;103(8S):S237-S244. doi: 10.1016/j.otsr.2017.08.003.
15. Feeley BT, Lau BC. Biomechanics and Clinical Outcomes of Partial Meniscectomy. J Am Acad Orthop Surg. 2018 Dec 15;26(24):853-863. doi: 10.5435/JAAOS-D-17-00256.
16. Beaufils P, Becker R, Kopf S, Englund M, Verdonk R, Ollivier M, et al. Surgical Management of Degenerative Meniscus Lesions: The 2016 ESSKA Meniscus Consensus. Joints. 2017 Jul 28;5(2):59-69. doi: 10.1055/s-0037-1603813.

17. Thorlund JB, Holsgaard-Larsen A, Creaby MW, Jørgensen GM, Nissen N, Englund M, et al. Changes in knee joint load indices from before to 12 months after arthroscopic partial meniscectomy: a prospective cohort study. Osteoarthritis Cartilage. 2016 Jul;24(7):1153-9. doi: 10.1016/j.joca.2016.01.987.
18. Shimomura K, Hamamoto S, Hart DA, Yoshikawa H, Nakamura N. Meniscal repair and regeneration: Current strategies and future perspectives. J Clin Orthop Trauma. 2018 Jul-Sep;9(3):247-253. doi: 10.1016/j.jcot.2018.07.008.
19. Elmallah R, Jones LC, Malloch L, Barrett GR. A Meta-Analysis of Arthroscopic Meniscal Repair: Inside-Out versus Outside-In versus All-Inside Techniques. J Knee Surg. 2019 Aug;32(8):750-757. doi: 10.1055/s-0038-1668123.
20. Kang DG, Park YJ, Yu JH, Oh JB, Lee DY. A Systematic Review and Meta-Analysis of Arthroscopic Meniscus Repair in Young Patients: Comparison of All-Inside and Inside-Out Suture Techniques. Knee Surg Relat Res. 2019 Mar 1;31(1):1-11. doi: 10.5792/ksrr.17.078.
21. Samuelsen BT, Johnson NR, Hevesi M, Levy BA, Dahm DL, Stuart MJ, et al. Comparative Outcomes of All-Inside Versus Inside-Out Repair of Bucket-Handle Meniscal Tears: A Propensity-Matched Analysis. Orthop J Sports Med. 2018 Jun 15;6(6):2325967118779045. doi: 10.1177/2325967118779045.
22. Fillingham YA, Riboh JC, Erickson BJ, Bach BR Jr, Yanke AB. Inside-Out Versus All-Inside Repair of Isolated Meniscal Tears: An Updated Systematic Review. Am J Sports Med. 2017 Jan;45(1):234-242. doi: 10.1177/0363546516632504.
23. Schmitt A, Batisse F, Bonnard C. Results with all-inside meniscal suture in pediatrics. Orthop Traumatol Surg Res. 2016 Apr;102(2):207-11. doi: 10.1016/j.otsr.2015.12.018.
24. Zimmerer A, Sobau C, Nietschke R, Schneider M, Ellermann A. Long-term outcome after all inside meniscal repair using the FasT-Fix system. J Orthop. 2018 May 8;15(2):602-605. doi: 10.1016/j.jor.2018.05.042.
25. Pujol N, Tardy N, Boisrenoult P, Beaufils P. Long-term outcomes of all-inside meniscal repair. Knee Surg Sports Traumatol Arthrosc. 2015 Jan;23(1):219-24. doi: 10.1007/s00167-013-2553-5.
26. Morgan CD. The "all-inside" meniscus repair. Arthroscopy. 1991;7(1):120-5.
27. Barber FA, Herbert MA, Bava ED, Drew OR. Biomechanical testing of suture-based meniscal repair devices containing ultrahigh-molecular-weight polyethylene suture: update 2011. Arthroscopy. 2012 Jun;28(6):827-34. doi: 10.1016/j.arthro.2011.11.020.
28. M Buckland D, Sadoghi P, Wimmer MD, Vavken P, Pagenstert GI, Valderrabano V, et al. Meta-analysis on biomechanical properties of meniscus repairs: are devices better than sutures? Knee Surg Sports Traumatol Arthrosc. 2015 Jan;23(1):83-9. doi: 10.1007/s00167-014-2966-9.
29. Rosso C, Müller S, Buckland DM, Schwenk T, Zimmermann S, de Wild M, et al. All-inside meniscal repair devices compared with their matched inside-out vertical mattress suture repair: introducing 10,000 and 100,000 loading cycles. Am J Sports Med. 2014 Sep;42(9):2226-33. doi: 10.1177/0363546514538394.

30. Matsubara H, Okazaki K, Izawa T, Tashiro Y, Matsuda S, Nishimura T, et al. New suture method for radial tears of the meniscus: biomechanical analysis of cross-suture and double horizontal suture techniques using cyclic load testing. Am J Sports Med. 2012 Feb;40(2):414-8. doi: 10.1177/0363546511424395.
31. Stender ZC, Cracchiolo AM, Walsh MP, Patterson DP, Wilusz MJ, Lemos SE. Radial Tears of the Lateral Meniscus-Two Novel Repair Techniques: A Biomechanical Study. Orthop J Sports Med. 2018 Apr 27;6(4):2325967118768086. doi: 10.1177/2325967118768086.
32. Aşçi M, Balta O, Kurnaz R, Eren MB, Kuyucu YE, Güneş "Horizontal butterfly" technique in repair of radial meniscus tears: A biomechanical study. Acta Orthop Traumatol Turc. 2018 Sep;52(5):392-396. doi: 10.1016/j.aott.2018.07.002.
33. Kocabey Y, Taser O, Nyland J, Doral MN, Demirhan M, Caborn DN, et al. Pullout strength of meniscal repair after cyclic loading: comparison of vertical, horizontal, and oblique suture techniques. Knee Surg Sports Traumatol Arthrosc. 2006 Oct;14(10):998-1003. doi: 10.1007/s00167-006-0079-9.
34. Tagliero AJ, Desai VS, Kennedy NI, Camp CL, Stuart MJ, Levy BA, et al. Seventeen-Year Follow-up After Meniscal Repair With Concomitant Anterior Cruciate Ligament Reconstruction in a Pediatric and Adolescent Population. Am J Sports Med. 2018 Dec;46(14):3361-3367. doi: 10.1177/0363546518803934.
35. Wu IT, Hevesi M, Desai VS, Camp CL, Dahm DL, Levy BA, et al. Comparative Outcomes of Radial and Bucket-Handle Meniscal Tear Repair: A Propensity-Matched Analysis. Am J Sports Med. 2018 Sep;46(11):2653-2660. doi: 10.1177/0363546518786035.
36. Uzun E, Misir A, Kizkapan TB, Ozcamdalli M, Akkurt S, Guney A. Arthroscopic medial meniscal repair with or without concurrent anterior cruciate ligament reconstruction: A subgroup analysis. Knee. 2018 Jan;25(1):109-117. doi: 10.1016/j.knee.2017.11.003.
37. Uzun E, Misir A, Kizkapan TB, Ozcamdalli M, Akkurt S, Guney A. Factors Affecting the Outcomes of Arthroscopically Repaired Traumatic Vertical Longitudinal Medial Meniscal Tears. Orthop J Sports Med. 2017 Jun 23;5(6):2325967117712448. doi: 10.1177/2325967117712448.
38. Dean CS, Chahla J, Matheny LM, Mitchell JJ, LaPrade RF. Outcomes After Biologically Augmented Isolated Meniscal Repair With Marrow Venting Are Comparable With Those After Meniscal Repair With Concomitant Anterior Cruciate Ligament Reconstruction. Am J Sports Med. 2017 May;45(6):1341-1348. doi: 10.1177/0363546516686968.

Figures

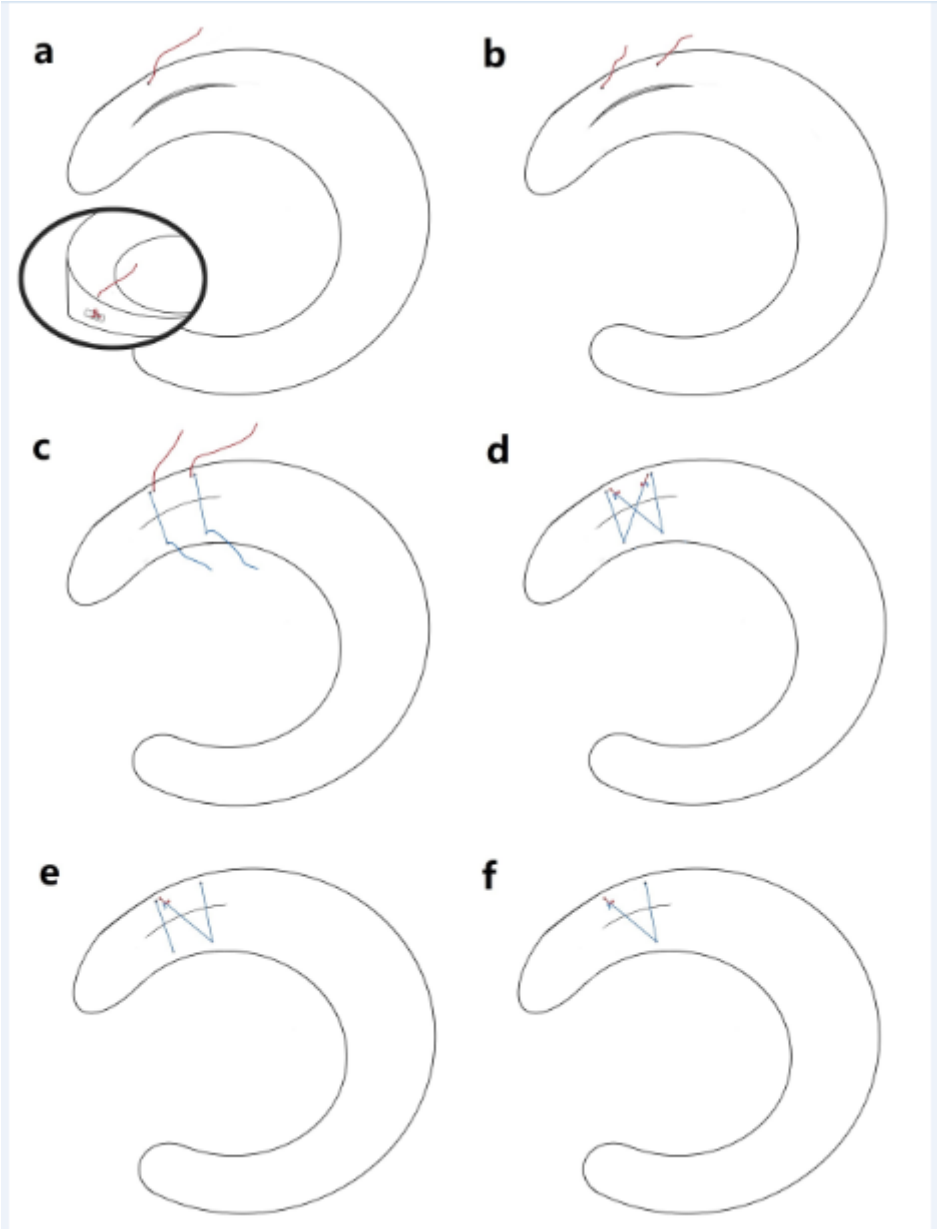

Figure 1

Schematic diagram of "modified cross-suture": Fig a: The vertical longitudinal tear at the posterior angle of the medial meniscus. The suture (red line) in the diagram represents the free end of the suture of the all-inside meniscal repair system after unilateral anchor pulling out. Fig b: The two sutures (red line) in the diagram represent the two free ends of the suture of the all-inside meniscal repair system after unilateral anchor pulling out. Fig c: The two all-inside meniscal repair systems were reinstalled into the torn meniscus. The free suture leg (blue line) was pulled until the suture was tight against the meniscus surface and the meniscal tear was closed. The two free ends (blue line) were left at the opposite side of the standby suture (red line), as shown in Fig b. Fig d: The two sutures (red line) of the unilateral anchor pulling out and the other two sutures (blue line) of normal state were cross-knotted to reinforce the meniscal tear. Fig e: The cross-suture was finished if there was only one suture of unilateral anchor pulling out. Fig f: If the length of meniscal tear was less than 10 mm, the cross-suture was finished more easily if there was only one suture of unilateral anchor pulling out.

Figure 2

Typical case