Occurrence of *Eimeria* Species (Apicomplexa: Eimeriidae) in Domestic Rabbits (*Oryctolagus Cuniculus*) in Qena Governorate, Upper Egypt, with a Special Key

Nermean Moamen Hussein (nermeanmohu@yahoo.com)
South Valley University https://orcid.org/0000-0002-6003-5710

Soheir Ahmed Rabie
South Valley University Faculty of Science

Wafaa Ade-Eldaiem Abuelwafa
South Valley University Faculty of Science

Research Article

Keywords: Eimeria, Domestic rabbits, Light microscopy, Transmission electron microscopy, Key, Egypt

Posted Date: October 20th, 2021

DOI: https://doi.org/10.21203/rs.3.rs-927932/v1

Abstract

A total of 200 domestic rabbits were collected from Qena Governorate, Egypt, from October 2018 to October 2020. Their fecal samples were tested for the presence of *Eimeria* species oocysts using the standard flotation technique, which revealed oocysts in 100 rabbits (50%). The following 11 species of *Eimeria* were examined morphologically and morphometrically from different parts of the rabbits' intestine (duodenum, ileum, cecum, colon and rectum): *Eimeria coecicola*, *E. exigua*, *E. flavescens*, *E. irresidua*, *E. magna*, *E. media*, *E. perforans*, *E. intestinalis*, *E. stiedae*, *E. vejdovskyi*, and *E. piriformis*. Moreover, the endogenous stages of *E. intestinalis* were examined by light and transmission electron microscopy. Macrogametogenesis and microgametogenesis were clearly observed. The development of microgamonts, macrogametes, and oocysts with their fine structural characteristics was detected. Additionally, a detailed key for each species is provided according to the common morphological characters such as the presence or absence of oocyst and sporocyst residua as well as conspicuous or inconspicuous micropyle. *E. stiedae*, *E. irresidua*, and *E. vejdovskyi* are reported for the first time in Qena Governorate, Upper Egypt.

Introduction

In Egypt, the demand for animal protein has been increasing significantly along with the continuous increase in human population and improvement in the standard of life. Rabbits can fulfill this increased demand as they are considered to be the best and important source of animal protein. Moreover, they have low cholesterol and fat contents (Al-Mathal, 2008 and Lebdah and Shahn, 2011).

Generally, rabbits are infected by a range of parasites, including ectoparasites and endoparasites. Studies have reported that parasitic infections have caused considerable losses to rabbits in terms of production and scientific applications (Ghanem and Ismail 1992; Hansen and Perry 1994 and Eid and Ibraheem, 2006). Coccidiosis is considered to be one of the most important diseases that affect rabbits. The members of the genus *Eimeria* represent the common endoparasites that cause coccidiosis in rabbits (Vancraeynest *et al*., 2008 and Oncel *et al*., 2011).

At the level of *Eimeria* spp., coccidiosis can be classified into two forms, viz., hepatic coccidiosis that occurs because of *E. stiedae* and intestinal coccidiosis that occurs because of the remaining members of *Eimeria*. Several authors have discussed the presence of *Eimeria* species in domestic rabbits in Egypt (Ahmed 1952; Taha 1952; Haiba *et al.,* 1955; Saad, 1970; Abd El Rahman, 1979; Ahmed, 1983; El Masry, 1983; Fahmy *et al*., 1985; Hamed, 1988; Rashed, 1993; Mekawy, 1997; Mohamed, 1997; Kutkat *et al*., 1998; Ibraheem, 1999; Helmy, 2002; El-Shahawi *et al*., 2012; El-Shahawy and El-Goniemy, 2018 and El-Sayed *et al*., 2020).

Kasim and Al-Shawa (1987) reported seven species of *Eimeria* from domestic rabbits collected from three regions in Saudi Arabia. El-Shahawi *et al*. (2012) reported eight species of *Eimeria* from domestic rabbits in Beni Suef Governorate, Egypt. Abdel-Baki and Al-Quraishy (2013) described 10 species of *Eimeria* from

domestic rabbits in Riyadh, Saudi Arabia. El-Shahawy and El-Goniemy (2018) recorded eight species of *Eimeria* in domestic rabbits in Qena Governorate, Upper Egypt. In the present study, 11 species of *Eimeria* were recorded from the feces of domestic rabbits in Qena Governorate, Upper Egypt.

Other previous studies have also reported *Eimeria* species among domestic rabbits (Gill and Ray, 1960; Mirza, 1970; Flatt and Campbell, 1974; Mandal, 1976; Peeters *et al*., 1981; Pakandl, 1986; Pakandl, 1989; Darwish and Golemansky, 1991; Musongong and Fakae, 1999; Yakhchali and Tehrani, 2007; Al-Mathal, 2008; Jelı´nkova´ *et al*., 2008; Li *et al*., 2010 and Ola-Fadunsin *et al*., 2019).

The overall prevalence rates of infection were 73%, 70%, 75%, and 33.9% in the previous studies of Kasim and Al-Shawa (1987), El-Shahawi *et al*. (2012), Abdel-Baki and Al-Quraishy (2013), and El-Shahawy and El-Goniemy (2018), respectively compared with the overall prevalence of infection in the present study (50%). The variations in the prevalence of coccidian infection in domestic rabbits may be due to the wide usage of grains and grass as rabbit diet besides the use of chemoprophylaxis and the difference in environmental conditions among regions (Chowdhury and Fraser, 2008; El-Shahawy and El-Goniemy, 2018).

Generally, the morphology and morphometry of the oocysts and sporocysts of *Eimeria* species are the most common criteria used for their identification (Coudert *et al*., 1995; Pakandl, 2009 and Oliveira *et al*., 2011). *E. exigua* and *E. perforans* can be considered to be slightly-to-mildly pathogenic. *E. flavescens*, *E. media*, and *E. stiedae* can be considered to be pathogenic, especially in young rabbits and in high inoculation/infective doses. *E. coecicola*, *E. intestinalis*, *E. irresidua*, and *E. magna* can be considered as the most pathogenic intestinal species. However, there is no information regarding the pathology of both *E. piriformis* and *E. vejdovskyi* (Duszynski and Couch, 2013).

Eleven species of *Eimeria* have been previously accepted as valid species infecting domestic rabbits (Coudert *et al*. 1995; Eckert *et al*. 1995; Kvicerova *et al*. 2008; Pakandl 2009; Oliveira *et al*., 2011 and Li *et al*., 2016). Thus, the present study was conducted to investigate the morphology and morphometry of 11 species of *Eimeria* present in domestic rabbits in Qena Governorate, Upper Egypt, and to provide a detailed key for these species on the basis of their morphological characteristics. Furthermore, the endogenous stages (gametogony and oocyst wall formation) of *E. intestinalis* were observed via light and transmission electron microscopy. Moreover, this study reveals the overall prevalence of infection with different *Eimeria* species besides the prevalence of infection for each species separately.

Materials And Methods

Sample collection

Domestic rabbits were collected from different localities in Qena Governorate, Upper Egypt, from October 2018 to October 2020. They ranged from young (up to one year) to adult samples (over one year). The weight of collected rabbits ranged from 350-900 g to 980-2700 g. Their fecal samples were freshly

collected and examined microscopically for the presence of *Eimeria* spp. at the Laboratory of Parasitology, Zoology Department, Faculty of Science, South Valley University, Qena.

Light microscopy

Unsporulated oocysts were examined directly in the fecal material of the infected rabbits using the flotation method (Long *et al.,* 1976; Kvičerová *et al.,* 2008). The collected oocysts were sporulated in a 2.5% aqueous potassium dichromate solution in Petri dishes in air at room temperature for a week and stored in glass bottles until use. The morphological and morphometric characters of unsporulated and sporulated oocysts were investigated under a binocular compound microscope using an oil immersion lens.

On the basis of 30 sporulated oocysts, measurements were made using a calibrated micrometer. All measurements were made in micrometers and represented as mean followed by range in parentheses. Hand drawings were made from the original figures after adjusting them using the Adobe Photoshop CS6 program (version 13.0 × 32). The drawing process was divided into several stages, which were then assembled to form the final stage.

Transmission electron microscopy

Samples were removed from the proximal and distal ileum of the rabbits' intestine and placed immediately in 3% glutaraldehyde in a 0.1 M cacodylate buffer (pH 7.3) for 24 h. After fixation in 2% OsO_4 for 4 h, dehydration was performed in an ascending ethanol series. The samples were routinely processed and embedded in an araldite embedding medium. Semithin sections were cut and stained with toluidine blue for examination under a light microscope. Ultrathin sections were stained with uranyl acetate and lead citrate (El Fayoumi and Abdel-Haleem, 2014) and examined under a JEOL-JEM-1010 electron microscope at 80 kV at the Central Laboratory of South Valley University.

Results

Out of the 200 examined rabbits, 100 were positively infected with *Eimeria* spp., indicating a prevalence of 50%.

E. exigua, *E. perforans*, *E. intestinalis*, and *E. irresidua* were the most common species; *E. flavescens* and *E. media* were less common; and *E. magna*, *E. coecicola*, *E. vejdovskyi*, *E. piriformis*, and *E. stiedae* were rare (Table 1).

The morphological and morphometric characters of the recovered *Eimeria* species are summarized in Tables 1 and 2. The oocysts of 11 *Eimeria* species collected from the domestic rabbits in the present study are illustrated in Figs. 1-15.

1. E. coecicola Cheissin (1947)

Synonym: *Eimeria oryctolagi* Ray and Banik, 1965

Host: Domestic rabbits (*Oryctolagus cuniculus*) (L., 1758) (syn. *Lepus cuniculus*).

Locality: Qena governorate, Upper Egypt

Prevalence: 8% (8/100)

Sporulation time: 60h

Description (Tables 1 and 2, Fig. 1):

Sporulated oocysts are cylindrical and 29.75 µm (27.41–31.58 µm) in length and 17.38 µm (16.27–18.11 µm) in width, with a distinct micropyle at one end (Figs. 1B and 1D). The oocyst wall is double-layered; the outer layer is smooth, somewhat thickened, forming a small ridge at the micropyle, and the inner layer is membranous. The micropyle is well-pronounced and surrounded by a slightly thickened wall, the oocyst residuum is rounded; and the polar granule is absent (Figs. 1B and 1D). Sporocysts are elongated ovoid to spindle-shaped with a pointed end, measuring 12.04 µm (10.27–13.8 µm) in length and 7.03 µm (6.16–7.75 µm) in width, with the Stieda body and residuum (Fig. 1D). Sporozoites are elongate, lying lengthwise head to tail in the sporocysts, each with one refractile body at the wider end (Figs. 1B and 1D).

Unsporulated oocysts are cylindrical and 30.3 µm (29.52–31.22 µm) in length and 16.32 µm (15.43–16.88 µm) in width, with a conspicuous micropyle (Figs. 1A and 1C). Sporoblast (zygote) is cylindrical, measuring 22.54 µm (19.37–24.7 µm) in length and 12.07 µm (11.64–12.54 µm) in width (Figs. 1A and 1C).

***2. E. exigua* Yakimoff (1934)**

Synonymy: *Eimeria exigua* Type I of Yakimoff, 1934; *Eimeria exigua* var. *septentrionalis* Madsen, 1938, pro parte; *Eimeria hungarica* Pellérdy, 1956, pro parte.

Host: Domestic rabbit, *Oryctolagus cuniculus* (L., 1758) (syn. *Lepus cuniculus*).

Locality: Qena governorate, Upper Egypt.

Prevalence: 65 (65/100)

Sporulation time: 33h

Description (Tables 1 and 2, Fig. 2):

Sporulated oocysts are spherical to subspherical, measuring 19.41 µm (17.13–24.27 µm) in length and 19.61 µm (17.56–23.37 µm) in width. The micropyle and the oocyst residuum are absent. The sporocyst is ellipsoid to elongated ovoid, measuring 11.44 µm (10.26–12.47 µm) in length and 6.75 µm (5.56–7.84

µm) in width (Figs. 2B and 2D). The sporocyst residuum is present (Figs. 2B and 2D). The Stieda body is present, and substieda and parastieda bodies are absent (Fig. 2D).

Unsporulated oocysts are spherical to subspherical, measuring 22.74 µm (20.48–25.41 µm) in length and 21.96 µm (20.61–23.88 µm) in width. The micropyle is absent (Figs. 2A and 2C). Sporoblast (zygote) is spherical to subspherical, measuring 14.58 µm (11.96–18.12 µm) in length and 13.9 µm (11.5–17.25 µm) in width (Figs. 2A and 2C).

3. E. flavescens Marotel and Guilhon (1941)

Synonymy: *Eimeria pellerdyi* Coudert, 1977a, b; *Eimeria hakei* Coudert, 1978; *Eimeria irresidua* Kessel and Jankiewicz, 1931 of Francalani and Manfredini, 1967.

Host: Domestic rabbit, *Oryctolagus cuniculus* (L., 1758) (syn. *Lepus cuniculus*).

Locality: Qena Governorate, Upper Egypt.

Prevalence: 30% (30/100)

Sporulation time: 45h

Description (Tables 1 and 2, Fig. 3**):**

Sporulated oocysts are ovoid and 29.63 µm (24.71–34.42 µm) in length and 21.08 µm (17.06–25.45 µm) in width. There are two oocyst walls; the outer wall is smooth, and the inner wall is thick. The micropyle is prominent and well-defined. There are no oocyst residuum and polar granule. The sporocyst is elongated ovoid, measuring 13.31 µm (12.08–14.07 µm) in length and 7.63 µm (6.23–8.96 µm) in width (Figs. 3B and 3C). The Stieda body is small, without substieda or parastieda bodies (Fig. 3D). The sporocyst residuum is present as a subspheroidal cluster of granules (Figs. 3B and 3D). Sporozoites are elongate, each with one clear refractile body (Figs. 3B and 3D).

Unsporulated oocysts are ovoid, measuring 27.4 µm (25.25–29.79 µm) in length and 20.25 µm (18.54–21.86 µm) in width, with a conspicuous micropyle (Figs. 3A and 3B). The sporoblast (zygote) is ovoid, measuring 18.78 µm (17.67–20.43 µm) in length and 16.6 µm (14.33–18.7 µm) in width (Figs. 3A and 3C).

4. E. irresidua Kessel and Jankiewicz (1931)

Synonymy: *Eimeria elongata* Marotel and Guilhon, 1941.

Host: Domestic rabbit, *Oryctolagus cuniculus* (L., 1758) (syn. *Lepus cuniculus*).

Locality: Qena Governorate, Upper Egypt.

Prevalence: 35% (35/100)

Sporulation time: 50h

Description (Tables 1 and 2, Fig. 4):

Sporulated oocysts are ellipsoid, measuring 29.69 µm (26.15–35.88 µm) in length and 19.18 µm (17.27–23.06 µm) in width. There are two oocyst walls; the outer wall is smooth, and the inner wall is thick. The micropyle is concave and conspicuous. Both the oocyst residuum and the polar granule are absent. The sporocyst is ovoidal to ellipsoidal, measuring 13.65 µm (11.98–18.9 µm) in length and 7.68 µm (6.56–9 µm) in width (Fig. 4D). The Stieda body is pointed, and substieda and parastieda bodies are absent (Figs. 4B and 4D). The sporocyst residuum is irregularly elongate, compact, and granular (Figs. 4B and 4D). Sporozoites lay end to end, each with a large refractile body at the wider end (Figs. 4B and 4D).

Unsporulated oocysts are ellipsoid, measuring 29.08 µm (28.28–29.53 µm) in length and 17.87 µm (17.53–18.11 µm) in width, with a conspicuous micropyle (Figs. 4A and 4C). The sporoblast (zygote) is ellipsoid, measuring 17.81 µm (17.75–17.87 µm) in length and 14.76 µm (14.32–15.01 µm) in width (Figs. 4A and 4C).

***5. E. magna* Pe´rard (1925)**

Synonymy: *Eimeria perforans* var. *magna* Pe´rard, 1925.

Host: Domestic rabbit, *Oryctolagus cuniculus* (L., 1758) (syn. *Lepus cuniculus*).

Locality: Qena Governorate, Upper Egypt.

Prevalence: 10% (10/100)

Sporulation time: 48h

Description (Tables 1 and 2, Fig. 5):

Sporulated oocysts are ovoid, measuring 29.82 µm (28.13–32.31 µm) in length and 18.25 µm (17.82–18.97 µm) in width. The micropyle is present, with a collar-like thickening of the outer layer around the micropyle. The oocyst residuum is large (Fig. 5D); polar granule is absent. The sporocyst is ovoidal to ellipsoidal, measuring 12.72 µm (9.7–15.43 µm) in length and 7.24 µm (6.64–7.59 µm) in width (Figs. 5B and 5D). The Stieda body is small, and substieda and parastieda bodies are absent (Fig. 5B). The sporocyst residuum is coarsely granular and appears as a small cluster in the middle of sporocysts (Figs. 5B and 5D). Sporozoites lay head to tail around the sporocyst residuum, each with a central nucleus and one large refractile body at their broad end (Figs. 5B and 5D).

Unsporulated oocysts are ovoid, measuring 30.2 µm (29.74–30.87 µm) in length and 18.8 µm (17.89–19.32 µm) in width, with a conspicuous micropyle (Figs. 5A and 5C). The sporoblast (zygote) is spherical to subspherical, measuring 19.09 µm (18.72–14.07 µm) in length and 15.05 µm (13.94–16.64 µm) in width (Figs. 5A and 5C).

6. E. media Kessel and Jankiewicz (1931)

Synonymy: *Eimeria media* Kessel, 1929.

Host: Domestic rabbit, *Oryctolagus cuniculus* (L., 1758) (syn. *Lepus cuniculus*).

Locality: Qena Governorate, Upper Egypt.

Prevalence: 25% (25/100)

Sporulation time: 31h

Description (Tables 1 and 2, Fig. 6):

Sporulated oocysts are ellipsoid, measuring 27.44 µm (25.34–29.4 µm) in length and 18.61 µm (16.36–22.11 µm) in width. The micropyle is convex, protruding with thickening of the wall surrounding it (Figs. 6B and 6D). The oocyst residuum is spheroidal; the polar granule is absent (Figs. 6B and 6D). The sporocyst is fusiform or ovoidal to ellipsoidal, measuring 13.72 µm (11.22–15.88 µm) in length and 6.95 µm (6.5–8.01 µm) in width (Figs. 6B and 6D). The Stieda body is small and flat (Fig. 6B), and substieda and parastieda bodies are absent. The sporocyst residuum is compact and spheroidal and composed of rough granules and is generally present near the sporocyst wall. Sporozoites lay end to end (Figs. 6B and 6D).

Unsporulated oocysts are ellipsoid, measuring 26.45 µm (25.68–27.14 µm) in length and 16.94 µm (16.73–17.24 µm) in width, with an inconspicuous micropyle (Figs. 6A and 6C). The sporoblast (zygote) is spherical, measuring 18.63 µm (18.26–18.98 µm) in length and 13.78 µm (13.5–14.04 µm) in width (Figs. 6A and 6C).

7. E. perforans (Leuckart, 1879) Sluiter and Swellengrebel (1912)

Synonymy: *Coccidium cuniculi* Rivolta, 1878; *Coccidium perforans* Leuckart, 1879; *Eimeria nana* Marotel and Guilhon, 1941; *Eimeria lugdunumensis* Marotel and Guilhon, 1942.

Host: Domestic rabbit, *Oryctolagus cuniculus* (L., 1758) (syn. *Lepus cuniculus*).

Locality: Qena Governorate, Upper Egypt.

Prevalence: 63% (63/100)

Sporulation time: 30h

Description (Tables 1 and 2, Fig. 7):

Sporulated oocysts are ellipsoid, measuring 24.19 µm (16.46–26.68 µm) in length and 17.08 µm (11.73–19.76 µm) in width. The micropyle is occasionally present or absent, rarely visible in smaller oocysts. The

oocyst residuum is variable, spheroidal, triangular, or composed of a chain of granules; the polar granule is absent (Figs. 7B and 7D). The sporocyst is fusiform or ovoidal to ellipsoidal, measuring 11.92 µm (8.24–13.23 µm) in length and 6.52 µm (4.26–7.88 µm) in width (Figs. 7B and 7D). The Stieda body is small (Fig. 7B), and substieda and parastieda bodies are absent. The sporocyst residuum is small and granular (Figs. 7B and 7D). Sporozoites lay end to end, each with one end being broader than the other and with one clear refractile body at the large end (Figs. 7B and 7D).

Unsporulated oocysts are ellipsoid, measuring 19.56 µm (15.25–22.96 µm) in length and 14.08 µm (11.64–16.72 µm) in width, with an inconspicuous micropyle (Figs. 7A and 7C). Sporoblast (zygote) is ellipsoid to ovoid, measuring 13.5 µm (11.63–15.19 µm) in length and 9.56 µm (7.9–10.63 µm) in width (Figs. 7A and 7C).

8. E. intestinalis Cheissin (1948)

Synonymy: *E. agnosta* Pelle´rdy (1954); *E. piriformis* Gve´le´ssiani and Nadiradze (1945); *E. piriformis* Cheissin (1948) (Pelle´rdy, 1953); non-*E. piriformis* Kotlan and Pospesch (1934); non-*E. piriformis* Marotel and Guilhon (1941); non-*E. piriformis* Lubimov (1934).

Host: Domestic rabbit, *O. cuniculus* (L., 1758) (syn. *Lepus cuniculus*).

Locality: Qena Governorate, Upper Egypt.

Prevalence: 50% (50/100)

Sporulation time: 52 h

Description (Tables 1 and 2, Fig. 8):

Sporulated oocysts are piriform, measuring 25.19 µm (23.38–26.56 µm) in length and 18.3 µm (16.81–19.37 µm) in width. The micropyle is well-defined with a wall somewhat thickened around it. The oocyst residuum is conspicuous and granular; the polar granule is absent (Figs. 8B and 8D). The sporocyst is oblong to ovoidal, measuring 10.97 µm (9.04–13.02 µm) in length and 6.38 µm (5.74–7.77 µm) in width (Figs. 8B and 8D). The Stieda body is small (Fig. 8B), and substieda and parastieda bodies are absent. The sporocyst residuum is small or a round, compact mass (Figs. 8B and 8D). Sporozoites are elongate, lying lengthwise head to tail in sporocysts, each with one clear refractile body at the larger end (Figs. 8B and 8D).

Unsporulated oocysts are piriform, measuring 23.9 µm (20.97–25.92 µm) in length and 163.83 µm (13.71–20.34 µm) in width, with a conspicuous micropyle (Figs. 8A and 8C). The sporoblast (zygote) is spherical to subspherical, measuring 15.22 µm (14.85–15.8 µm) in length and 14.31 µm (11.87–16.57 µm) in width (Figs. 8A and 8C).

Endogenous stages (Fig. 9):

Examination of the histological section of the ileum revealed the presence of microgametes, macrogametes, and oocysts. The early microgamonts were recognized by their large number of dark small nuclei distributed throughout the entire surface of the gamont. The macrogametes were distinguishable from microgametes by their large central nucleus with a prominent nucleolus and the appearance of wall-forming bodies at their periphery. Numerous oocysts at different stages of maturation could be distinguished within parasitophorous vacuoles.

Transmission electron microscopy (Figs. 10–12):

Microgametogenesis (Fig. 10): The developing microgamonts increased in length and eventually became detached and occupied the parasitophorous vacuole. As the development of microgamonts proceeded, the microgametes began to differentiate. The fully formed microgamete had an elongated nucleus and a tubular mitochondrion, and two flagella were clearly observed. The nucleus occupied nearly all the microgamete space, and a single stretched mitochondrion was present in the nuclear depression and extended along the anterior half of the microgamete nucleus.

Macrogametogenesis (Fig. 11): The electron microscopic study revealed that a mature macrogamete was characterized by a large central nucleus with a prominent nucleolus. The most significant structure was the appearance of the so-called wall-forming bodies (WFB). Two types of WFBs (WFBI and WFBII) were detected. These stages were abundantly supplied with backup nutrients, amylopectin granules, and lipid droplets that were clearly visible within this stage.

Oocyst development (Fig. 12): The dissociation and progressive disappearance of WFBs were related to the onset of the appearance of the inner wall and the outer wall of the oocyst. After the completion of the formation of the oocyte wall, the WFBs were no longer observed (Fig. 12B).

***9. Eimeria stiedae* (Lindemann, 1865) Kisskalt and Hartmann, 1907**

Synonymy: *Monocystis stiedae* Lindemann, 1865; *Psorospermium cuniculi* Rivolta, 1878; *Coccidium oviforme* Leuckart, 1879; *Coccidium cuniculi* (Rivolta, 1878) Labbe´, 1899; *Eimeria cuniculi* (Rivolta, 1878) Wasielewski, 1904; *Eimeria oviformis* (Leuckart, 1879) Fantham, 1911; *Eimeria stiedae* var. *cuniculi* Graham, 1933.

Host: Domestic rabbit, *Oryctolagus cuniculus* (L., 1758) (syn. *Lepus cuniculus*).

Locality: Qena Governorate, Upper Egypt.

Prevalence: 2% (2/100)

Sporulation time: 58h

Description (Tables 1 and 2, Fig. 13):

Sporulated oocysts are ovoid, measuring 28.13 µm (27.65 - 28.44 µm) in length and 16.99 µm (16.55 - 17.66 µm) in width. The micropyle is smooth at the narrow end of the oocyst, sometimes inapparent (Figs. 13B and 13D). The oocyst residuum and the polar granule are absent (Figs. 13B and 13D). The sporocyst is elongate ovoidal, measuring 11.01 µm (10.82 -11.18 µm) in length and 5.89 µm (5.67 - 6.03 µm) in width (Figs. 13B and 13D). The Stieda body is present (Fig. 13D), and substieda and parastieda bodies are absent. The sporocyst residuum is granular (Figs. 13B and 13D). Sporozoites are elongate (Figs. 13B and 13D).

Unsporulated oocysts are ovoid, measuring 27.31 µm (26.58 - 27.74 µm) in length, 17.37 µm (16.74 - 17.86 µm) in width, with an inconspicuous micropyle (Figs. 13A and 13C). The sporoblast (zygote) is spherical, measuring 17.05 µm (16.55 - 17.38 µm) in length and 15.24 µm (14.88 - 15.46 µm) in width (Figs. 13A and 13C).

***10. Eimeria vejdovskyi* Pakandl, 1988**

Synonymy: *Eimeria media* Kessel, 1929

Host: Domestic rabbit, *Oryctolagus cuniculus* (L., 1758) (syn. *Lepus cuniculus*).

Locality: Qena Governorate, Upper Egypt.

Prevalence: 5% (5/100)

Sporulation time: 48h

Description (Tables 1 and 2, Fig. 14):

Sporulated oocysts are ovoid, measuring 28.64 µm (27.27 - 30.44 µm) in length, 18.97 µm (18.08 - 20.27 µm) in width. There are two oocyst walls; the outer wall is smooth and interrupted by the micropyle, while the inner wall is flattened or slightly concave. The micropyle is present. The oocyst residuum is spheroidal and composed of many granules, and the polar granule is absent (Figs. 14B and 14D). The sporocyst is fusiform, measuring 13.55 µm (12.68 - 14.48 µm) in length and 7.32 µm (7.07 - 7.79 µm) in width (Figs. 14B and 14D). The Stieda body is small and flat (Fig. 14B) and substieda and parastieda bodies are absent. The sporocyst residuum is compact and composed of rough granules near the sporocyst wall (Figs. 14B and 14D). Sporozoites lay end-to-end, each with a large refractile body at the more rounded end (Figs. 14B and 14D).

Unsporulated oocysts are ovoid, measuring 29.97 µm (29.56 - 30.58 µm) in length and 18.14 µm (17.93 - 18.45 µm) in width, with a conspicuous micropyle (Figs. 14A and 14C). The sporoblast (zygote) is spherical, measuring 15.14 µm (15.04 - 15.36 µm) in length and 16.2 2 µm (15.99 - 16.61 µm) in width (Figs. 14A and 14C).

***11. Eimeria piriformis* Kotla´n and Pospesch, 1934**

Synonymy: *Eimeria pyriformis* Kotla´n and Pospesch, 1934 *lapsus calami*; non *Eimeria piriforsmis* Lubimov, 1934; *Eimeria piriformis* Marotel and Guilhon, 1941; non *Eimeria pellerdyi* Prasad, 1960; non *Eimeria pellerdyi* Coudert, 1977a, b.

Host: Domestic rabbit, *Oryctolagus cuniculus* (L., 1758) (syn. *Lepus cuniculus*).

Locality: Qena Governorate, Upper Egypt.

Prevalence: 3% (3/100)

Sporulation time: 40h

Description (Tables 1 and 2, Fig. 15):

Sporulated oocysts are piriform, measuring 23.98 µm (22.2 - 25.12 µm) in length and 18.25 µm (17.93 -18.51 µm) in width. There are two smooth oocyst walls and the outer wall is thickened around the micropyle. The micropyle is prominent, located at the narrow end of the oocyst and surrounded by the thickened outer wall. The oocyst residuum and polar granule are absent (Figs. 15B and 15D). Sporocysts are ovoidal to spindle-shaped, measuring 10.54 µm (10.4 - 10.71 µm) in length and 6.42 µm (6.15 - 6.66 µm) in width (Figs. 15B and 15D). The Stieda body is apparently present at the pointed end of the sporocyst (Fig. 15B) and substieda and parastied bodies are absent. The sporocyst residuum is granular and usually located in the center of the sporocyst (Figs. 15B and 15D). Sporozoites are elongate, lay head-to-tail in the sporocyst, each with one end being wider than the other and with one clear refractile body at the wider end (Figs. 15B and 15D).

Unsporulated oocysts are piriform, measuring 25.68 µm (24.35 - 26.83 µm) in length and 20.12 µm (18.58 - 21.13 µm) in width, with a conspicuous micropyle (Figs. 15A and 15C). The sporoblast (zygote) is spherical, measuring 15.44 µm (14.32 - 16.14 µm) in length and 13.87 µm (13.05 - 14.53 µm) in width (Figs. 15A and 15C).

A Key to *Eimeria* spp. infecting domestic rabbits:

1- Oocysts piriform …… 2

Oocysts ovoid or ellipsoid ……..... 3

Oocysts spherical or cylindrical …….…….. 7

2- Oocyst residuum present..... *E. intestinalis*

Oocyst residuum absent……. *E. piriformis*

3- Oocysts ovoid …… 4

Oocysts ellipsoid ……..... 6

4- With micropyle and oocyst residuum; collar-like thickening of outer wall layer around micropyle…….…….…… *E. magna*

With normal micropyle and oocyst residuum…… *E. vejdovesky*

With micropyle and without oocyst residuum …….…… 5

5- With prominent micropyle …….…….. *E. flavescens*

With smooth micropyle, sometimes inapparent..... *E. stiedae*

6- No apparent micropyle; with variable oocyst residuum, spherical, triangular or composed of a chain of granules.....……*E.perforans*

With micropyle and spherical oocyst residuum ……. …….. *E. media*

With conspicuous micropyle and without oocyst residuum……. *E. irresidua*

7- Oocyst spherical, micropyle and oocyst residuum absent …….…… *E. exigua*

Oocyst cylindrical, well-pronounced micropyle and rounded oocyst residuum …… *E. coecicola*

Discussion

Mixed infection with more than one species of *Eimeria* was the most common in this study, which is consistent with previous studies. This can be attributed to the nature of food that may be contaminated with several types of parasites.

The present study carefully reviewed the descriptions of the 11 valid species of *Eimeria* among domestic rabbits, *Oryctolagus cuniculus* (all including descriptions supported with clear illustrations). The morphological and morphometric characters of the sporulated oocysts of each *Eimeria* species are comparatively consistent with those reported by the previous studies. Lie *et al.* (2016) observed that the unsporulated morphology characteristics between *E. vejdovskyi* and *E. coecicola* as well as between *E. piriformis* and *E. intestinalis* were similar. They did not differentiate *E. vejdovskyi* from *E. coecicola* and *E. piriformis* from *E. intestinalis* based on their unsporulated morphological features.

In the present study, *Eimeria exigua* and *E. perforans* lack their micropyle. Additionally, oocyst residuum is absent in *E. exigua*, *E. flavescens*, *E. irresidua*, *E. stiedae* and *E. piriformis*.

The sporocyst residuum was not mentioned in the described species of *Eimeria* by Kasim and Al-Shawa (1987). El-Shahawy *et al.* (2012) and El-Shahawy and El-Goniemy (2018) did not mention the sporocyst

residuum and the prevalence of infection for their examined *Eimeria* species. The size of sporoblast was not mentioned in the description of *Eimeria* species given by Li *et al.* (2016).

In addition to, there are some minor observations as follows: (i) the oocysts and sporocysts of *Eimeria flavescens*, *E. magna*, *E. media*, *E. intestinalis* and *E. stiedae* in the present study are larger than those described by El-Shahawy *et al.* (2012) and Abdel-Baki and Al-Quraishy (2013), (ii) the micropyle of *E. flavescens* was absent in the specimens described by El-Shahawy *et al.* (2012) and it was present in *E. perforans* collected by El-Shahawy *et al.* (2012) and Abdel-Baki and Al-Quraishy (2013) and *E. vejdovskyi* examined by Pakandl (1988), (iii) the sporocyst residuum of *E. magna* and *E. media* was absent in the description provided by Abdel-Baki and Al-Quraishy (2013) and (iv) the oocyst residuum of *E. stiedae* was absent in the description provided by El-Shahawy *et al.* (2012) and Abdel-Baki and Al-Quraishy (2013), in which it was present in *E. irresidua* described by Norton *et al.* (1979), *E. magna* examined by Kasim and Al-Shawa (1987), El-Shahawy *et al.* (2012), Abdel-Baki and Al-Quraishy (2013) and El-Shahawy and El-Goniemy (2018) and *E. vejdovskyi* collected by Pakandl (1988).

Endogenous stages:

In the present study, macrogamonts, microgamonts, and oocysts were observed together. These observations were in agreement with the results reported by El-Shahawy *et al.* (2012) in *E. intestinalis* and those reported by El-Sayed *et al.* (2020) in different *Eimeria* spp.

Transmission electron microscopic studies were performed on the endogenous stages of *E. intestinalis*, merozoite formation (Snigirevskaya, 1969, Licois *et al*., 1992), microgametogenesis (Kheysin, 1958), and merogony and gametogony (El Fayoumi and Abdel-Haleem 2014).

Licois *et al.* (1992) conducted transmission electron microscopic studies on this species collected from domestic rabbits in France. They reported four merogonous (asexual) generations. El Fayoumi and Abdel-Haleem (2014) also performed transmission electron microscopic studies on this species collected from domestic rabbits in Egypt. They reported four asexual generations (merogony) and gametogony. In the present study, gametogony was clearly consistent with that reported by El Fayoumi and Abdel-Haleem (2014). The present study has described the stage of oocyst formation for the first time on the basis of previous studies.

The elongation of the microgamete nucleus results in a finger-like protrusion that fuses one mitochondrion with flagellar buds and finally develops into a microgamete. These observations were recorded for other *Eimeria* species (Kheysin 1965; Scholtyseck 1973; Abdel-Ghaffar *et al.,* 1990 and Al-Ghamdy *et al.,* 2005). At least two definite flagella were recorded in each mature microgamete. This result was similar to that of *E. intestinalis* (Kheysin 1965; El Fayoumi and Abdel-Haleem 2014).

The present study showed that the developing macrogametes have two types of WFBs (WFBI and WFBII). As the development proceeded, WFBI was arranged more peripherally, whereas WFBII was arranged approximately centrally, and a large amount of food reserve (amylopectin granules and lipid droplets)

was observed in the cytoplasm of mature macrogametes. Similar observations have been reported (Dai *et al.,* 2005 and Bashtar *et al.,* 2010). After fertilization, the WFBs fuse together, giving rise to the oocyst wall. The appearance of the double-layered oocyst wall is generally accompanied by the disappearance of the WFBs in the young oocyst. These results are consistent with previously reported findings in several *Eimeria* species (Teixeira et al. 2004; Bashtar *et al.,* 2010 and El-Shahawi *et al.,* 2012).

Host- specificity:

Host specificity in *Oryctolagus cuniculus* seems fairly strict. Based on the evidence available at this time, the majority of valid intestinal species are reported only from *Oryctolagus cuniculus* with a few isolated, and questionable, reports from *Lepus* and/or *Sylvilagus* species, but without supporting cross-transmission or molecular work; these include *E. coecicola*, *E. exigua*, *E. flavescens*, *E. intestinalis*, *E. piriformis*, and *E. vejdovskyi*. Of the remaining four intestinal species, *E. irresidua*, *E. magna*, *E. media*, *E. perforans* were discovered first in *O. cuniculus*, but have been transmitted to at least one species of *Sylvilagus*; none of these has yet been transmitted to *Lepus* species. The only species to infect the liver, *E. stiedai*, is the least specific of the eimerians of *O. cuniculus*, as it is known to also infect both *Lepus* and *Sylvilagus* species, both naturally and experimentally (Duszynski and Couch 2013).

Conclusion

Eimeria stiedae, *E. irresidua*, and *E. vejdovskyi* were described for the first time in Qena Governorate, Upper Egypt. Domestic rabbits in Egypt are at potential risk for coccidiosis, and it is necessary to conduct further studies on the epidemiology of coccidiosis to control this disease. Further molecular studies are also recommended to justify the true taxonomic position of these species.

Declarations

Compliance with Ethical Standards

Conflict of interest The authors declare that they have no conficts of interest.

Ethical standards This article does not contain any studies with human participants or animals performed by any of the authors.

References

1. Abd El Rahman MM (1979) Chemotherapy of hepatic coccidiosis of rabbits. Master Thesis, Assiut University
2. Abdel-Baki AS, Al-Quraishy, S (2013) Prevalence of Coccidia (*Eimeria* spp.) infection in Domestic Rabbits, *Oryctolagus cuniculus*, in Riyadh, Saudi Arabia. Pak J 45: 1329–1333
3. Ahmed AT (1952) The problem of coccidiosis of the rabbit in Egypt. Master Thesis, Cairo University

4. Ahmed NE (1983) Some biological studies on *Eimeria magna* in rabbit using electron microscope, Ph.D. Thesis, Zagazig University
5. Al-Mathal EM (2008) Hepatic coccidiosis of the domestic rabbit Oryctolagus cuniculus domesticus L. in Saudi Arabia. World Journal of Zoology (WJZ) 3(1): 30–35
6. Bashtar A, Abdel-Ghaffar F, Al-Rasheid K, Mehlhorn H, Al Nasr I (2010) Light microscopic study on *Eimeria* species infecting Japanese quails reared in Saudi Arabian farms. Parasitol Res 107: 409–416
7. Chowdhury AA, Fraser GC (2008) Coccidia (*Eimeria* spp.) of domestic rabbits in New South Wales. Aust Vet J 86: 365–366
8. Coudert P, Licois D, Drouet-viard F (1995) *Eimeria* species and strains of rabbit. In: Eckert, J., Braun, R., Shirley, M.W. and Coudert, P. (eds.) Biotechnolohy: guidelines on techniques in coccidiosis research. Office for Official Publications of the European Communities, Luxembourg, pp 52-73
9. Dai Y, Liu X, Lju M, Tao J (2005) The life cycle and pathogenicity of the coccidium *Eimeria nocens* (Kotlan, 1933) in domestic goslings. J Parasitol 91: 1122–1125
10. Darwish AI, Golemansky V (1991) Coccidian parasites (Coccidia: Eimeriidae) of domestic rabbits (*Oryctolagus cuniculus domesticus* L.) in Syria. Acta Protozool 31: 209–216
11. Duszynski DW, Couch L (2013) The biology and identification of the Coccidia (Apicomplexa) of rabbits of the world. Newnes, Oxford, United Kingdom
12. Eckert J, Taylor M, Catchpole J, Licois D, Coudert P, Bucklar H (1995) Identification of *Eimeria* species and strains, “Morphological characteristics of oocysts” In: Eckert, J., Braun, R., Shirley, M.W., Coudert, P. (eds) Biotechnology: Guidelines on techniques in coccidiosis research. Office for Official Publications of the European Communities, Luxembourg, pp 103-119
13. Eid AAM, Ibraheem OK (2006) Sudden death among rabbits in Sharkia Province, Egypt. Zagazig Vet J 34: 108–119
14. El Fayoumi H, Abdel-Haleem HM (2014) Electron microscopic study of the developmental stages of *Eimeria intestinalis* Cheissin, 1948 in domestic rabbit (*Oryctolagus cuniculus*) with reference to endodyogeny. J Egypt Soc Parasitol 44(3): 531–538
15. El Masry NMM (1983) Problems of coccidiosis in rabbits, Master thesis, Zagazig University
16. El-Sayed N, Metwally MMM, Ras R (2020) Prevalence and morphological identification of *Eimeria* spp. in domestic rabbit (*Oryctolagus cuniculus*) in Sharkia province, Egypt. Egyptian Veterinary Medical Society of Parasitology Journal (EVMSPJ) 16: 114–130
17. El-Shahawi GA, El-Fayomi H, Abdel-Haleem HM (2012) Coccidiosis of domestic rabbit (*Oryctolagus cuniculus*) in Egypt: Light microscopic study, Parasitol Res 110: 251–258
18. El-Shahawy I, El-Goniemy A (2018) An Epidemiological Study on Endoparasites of Domestic Rabbits (*Oryctolagus cuniculus*) in Egypt with Special Reference to Their Health Impact. Sains Malays 47(1): 9–18

19. Fahmy MF, Anisa M, Moustafa AGM (1985) Pathological studies on rabbit diseases. Zagazig Vet J 12: 285–304
20. Flatt RE, Campbell WW (1974) Cysticercosis in rabbits: incidence and lesions of the naturally occurring disease in young domestic rabbits. Lab Anim Sci 24: 914–918
21. Ghanem IA, Ismail AN (1992) Occurrence of rabbit haemorrhagic disease in Sharkia province. Zagazig Vet J 20: 491–502
22. Gill BS, Ray HN (1960) The coccidia of domestic rabbit and the common field hare of India. Proceedings of the Zoological Society of Calcutta, 13: 129–143
23. Haiba MH, Fahmy MAM, Abodou AH, Selim MK (1955) Survey on the incidence of parasites in farm animals of Faculty of Agriculture, Giza, Egypt. Vet Med J 2: 181–186
24. Hamed SH (1988) Some biological and immunological studies on *E. stiedae* of rabbits under the Egyptian environment condition. Master Thesis, Cairo University
25. Hansen J, Perry BD (1994) The epidemiology, diagnosis and control of helminth parasites of ruminants. The International Laboratory for Research on Animal Diseases, Nairobi, Kenya
26. Helmy NA (2002) Evaluation of counter immune electrophoresis and ELISA for immune diagnosis of rabbits experimentally infected with *Eimeria stiedae*. Master thesis, Zagazig University
27. Ibraheem OK (1999) Some pathological causes of diarrhea in rabbits, Zagazig Vet J 27: 92–101
28. Jelı´nkova´ A, Licois D, Pakandl M (2008) The endogenous development of the rabbit coccidium *Eimeria exigua* Yakimoff, 1934. Vet Parasitol 156: 166–172
29. Kasim AA, Al-Shawa YR (1987) Coccidia in rabbits (*Oryctolagus cuniculus*) in Saudi Arabia. Int J Parasitol 17: 941– 944
30. Kessel JF (1929) The *Eimeria* of the domestic rabbits. Journal of Parasitology, 16, p. 100 (abstract)
31. Kessel JF, Jankiewicz HA (1931) Species differentiation of the coccidia of the domestic rabbit based on a study of the oo¨cysts. Am J Hyg 14: 304–324
32. Kheysin YM (1958) Cytologische untersuchungen verschiedener Stadien des Lebenszyklus der Kaninchencoccidien. I. *Eimeria intestinalis* Cheissin 1948. Arch. Protistenk 102: 265–89 (in German)
33. Kheysin YM (1965) Electron microscopic study of microgametogenesis in two species of coccidia from rabbit (*Eimeria magna* and *E. intestinalis*). Acta Protozool 3: 215–234
34. Kutkat MA, Zayed AA, El Ezz A, Nadia MT (1998) A trial for immunization of rabbit against hepatic coccidiosis. Zagazig Vet J 26: 70–77
35. Kvičerová J, Pakandl M, Hypša V (2008) Phylogenetic relationships among *Eimeria* spp. (Apicomplexa, Eimeriidae) infecting rabbits: Evolutionary significance of biological and morphological features. Parasitology 135: 443–452
36. Lebdah MA, Shahn AM (2011) Closteridia as an etiological agent of mucoid enteropathy in rabbits. Nat Sci 9: 63–72
37. Levine ND, Ivens V (1972) Coccidia of the Leporidae. J Protozool 19: 572–581

38. Li H, Shen M, Hou Z, Yin X (2016) Morphology and Molecular Identification of the *Eimeria* spp. in Domestic Rabbits. Pak J Zool 48(1): 289–291
39. Li M-H, Huang HI, Ooi H-K (2010) Prevalence, infectivity and oocyst sporulation time of rabbit-coccidia in Taiwan. Trop Biomed 27: 424–429
40. Licois D, Coudert P, Bahagia S, Rossi GL (1992) Endogenous development of *Eimeria intestinalis* in the rabbit (*Oryctolagus cuniculus*). J Parasitol 78: 1041–1048
41. Lindemann K (1865) Weiteres u¨ ber Gregarinen, Bulletin de la Socie´te´ Impe´riale des Naturalistes de Moscow, 38: 381–387 (in German)
42. Long PL, Joyner LP, Millard BJ, Norton C (1976) A guide to laboratory techniques used in the study and diagnosis of avian coccidiosis, Folia Veterinaria, 6: 201–207
43. Mandal AK (1976) Coccidia of Indian vertebrates. Records of the Zoological Survey of India, 70: 39–120
44. Mekawy SAM (1997) Clinic pathologic studies on liver coccidiosis in rabbits. Master thesis, Zagazig University
45. Mirza MY (1970) Incidence and distribution of coccidian (Sporozoa: Eimeriidae) in mammals from Baghdad area. Master Thesis, University of Baghdad
46. Mohamed EAM (1997) Clinico pathological studies on the immunity status post infestation with hepatic coccidiosis in rabbit. Master thesis, Zagazig University
47. Musongong GA, Fakae BB (1999) Prevalence of *Eimeria stiedai* infection in outbred domestic rabbits (*Orytolagus cuniculus*) in eastern Nigeria. Revue d'élevage et de médecine vétérinaire des pays tropicaux, 52: 117–118
48. Norton CC, Catchpole J, Joyner LP (1979) Redescriptions of *Eimeria irresidua* Kessel & Jankiewicz, 1931 and *E. flavescens* Marotel & Guilhon, 1941 from the domestic rabbit. Parasitology 79: 231–248
49. Ola-Fadunsin SD, Nuhu AA, Fabiyi JP, Sanda IM, Hussain K, Rabiu M, Ganiyu IA (2019) Prevalence and associated risk factors of *Eimeria* species in rabbits (*Oryctolagus cuniculus*) in Ilorin, Kwara State, Nigeria. Ann parasitol 65(3): 267–237
50. Oliveira UC, Fraga JS, Licois D, Pakandl M, Gruber A (2011) Development of molecular assays for the identification of the 11 *Eimeria* species of the domestic rabbit (*Oryctolagus cuniculus*). Vet Parasitol 176: 275–280
51. Oncel T, Gulegen E, Senlik B, Bakirci S (2011) Intestinal coccidiosis in angora rabbits (*Oryctolagus cuniculus*) caused by *Eimeria intestinalis*, *Eimeria perforans* and *Eimeria coecicola*. YYU Vet Fak Derg 22(1): 27–29
52. Pakandl M (1988) Description of *Eimeria vejdovskyi* sp. n. and redescription of *Eimeria media* Kessel, 1929 from the rabbit. Folia Parasitol (Praha) 35: 1–9
53. Pakandl M (1989) Life cycle of *Eimeria coecicola* Cheissin, 1947. Folia Parasitol (Praha) 36: 97–105
54. Pakandl M (2009) Coccidia of rabbit: a review. Folia Parasitol 56: 153–166

55. Peeters JE, Geeroms R, Froyman R, Halen P (1981) Coccidiosis in rabbits: a field study. Res Vet Sci 30: 328–334
56. Rashed EAO (1993) Survey on parasitic diseases of rabbits. Master thesis, Zagazig University
57. Saad FES (1970) Studies on some infectious diseases of rabbits in UAR with special reference to *E. coli* infection and pasteurellosis. Master thesis, Cairo University
58. Snigirevskaya ES (1969) Electron microscopic study of the schizogony process in *Eimeria intestinalis*. Acta Protozool 7: 57–79
59. Taha A (1952) Coccidiosis of rabbits. Master Thesis, Cairo University
60. Teixeira M, Teixeira FWL, Lopes CWG (2004) Coccidiosis in Japanese quails (*Coturnix japonica*): characterization of a naturally occurring infection in a commercial rearing farm. Rev Bras Cienc Avic 6: 129–134
61. Vancraeynest D, De Gussem M, Marien M, Maertens L (2008) The anticoccidial efficacy of robenidine hydrochloride in *Eimeria* challenged rabbits. Proceedings of the 9th World Rabbit Congress, Verona, Italy
62. Yakhchali M, Tehrani A (2007) Eimeriidosis and pathological findings in New Zealand white rabbits. J Biol Sci 7: 1488–1491

Tables

Due to technical limitations, tables are only available as a download in the Supplemental Files section.

Figures

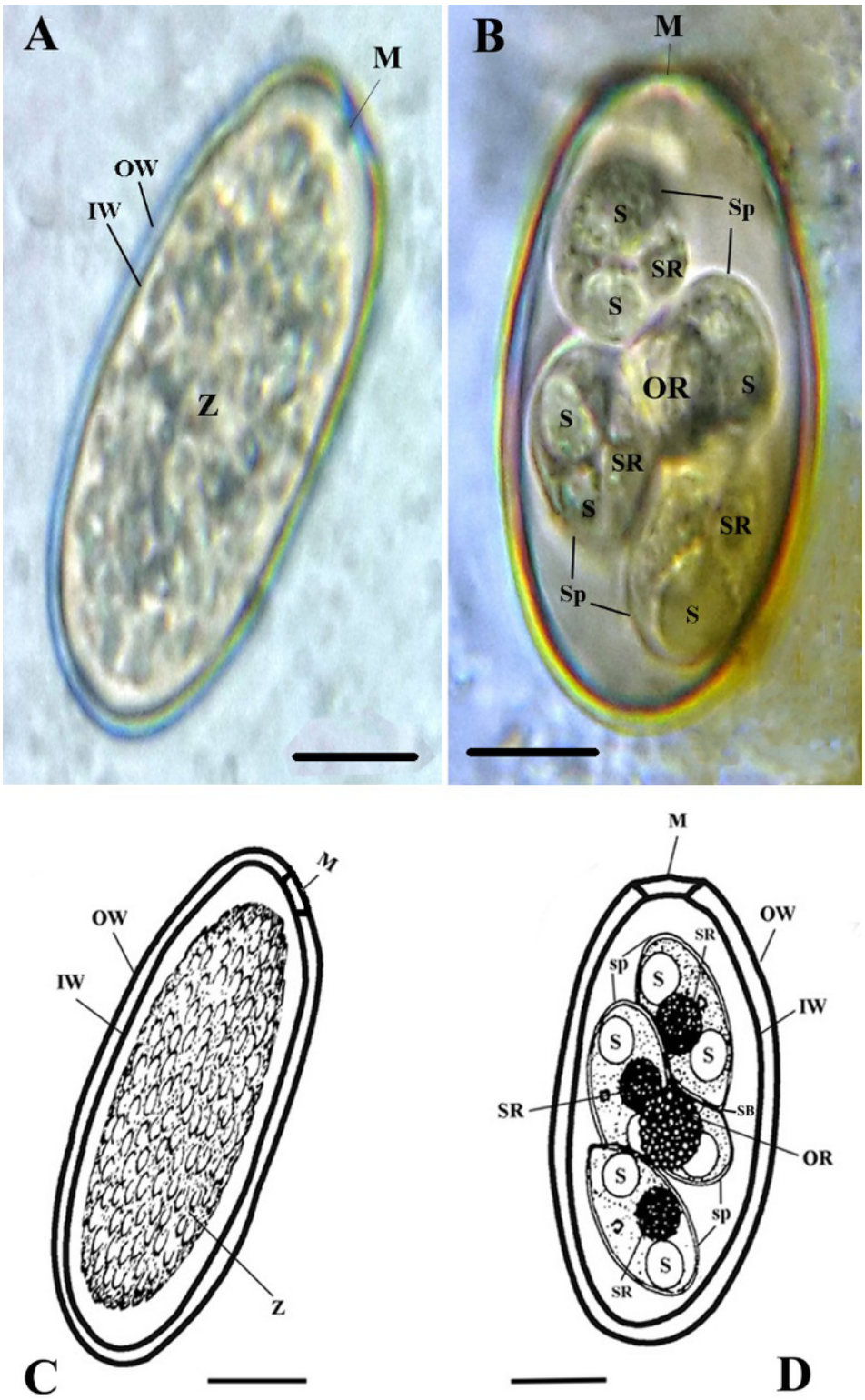

Figure 1

Eimeria coecicola collected from domestic rabbits, Oryctolagus cuniculus in Qena Governorate, Upper Egypt. Figs. (A and B): Light micrographs of unsporulated and sporulated oocysts respectively. Figs. (C and D): Line drawings of unsporulated and sporulated oocysts respectively. Scale bars, 5 µm. Abbreviations; IW, inner wall; M, micropyle; OW, outer wall; S, sporozoite; SP, sporocyst(s); SR, sporocyst residuum; OR, oocyst residuum; Z, zygote.

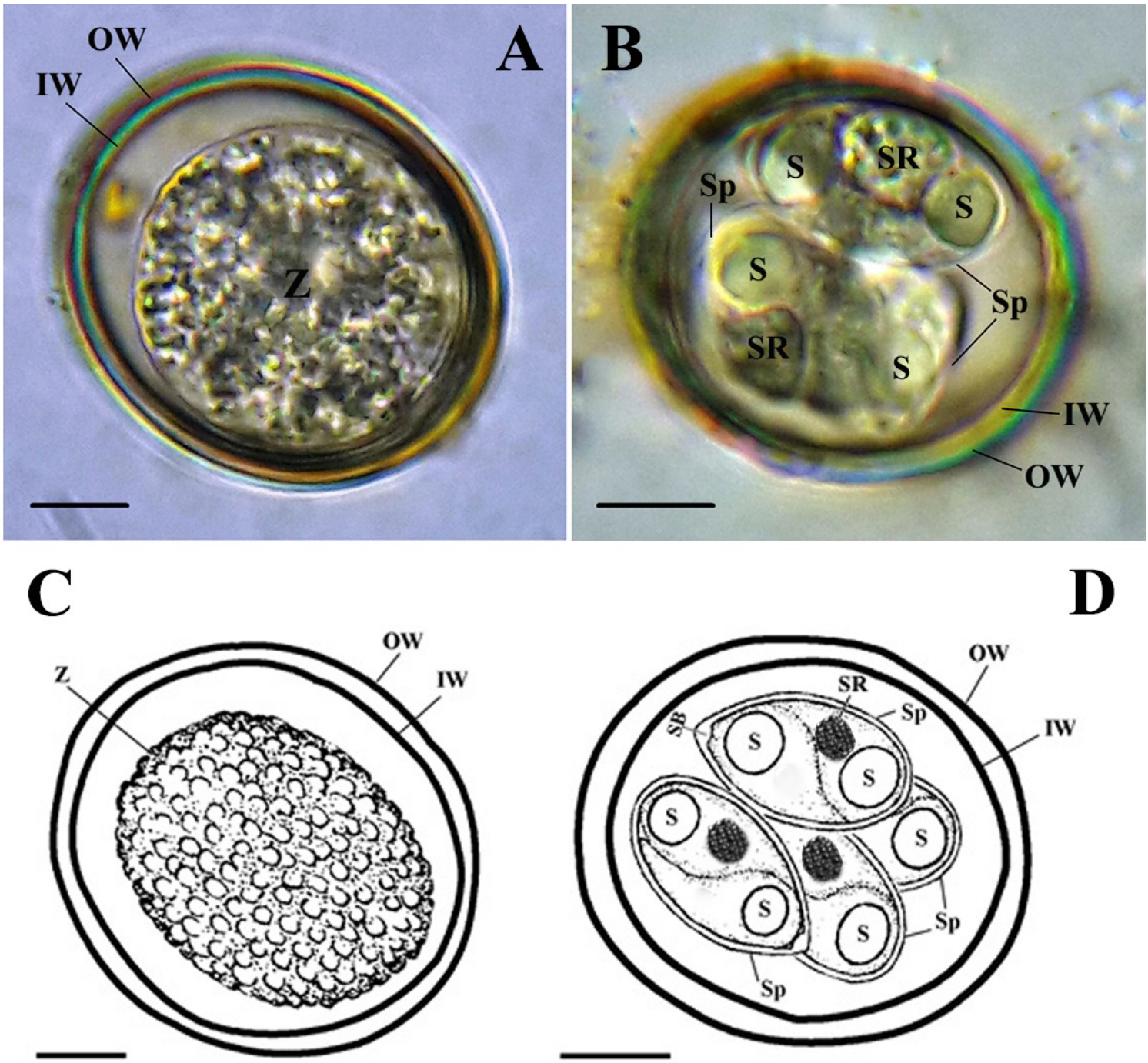

Figure 2

Eimeria exigua collected from domestic rabbits Oryctolagus cuniculus in Qena Governorate, Upper Egypt. Figs. (A and B): Light micrographs of unsporulated and sporulated oocysts respectively. Figs. (C and D): Line drawings of unsporulated and sporulated oocysts respectively. Scale bars, 5 µm. Abbreviations; IW, inner wall; OW, outer wall; S, sporozoite; SB, Stieda body; SP, sporocyst(s); SR, sporocyst residuum; Z, zygote.

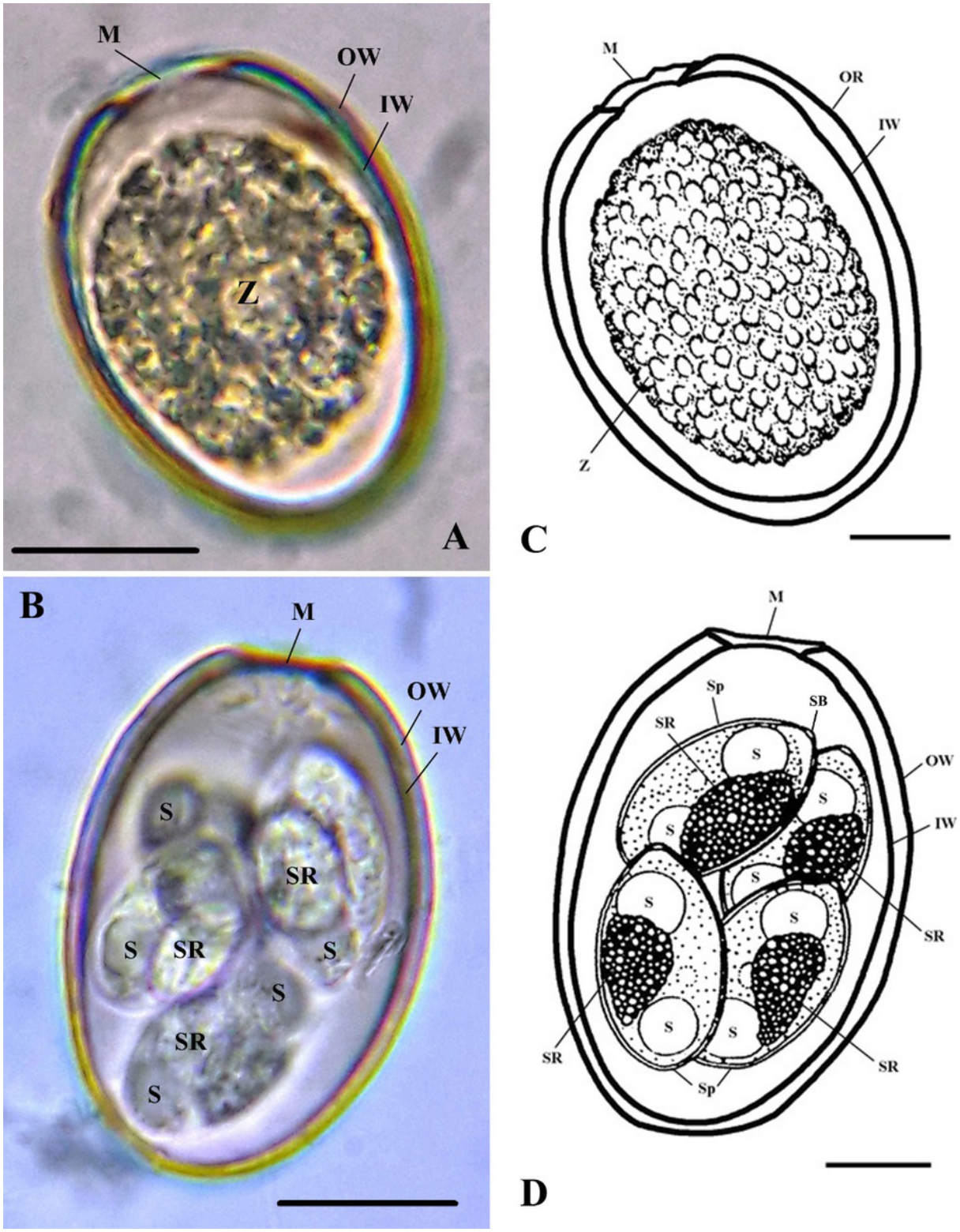

Figure 3

Eimeria flavescens collected from domestic rabbits, Oryctolagus cuniculus in Qena Governorate, Upper Egypt. Figs. (A and B): Light micrographs of unsporulated and sporulated oocysts respectively. Figs. (C and D): Line drawings of unsporulated and sporulated oocysts respectively. Scale bars, 10 µm. Abbreviations; IW, inner wall; M, micropyle; OW, outer wall; S, sporozoite; SP, sporocyst(s); SR, sporocyst residuum; Z, zygote.

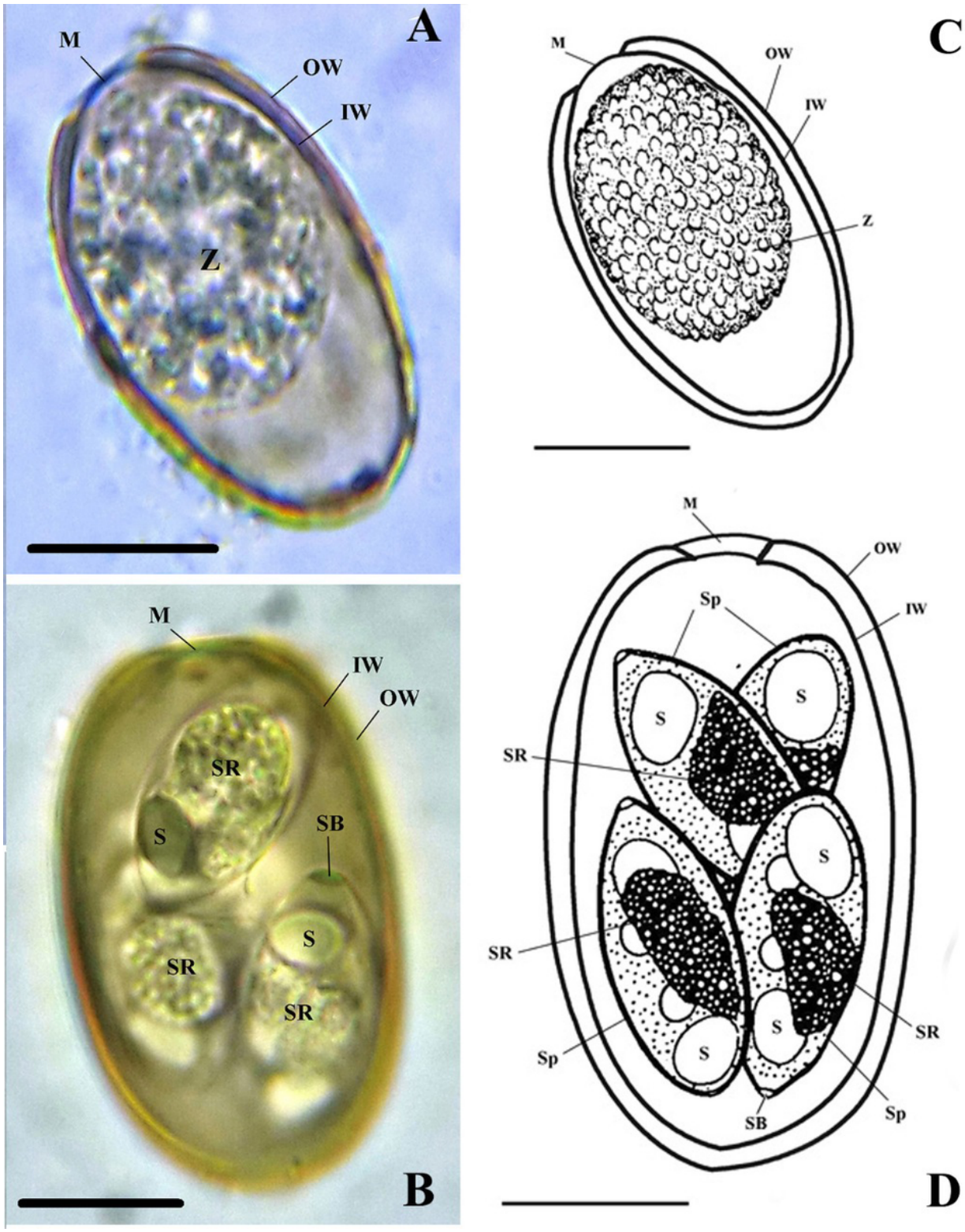

Figure 4

Eimeria irresidua collected from domestic rabbits, Oryctolagus cuniculus in Qena Governorate, Upper Egypt. Figs. (A and B): Light micrographs of unsporulated and sporulated oocysts respectively. Figs. (C and D): Line drawings of unsporulated and sporulated oocysts respectively. Scale bars, 10 µm. Abbreviations; IW, inner wall; M, micropyle; OW, outer wall; S, sporozoite; SB, Stieda body; SP, sporocyst(s); SR, sporocyst residuum; Z, zygote.

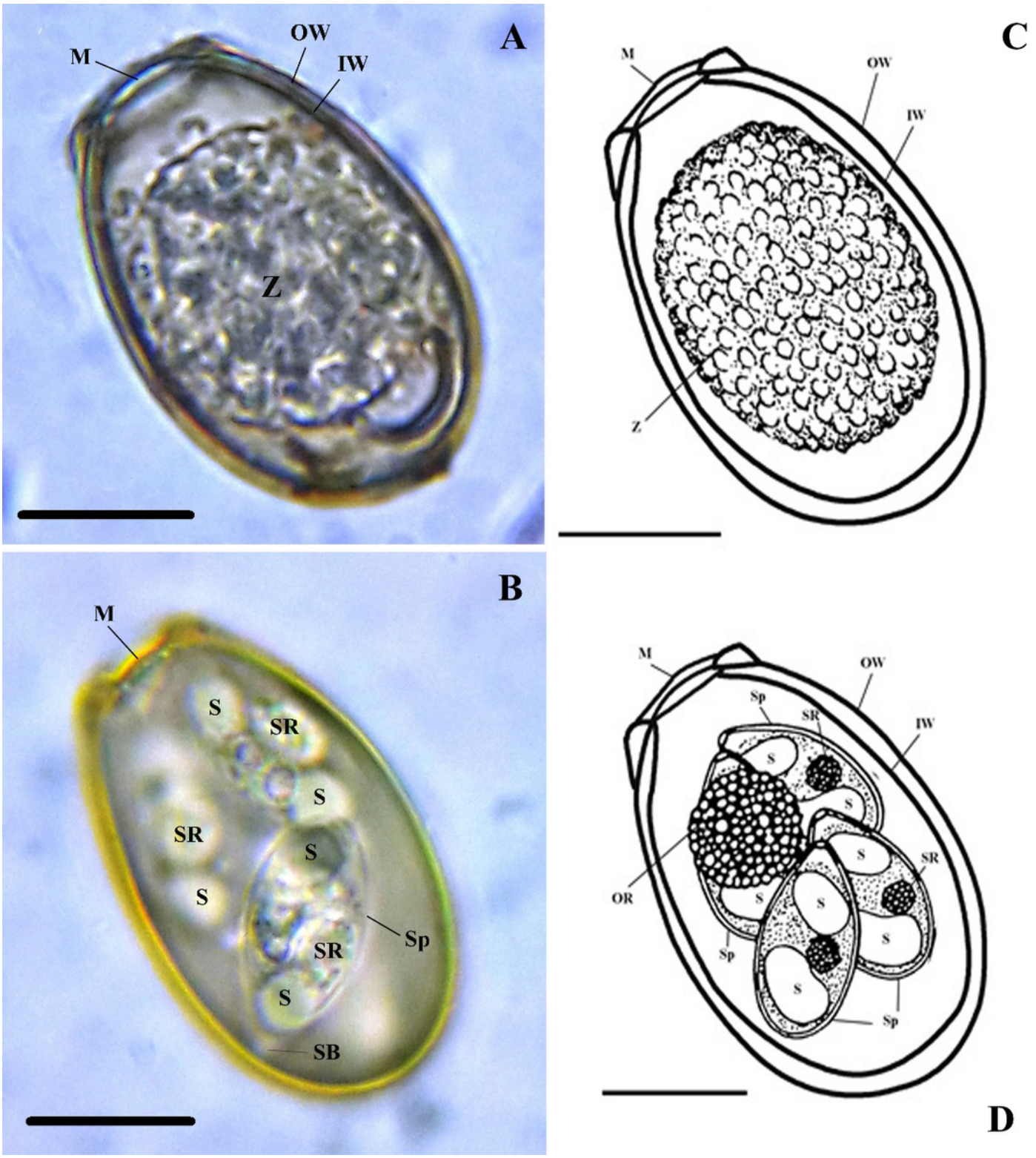

Figure 5

Eimeria magna collected from domestic rabbits, Oryctolagus cuniculus in Qena Governorate, Upper Egypt. Figs. (A and B): Light micrographs of unsporulated and sporulated oocysts respectively. Figs. (C and D): Line drawings of unsporulated and sporulated oocysts respectively. Scale bars, 10 µm. Abbreviations; IW, inner wall; M, micropyle; OW, outer wall; S, sporozoite; SB, Stieda body; SP, sporocyst(s); SR, sporocyst residuum; OR, oocyst residuum; Z, zygote.

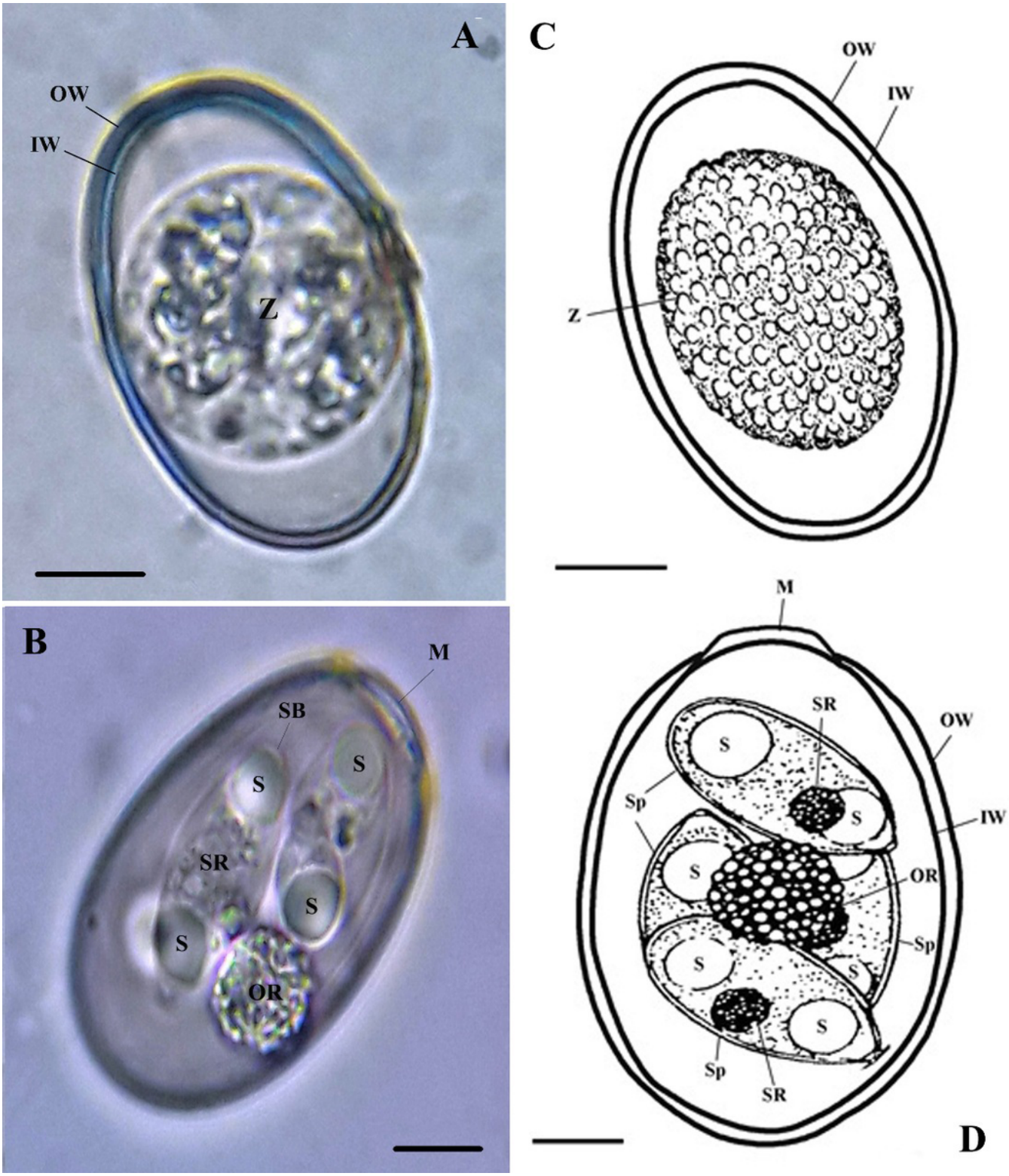

Figure 6

Eimeria media collected from domestic rabbits, Oryctolagus cuniculus in Qena Governorate, Upper Egypt. Figs. (A and B): Light micrographs of unsporulated and sporulated oocysts respectively. Figs. (C and D): Line drawings of unsporulated and sporulated oocysts respectively. Scale bars, 5 µm. Abbreviations; IW, inner wall; M, micropyle; OW, outer wall; S, sporozoite; SB, Stieda body; SP, sporocyst(s); SR, sporocyst residuum; OR, oocyst residuum; Z, zygote.

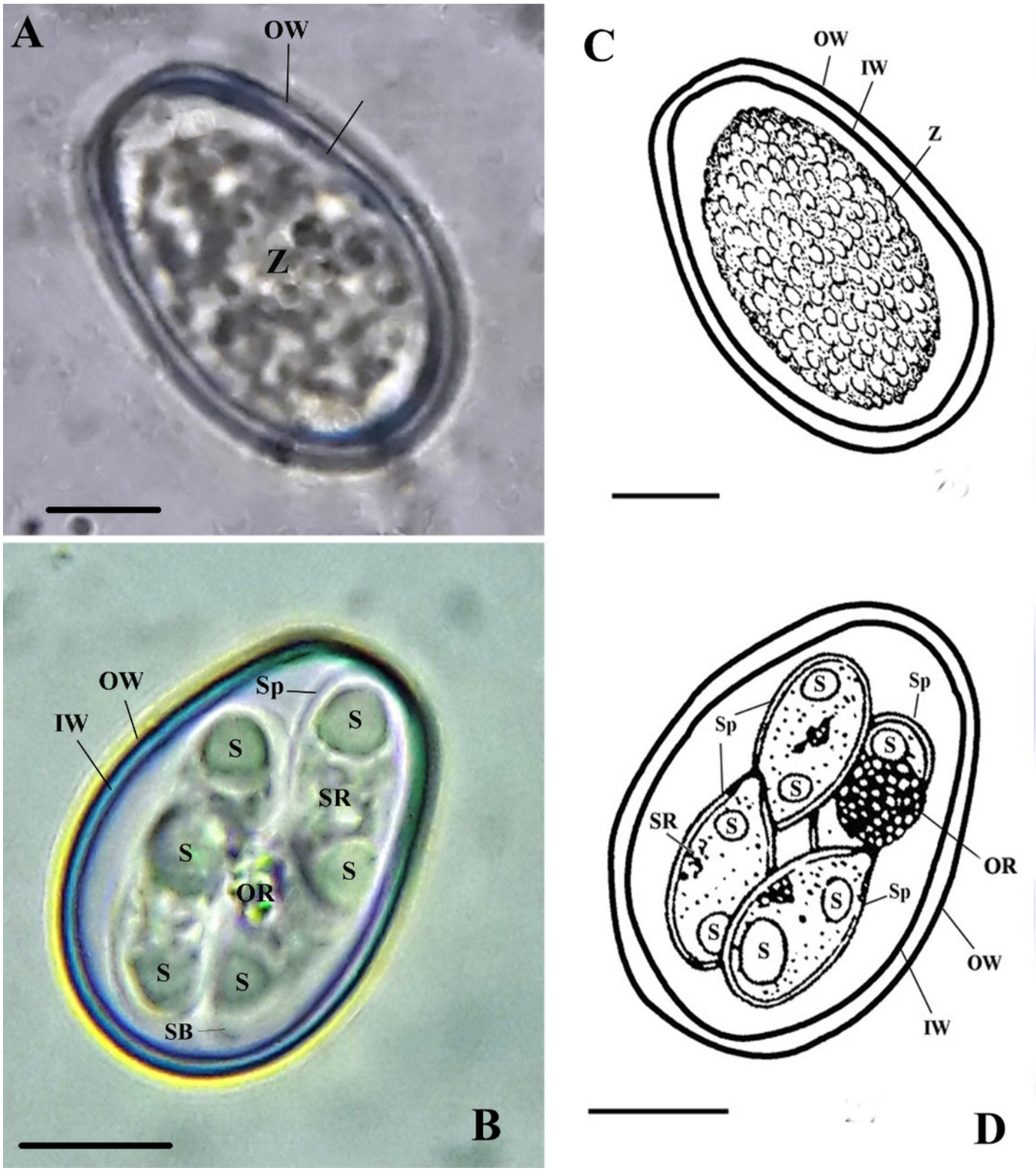

Figure 7

Eimeria perforans collected from domestic rabbits, Oryctolagus cuniculus in Qena Governorate, Upper Egypt. Figs. (A and B): Light micrographs of sporulated and unporulated oocysts respectively. Figs. (C and D): Line drawings of sporulated and unporulated oocysts respectively. Scale bars, 5 µm. Abbreviations; IW, inner wall; M, micropyle; OW, outer wall; S, sporozoite; SB, Stieda body; SP, sporocyst(s); SR, sporocyst residuum; OR, oocyst residuum; Z, zygote.

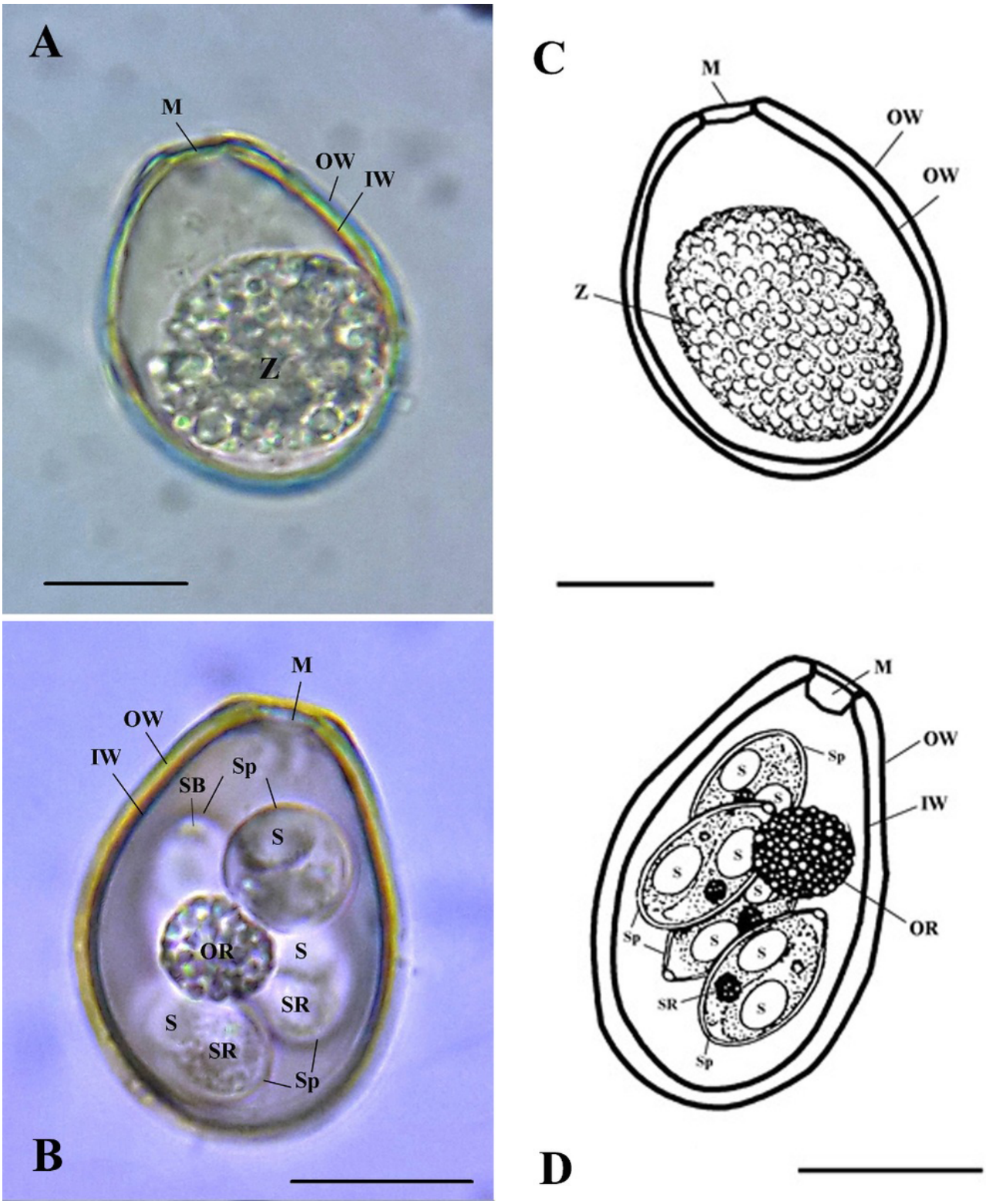

Figure 8

Eimeria intestinalis collected from domestic rabbits Oryctolagus cuniculus in Qena Governorate, Upper Egypt. Figs. (A and B): Light micrographs of sporulated and unporulated oocysts respectively. Figs. (C and D): Line drawings of sporulated and unporulated oocysts respectively. Scale bars, 10 µm. Abbreviations; IW, inner wall; M, micropyle; OW, outer wall; S, sporozoite; SB, Stieda body; SP, sporocyst(s); SR, sporocyst residuum; OR, oocyst residuum; Z, zygote.

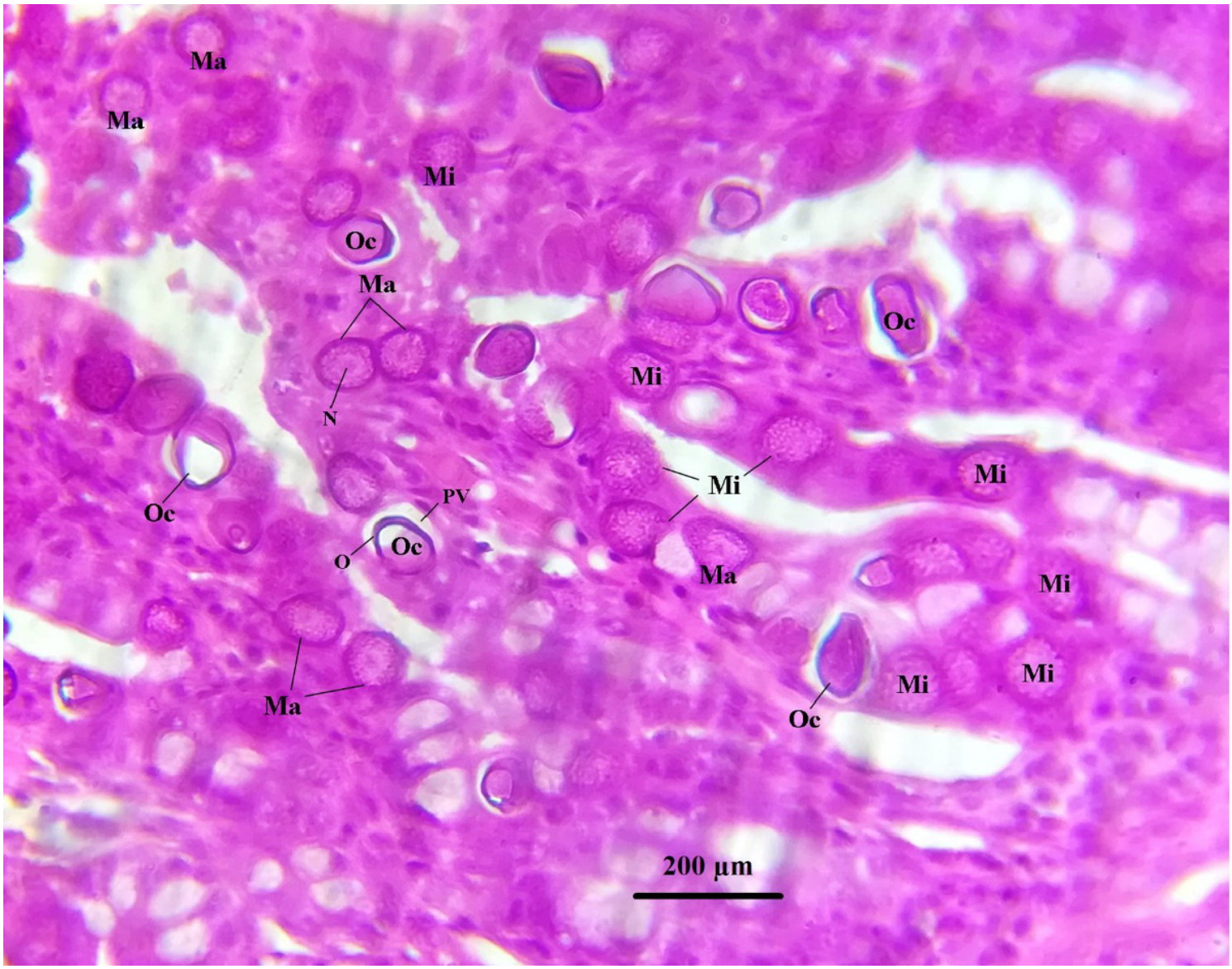

Figure 9

Light micrographs of microgametogensis, macrogametogensis and oocyst development of Eimeria intestinalis collected from domestic rabbits Oryctolagus cuniculus in Qena Governorate, Upper Egypt. Scale bar; 200 µm. Abbreviations; Ma, macrogamet (s); Mi, macrogamont (s); N, nucleus; Oc, oocyst; PV, parasitophorous vacuole.

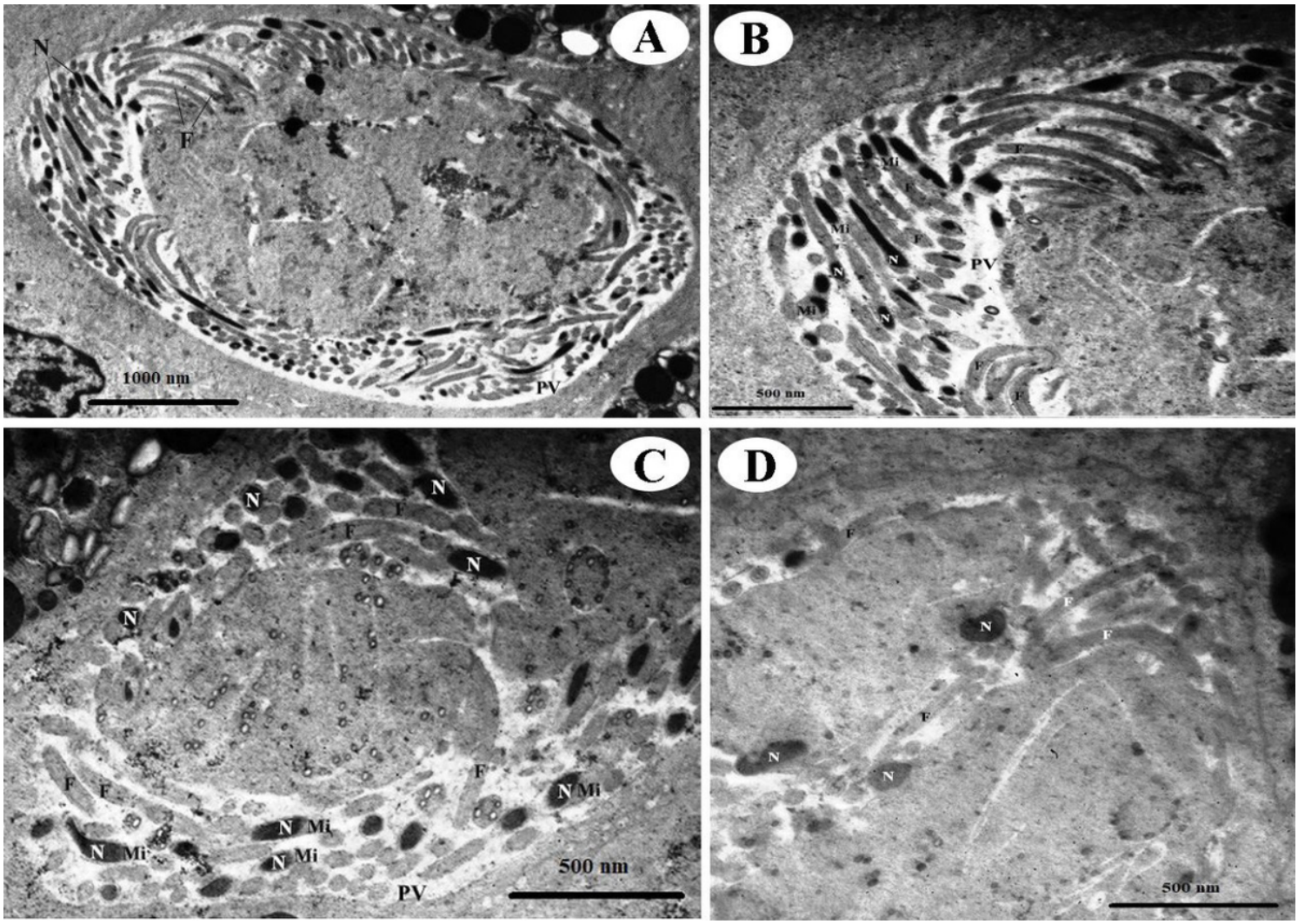

Figure 10

Transmission electron micrographs of microgamonts of Eimeria intestinalis collected from domestic rabbits Oryctolagus cuniculus in Qena Governorate, Upper Egypt. Figs. (A and C): Mature microgamonts. Figs. (B and D): High magnification of mature microgamonts. Scale bars; Fig. (A), 1000 nm and Figs. (B,C and D), 500 nm. Abbreviations; F, flagella; Mi, mitochondrion; N, nucleus; PV, parasitophorous vacuole.

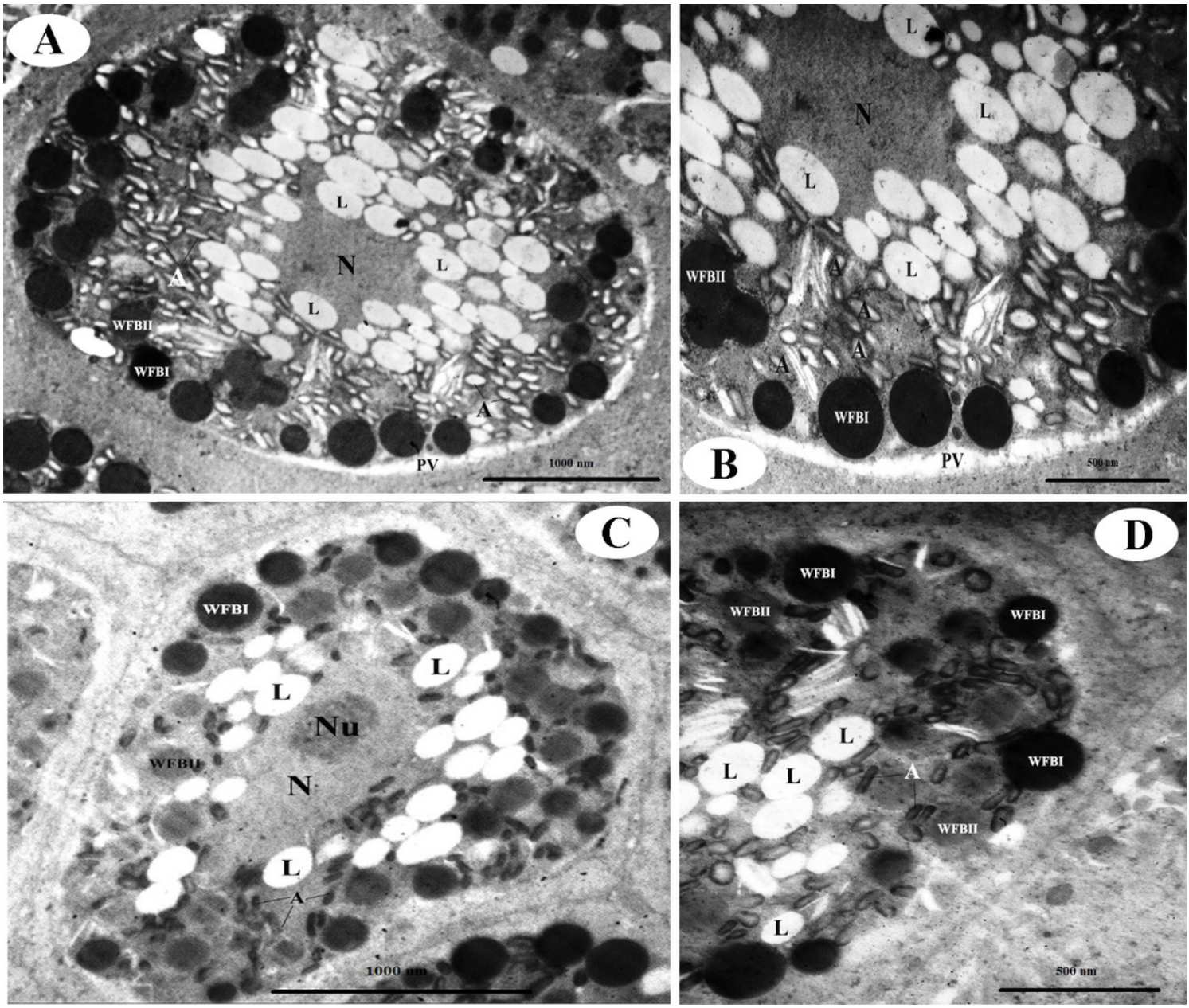

Figure 11

Transmission electron micrographs of macrogametes of Eimeria intestinalis collected from domestic rabbits Oryctolagus cuniculus in Qena Governorate, Upper Egypt. Figs. (A and C): Mature macrogametes. Figs. (B and D): High magnification of mature microgametes. Scale bars; Figs. (A and C), 1000 nm and Figs. (B and D), 500 nm. Abbreviations; A, amylopectin granules; L, lipid droplets; N, nucleus; Nu, nucleolus; PV, parasitophorous vacuole; WFBI, wall-forming bodies I; WFBII, wall-forming bodies II.

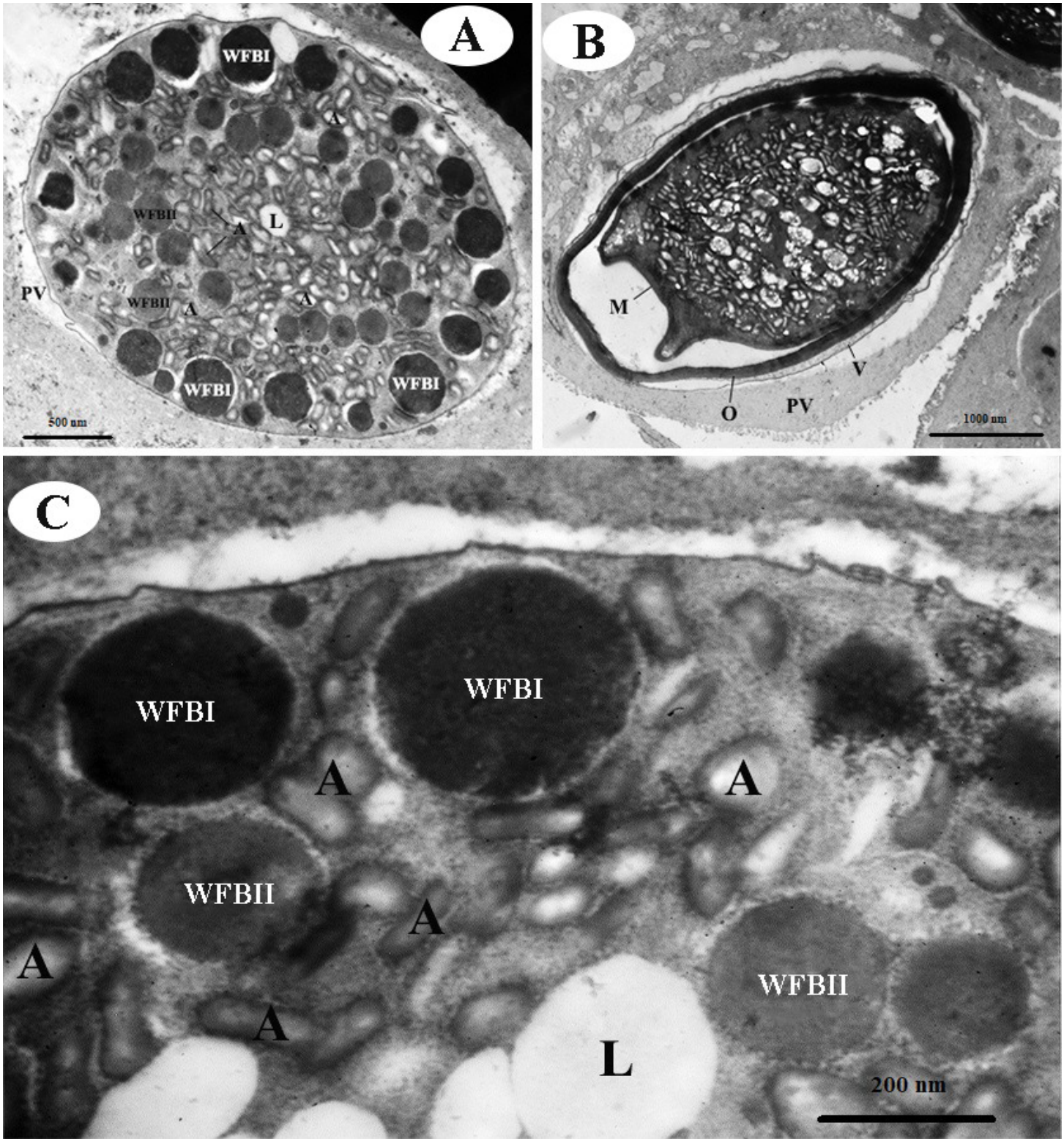

Figure 12

Transmission electron micrographs of oocysts of Eimeria intestinalis collected from domestic rabbits Oryctolagus cuniculus in Qena Governorate, Upper Egypt. Fig. (A): Early oocyst. Fig. (B): Mature oocyst. Fig. (C): High magnification of early oocyst. Scale bars; Fig. (A), 500 nm, Fig. (B), 1000 nm and Fig. (C), 200 nm. Abbreviations; A, amylopectin granules; L, lipid droplets; M, micropyle; O, oocyst wall; PV, parasitophorous vacuole; V, veil; WFBI, wall-forming bodies I; WFBII, wall-forming bodies II.

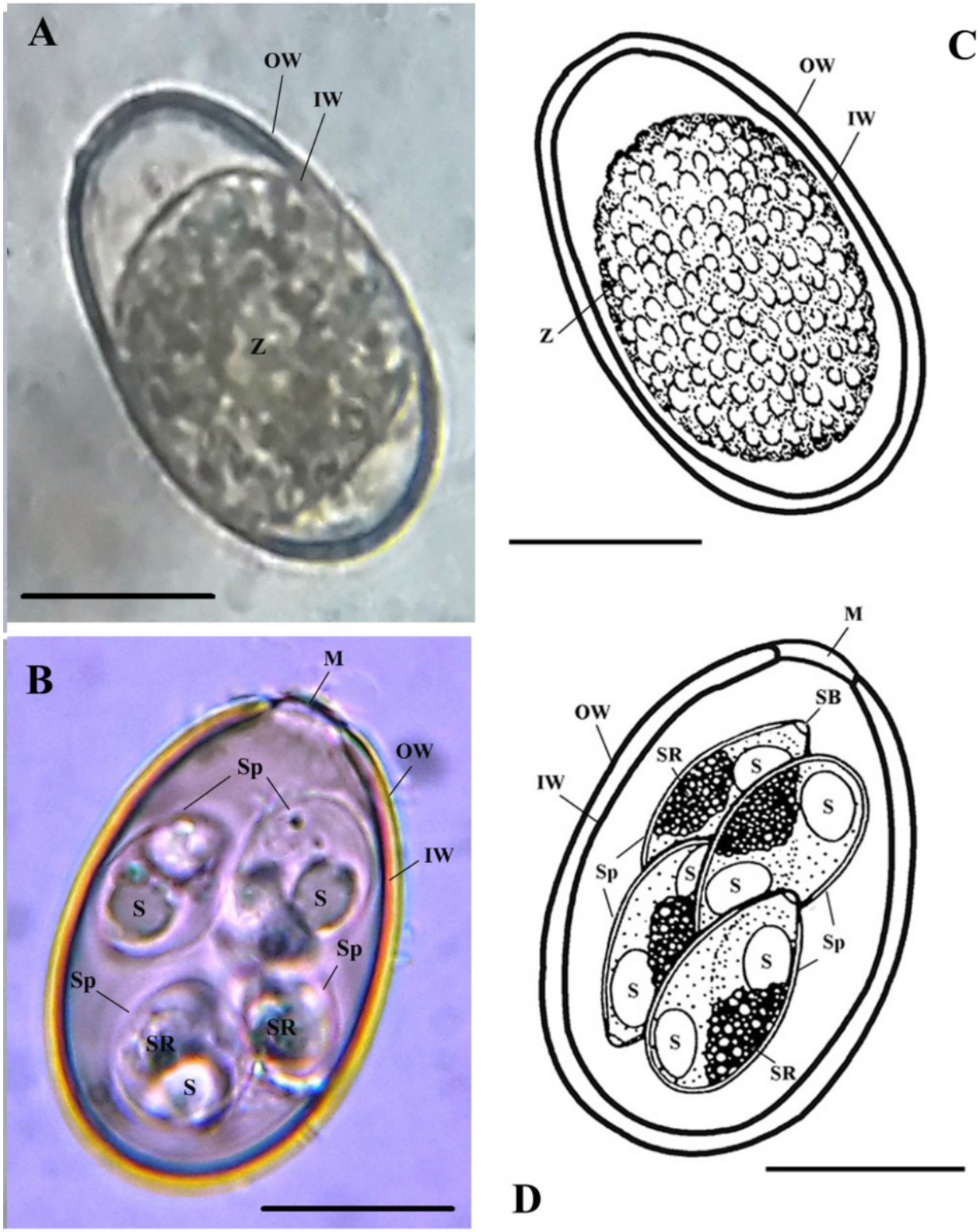

Figure 13

Eimeria steidai collected from domestic rabbits Oryctolagus cuniculus in Qena Governorate, Upper Egypt. Figs. (A and B): Light micrographs of sporulated and unporulated oocysts respectively. Figs. (C and D): Line drawings of sporulated and unporulated oocysts respectively. Scale bars, 10 µm. Abbreviations; IW, inner wall; M, micropyle; OW, outer wall; S, sporozoite; SB, Stieda body; SP, sporocyst(s); SR, sporocyst residuum; OR, oocyst residuum; Z, zygote.

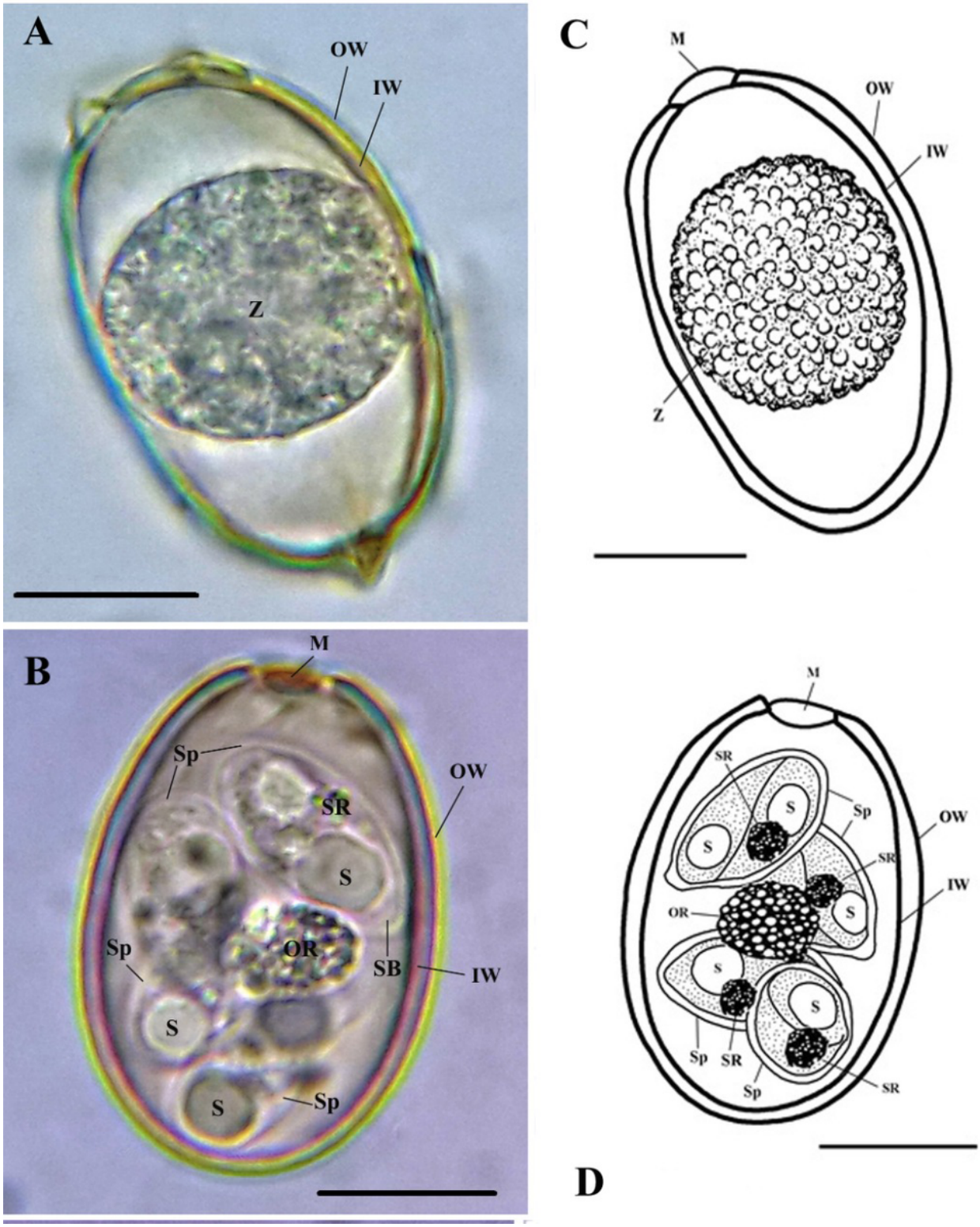

Figure 14

Eimeria vejdovskyi collected from domestic rabbits Oryctolagus cuniculus in Qena Governorate, Upper Egypt. Figs. (A and B): Light micrographs of sporulated and unporulated oocysts respectively. Figs. (C and D): Line drawings of sporulated and unporulated oocysts respectively. Scale bars, 10 µm. Abbreviations; IW, inner wall; M, micropyle; OW, outer wall; S, sporozoite; SB, Stieda body; SP, sporocyst(s); SR, sporocyst residuum; OR, oocyst residuum; Z, zygote.

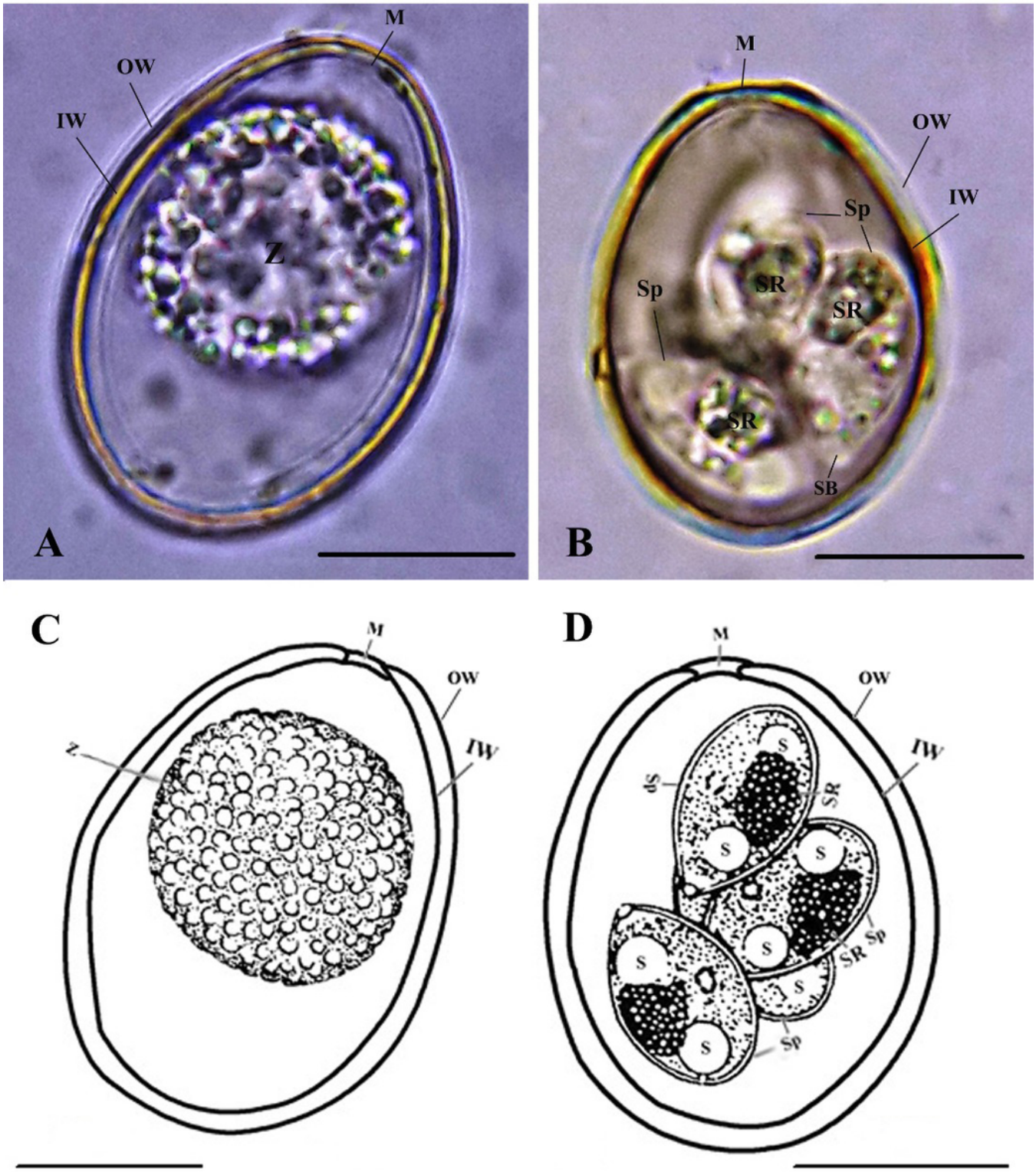

Figure 15

Eimeria piriformis collected from domestic rabbits Oryctolagus cuniculus in Qena Governorate, Upper Egypt. Figs. (A and B): Light micrographs of sporulated and unporulated oocysts respectively. Figs. (C and D): Line drawings of sporulated and unporulated oocysts respectively. Scale bars, 10 µm. Abbreviations; IW, inner wall; M, micropyle; OW, outer wall; S, sporozoite; SB, Stieda body; SP, sporocyst(s); SR, sporocyst residuum; OR, oocyst residuum; Z, zygote.

Supplementary Files

This is a list of supplementary files associated with this preprint. Click to download.

- Table1..doc
- Table2..docx