Arthroscopic-assisted Treatment of Popliteus Tendinitis

Biao Chen
Zhongnan Hospital of Wuhan University
Hankun Liu
Zhongnan Hospital of Wuhan University
Haitao Chen
Zhongnan Hospital of Wuhan University
Liaobin Chen
Zhongnan Hospital of Wuhan University
Hua Wang (whzkwlh@sina.com)
Department of Orthopedic Surgery, Zhongnan Hospital of Wuhan University, Wuhan 430071, China

Research article

Keywords: arthroscopic treatment, popliteus tendinitis, extreme lateral approach, popliteus tendon

Posted Date: October 21st, 2020

DOI: https://doi.org/10.21203/rs.3.rs-93184/v1

Abstract

Background: Popliteus tendinitis is an unusual factor to cause pain of the knee joint in its posterolateral compartment. There are few reports that the arthroscopy used for the treatment of refractory and symptomatic popliteus tendinitis. This study aimed to evaluate the effect of arthroscopic treatment of popliteus tendinitis via an auxiliary extreme lateral approach and to investigate the pathogenesis and treatment of popliteus tendinitis.

Methods: From 2014 to 2018, arthroscopic popliteus tendon ablation was performed in 15 patients (15 knees) with popliteus tendinitis via an auxiliary extreme lateral approach. Clinical outcomes were assessed using the Lysholm knee scoring scale, the Tegner score, the International Knee Documentation Committee (IKDC) score and the visual analogue scale (VAS) pain score at the 24-month follow-up after surgery.

Results: A total of 15 patients (mean age, 51.1 ± 7.1 years) were included; they had a mean body mass index of 23.8 ± 2.1. The minimum follow-up period was 24 months. Comparing the postoperative state to the preoperative state, the mean postoperative Lysholm score, Tegner score, and IKDC score improved significantly from 70.0 ± 5.0, 3.0 ± 0.9, and 62.3 ± 5.5 to 89.3 ± 4.2, 4.6 ± 0.61, and 80.5 ± 4.4, respectively ($p < 0.01$). The preoperative VAS score for pain improved from 4.3 ± 0.7 to 0.9 ± 0.6 ($p < 0.01$). No patients were lost to follow-up.

Conclusion: Following arthroscopic-assisted treatment, all the patients with popliteus tendinitis achieved satisfactory clinical outcomes in terms of pain relief and improved function.

Introduction

With medical diagnostic and technical improvements, recent studies indicate that popliteus tendon injuries are being reported with increasing frequency due to the popularity of higher levels of sports[1]. However, popliteus tendinitis is an uncommon pathology that often occurs in professional athletes and dancers[2–4]. Patients with this condition usually have posterolateral pain in the knee joint. The symptoms of popliteus tendinitis can be severe enough to limit or prevent athletic participation, thereby affecting daily life and work. Because the pain is very close to the joint line, sometimes patients are misdiagnosed as having a meniscal tear or lateral compartment articular damage and occasionally have been treated with arthroscopic meniscus partial resection or arthrotomy[3]. On the other hand, many physicians lack professional knowledge about popliteus tendinitis, leading to inaccurate diagnoses. Therefore, mastering knowledge about the disease and learning how to manage it correctly are essential.

Many non-surgical options have been described for the treatment of symptomatic popliteus tendinitis, including strengthening of the quadriceps muscle, rest, NSAIDs (Nonsteroidal Antiinflammatory Drugs), and localized corticosteroid injections[5]. With these conservative treatments, the majority of patient symptoms can be significantly relieved, and the patient can recover the ability to perform normal physical

exercise. However, there are certain drawbacks to these treatments[6]. That is, the patient symptoms are prone to relapse. Drugs have side effects, such as allergies and impairment of liver and kidney function. Furthermore, repeated corticosteroid injections result in reduced biomechanical performance of the popliteus tendon, potentially even having a deleterious effect on the hypothalamic-pituitary-adrenal (HPA) axis, which can result in adrenal suppression[7, 8]. In view of this situation, there is an urgent need to find an updated solution to this dilemma.

In this article, we describe a novel arthroscopic technique that treats recurrent and refractory popliteus tendinitis. Clinical data for patients with popliteus tendinitis who were followed up for more than 24 months were retrospectively analyzed. We speculate that popliteus tendon can be better observed through this kind of procedure, which also helps in the further diagnosis of popliteus tendinitis. Besides, under this operation, these patients will achieve better clinical effects.

Materials And Methods

Patients

From 2014 to 2018, we retrospectively collected 123 registered cases of popliteus tendinitis. After review, fifteen patients (15 knees) were included in our study. The 15 patients were clearly diagnosed with popliteus tendinitis and treated by arthroscopic interventions via an auxiliary extreme lateral approach. There were no cases of calcific tendinitis of the popliteus tendon. The inclusion criteria were as follows: (1) The symptoms of all patients were significant. (2) All patients had failed a course of nonoperative treatment, including extensive physiotherapy and appropriate analgesia for a minimum period of 3 months. (3) No patients had any history of knee surgery and infection. (4) All patients followed up for at least 24 months after surgery. (5) The patients had indispensable imaging findings, such as MRI and radiographs, before the operation (Fig. 1). (6) All operations were performed via an auxiliary extreme lateral approach by the same experienced surgeon.

Physical examination

Each patient received regular physical examinations of the knee joint and a specific exam for the popliteus tendon. In addition, there were two tests aimed at isolating and diagnosing issues with the popliteus muscles and evaluating popliteus tendon injury (Fig. 2): (1) Garrick test (active tibial external rotation against resistance): the patient was in the supine position, the hip and knee were flexed to 90°, and the leg as internally rotated. A symptomatic patient experiences pain with resisted tibial internal rotation[5]. (2) Passive external rotation test: the patient was asked to apply passive external force with the leg in the same position[5].

Surgical technique

First, standard anterolateral (AL) and anteromedial (AM) portals were established to explore the intact intra-articular structure and the posterior horn of the lateral meniscus in particular. Second, hyperplasia of

the synovium, synovial plica, edema, wear of the cruciate ligaments or meniscus as well as osteochondral injury were detected and approached simultaneously. Finally, an extreme lateral approach was established to examine and assess the popliteus hiatus and the status of the popliteus tendon (Fig. 3).

The extreme lateral approach is approximately 1 cm above the joint line and 3 cm outside the anterolateral portal. The arthroscope is introduced via the AL portal. Using the arthroscope's light to aid in positioning, an injector needle is percutaneously inserted at a site between the AL portal and the posterolateral (PL) portal. After seeing the needle under arthroscopy, a small stab wound is made using a No. 11 blade at the puncture site and enlarged with a straight hemostat. This approach is established under arthroscopy with the full knee extension (Fig. 4). Through this approach, the popliteus hiatus and coverage of the popliteus tendon can be clearly viewed during extension and flexion of the knee joint (Fig. 5). We use plasma ablation to ablate the inflamed part of the popliteal tendon under arthroscopy. At the same time, we also ablate and shave the inflammatory synovial tissue surrounding the popliteal tendon appropriately (Video 1).

Postoperative management

Postoperative management included diminishing pain and swelling and establishing a full range of motion to prevent muscle hypotrophy. First, all patients were treated with rest, ice, compression, and elevation of the injured knee postoperatively. They were full weight bearing immediately, but the time and intensity of their activities were limited one week after the operation. The subsequent therapeutic program focused on restoring the knee joint range of motion, incorporating quadriceps strengthening and progressing to dynamic proprioceptive training. Conditioning was maintained with the use of an exercise bike and walking and, eventually, running and other sport-specific exercises. Patients were discharged the day after surgery and visited the outpatient clinic for follow-up.

Outcome evaluation

Clinical and functional evaluations were carried out with preoperative and postoperative Lysholm scores, Tegner scores, IKDC scores and VAS scores. The postoperative scores were used from the 24-month follow-up after surgery.

Statistical methods

SPSS 20 statistical software was used for the statistical analysis. Descriptive statistics were used to report the data. Baseline patient characteristics were expressed as n for categorical variables and as the mean with the standard deviation for continuous variables. A two-sided paired samples *t* test was used to compare age, BMI, and the Lysholm score, Tegner score, IKDC score, VAS pain scale before and after surgery. A *p*-value less than 0.05 was considered statistically significant.

Results

Fifteen patients (15 knees) underwent arthroscopic-assisted treatment for popliteus tendinitis. The cohort comprised 9 females and 6 males with a median age of 51.1 years (38–63 years). The mean body mass index of participants was 23.8 ± 2.1, and the minimum follow-up duration was 24 months (Table 1).

Table 1
Preoperative Demographics and Characteristics of Patients Included

Demographics	**n = 15**
Gender (M/F)	6/9
Age (years) *	51.1 ± 7.1
BMI (kg/m^2) *	23.8 ± 2.1
Follow-up period, mo	21 ± 7.9
M male, F female	
*The value is given as mean ± SD (standard deviation)	

Diagnosis of popliteus tendinitis

Popliteus tendinitis is an infrequent and often misdiagnosed injury of the posterolateral part of the knee. Recognizing and correctly diagnosing popliteus tendinitis is indispensable. It can be very painful, and most patients described the pain as increased when running downhill and when performing activities of daily living. The diagnosis was established by carefully assessing the case history, performing a physical examination and examining the medical imaging features (Table 2).

Table 2
Diagnosis of popliteus tendinitis

Case history and physical examination	Patients (n = 15)
History of trauma	2
Tenderness along the popliteus tendon	15
Garrick test	11
Passive external rotation test	13
MRI features	
Local tendon enlargement	3
Increased intratendinous or myotendinous signal on fluid-sensitive sequences	11
Unusual amount of fluid around tendon	12
Partial tendon tearing	1
A case history, physical examination and medical imaging features are effective diagnostic tools for popliteus tendinitis.	

In this study, all patients had a history of excessive exercise. All of them participated in at least one sports activity every week. They all complained of significant tenderness on the popliteus tendon and had positive signs during at least one specific physical examination. No significant abnormalities were observed on their radiographs. According to the MRI findings, 11 patients had increased intratendinous or myotendinous signals on fluid-sensitive sequences, 12 patients had fluid effusion of the popliteus tendon, and 1 patient had partial degenerative tearing of the popliteus tendon.

Clinical outcomes

The preoperative Lysholm, Tegner, IKDC and VAS scores were 70.0 ± 5.0, 3.0 ± 0.9, 62.3 ± 5.5, and 4.3 ± 0.7, respectively. The last follow-up Lysholm, Tegner, IKDC and VAS scores were 89.3 ± 4.2, 4.6 ± 0.6, 80.5 ± 4.4, and 0.9 ± 0.6, respectively. There were significant differences between the preoperative and postoperative scores (Lysholm $p < 0.01$, Tegner $p < 0.01$, IKDC $p < 0.01$, VAS $p < 0.01$) (Table 3), which indicated good outcomes.

Table 3
Pre- and Post-operative Knee Function Scores for Patients Included

Outcome score (Mean ± SD)	Preoperative	Postoperative	*p* value
Lysholm	70.0 ± 5.0	89.3 ± 4.2	< 0.01
Tegner	3.00 ± 0.89	4.6 ± 0.61	< 0.01
IKDC	62.3 ± 5.5	80.5 ± 4.4	< 0.01
VAS	4.3 ± 0.68	0.9 ± 0.57	< 0.01

Discussion

Theoretically, popliteus tendinitis means localized inflammation in the tendon of the popliteus[6, 9]. As a kind of tendinitis, popliteus tendinitis also has some common symptoms of tendinitis itself. The main complaint of patient is the pain in the posterolateral corner of the knee. In some cases, there is significant tingling accompanied by sharp pain and joint stiffness, which limits the movement of the affected joints[3, 9]. In the cases that we included, most of the patients were middle-aged and elderly individuals. The clinical manifestations of the preoperative patients affected their daily living. At present, many researchers have proposed that repeated minor trauma, repetitive application of knee rotation in turnout, exercise, overuse and poor blood supply to tendons are the most common causes of popliteus tendinitis[2, 3, 10].

Based on cadaveric study, LaPrade et al. reported that the popliteus tendon rested proximal to the popliteus sulcus on the lateral femoral condyle from full knee extension to 112° of flexion. At knee angles of 112° or more, the popliteus tendon engaged in the popliteus sulcus[11, 12]. However, to date, there have been no reports in the literature about the intra-articular trajectory of the popliteus tendon. According to our arthroscopic findings, the popliteus tendon could be comprehensively observed arthroscopically via an auxiliary extreme lateral approach. We found that when the knee flexed from full extension, the popliteus tendon stretched properly and externally rotated against the lateral tibial plateau and the lateral femoral condyle. Conversely, when the knee from approximately 90° of flexion angle to extension, the popliteus tendon begins to internally rotated relative to the lateral tibial plateau and the lateral femoral condyle (Video 2). Consequently, we speculated that the mechanism of popliteus tendon injury might be related to repeated rolling friction against the lateral tibial plateau and the lateral femoral condyle, and traction injury to its collagen fiber tissue. Previous research reported that the popliteus tendon was in tension when the proximal tibia was externally rotated and became relaxed when the tibia was internally rotated[13, 14]. Due to the clinically relevant anatomy of the popliteus tendon, Marc et al. found that downhill running or other deceleration activities was prone to lead to popliteus tendinitis. This might stem from the popliteus acting to prevent excessive posterior tibial translation relative to the femur[15]. Ferrari et al. indicated that inflammation of the popliteus was associated with overuse or fatigue of the quadriceps[4]. When the fatigued quadriceps cannot adequately resist forward displacement of the femur

on the tibia, undue stress occurs on the secondary restraints, overwhelming the relatively small popliteus muscle. Moreover, the blood supply of the popliteus muscle is from the medial inferior genicular branch of the popliteus artery and the muscular branch of the posterior tibial artery[16]. It is different from the posterior cruciate ligament, which has abundant blood vessel and synovial coverage. There was no obvious capillary and synovial coverage on the surface of the popliteal tendon under the arthroscopic examination. Thus, it occurs with some physical injuries and degeneration over time.

Popliteus tendinitis is not a common cause of knee pain. Many doctors are not knowledgeable about popliteus tendinitis and readily misdiagnose it. Therefore, it is essential that it is diagnosed correctly. First, a detailed understanding of the patient's case history is required. Patients with popliteus tendinitis usually have posterolateral pain in the knee joint, especially when running downhill and participating in strenuous activities. Upon physical examination, the main finding is tenderness along the posterolateral joint line. Palpating while the patient is sitting up with the leg crossed in a "4" position is recommended. For the two specific physical examinations, the patient is asked to resist the examiner's external rotation force on the tibia. These actions result in pain if the popliteus tendon is inflamed. Although more common medially, a popliteus cyst, lateral meniscus tear or lateral compartment articular damage can present a similar pattern of symptoms. If the physician is not sure about the diagnosis, the imaging examination (radiographs and MRI) may be helpful[17]. In our study, there were 11 and 12 patients with increased intratendinous or myotendinous signals and fluid signals around the popliteus tendon in MR images, respectively. MRI has a vital role in the diagnosis and treatment management of popliteus tendinitis due to inherent difficulties in visualizing this region with arthroscopy and the challenge in detecting these injuries clinically.

Generally, the patients with popliteus tendinitis can choose conservative therapy for their management. These patients require a reduction in sports activities, getting more rest, avoiding trauma or injury, and even wearing knee braces with 30° of knee flexion for 3 weeks[18]. When popliteus tendinitis is accompanied by severe symptoms or injuries in other posterolateral side structures, there will be different management depending on the specific circumstance. In Eric’s study, a patient with a popliteus tendon injury received a steroid injection and conservative management with physical therapy[9]. Petsche et al. suggested that most patients respond well to physical therapy and NSAIDs[5]. Recalcitrant cases may require a local corticosteroid injection. In Blake’s study of patients with popliteus tendon tenosynovitis, the sheath was injected with 40 mg of methylprednisolone under arthroscopic guidance after joint irrigation[3]. However, repeated corticosteroid injections result in a series of unwanted events, including a loss of tensile strength of the popliteus tendon, septic arthritis, a postinjection flare and suppression of the HPA axis[7, 8, 19, 20].

For most popliteus tendinitis patients, we recommend non-surgical therapy for those who have minor injuries. However, for patients whose symptoms are severe and not responsive to conservative therapy, the patients could undergo arthroscopic intervention. In our study, we chose an extreme lateral approach to obtain a better view of the relations of the popliteus tendon and tibial plateau and their trajectories. In

addition, we also clean the loose body that is beside the popliteus hiatus with this approach (see the details on our previous studies)[21]. In our cohort of patients, compared with the preoperative data, there were significant improvements in knee joint scores (Lysholm, Tegner, IKDC and VAS scores) after surgery. Hence, arthroscopic treatment is positive and effective clinical management in popliteus tendinitis patients.

In this article, we introduced a new extreme lateral approach to observe and manage popliteus tendonitis, which is accompanied by deformation of the popliteus hiatus. From our intraoperative findings, we observed that long-term chronic abrasion of the knee joint can cause tissue degeneration injuries and inflammation of the popliteus tendon articular cavity. The patients felt discomfort and pain with this degeneration. Through arthroscopic observation and ablation, local inflammation and wear were effectively controlled. The postoperative symptoms were significantly relieved. After follow-up, the patients' life quality was improved, and the knee function score increased significantly. From 2014 to 2018, we collected 123 registered cases of popliteus tendinitis. However, only 15 patients required arthroscopic intervention. This is also proved that the incidence of popliteus tendinitis is low and conservative treatment can also play an important role in treatment. Arthroscopic surgery is an effective method in recurrent patients or even patients with a more serious condition.

Conclusion

Popliteus tendinitis is an unusual condition that causes pain in the posterolateral compartment of the knee joint. In our study, all the patients with popliteus tendinitis who were treated with arthroscopic popliteus tendon ablation via the auxiliary extreme lateral approach achieved satisfactory outcomes in terms of pain relief and improved function. We recommend that arthroscopic treatment be considered an option in cases of persistent and intractable popliteus tendinitis.

Declarations

Ethics approval and consent to participate

The Ethics Committee of Zhongnan Hospital of Wuhan University approved this study, and all patients provided written informed consent.

Consent for publication

Not applicable.

Competing interests

The authors declare that they have no competing interests.

Acknowledgements

This research was supported by the Natural Science Foundation of China (81871779), Hubei Provincial Natural Science Foundation (2018CFB443) and Zhongnan Hospital of Wuhan University Science, Technology and Innovation Seed Fund (znpy2017025).

Authors' information

Biao Chen, Email: chenbiao20030701@163.com.

Hankun Liu, Email: hankunliu@126.com.

Haitao Chen, Email: chenht33@sina.com.

Liaobin Chen, Email: lbchen@whu.edu.cn.

Hua Wang, Phone: +86 13006147532, Email: whzkwlh@sina.com.

References

1. Koong DP, An VVG, Lorentzos P, Moussa P, Sivakumar BS. Non-Operative Rehabilitation of Isolated Popliteus Tendon Rupture in a Rugby Player. Knee surgery & related research. 2018;30:269-72. https://doi.org/10.5792/ksrr.17.072.
2. Aumann EK, Aksu T, Atansay V, Kara AN, Aksu N. Relationship of Popliteus Sulcus Depth and Tibiofemoral Rotational Alignment with Popliteus Tendinitis in Professional Folk Dancers Exposed to Turnout Positions: An MRI Analysis. Medical problems of performing artists. 2019;34:141-6. https://doi.org/10.21091/mppa.2019.3024.
3. Blake SM, Treble NJ. Popliteus tendon tenosynovitis. British journal of sports medicine. 2005;39:e42. https://doi.org/10.1136/bjsm.2005.019349.
4. Ferrari DA, Wilson DR, Hayes WC. The effect of release of the popliteus and quadriceps force on rotation of the knee. Clinical orthopaedics and related research. 2003:225-33. https://doi.org/10.1097/01.blo.0000071752.41516.6e.
5. Petsche TS, Selesnick FH. Popliteus tendinitis: tips for diagnosis and management. The Physician and sportsmedicine. 2002;30:27-31. https://doi.org/10.3810/psm.2002.08.401.
6. Olson WR, Rechkemmer L. Popliteus tendinitis. Journal of the American Podiatric Medical Association. 1993;83:537-40. https://doi.org/10.7547/87507315-83-9-537.
7. Johnston PC, Lansang MC, Chatterjee S, Kennedy L. Intra-articular glucocorticoid injections and their effect on hypothalamic-pituitary-adrenal (HPA)-axis function. Endocrine. 2015;48:410-6. https://doi.org/10.1007/s12020-014-0409-5.
8. Pekarek B, Osher L, Buck S, Bowen M. Intra-articular corticosteroid injections: a critical literature review with up-to-date findings. Foot. 2011;21:66-70. https://doi.org/10.1016/j.foot.2010.12.001.
9. Davalos EA, Barank D, Varma RK. Two cases of chronic knee pain caused by unusual injuries to the popliteus tendon. Joints. 2016;4:62-4. https://doi.org/10.11138/jts/2016.4.1.062.

10. Quinlan JF, Webb S, McDonald K, Meikle G, McMahon SF. Isolated popliteus rupture at the musculo-tendinous junction. The journal of knee surgery. 2011;24:137-40. https://doi.org/10.1055/s-0031-1275397.
11. James EW, LaPrade CM, LaPrade RF. Anatomy and biomechanics of the lateral side of the knee and surgical implications. Sports medicine and arthroscopy review. 2015;23:2-9. https://doi.org/10.1097/JSA.0000000000000040.
12. LaPrade RF, Ly TV, Wentorf FA, Engebretsen L. The posterolateral attachments of the knee: a qualitative and quantitative morphologic analysis of the fibular collateral ligament, popliteus tendon, popliteofibular ligament, and lateral gastrocnemius tendon. The American journal of sports medicine. 2003;31:854-60. https://doi.org/10.1177/03635465030310062101.
13. LaPrade RF, Wozniczka JK, Stellmaker MP, Wijdicks CA. Analysis of the static function of the popliteus tendon and evaluation of an anatomic reconstruction: the "fifth ligament" of the knee. The American journal of sports medicine. 2010;38:543-9. https://doi.org/10.1177/0363546509349493.
14. Nyland J, Lachman N, Kocabey Y, Brosky J, Altun R, Caborn D. Anatomy, function, and rehabilitation of the popliteus musculotendinous complex. The Journal of orthopaedic and sports physical therapy. 2005;35:165-79. https://doi.org/10.2519/jospt.2005.35.3.165.
15. Fineberg MS, Duquin TR, Axelrod JR. Arthroscopic visualization of the popliteus tendon. Arthroscopy : the journal of arthroscopic & related surgery : official publication of the Arthroscopy Association of North America and the International Arthroscopy Association. 2008;24:174-7. https://doi.org/10.1016/j.arthro.2007.08.018.
16. Banjo AO. Aberrant popliteus muscle: anatomy and clinical consideration. African journal of medicine and medical sciences. 1996;25:69-73.
17. Pacholke DA, Helms CA. MRI of the posterolateral corner injury: a concise review. Journal of magnetic resonance imaging : JMRI. 2007;26:250-5. https://doi.org/10.1002/jmri.21013.
18. Holt PD, Keats TE. Calcific tendinitis: a review of the usual and unusual. Skeletal radiology. 1993;22:1-9. https://doi.org/10.1007/BF00191518.
19. Caldwell JR. Intra-articular corticosteroids. Guide to selection and indications for use. Drugs. 1996;52:507-14. https://doi.org/10.2165/00003495-199652040-00004.
20. Haslock I, MacFarlane D, Speed C. Intra-articular and soft tissue injections: a survey of current practice. British journal of rheumatology. 1995;34:449-52. https://doi.org/10.1093/rheumatology/34.5.449.
21. Chen B, Chen L, Chen H, Yang X, Tie K, Wang H. Arthroscopic removal of loose bodies using the accessory portals in the difficult locations of the knee: a case series and technical note. Journal of orthopaedic surgery and research. 2018;13:258. https://doi.org/10.1186/s13018-018-0966-z.

Figures

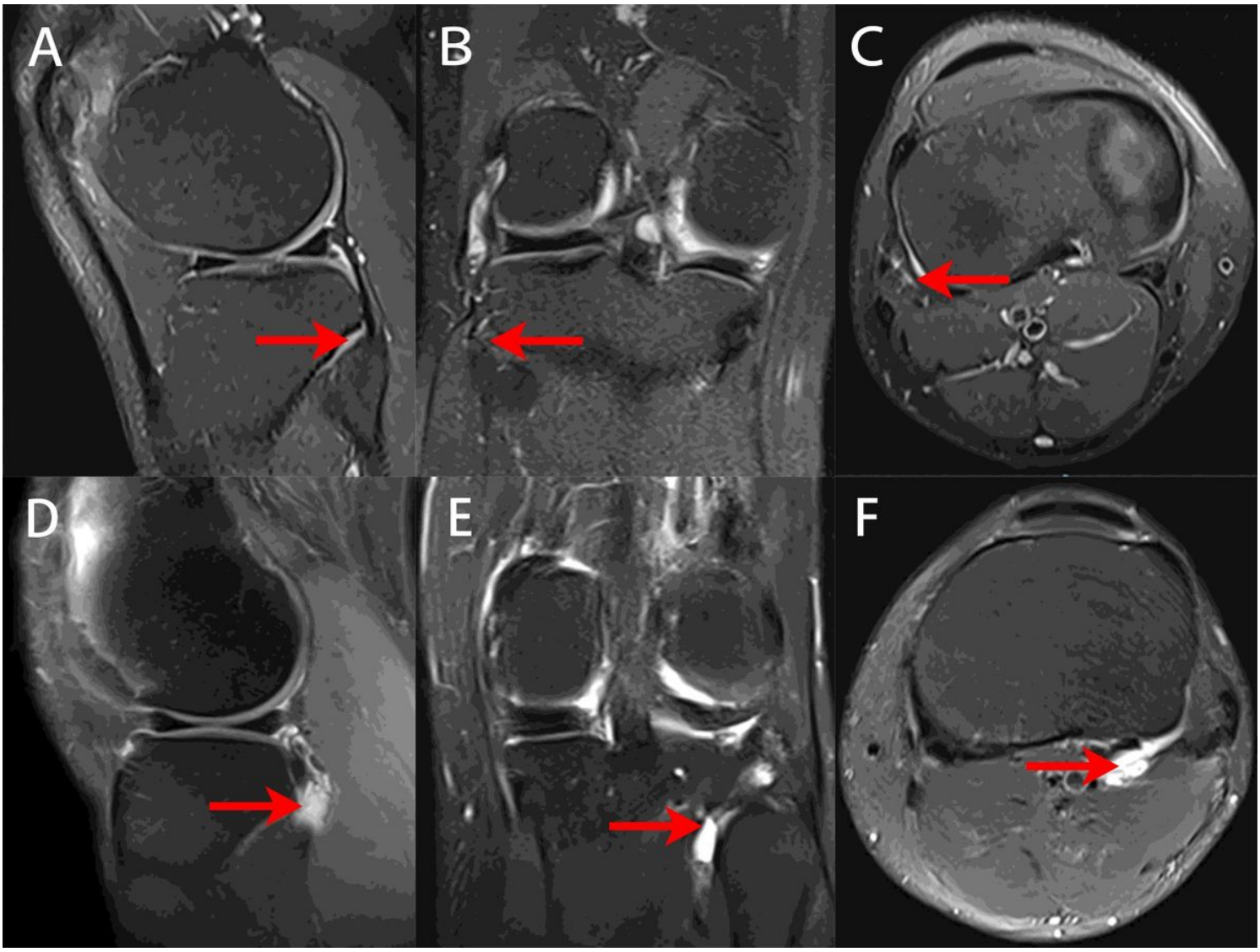

Figure 1

MRI images of the knees of normal people and of patients with popliteus tendinitis. Red arrows show the location of the popliteus tendon. A, B, C. Preoperative sagittal, coronal and horizontal MRI views of MRI of the normal people. D, E, F. Preoperative sagittal, coronal and horizontal MRI views of a 55-year-old female with popliteus tendinitis.

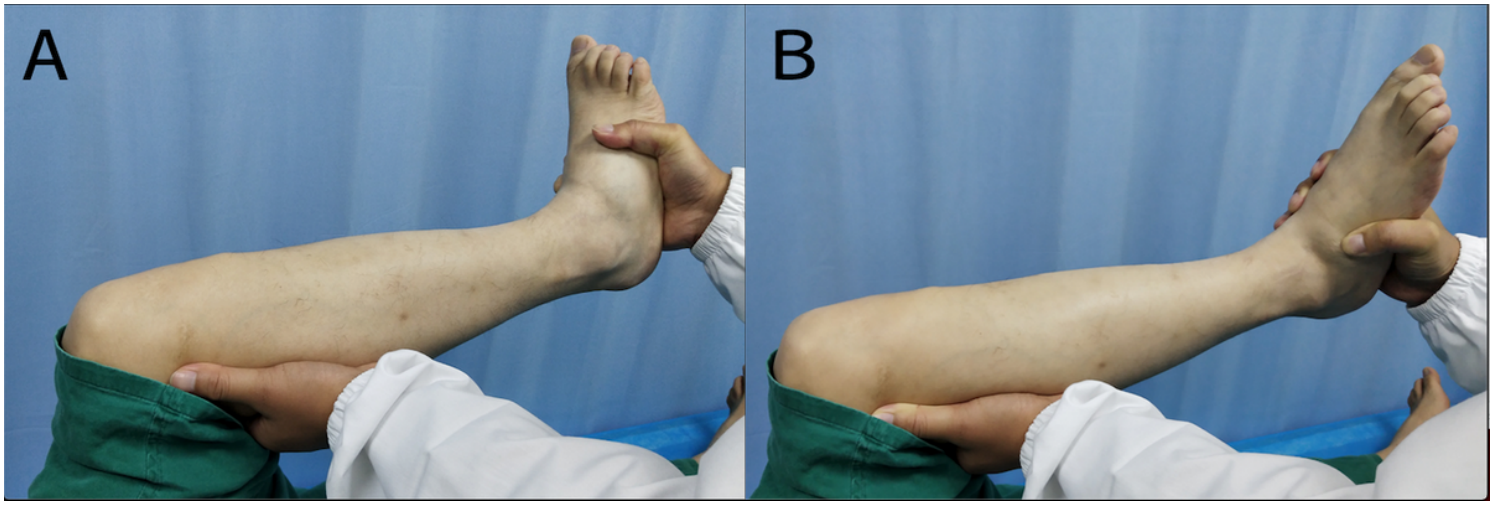

Figure 2

A. Garrick test (active tibial external rotation against resistance). B. Passive external rotation test.

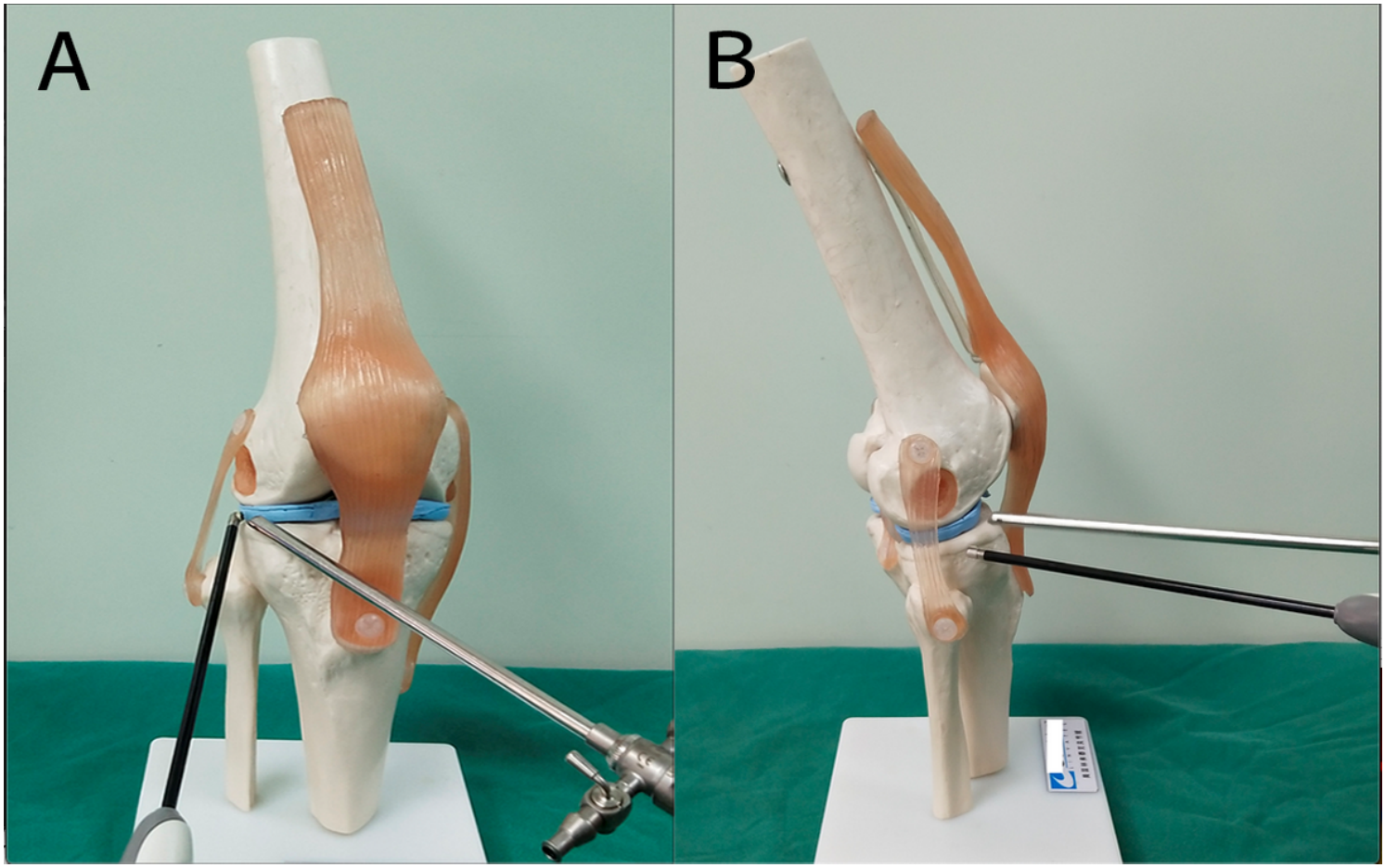

Figure 3

Model of an auxiliary extreme lateral approach combined with a conventional anterolateral approach in the knee. A. anterolateral view, B. lateral views.

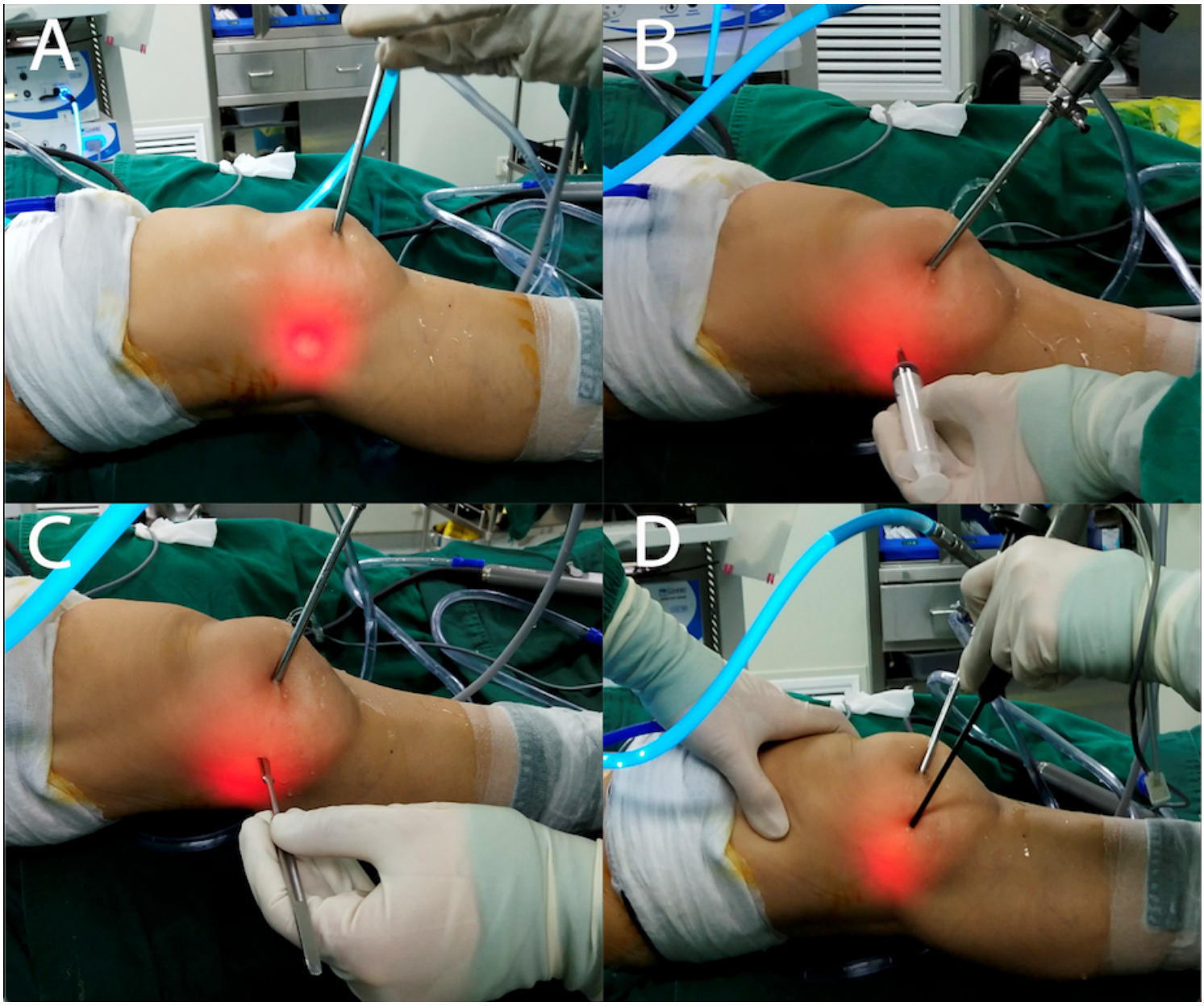

Figure 4

A.B.C.D. The location and establishment of an auxiliary extreme lateral approach.

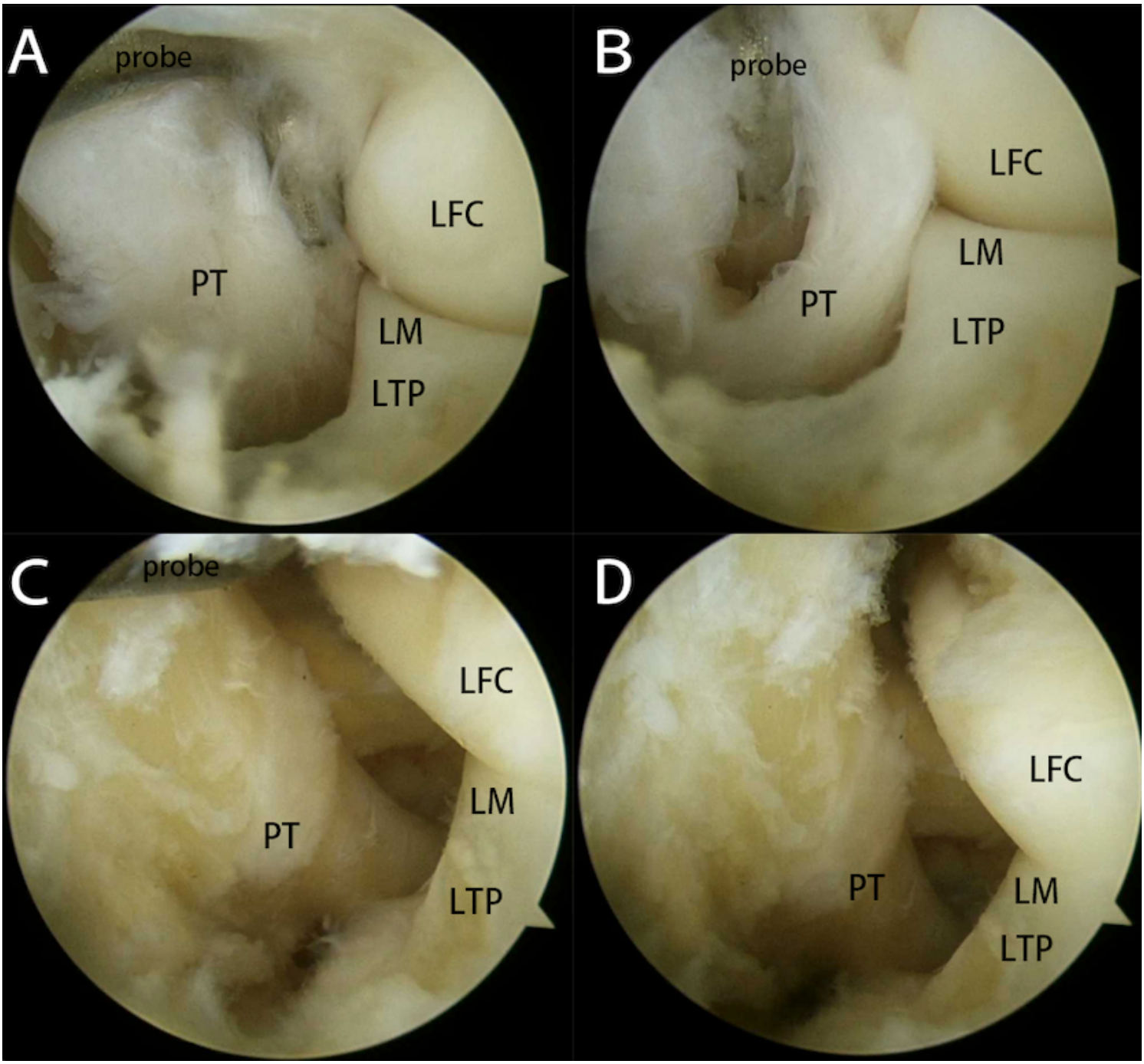

Figure 5

The arthroscopic finding of the popliteus tendon and popliteus hiatus via an auxiliary extreme lateral approach. A, B. Before ablation: The arthroscopic finding of the popliteus tendon and popliteus hiatus (PT, popliteus tendon; LM, lateral meniscus; LFC, lateral femoral condyle; LTP, lateral tibial plateau). C, D. After ablation: The arthroscopic finding of the popliteus tendon and popliteus hiatus (PT, popliteus tendon; LM, lateral meniscus; LFC, lateral femoral condyle; LTP, lateral tibial plateau).

Supplementary Files

This is a list of supplementary files associated with this preprint. Click to download.

- video1.mp4
- video2.mp4