Inflammatory Pseudotumor of Omentum Containing Gas Misdiagnosed as Perforation of Hollow Organs

Shiwen Nie
North China University of Technology Affiliated Hospital https://orcid.org/0000-0002-0188-4456

Yadong He
North China University of Science and Technology Affiliated Hospital

Shuo Zhang
North China University of Science and Technology Affiliated Hospital

Fenghong Cao (caofenghong@163.com)
North China University of Science and Technology Affiliated Hospital

---

Case Report

Keywords: Inflammatory pseudotumor of omentum, case report

Posted Date: October 19th, 2021

DOI: https://doi.org/10.21203/rs.3.rs-934231/v1

Abstract

Background

Inflammatory pseudotumors that grow on the omentum are relatively rare, and inflammatory pseudotumor most often involves the lung. As far as we know, the inflammatory pseudotumor of omentum, which is in the shape of beaded vesicles and contains gas, has never been reported in the literature.

Case presentation

we report a 45-year-old Chinese woman who complained of epigastric pain with hematemesis for 9 hours, physical examination showed subxiphoid tenderness, previous history of gastric ulcer and repair of gastric perforation, laboratory examination showed slight increase of white blood cells and decrease of hemoglobin. Computed tomography showed dotted free gas in the abdominal cavity, and the perforation of the hollow organs was considered. The pathological results after emergency operation showed that histiocyte aggregation with multinucleated giant cell reaction could be seen in the omental tissue. Immunohistochemistry :ER (-), PR (-), PAX-8 (-), CK (mesothelial+), MC (mesothelial+), CR (mesothelial+), CD68 (histiocyte+), SMA (smooth muscle+). The abdominal pain was relieved after surgical resection of the tumor, and recovered well after symptomatic treatment.

Conclusion

Inflammatory pseudotumor of omentum containing gas is easily diagnosed as perforation of hollow organs, with few clinical manifestations of acute abdomen, mostly non-specific, and a good prognosis. Understanding its clinicopathological features and pathological examination methods are helpful to diagnose the disease, so as to choose an appropriate treatment plan, and whether surgical treatment is better than conservative treatment remains to be further studied. The disease should be distinguished from perforation of hollow organs, but the source of gas is unknown. It may have something to do with past medical history.

Background

Inflammatory pseudotumor is kind of inflammatory reactive hyperplastic mass similar to tumor changes. Because of its rare incidence and diverse properties, it is named by various terms, including inflammatory fibrosarcoma,inflammatory myofibrous, mucinous hamartoma, fibrous xanthoma and histiocytomainflammatory myofibroblastoma [1, 2]. It occurs most often in the lungs and orbit,However, it is reported that this kind of disease can occur all over the body of the human body. In addition to the lungs and orbits, the most common locations reported are the greater omentum and mesenteric[3–6].The inflammatory pseudotumor on the greater omentum is relatively rare, and the inflammatory pseudotumor of the greater omentum containing gas is more rare, which is characterized by grape-like cystic bubbles attached to the greater omentum..Here, we report the first case of inflammatory pseudotumor of the

greater omentum diagnosed pathologically after surgical resection. On the basis of literature review, we describe the clinicopathological features of the disease and summarize the pathological examination methods of the disease. the cause of gas production of the disease was also discussed.

Case Presentation

A 45-year-old Chinese woman complained of abdominal pain and hematemesis for 9 hours and was admitted to the Affiliated Hospital of North China University of Technology in Hebei, China. Abnormal laboratory test results as follows: WBC 11.6 (4–10 × 10 ^ 9 / L); hemoglobin 68 (110-150g/L). All the figures in the above parentheses are shown as reference intervals. Abdominal computed tomography (CT) showed dotted free gas density in the abdominal cavity (Fig. 1). Combined with medical history and imaging examination, gastrointestinal perforation was considered.

Discussion

The most common clinical manifestation of inflammatory pseudotumor on the omentum is the accidental discovery of abdominal masses. A small number of patients may be associated with fever, weight loss, abdominal pain and intestinal obstruction[7].*In this case, the abdominal mass was not touched during the physical examination. Imaging examination of inflammatory pseudotumor of the greater omentum containing gas often shows that there is free gas in the abdominal cavity, so it is very easy to be diagnosed as perforation of hollow organs.Because there is no obvious lump.The definite diagnosis of omentum inflammatory pseudotumor requires histopathological and / or immunohistochemical staining of the resected tumor[8]. Histopathological and immunohistochemical staining can be used in the diagnosis of omentum inflammatory pseudotumor. Hematoxylin-eosin staining is the most commonly used histopathological method, which can identify lymphocytes, histiocytes, plasma cells,spindle cells and myofibroblasts. The most commonly used immunohistochemical staining techniques areVEGF, desmin (positive: 60–70%), COX-2,ALK-1 (positive: 33–50%) and SMA (positive: 80–90%)[9,10]*.The non-specific pathological features of omentum inflammatory pseudotumor can be that there are only omental fat necrosis, multinucleated cells and inflammatory cell infiltration in the pseudotumor. Some manifestations are venous congestion, fibrous tissue hyperplasia or calcified tissue and so on. Finally, the source of gas may be a previous gastric perforation, the gas in the stomach escapes and is enveloped by the omentum, resulting in the formation of the omentum inflammatory pseudotumor that contains gas. The specific reason is not clear. However, the differential diagnosis of this disease and hollow organ perforation is still worthy of reference.

Conclusions

In summary, we describe a rare case of inflammatory pseudotumor of omentum containing gas. Due to imaging examination, clinical manifestations, and previous medical history (except for physical examination with only subxiphoid tenderness andno symptoms of peritonitis), we tend to support hollow organ perforation, so we performed surgery on the patient. For such cases, only histological examination can confirm the diagnosis. Due to the difficulties in diagnosis, we usually have surgical treatment first

when misdiagnosed as perforation of hollow organs, but for patients, whether the benefit of surgical treatment is greater than that of conservative treatment, further research is needed to clarify.

Declarations

Availability of data and materials

All data generated or analyzed during this case are included within the article.

Acknowledgments

We thank the Department of Pathology,Affiliated Hospital of North China University of Technology for assistance with pathological diagnosis.

Funding

Not applicable.

Author information

Affiliations

Department of Urology, North China University of Science and Technology Affiliated Hospital, 2Department of General surgery, North China University of Science and Technology Affiliated Hospital

Shi-Wen Nie Shuo Zhang Ya-Dong He & Feng-Hong Cao*

Contributions

NSW collected the clinical data and drafted the manuscript.HYD, and ZS offered assistance in image selection. CFH made revision to the final manuscript and provided the funding support. All authors read and approved the final manuscript.

Corresponding author

Correspondence to Feng-Hong Cao

Ethics declarations

Ethics approval and consent to participate

This case study was approved by the Institutional Ethics Committee of North China University of Science and Technology Affiliated Hospital

Consent for publication

Written informed consent was obtained from the patient for the publication of this case report and any accompanying images. A copy of the consent form is available for review by the Editor of Diagnostic Pathology.

Competing interests

The authors declare that they have no competing interests.

References

1. Narla LD, Newman B, Spottswood SS, Narla S, Kolli R. Inflammatory pseudotumor. *Radiographics* 2003; 23: 719-729.
2. Levy AD, Rimola J, Mehrotra AK, Sobin LH. From the archives of the AFIP: Benign fibrous tumors and tumor like lesions of the mesentery: Radiologic-pathological correlation. *Radiographics* 2006; 26: 245-264.
3. Corapçioğlu F, Kargi A, Olgun N, Ozer E, Olguner M, Sarialioğlu F. Inflammatory myofibroblastic tumor of the ileocecal mesentery mimicking abdominal lymphoma in childhood: report of two cases. Surg Today. 2005;35(8):687–91. doi:10.1007/s00595-005-2992-9.
4. . Hirose Y, Kaida H, Kurata S, Okabe Y, Kage M, Ishibashi M. Incidental detection of rare mesenteric inflammatory pseudotumor by (18)F-FDG PET. Hell J Nucl Med. 2012;15(3):247–50. doi:10.1967/s002449910060.
5. Aptel S, Gervaise A, Fairise A, Henrot P, Leroux A, Guillemin F, et al. Abdominal inflammatory myofibroblastic tumour. Diagn Interv Imaging. 2012;93(5):410–2. doi:10.1016/j.diii.2012.02.002.
6. Chen SS, Liu SI, Mok KT, Wang BW, Yeh MH, Chen YC, et al. Mesenteric inflaofibroblastic proliferation in children. *Pediatr Surg Int* 1998; 13: 95-9
7. Kutumbale R, Kothari P, Jiwane A, Kumar T. Mesenteric inflammatory pseudotumor- an interesting presentation. J Indian Assoc Pediatr Surg. 2001;6:45–8.
8. Choi AH, Bohn OL, Beddow TD, McHenry CR. Inflammatory myofibroblastic tumor of the small bowel mesentery: an unusual cause of abdominal pain and uveitis. J Gastrointest Surg. 2011;15(4):584–8. doi:10.1007/s11605-010-1408-3.
9. Gupta CR, Mohta A, Khurana N, Paik S. Inflammatory pseudotumor of the omentum: an uncommon pediatric tumor. Indian J Pathol Microbiol. 2009;52:219–21. doi:10.4103/0377-4929.48924.

Figures

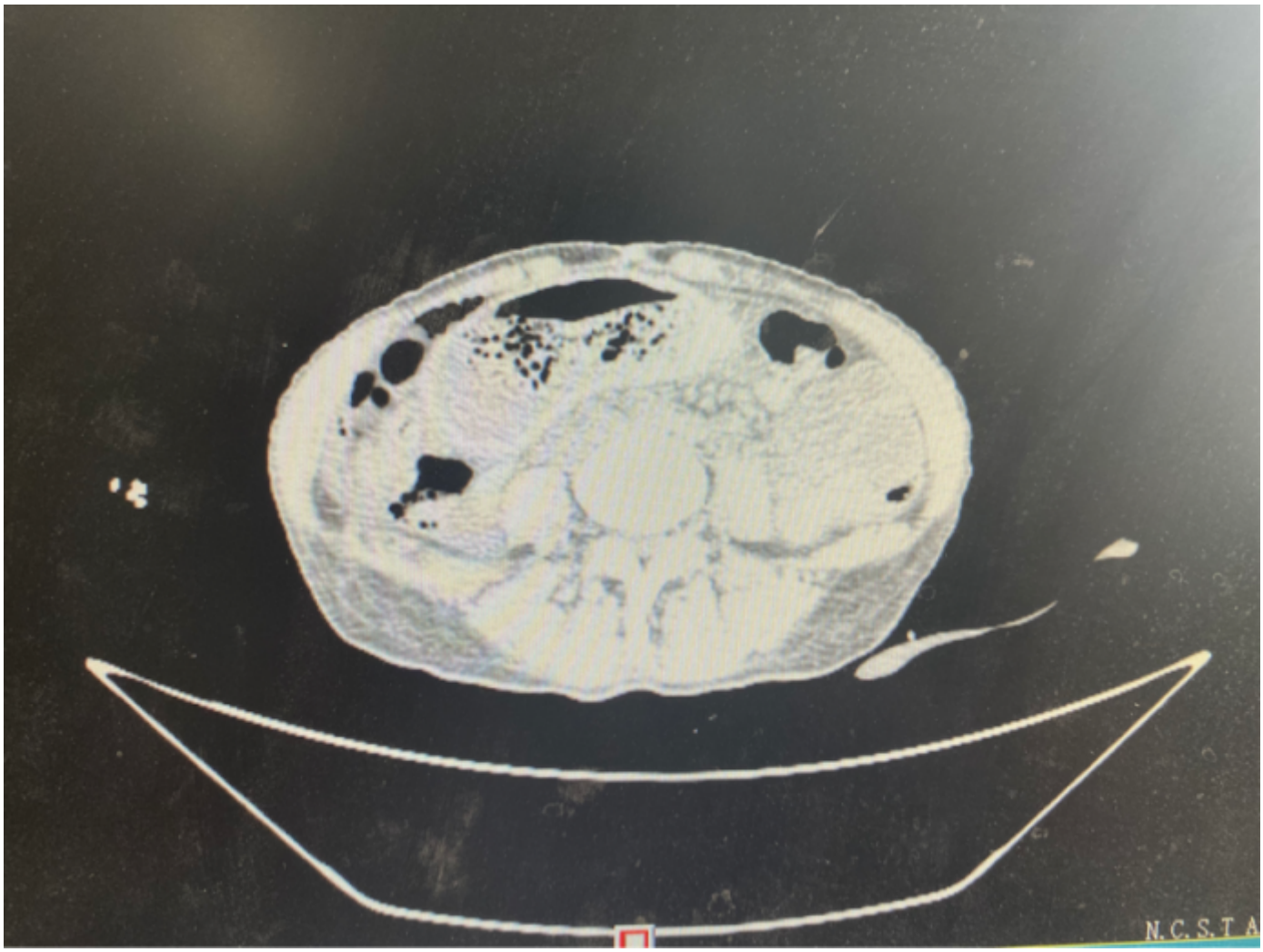

Figure 1

Spot free gas. on the abdominal CT image.

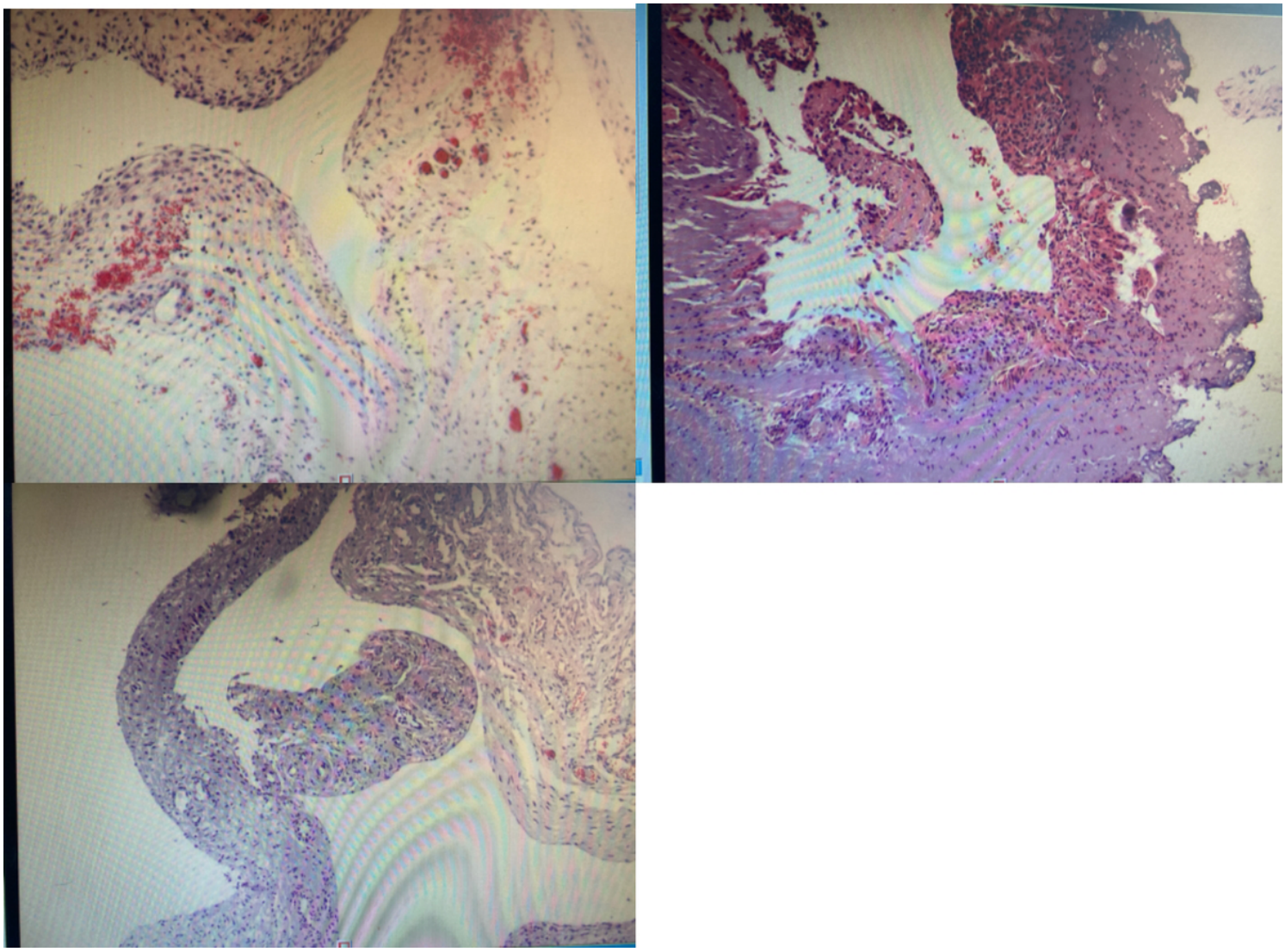

Figure 2

Histiocyte aggregation with multinucleated giant cell reaction can be seen in omental tissue.