Comparison of Left Lower Entrance and Traditional Laparoscopic Greater Omentum Resection for Stage I Ovarian Cancer

Aiwen Le
Huazhong University of Science and Technology https://orcid.org/0000-0002-7678-4548

Fan Yang
Suzhou Ninth People's Hospital

Kai Kang
Maternal and Child Health Hospital of Hubei Province: Hubei Province Women and Children Hospital

Guna He (leaiwen362531@126.com)
fuzhou second hospital affiliated to Xiamen university

Research

Keywords: laparoscopy, ovarian cancer, greater omentum, resection

Posted Date: October 1st, 2021

DOI: https://doi.org/10.21203/rs.3.rs-934284/v1

Abstract

Objective : To describe the surgical method, safety and convenience of " lower left entrance laparoscopic greater omentum resection" and evaluate its clinical application value for stage I ovarian cancer.

Methods: 31 patients with early stage I ovarian cancer underwent with laparoscopic staging surgery adopted " lower left entrance laparoscopic omentum resection " as the observation group, and 29 cases underwent by conventional laparoscopy as control group. The intraoperative and postoperative indexes were compared.

Results: During the greater omentum resection, there was no significant difference between two groups in the blood loss, but the operation time in observation group was significantly shorter than the control group. There was no difference in postoperative hospital stay gastrointestinal exhaust time and postoperative severe complications.

Conclusion: " lower left entrance laparoscopic greater omentum resection " may be a safe and effective technique in stage I ovarian cancer.

Introduction

According to the NCCN guidelines, standard staging operations for early ovarian cancer (EOC) include bilateral adnexectomy hysterectomy biopsy of suspected metastatic foci peritoneal biopsy omental excision peritoneal irrigation pelvic and paraaortic lymphadenectomy[1]. Omental excision generally refers to the removal of greater omentum [2]. Studies have shown that minimally invasive surgery will not have adverse effects and affect 10-year survival[3]. Antonino Ditto et al [4]compared the feasibility and safety of stage I EOC by laparoscopy and laparotomy, the laparoscopic group had less blood loss faster recovery of defecation and shorter hospital stay but had longer operative time. Bogani et al [5] also found that the incidence of laparoscopic postoperative complications was low. However, there are some problems in the conventional laparoscopic approach, such as narrow visual field caused by the large distance between the laparoscopy and the omentum, the surgical field for aortic node resection which also is exposed difficultly, longer operative time. The purpose of this study is to describe the safety and reliability of laparoscopic greater omentum resection by left lower entrance in patients with stage I ovarian cancer compared with conventional laparoscopy since 2012.

Materials And Methods

1.1 General information Retrospective 60 patients with stage I ovarian cancer who were hospitalized and diagnosed in Chongqing Ninth People's Hospital Beijing Ditan Hospital Affiliated to Capital Medical University and Luohu Maternal and Child Health Hospital Shenzhen from February 2012 to May 2020 were selected. The first 29 cases were treated with conventional laparoscopy(control group),next 31 cases were treated with left lower laparoscopic greater omentum resection (observation group). Case selection criteria: The patients had no severe medical diseases and can tolerate surgery. The maximum

diameter of the tumor was less than 12 cm. The Ethics Committee of Chongqing Ninth People's Hospital approved the study. All patients signed informed consent.

1.2 Method

Surgical procedures followed: The ascites or lavage fluid of pelvic cavity were collected for cytological examination; after high ligation of ovarian artery and vein, removal one or both adnexa were put into the specimen bag, and the rapid frozen pathology was carried out. The removal uterus was taken out from the vagina. pelvic and paraaortic lymph node were taken out from the vagina . greater omentum below transverse colon was excised. multi point peritoneal biopsy of paracolonic sulcus and pelvic wall were performed. appendectomy was performed(for mucinous tumor). The vaginal stump was sutured under laparoscope. The procedure were performed by conventional four ports (Fig. 1–3).

We took trendelenburg position to remove the greater omentum in control group, the surgeons faced the patient's feet, the laparoscopy was inserted from A point. In the observe group, the patient's position was anti-trendelenburg. Laparoscopic holder standed on the outside of the patient's left thigh, facing the patient's head, the laparoscopy was inserted from D point towardpatient's head. The surgeon standed between patient two legs. When the greater omentum near splenic flexure was resected, noninvasive forcep was put from incision A and ultrasonic scalpel was put from incision B; During the resection of the greater omentum near the liver, ultrasonic scalpel was put through incision A, and noninvasive forceps was put from the incision C (Fig. 4).

1.2.4 observation index The operation time (only removal the greater omentum) intraoperative blood loss(volume change of negative pressure suction bottle during omentum resection, we did not wash to avoid inaccurate measurement). Intraoperative complications(the injury of stomach, intestine, liver and spleen) and postoperative severe complications (intestinal obstruction bacteremia pulmonary embolism Lymphocyst respiratory failure and deep venous thrombosis) after omentum resection, hospital stay and postoperative gastrointestinal exhaust time. All patients were followed up every 3 months. The complications and recurrence or death were observed.

1.3 Statistical methods

Spss17.0 statistical software (IBM Corp., New York,NY)was used,the measurement data was expressed by $\bar{x} \pm s$, independent sample t test, Fisher exact test was used for counting data, and the test level was $\alpha = 0.05$.

Results

2.1 Two groups general condition The age was 30–69 years old, the body mass index was 17-28.8 kg/m^2, and the diameter was 4–12 cm; There was no significant difference in age, body mass index, tumor size(Table 1).

Table 1
Comparison of general conditions between the two groups

group	age(year)	BMI (kg/m2)	tumor diameter(cm)
observe group	53.6 ± 9.3	22.51 ± 1.68	9.1 ± 2.1
control group	55.1 ± 10.2	23.06 ± 2.17	8.9 ± 2.3
P-value	0.781	0.658	0.680

2.2 The two groups intraoperative conditions In the control group, transverse colon serosa layer was damaged and sutured with 3 – 0 absorbable suture under laparoscopy for 2 cases, the operation was successfully completed. There were not large blood vessels. There was no significant difference in intraoperative blood loss between the two groups. However, the omentum resection operation time in the observe group was significantly shorter than that in the control group(Table 2).

Table 2
Intraoperative conditions comparison between the two groups

group	blood loss(ml)	Omentum resectionoperative time(min)	intraoperative complications
observe group	10.68 ± 4.56	26.62 ± 6.41	0
control group	12.03 ± 5.23	55.88 ± 7.09	2
P-value	0.386	0.027	0.137

2.3 Postoperative conditions comparison There was no significant difference in postoperative hospital stay exhaust time and postoperative severe complications between the two groups. No serious complications occurred (Table 3).There is no recurrence or death cases up to now.

Table 3
Postoperative conditions comparison between the two groups

group	hospitalization (d)	exhaust time (d)	complications
observe group	13.6 ± 4.6	1.8 ± 0.7	0
control group	14.1 ± 4.8	1.7 ± 0.9	0
P-value	0.395	0.691	

Discussion

The greater omentum is a membranous tissue connecting stomach greater curvature and transverse colon[6]. The rate of peritoneal/omental metastasis in apparent early stage was 5.2%[7] Compared with traditional open surgery, laparoscopic surgery is superior to open surgery in operative vision and postoperative recovery time[8]. In epithelial ovarian cancer, minimally invasive surgery is not associated with poor survival in women with stage I disease [9]. Yoo [10] found that laparoscopic surgery did not decrease the overall survival rate and did not increase the risk of tumor cell dissemination and recurrence. In this study, there was no recurrence or death cases during the follow-up period, it it supports that laparoscopic surgery is feasible for stage I ovarian cancer.

In laparoscopic greater omental resection, because of its large coverage area, adjacent to the liver, stomach and spleen and other important organs, open and clear vision is an important. For conventional laparoscopic greater omental excision, the laparoscopy is put from the umbilical or near umbilical incision (point A) which limits vision, increasing the risk of damage surrounding organs. In order to reduce the visceral injury, ultrasonic scalpel should not be too close to transverse colon, greater curvature of stomach and splenic hilum. It is safe to remove omentum 0.5-1 cm away from normal organs surface. Although some teams used 5 ports technique for diaphragm peritoneal resection, we were used to use 4-trocar technique to perform surgery by changing ports, it was also feasible.

The main complications included bleeding embolism infection myocardial infarction intestinal obstruction organ injury fistula incision dehiscence, etc [11]. In control group, transverse colon serosa layer was damaged. However, the laparoscope was inserted by left lower operating hole (point D), there was enough space between the laparoscope and greater omentum,there was no organ injury in observe group, so the time in observe group was shorter than in control group. There was no significant difference in postoperative hospital stay and anal exhaust time between the two groups, the reasons may be: 1) there was no significant difference in the total operative time ; 2) it was related to postoperative chemotherapy; 3) the sample size was small. There were no serious complications in both groups, which indicated that left lower entrance for stage I ovarian cancer was safe.

To sum up, comparing with the conventional laparoscopic approach, left lower entrance can shorten the operation time. It has the characteristics of wide vision. In the future, prospective large sample and long-term further study is needed.

Declarations

Funding:

This study was funded by a grant from the Shenzhen Science creation Committee(grant no.JCYJ20190809104403566).

Competing interests statement:

They declares that she has no conflict of interest.

Research involving human participants:

All procedures performed in studies involving human participants were in accordance with the ethical standards of the institutional and/or national research committee and with the 1964 Helsinki declaration and its later amendments or comparable ethical standards.The study was approved by the Chongqing Ninth People's Hospital Ethics Committee.

Informed consent:

Informed consent was obtained from all individual participants included in the study.

References

1. Siegel RL,Miller KD,Jemal A. Cancer Statistics. CA Cancer J Clin.2017,67(1):7-30(2017).
2. Arri Coomarasamy MBChB MD FRCOG,G. Willy Davila MD FACOG,Kiong K. Chan MBBS FRCS FRCOG.141.Omental Procedures: Supracolic Omentectomy,Infracolic Omentectomy,Omental Biopsy[M].Gynecologic and Obstetric Surgery,Challenges and Management Options. :423-424(John Wiley & Sons,Ltd,2016).
3. Beijiao Qin, Wenyan Xu, Yanfang Li.Are Omentectomy and Lymphadenectomy Necessary in Patients With Apparently Early-Stage Malignant Ovarian Germ Cell Tumors?Int J Gynecol Cancer. 2019,29(2):398-403.
4. Antonino Ditto,Giorgio Bogani,Fabio Martinelli,Mauro Signorelli,Valentina Chiappa,Cono Scaffa,Alice Indini,et al.Minimally Invasive Surgical Staging for Ovarian Carcinoma: A Propensity-Matched Comparison With Traditional Open Surgery.J Minim Invasive Gynecol.2017,24(1):98-102.
5. Bogani G Borghi C Leone Roberti Maggiore U et al. Minimally Invasive Surgical Staging in Early -stage Ovarian Carcinoma: A Systematic Review and Meta -analysis. J Minim Invasive Gynecol.2017,24(4):552-562.
6. Aroeira LS,Aguilera A,Sánchez-Tomero JA,et al.Epithelial to mesenchymal transition and peritoneal membrane failure in peritoneal dialysis patients: pathologic significance and potential therapeutic interventions.J Am Soc Nephrol.2007,18(7) : 2004-2013.
7. Renée E W M van de Vorst,Jacob P Hoogendam,Maaike A van der Aa,Petronella O Witteveen,Ronald P Zweemer,Cornelis G Gerestein.The attributive value of comprehensive surgical staging in clinically early-stage epithelial ovarian carcinoma: A systematic review and meta-analysis.Gynecologic Oncology.2021,161(3):876-883.
8. Gallotta V, Jeong SY,Conte C,Trozzi R,Cappuccio S,Moroni R,et al. Minimally invasive surgical staging for early stage ovarian cancer: A long-term follow up. Eur J Surg Oncol. 2021 ,47(7):1698-1704.
9. Alexander Melamed,Nancy L Keating,Joel T Clemmer,Amy J Bregar,Jason D Wright,David M Boruta,et al. Laparoscopic staging for apparent stage I epithelial ovarian cancer[J]. Am J Obstet Gynecol .2017,216(1):50.e1-50.e12.

10. Yoo JG Kim WJ Lee KH Single-Site Robot-Assisted Laparoscopic Staging Surgery for Presumed Clinically Early-Stage Ovarian Cancer.J Minim Invasive Gynecol.2018,25(3):380-381.
11. Ahmed Elattar,Andrew Bryant,Brett A Winter-Roach,Mohamed Hatem,Raj Naik.Optimal primary surgical treatment for advanced epithelial ovarian cancer.Cochrane Database Syst Rev.2011,2011(8):CD007565.

Figures

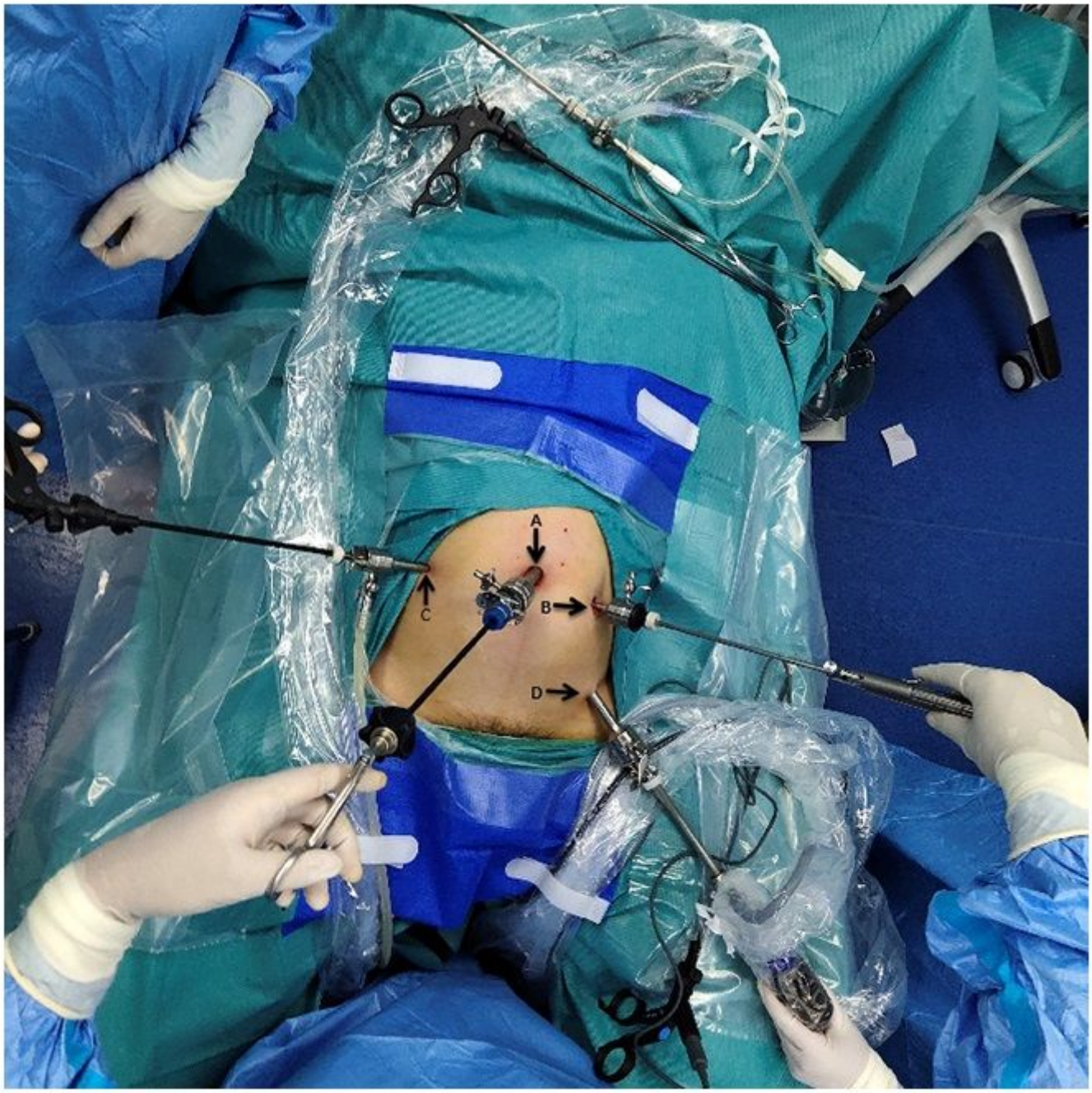

Figure 1

abdominal incisions in laparoscopic greater omental surgery The arrow shows the umbilicus. A and D were 10mm incision, B and C were 5mm. A is 3cm above the umbilicus; B and C are 0-1cm below the umbilicus. The horizontal position is 3-6cm away from the umbilicus, and D is 1/3 of the line between the left anterior superior iliac spine and the umbilicus.

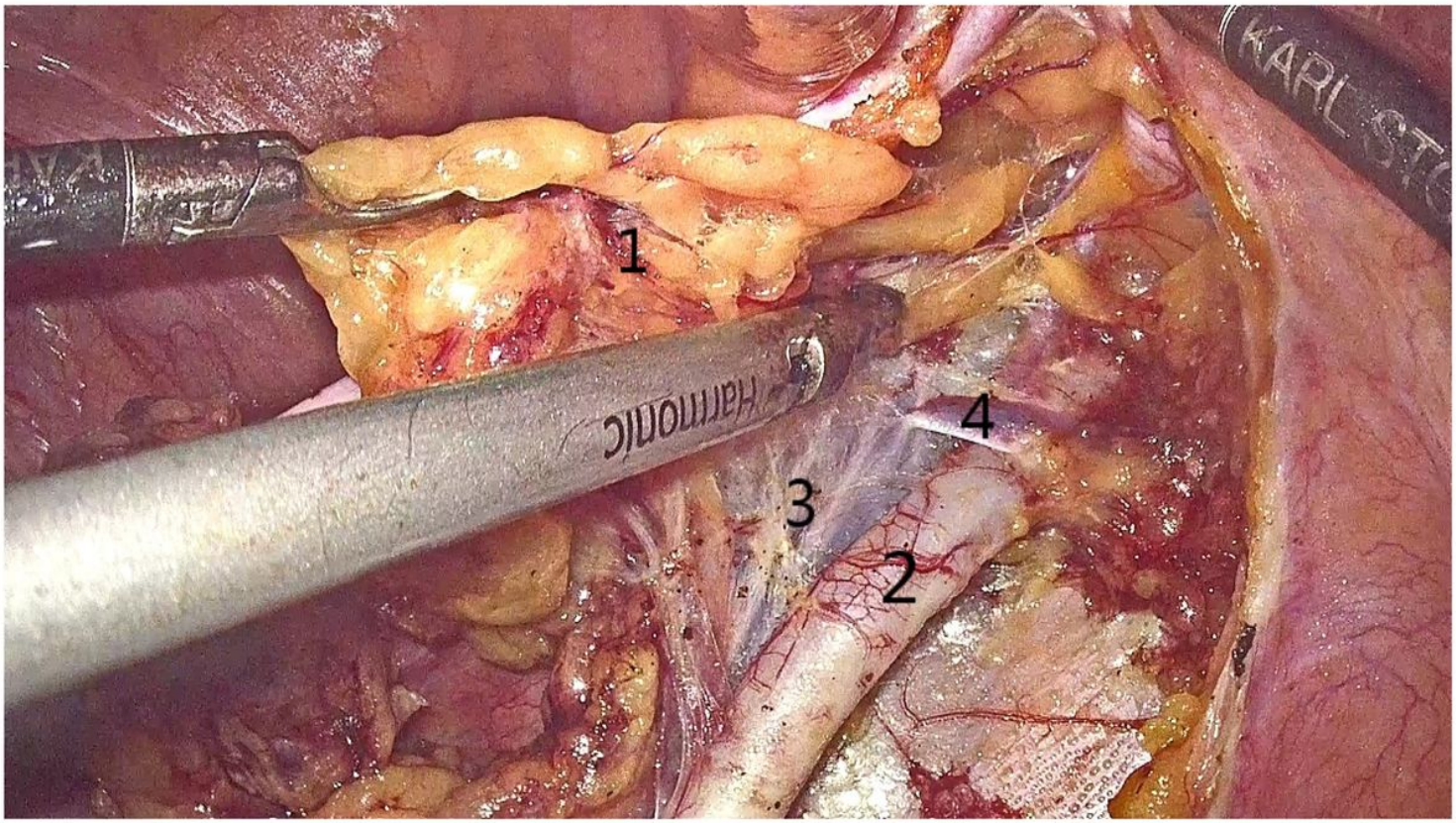

Figure 2

Right lymph nodes under external iliac vessels 1: right lymph nodes under external iliac vessels; 2: right external iliac artery 3: right external iliac vein 4: right deep circumflex iliac vein

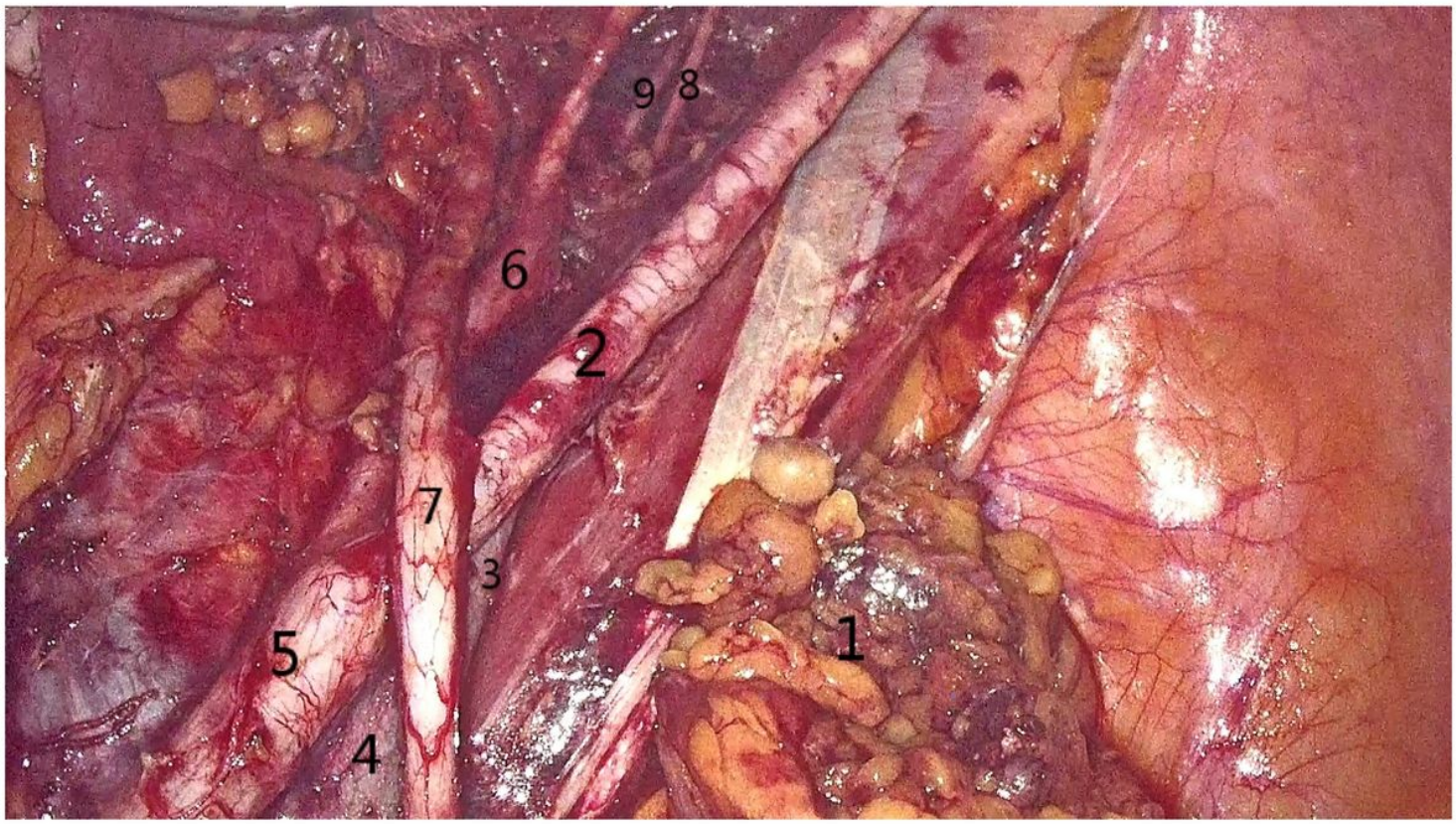

Figure 3

Right pelvic lymph node 1: Right pelvic lymph node; 2: right external iliac artery 3: right external iliac vein; 4: right common iliac vein; 5: right common iliac artery; 6: right internal iliac artery; 7: right ureter; 8: right obturator nerve 9 right obturator artery

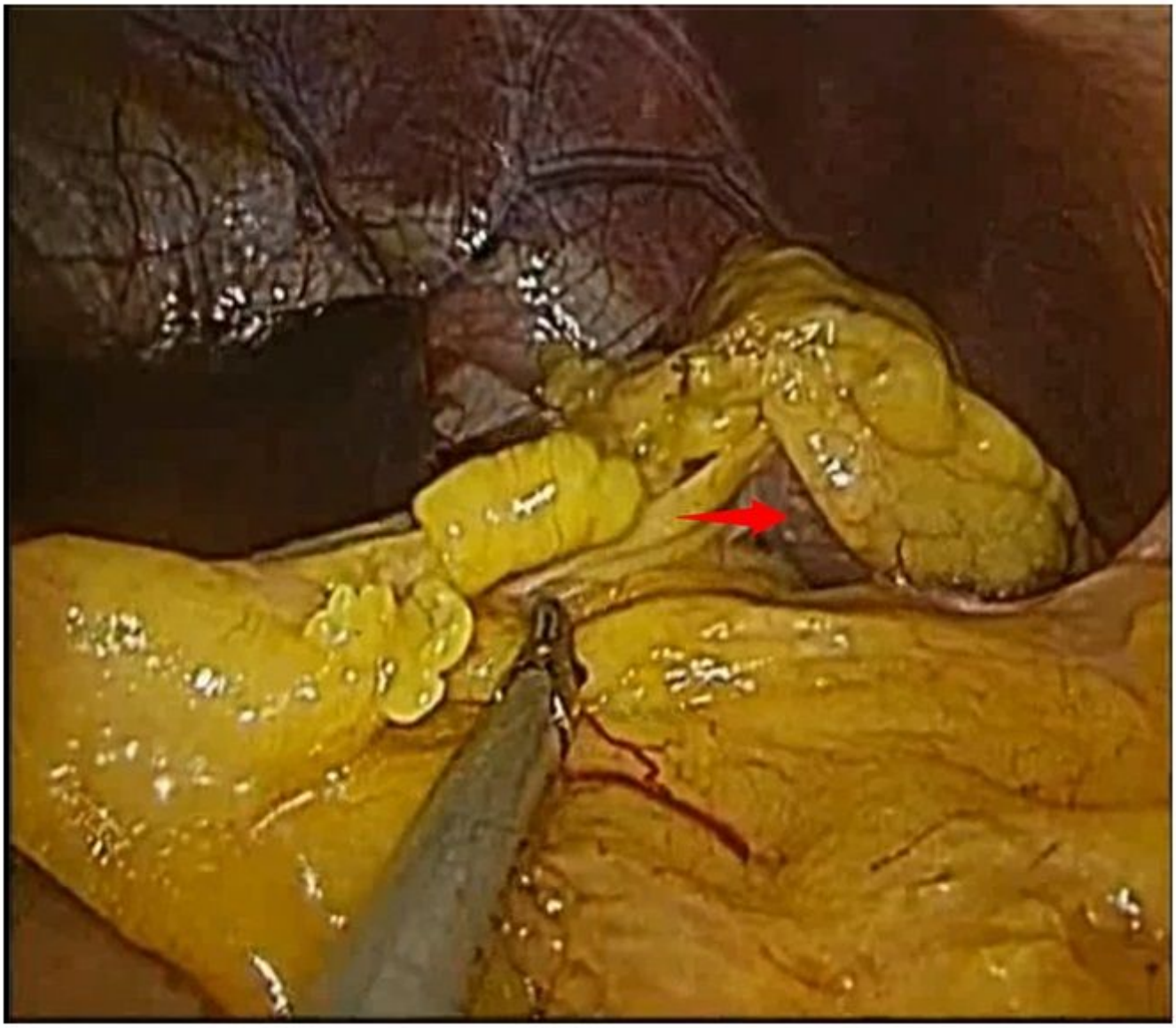

Figure 4

laparoscopic resection of splenic flexure of greater omentum The red arrow was spleen