Transcatheter Closure of Anastomotic Leakage of Aortic Root after Aortic Surgery for Type A Dissection: Two Case Reports

Lin Song
Department of Medical Ultrasound, The First Affiliated Hospital of Shandong First Medical University

Yiran Zhang
The First Affiliated Hospital of Shandong First Medical University

Binyu Zhou
The First Affiliated Hospital of Shandong First Medical University

Xiaozhou Zheng
The First Affiliated Hospital of Shandong First Medical University

Peixuan Shi
Shandong First Medical University

Haiyan Wang (Wanghaiyan96@126.com)
Shandong First Medical University

Case report

Keywords: Standford Type A dissection, Anastomotic leakage, Transcatheter closure, Clinical manifestation

Posted Date: September 28th, 2021

DOI: https://doi.org/10.21203/rs.3.rs-936582/v1

Abstract

Background: Anastomotic leakage of postoperative aortic dissection is an intractable complication with different clinical manifestations. It is important to detect and manage anastomotic leakage in a timely manner. This case report describes 2 patients who were admitted to the hospital with different clinical manifestations and were diagnosed with aortic root anastomotic leakage through imaging. Both patients received transcatheter closure treatment with definite early effects.

Case presentation: Two middle-aged women with aortic root anastomotic leakage who were admitted with different clinical manifestations and received transcatheter closure.

Conclusion: Paying attention to the clinical manifestations and imaging diagnosis of patients after aortic dissection surgery is important for early detection of disease progression. Transcatheter closure can be used as an alternative treatment who cannot tolerate secondary thoracotomy due to its small trauma and exact efficacy in the near and medium terms, but further follow-up is needed for long-term clinical outcomes.

Background

The incidence of anastomotic leakage after aortic dissection surgery is 5–8% [1–2]. Anastomotic leakage can result in heart failure, pseudoaneurysm formation, persistent enlargement of the dissecting false lumen, and hemolytic anemia. Surgical repair is still the most effective method, despite its high surgical risk, technical difficulty, and postoperative morbidity and mortality [1]. Transcatheter closure can be used as an alternative treatment because of its low trauma and efficacy. Herein, we describe 2 patients with aortic root anastomotic leakage who were admitted with different clinical manifestations and received transcatheter closure.

Case Presentation

Case 1

A 53-year-old woman was admitted to the hospital after experiencing chest pain for 1 week. She underwent aortic valvuloplasty, artificial vessel replacement of the ascending aorta and aortic arch, and stenting of the descending aorta trunk with a Cabrol shunt for a Stanford type A dissection 1.5 years ago. Follow-up echocardiography performed 20 days after the procedure revealed a visible gap between the posterior wall of the artificial vessel and the native vessel in the ascending aorta. Aortic computed tomography angiography(CTA) revealed a high-density contrast surrounding the artificial implantation. Two weeks prior, she experienced sudden headache, nausea, and vomiting, and was diagnosed with cerebral hemorrhage and subdural hematoma, which improved with hematoma drainage; however, she had sudden-onset chest pain. She had no history of hypertension. Physical examination revealed a heart rate of 77 bpm, blood pressure of 164/79 mmHg, enlarged heart border, and continuous murmur at the left 3rd–4th intercostal space. Laboratory tests showed normal myocardial enzyme and brain natriuretic

peptide (BNP) levels, and D-dimer level of 4.13 mg/L. Echocardiography revealed a gap between the posterior wall of the artificial vessel and the autologous aorta at the root (Fig. 1a). CTA revealed mild stenosis of the left anterior descending and normal pulmonary arteries. Aortic CTA showed that the aneurysm wrap has enlarged (Fig. 1b). Three-dimensional reconstruction revealed an aortic pseudoaneurysm (Fig. 1c). The diagnosis of an anastomotic leakage at the aortic root and pseudoaneurysm formation was clear. Aortic angiography revealed a 5-mm leakage located at the aortic root, and the contrast agent entered between the artificial vessel and autologous aorta through the leakage. A femoral artery-Cabrol shunt-leakage-femoral vein track was established. A 6-F delivery sheath was inserted through the femoral vein but failed to enter the leak due to an irregular angle; hence, the operator switched to the reverse approach and successfully passed through the leak and implanted a 7-mm VSD occluder. Unfortunately, repeat aortic angiography showed a residual shunting and visible aneurysm wrap. Another leak was found near the original leak, the femoral artery-Cabrol shunt-leakage-femoral vein track was re-established, and a 7-F delivery sheath was inserted through the femoral vein. Another 8-mm VSD occluder was deployed, with aortic angiography showing the position and morphology of the occluder without a visible aneurysm wrap (Fig. 1d). The patient's chest pain disappeared postoperatively.

Case 2

A 49-year-old woman was admitted to the hospital due to a 2-month history of chest tightness. Nine months ago, she underwent aortic valvuloplasty, artificial vessel replacement of the ascending aorta and aortic arch, and stenting of the descending aorta trunk with a Cabrol shunt for a Stanford type A dissection. Fifteen days postoperatively, CTA revealed a patchy high-density shadow around the artificial vessel of the ascending aorta (Fig. 2a), and echocardiography demonstrated a 5-mm gap with shunting between the posterior wall of the artificial vessel and the autogenous ascending aorta. On admission, physical examination revealed a heart rate of 91 bpm, blood pressure of 153/71 mmHg, coarse breath sounds, enlarged heart borders, continuous murmur in the aortic valve auscultation area, and mild edema in both lower extremities. Laboratory tests demonstrated normal myocardial enzyme and D-dimer levels, but the BNP level was elevated (1210 pg/mL). Echocardiogram revealed that the gap had enlarged to 10 mm, a 4-mm anastomotic leakage shunting was detected between the posterior wall of the artificial vessel and the wall of the autologous aorta at the sinotubular junction (Fig. 2b). Additionally, a shunting signal from the aneurysm wrap to the right atrium was observed (Fig. 2c), and left ventricular ejection fraction was 66%. Anastomotic leakage at the aortic root and right heart failure were diagnosed, and transcatheter closure was performed. Aortic angiography revealed a 6-mm leak located above the left coronary sinus, which had an irregular tunnel-like shape (Fig. 3a). A femoral artery-Cabrol shunt-leakage-femoral vein track was routinely established. Using the femoral vein approach, a 12/10-mm PDA occluder was used to close the leak, and repeat aortic angiography revealed a good position and morphology of the occluder, with only a small residual shunt around the occluder (Fig. 3b). The patient's chest tightness was relieved postperatively.

Discussion And Conclusions

The primary risk factors for anastomotic leakage at the aortic root are the vulnerable vascular tissues at the anastomosis site, aortic disease caused by non-specific inflammation, poor vascular anastomosis technology, and infection [3]. Currently, anastomotic leakage is preliminarily divided into three types [2]: type I, where the leakage is located at the anastomosis of the proximal ascending aorta, and the shunt goes into the right atrium from the aortic root while using the Cabrol shunt, resulting in heart failure; type II, where the leakage is located at the anastomosis of the ascending aorta, resulting in blood entering the aneurysm wrap to form a local pseudoaneurysm; and type III, where the leakage orifice is usually located at the anastomosis between the aortic arch and the intraoperative stent.

Cases 1 and 2 were diagnosed with type II and I anastomotic leakage, respectively. Case 1 presented with a sudden-onset chest pain, which is easily misdiagnosed as a new aortic dissection, acute coronary syndrome, or acute pulmonary embolism. It might be related to the following factors: (1) a sudden increase in blood pressure led to a significant incremental shunting into the aortic wrap cyst, then an obvious compression to adjacent tissue operated with a small Cabrol shunt; (2) the large shunting resulted in a decrease in coronary blood flow during diastole. Case 2 presented with severe heart failure associated with a significant increase in the Cabrol shunt due to a large anastomotic leakage.

A routine physical examination revealing a continuous murmur around the aortic valve region can aid in anastomotic leakage diagnosis [4]. Early postoperative echocardiographic and CTA findings of color shunting or high-density contrast of anastomosis and Cabrol shunting were signs of bleeding. If Cabrol shunting is present in the echocardiogram and an anastomotic leakage is not easily detected, the sonographer should carefully look for the leakage to avoid misdiagnosis. Transcatheter closure is the preferred procedure for high-risk patients who cannot tolerate secondary thoracotomy [2, 5]. The selection of the occluder also differs according to the leakage location, shape, and size. Currently, the commonly used devices include the VSD occluder, PDA occluder, and Amplatzer vascular plug (AVP). One of the technical difficulties in applying the occluder is that the scar tissue in the anastomotic leakage area is hard and inelastic; thus, it is difficult for the delivery sheath or guide catheter to pass through the leakage. To provide sufficient supporting force, it is conventional to use a hard guide wire or establish an intra-arterial track to ensure that the delivery system crosses the leakage. AVP or Amplatzer Duct Occluder II (ADO-II) is generally selected for sealing the currently reported case of aortic root anastomotic leakage. The advantages of ADO II are that the delivery sheath is thin, and its trafficability is good. Besides, the delivery sheath is flexible, and it can be guided by an ultra-smooth guidewire; thus, it is easy to pass through the small anastomotic leakage due to a lack of elasticity. The only shortcoming was that the detaining plate was large, and there was a risk of affecting the true lumen and branch blood flow after occlusion. The VSD occluder and domestic PDA occluder had a covered membrane structure, requiring a large-sized delivery system. The anastomotic leakage in our patients was large, and both occluders could pass through the leakage. Case 1 developed an ascending aortic pseudoaneurysm, with a large effective aneurysm cavity and regular shape. The guidewire track could be established to provide adequate support of the sheath tube, without the risk of puncturing the pseudoaneurysm. Therefore, a symmetrical

VSD occluder was implanted. In case 2, anastomotic leakage caused shunting between the aortic root and right atrium, and the leakage was located above the left coronary sinus in a tunnel shape. To avoid affecting the left coronary artery opening, a domestic PDA occluder was appropriate.

In conclusion, focusing on the clinical manifestations and imaging diagnosis of patients post-aortic dissection surgery is important for early detection of disease progression. The occluder and interventional approach should be individually selected. The short-term efficacy of transcatheter closure is definite, and further follow-up is needed for long-term clinical outcomes.

Abbreviations

CTA: Computed tomography angiography; BNP: Brain natriuretic peptide; AVP: Amplatzer vascular plug; ADO-II: Amplatzer Duct Occluder II.

Declarations

Acknowledgments

Throughout the writing of this dissertation I have received a great deal of support and assistance. First of all, I would like to thank Director Haiyan Wang for her help and support in my thesis writing. Secondly, I want to thank Director Xiaozhou Zheng of Cardiovascular Surgery for patiently explaining the operation and equipment selection related to surgery. In addition, I would like to thank Peixuan Shi for helping to collect relevant information. Finally, I would like to acknowledge my colleagues Yiran Zhang and Binyu Zhou , for their wonderful collaboration and patient support.

Authors' contributions

Lin Song collated data and wrote this article, Haiyan Wang was responsible for the article revision and proofreading. Yiran Zhang, Binyu zhou, Peixuan Shi were responsible for assisting Lin Song in data collation. Xiaozhou Zheng interpreted the operation and equipment selection related to surgery. All authors provided comments on the report at various stages of development. All authors read and approved the fnal manuscript.

Funding

Jinan clinical medicine science and technology innovation program; The Project number: 201907043.

Availability of data and materials

The data and material used and/or analyzed of this patient are available from the corresponding author on reasonable request.

Ethics approval and consent to participate

Our institution's Research Ethics Board does not require a review or approval for case reports.

Consent for publication

Consent for publication was obtained for every individual person's data included in the study.

Competing interests

The authors declare that they have no conflict of interest.

References

1. Luciani N, De Geest R, Lauria G, et al. Late reoperations after acute aortic dissection repair: single-center experience. Asian Cardiovasc Thorac Ann. 2015;23:787–94. https://doi.org/10.1177/0218492315584523.
2. Wu W, Ke Y, Zhao H, Huang L, Pu J. Trans-catheter closure of aortic anastomosis leak after aortic replacement: classifications and techniques. J Thorac Dis. 2020;12:4883–91. https://doi.org/10.21037/jtd-20-1496.
3. Chiesa R, Bertoglio L, Kahlberg A, Rinaldi E, Tshomba Y, Melissano G. Redo surgery in ascending aorta and aortic arch. J Cardiovasc Surg (Torino). 2014;55:803–12.
4. Pu J, Huang L, Wu W. Transcatheter closure of anastomotic leakage after aortic surgery for type A dissection with the amplatzer duct occluder II. Cardiovasc Intervent Radiol. 2017;40:1274–7. https://doi.org/10.1007/s00270-017-1640-2.
5. Ghazy T, Mahlmann A, Fajfrova Z, et al. Anastomotic leak after surgical repair of type A aortic dissection - prevalence and consequences in midterm follow-up. Vasa. 2017;46:377–82. https://doi.org/10.1024/0301-1526/a000644.

Figures

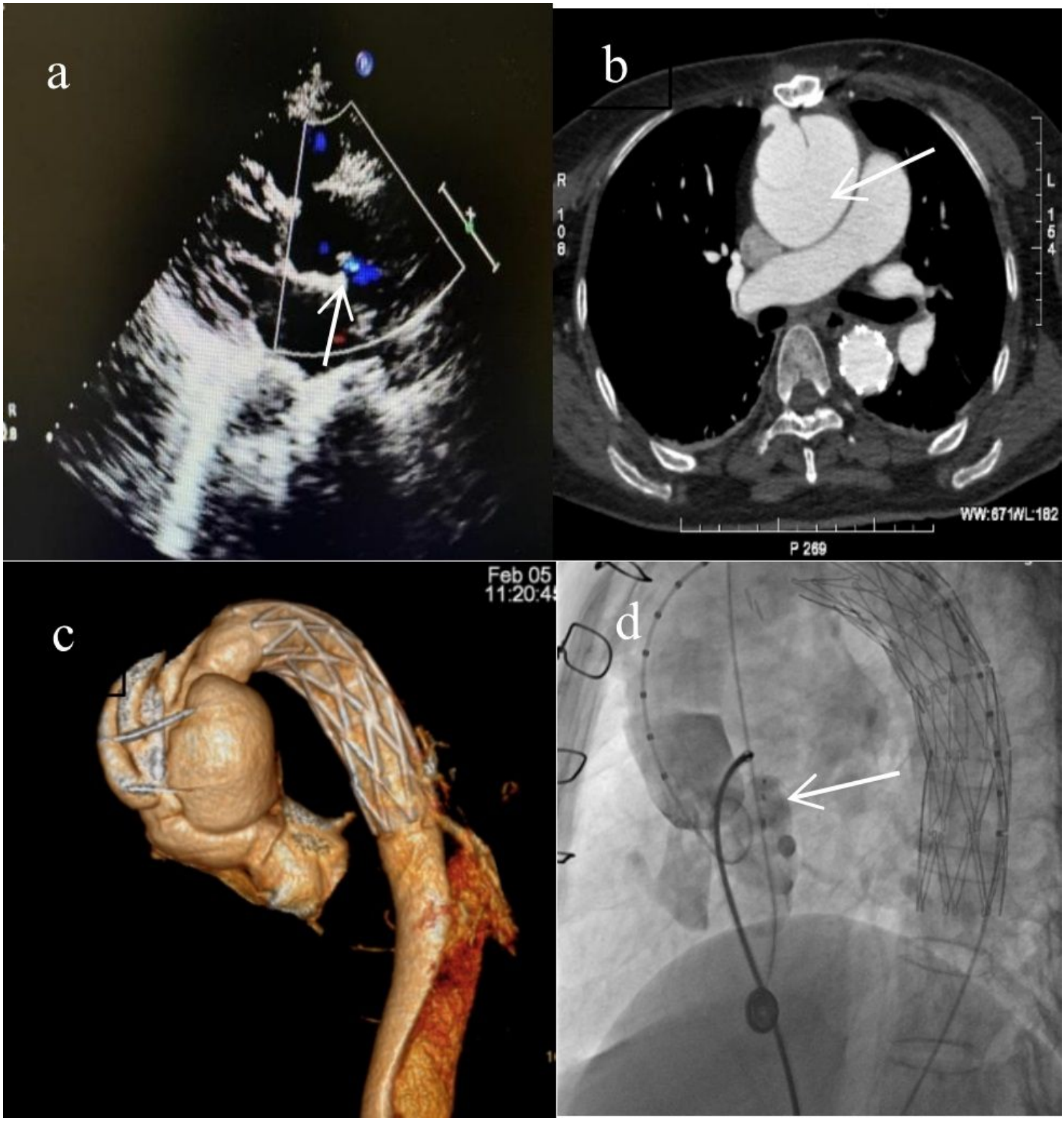

Figure 1

Preoperative echocardiography, CTA and postoperative DSA. a Echocardiography revealed a gap between the posterior wall of the artificial vessel and the autologous aorta at the root (arrow). b CTA showed that the aneurysm wrap(arrow). c Three-dimensional reconstruction revealed an aortic pseudoaneurysm. d postoperative DSA showing the position and morphology of the occluder without a visible aneurysm wrap(arrow).

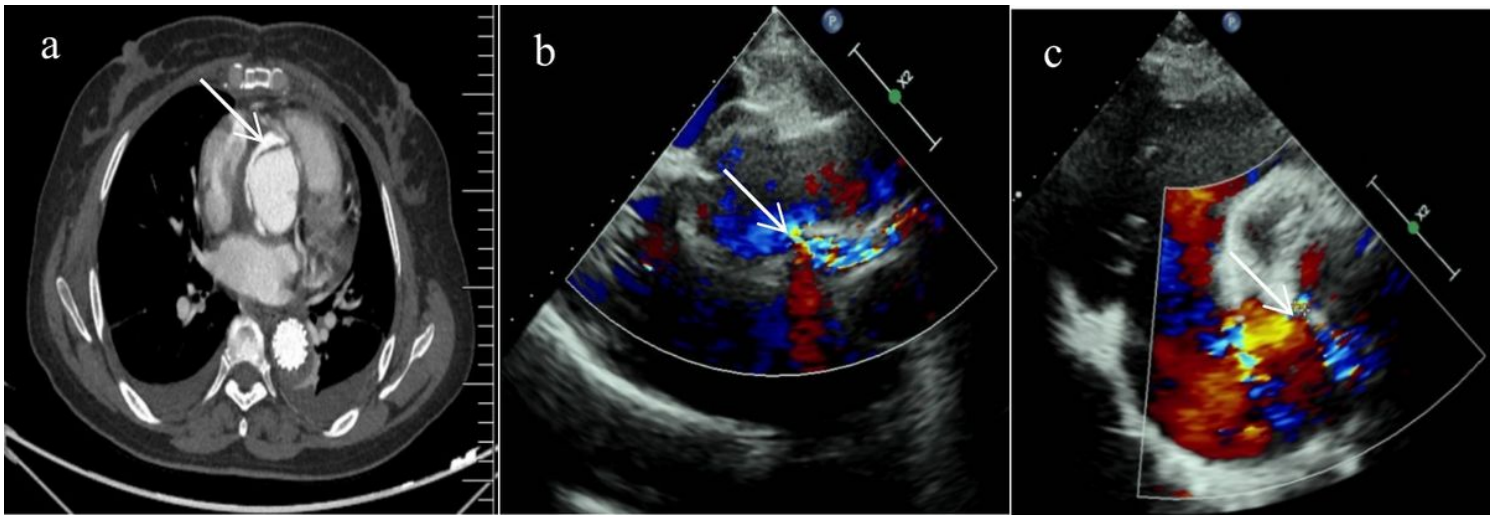

Figure 2

Preoperative CTA and echocardiography. a CTA revealed a patchy high-density seadow around the artificial vessel of the ascending aorta(arrow). b Echocardiogram revealed that the gap had enlarged to 10 mm , an 4-mm anastomotic leakage shunting was detected between the posterior wall of the artificial vessel and the wall of the autologous aorta at the sinotubular junction(arrow). c a shunting signal from the aneurysm wrap to the right atrium(arrow).

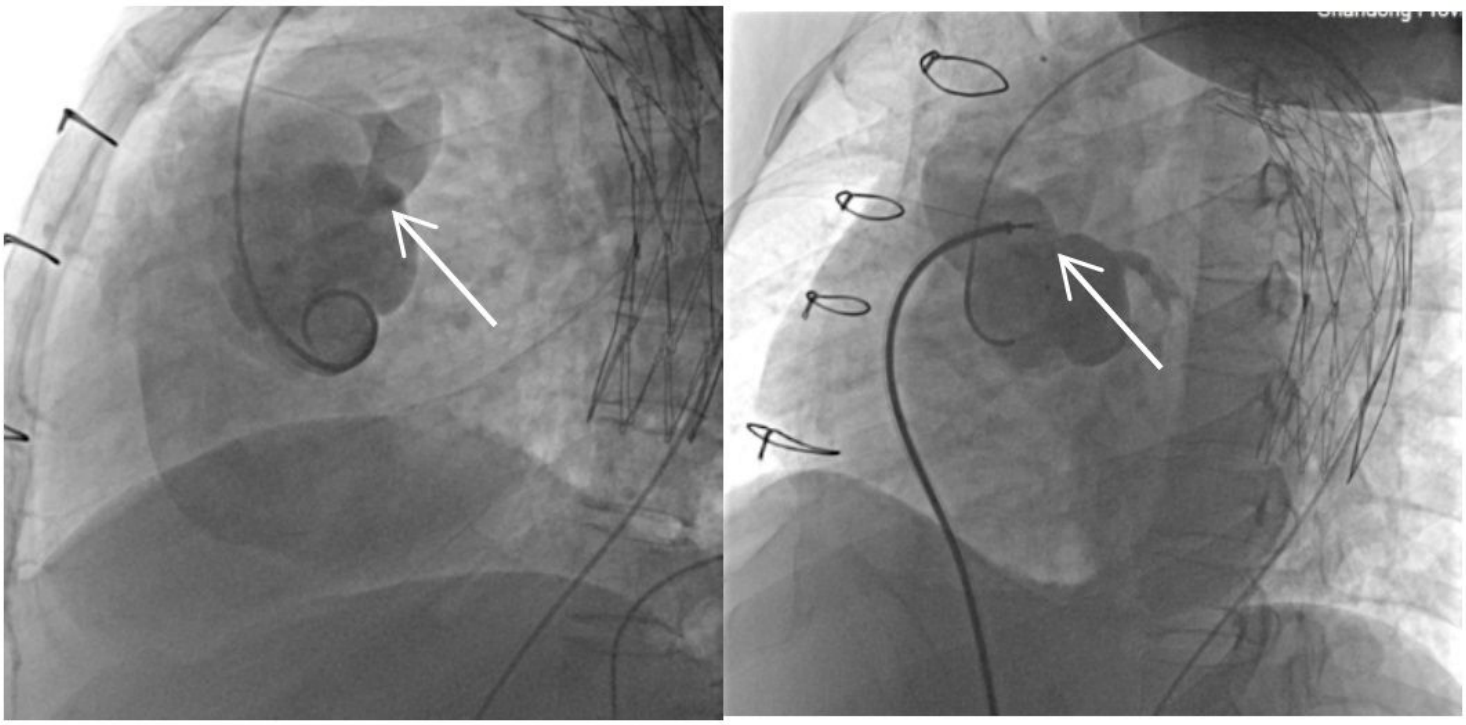

Figure 3

Preoperative and postoperative DSA. a Preoperative DSA revealed a 6-mm leak located above the left coronary sinus(arrow). b postoperative DSA revealed a good position and morphology of the occluder, with only a small residual shunt around the occluder(arrow).