Invasiveness prediction of pure ground glass nodules(≤3cm)

Ziyi Wang
Xiaogan Hospital Affiliated to Wuhan University of Science and Technology(Xiaogan Central Hospital)
https://orcid.org/0000-0002-2484-3382

Lindan Zuo
Childhealth Advocacy International: Maternal and Childhealth Advocacy International

Zhimin Liao
Xiaogan centeral hostpital

Wei Zheng
Xiaogan centeral hostpital

Qi Hu
Xiaogan centeral hostpital

Lei Pan
Xiaogan centeral hostpital

Xiongwen Guo
Xiaogan centeral hostpital

Weijiang Huang (hwj302@163.com)
Xiaogan centeral hostpital

Research article

Keywords: lung cancer, high resolution CT, pure ground glass lung nodule, pathological diagnosis

Posted Date: September 30th, 2021

DOI: https://doi.org/10.21203/rs.3.rs-936623/v1

Abstract

Background

Pure ground-glass nodules are considered to be radiologically noninvasive in lung adenocarcinoma. However, some pure ground-glass nodules are found to be invasive adenocarcinoma pathologically. This study aimed to find out the correlation between the clinical imaging features and the degree of invasion of pulmonary pure ground glass nodules (≤ 3cm).

Methods

The clinical data of 886 patients who underwent minimally invasive surgery for pulmonary nodules from June 2013 to June 2016 were collected. Among them, 72 patients had complete clinical data and isolated pulmonary ground glass nodule resection, and the diameter of pulmonary ground glass nodule was less than or equal to 3 cm.

Results

A total of 72 eligible patients were included in the study. Univariate analysis showed that there were significant differences in carcinoembryonic antigen, maximum diameter and area of pure ground glass nodules in patients with pre-invasive lesions and invasive lesions($P < 0.05$). Multivariate logistic regression analysis showed that there were only statistical differences in the maximum diameter of nodule pre-invasive lesions and invasive lesions. The optimal cutoff value for CT-maximal diameter to predict pre-invasive lesions or invasive lesions was 1.08cm.

Conclusion

It is reliable to predict the pathological types of nodules (pre-invasive and invasive) by measuring the maximum diameter of pure ground glass nodules, and the most reliable cut-off value is 1.08cm.

Introduction

Pure ground glass nodules (pGGNs) are defined as lesions showing hazy increased attenuation that does not obliterate the underlying bronchial or vascular structures on high-resolution computed tomography (HRCT)[1]. With the continuous development of society and the continuous improvement of people's living standards, the awareness of physical examination is gradually enhanced. In addition, with the popularization of high-resolution CT and AI, more and more pulmonary nodules were found, including ground glass nodules.[2–4] Causes of pulmonary ground glass nodules include infection, exudation, bleeding, etc. However, after long-term investigation, persistent ground glass nodules after surgery were

frequently confirmed to be pre-invasive or invasive lesions of lung cancer, Including AAH、AIS and early-stage lung adenocarcinoma [2.21]. Different diagnosis, treatment and follow-up plans need to be developed for ground glass nodules of different pathological types. The main purpose of this paper is to obtain the best prediction method to evaluate the pathological types of nodules according to different clinical imaging characteristics of nodules, so as to provide clinicians with more accurate diagnosis and treatment strategies.

Materials And Methods

Patients, Data Collection

The clinical data of 886 patients who underwent minimally invasive surgery for lung cancer or suspected lung cancer from June 2013 to June 2016 in the Department of Thoracic Surgery of Xiaogan Central Hospital were collected for re-screening. The screening conditions were as follows: 1. Chest high-resolution CT was performed one week before operation, and the diameter of pure ground glass nodule ≤ 3cm; 2. Patients have complete case data; 3. The surgically removed nodules were isolated pure ground glass nodules; multiple pure ground glass nodules and mixed ground glass nodules need to be excluded; 4. No previous history of lung surgery; 5.No previous chronic obstructive pulmonary disease, pulmonary insufficiency and other diseases. The clinical data of 72 patients were collected, including gender、age、nodule location、surgical method、pathological type and tumor markers(carcinoembryonic antigen, CEA/ cytokeratin 21 – 1, Cyfra21-1/ Neuron specific enolase, NSE / Squamous cell carcinoma associated antigen, SCCA). The patients were required to undergo high resolution CT (HRCT) examination before surgery, and the nodule data were based on averaged data measured by three radiologists. The postoperative pathology of nodules was confirmed again by two pathologists. If there was any disagreement, senior technologist would be consulted to reach final consensus.

Histopathology of lung lesion was classified as atypical adenomatous hyperplasia (AAH), adenocarcinoma in situ (AIS), minimally invasive adenocarcinoma (MIA), or invasive adenocarcinoma (IA) according to the 2015 World Health Organization (WHO) classification. Staging of lung cancer was based on the seventh edition of the American Joint Committee on Cancer cancer staging manual.

CT scans were performed using GE Discovery CT 750 HD gem detectors. The scanning parameters were as follows: pitch, 1.2; section thickness and interval, 5.0 and 5.0 mm, respectively; reconstruction section width and interval, 1.0 and 1.0 mm, respectively; field of view, 375 mm; voltage, 120 kV; and electric charge, 270 mAs. Scanning was performed with the patient in the supine position from the laryngeal to the level of the kidney during inspiration. The maximum diameter and area of the nodule were measured on the lung window. The lung windows were set at a window width of 1600 Hounsfield units (HU) and a window level of -600 HU. Using the delineation plug-in in the image browsing system, the maximum diameter and area of the nodule are measured at the plane where the nodule can be exposed to the maximum extent (the nodule outline is delineated at the edge of the nodules). Then the software will automatically display the maximum diameter and area of the nodule and the CT density of this area.

Statistical Analysis

The chi-square test, Fisher exact test, Kruskal–Wallis test, were used to evaluate the differences in baseline characteristics.

Logistic regression was conducted to determine the association between clinical or radiographic variables and tumor invasion for pGGNs. The potential factors associated with tumor invasion were obtained by univariate logistic regression analysis. Factors with P values less than 0.1 in univariate analyses were included in multivariate regression models (enter model) to identify independent factors.

Receiver operating characteristic (ROC) curve was used to determine and calibrate predictors. The cutoff value for invasiveness prediction was determined based on the value that maximized the Youden's index.

All statistical analyses were performed using IBM SPSS (version 27.0; IBM Corp;China-Chinese). It was considered statistically significant when p 0.05 .

Results

Baseline Characteristics

According to the inclusion criteria, a total of 72 patients were included in this study, including 24 males and 48 females, with an average age of 55.89 years (aged from 25 to 77 years). The average maximum diameter of pulmonary pure ground glass nodules was 1.28 cm (diameter from 0.48 to 2.99 cm), and the average area was 1.09 cm^2(size from 0.44 to 4.84 cm^2), average CT density was − 655.91 HU (density from − 830.0 to -406.6 HU). The pulmonary lobes of nodules were: right upper lung (37 cases), right middle lung (4 cases), right lower lung (6 cases), left upper lung (16 cases) and left lower lung (9 cases); the surgical methods for nodules were lobectomy (17 cases), segmental resection (7 cases) and wedge resection (48 cases). Postoperative pathology included 40 cases of AAH/AIS, 20 cases of MIA and 12 cases of IAC. Patient characteristics are shown in Table 1.

Table 1
Clinicopathologic characteristics of enrolled patients with pure ground-glass nodule

	Total (n = 72)	aah + ais (n = 40)	mia + ia (n = 32)	t/Fisher/c^2	p
gender				0.450	0.502
male	24 (33.33)	12 (30.00)	12 (37.50)		
female	48 (66.67)	28 (70.00)	20 (62.50)		
age	55.89 ± 11.16	54.05 ± 12.93	58.19 ± 8.07	-1.660	0.102
parts					0.272
right upper lung	37 (51.39)	20 (50.00)	17 (53.12)		
right lower lung	6 (8.33)	3 (7.50)	3 (9.38)		
right middle lung	4 (5.56)	4 (10.00)	0 (0.00)		
left upper lung	16 (22.22)	10 (25.00)	6 (18.75)		
left lower lung	9 (12.50)	3 (7.50)	6 (18.75)		
operation method					0.183
lung segment	7 (9.72)	2 (5.00)	5 (15.62)		
lobes of lung	17 (23.61)	8 (20.00)	9 (28.12)		
pulmonary wedge	48 (66.67)	30 (75.00)	18 (56.25)		
cea	1.93 ± 1.13	1.63 ± 1.00	2.29 ± 1.20	-2.525	0.014
cyfra21-1	2.57 ± 1.32	2.65 ± 1.55	2.47 ± 0.98	0.553	0.582
nse	11.22 ± 2.72	10.88 ± 3.04	11.65 ± 2.22	-1.193	0.237
scca	1.01 ± 0.68	0.99 ± 0.68	1.03 ± 0.68	-0.268	0.790
maximum diameter	1.28 ± 0.56	1.05 ± 0.46	1.57 ± 0.54	-4.432	< 0.001
area	1.08 ± 0.95	0.75 ± 0.78	1.50 ± 0.99	-3.503	0.001
CT density	-655.91 ± 86.63	-653.67 ± 97.60	-658.71 ± 72.03	0.244	0.808
ages-roc				13.903	< 0.001

The P values in bold indicated statistical significance (P 0.05). CT, computed tomography; cea,carcinoembryonic antigen.cyfra21-1,cytokeratin 21 – 1.nse,neuron specific enolase.scca,squamous cell carcinoma associated antigen.roc, receiver operating characteristic.aah,atypical adenomatous hyperplasia.ais,adenocarcinoma in situ.mia,minimally invasive adenocarcinoma.ia,invasive adenocarcinoma.

	Total (n = 72)	aah + ais (n = 40)	mia + ia (n = 32)	t/Fisher/c^2	p
< 45.5	14 (19.44)	14 (35.00)	0 (0.00)		
≥ 45.5	58 (80.56)	26 (65.00)	32 (100.00)		
cea-roc				9.088	0.003
< 1.75	39 (54.17)	28 (70.00)	11 (34.38)		
≥ 1.75	33 (45.83)	12 (30.00)	21 (65.62)		
maximum diameter-roc				20.160	< 0.001
< 1.08	30 (41.67)	26 (65.00)	4 (12.50)		
≥ 1.08	42 (58.33)	14 (35.00)	28 (87.50)		
area-roc				21.780	< 0.001
< 0.79	40 (55.56)	32 (80.00)	8 (25.00)		
≥ 0.79	32 (44.44)	8 (20.00)	24 (75.00)		
CT density- roc				2.205	0.138
<-579.8	60 (83.33)	31 (77.50)	29 (90.62)		
≥-579.8	12 (16.67)	9 (22.50)	3 (9.38)		

The P values in bold indicated statistical significance (P 0.05). CT, computed tomography; cea,carcinoembryonic antigen.cyfra21-1,cytokeratin 21 – 1.nse,neuron specific enolase.scca,squamous cell carcinoma associated antigen.roc, receiver operating characteristic.aah,atypical adenomatous hyperplasia.ais,adenocarcinoma in situ.mia,minimally invasive adenocarcinoma.ia,invasive adenocarcinoma.

Comparing the two groups, gender (P = 0.502), age (P = 0.102), nodule location (P = 0.272), surgical method (P = 0.502), tumor marker cyfra21-1 (P = 0.582), nse (P = 0.237), scca (P = 0.790), nodule CT density (P = 0.808) showed no statistical difference. There was a statistical difference of cea (P = 0.014) in the lung of patients with pure ground glass nodules. In addition, there were statistical differences in the maximum diameter (P < 0.001) and area (P = 0.001) of pulmonary pure ground glass nodules in imaging. ROC curve was used to find the optimal cut-off point for each clinical imaging feature, and the cut-off point was used as the boundary to dichotomize each data. Based on single factor analysis, it was found again that there were statistically significant differences in age (P < 0.001), cea (P = 0.003), maximum diameter (P < 0.001) and area (P < 0.001) of pure ground glass nodule. 14 patients were younger than 45.5 years old, and all of them were diagnosed with pre-invasive lesions (AAH, AIS).

Table 2
Univariate and multivariable logistic regression analyses of factors between noninvasive and invasive adenocarcinoma(N = 72)

Variable	Univariate		multivariable	
	OR (95%CI) P		OR (95%CI) P	
gender		0.503		
male	Reference			
female	0.714 (0.267, 1.912)			
age	1.036 (0.991, 1.083)	0.122		
parts				
right upper lung	Reference			
right lower lung	1.176 (0.209, 6.609)	0.854		
right middle lung	0.000 (0.000, Inf)	0.989		
left upper lung	0.706 (0.212, 2.346)	0.570		
left lower lung	2.353 (0.510, 10.859)	0.273		
operation method				
lung segment	Reference			
lobes of lung	0.450 (0.068, 2.998)	0.409		
pulmonary wedge	0.240 (0.042, 1.368)	0.108		
Cea	1.753 (1.091, 2.819)	0.020	1.570 (0.940, 2.624)	0.085
cyfra21-1	0.899 (0.616, 1.311)	0.580		
Nse	1.116 (0.929, 1.339)	0.242		
Scca	1.100 (0.552, 2.192)	0.786		
maximum diameter	9.395 (2.631, 33.543)	0.001	50.340(1.746, 1451.122)	0.022
Area	3.188 (1.446, 7.029)	0.004	0.311 (0.049, 1.977)	0.216
CT density	0.999 (0.994, 1.005)	0.805		

The P values in bold indicated statistical significance (P 0.05). OR, Odds ratio; CI, confidence interval; CT, computed tomography; cea,carcinoembryonic antigen.cyfra21-1,cytokeratin 21 – 1.nse,neuron specific enolase.scca,squamous cell carcinoma associated antigen.

Factors Associated With Invasive Adenocarcinoma for Pure Ground-Glass Nodules

Logistic regression analysis was performed to evaluate the correlation between clinical imaging features and the invasiveness of pure ground glass nodules. Univariate logistic regression analysis showed that cea (OR, 1.753; 95% CI, 1.091–2.819; P = 0.020)maximum diameter of ground glass nodule (OR, 9.395; 95% CI, 2.631–33.543; P = 0.001) and area of ground glass nodules (OR,3.188;95% CI1.446–7.029P = 0.004)were statistically different. Then multivariate logistic regression analysis showed that among these clinical imaging features, only the maximum diameter of ground glass nodule (OR, 50.340; 95% CI, 1.746-1451.122; P = 0.022) was an independent factor for predicting the invasiveness of ground glass nodules, while cea (OR, 1.570; 95% CI, 0.940–2.624; P = 0.085) and nodule area of ground glass (OR, 0.311; 95% CI, 0.049–1.977; P = 0.216) were not.

ROC curve was drawn to determine the optimal cut-off point for pre-invasive lesions (AAH, AIS) and invasive lesions (MIA, IAC). Compared with the ground glass nodule area AUC 0.804 (0.699–0.908), the maximum diameter AUC 0.823 (0.724–0.921) of ground glass nodule has better predictability. The optimum cut-off point for the maximum diameter of ground glass nodule was 1.08cm (sensitivity 0.871, specificity 0.641).

Discussion

With the gradual increase of chest high-resolution CT examinations, thoracic surgeons encounter more and more cases of pure ground glass nodules in clinical work. About 16–27% cases of pure ground glass nodules are diagnosed as infiltrating adenocarcinoma after surgery[5–7]. Therefore, what kind of pure ground glass nodules need surgery? This requires thoracic surgeons to distinguish the pathological types (pre-invasive or invasive) of pure ground glass nodules according to certain clinical imaging features. In this way, accurate diagnosis and reasonable treatment of tumor can be achieved, and transitional treatment can be avoided[12].

In this study, the pathologic imaging data of 72 patients were collected. Multivariate regression analysis showed that the maximum diameter of the nodules (P = 0.022) was an independent factor in predicting the invastivity of pure ground glass nodules[13–14]. Coincidentally, the maximum diameter of nodules is the most commonly used and easily collected data in clinical imaging[6–11]. A cutoff diameter of 10 mm for pre-invasive GGO nodules and 14 mm for invasive GGO nodules have been previously reported.[15] Eguchi et al. also reported a cutoff diameter of 11 mm in evaluating the invasiveness of pure GGO nodules.[16] Recently, Li et al. indicated that the GGO nodules showed a tendency to be invasive adenocarcinoma if the tumor diameter was larger than 13.5 mm.[17] Until now, there has been no definitive surgical policy for pure GGO nodules. Generally, a pure GGO nodule larger than 1 cm should be considered indicative for surgery. [18]

In daily clinical work, we always talk about the density of nodules, and think that the higher the density of nodules, the stronger the aggressiveness. [19–20]However, the conclusions are always contrary to experience. In this study, univariate regression analysis found that there was no statistical difference in CT density (P = 0.805) of pure ground glass nodules.

The tumor markers of patients with pure ground glass nodules are within the normal range of reference values. Therefore, Whether patients with pure ground glass nodules need to be tested for tumor markers. The answer of this study is yes .Univariate logistic regression analysis showed that CEA(P = 0.020) was significantly different. The best cut-off point of clinical imaging features was found by ROC curve. Taking the cut-off point as boundary, the data were divided into two categories, and single factor and multifactor analysis were carried out again. The results showed the carcinoembryonic antigen(cea) value was 1.75 at the cut-off point, and there was significant difference in multivariate logistic regression analysis. Results of univariate and multivariable logistic regression analyses are shown in Table 3.

Table 3
Univariate and multivariable logistic regression analyses of factors between noninvasive and invasive adenocarcinoma in pure groundglass nodules with optimal cutoff(N = 72)

Variable	**Univariate**		**multivariable**	
	OR (95%CI) P		**OR (95%CI) P**	
cea-roc				
< 1.75	Reference		Reference	
≥ 1.75	4.455 (1.647, 12.045)	0.003	5.695 (1.562, 20.758)	0.008
maximum diameter-roc				
< 1.08	Reference		Reference	
≥ 1.08	13.000 (3.789, 44.599)	< 0.001	6.548 (1.055, 40.632)	0.044
area-roc				
< 0.79	Reference		Reference	
≥ 0.79	12.000 (3.940, 36.550)	< 0.001	3.537 (0.703, 17.786)	0.125
The P values in bold indicated statistical significance (P 0.05). OR, Odds ratio; CI, confidence interval; cea, carcinoembryonic antigen				

Among other clinical features, we found that the incidence of pure ground glass nodules in female patients was 66.67%, but there was no statistical difference in whether the nodules were invasive. In our study, nodules mostly occurred in the upper lobe of the right lung (51.39%), and pulmonary wedge resection was the most selected surgical method (66.67%). A phase III study (JCOG0804) investigated the application of sublobar resection in peripheral GGNs with size 2 cm or less and consolidation-to-tumor ratio 0.25 or less, and the 5-year RFS was 99.7%.[22,23]Therefore, pulmonary wedge resection is sufficient

for pure ground glass nodules with a maximum diameter of less than or equal to 2cm. In this study, there were 6 patients with nodules larger than 2cm, of which 3 patients underwent pulmonary wedge resection and the remaining 3 patients underwent lobectomy. It can be found that the patients who underwent pulmonary wedge resection were elderly patients, with an average age of 64 years; On the contrary,the patients who underwent pulmonary lobectomy were young and middle-aged, with an average age of 48 years. Perhaps this is related to the surgeon's subconscious belief that young patients should undergo radical surgery to obtain a higher survival rate. However, whether ground glass nodules with a maximum diameter greater than 2cm are suitable for wedge or segmental resection depends on the results of the JOCG1211 study.[24]The pathology of the 6 patients was divided into 4 cases of invasive lesions (1 wedge-shaped lesion and 3 pulmonary lobes), 2 cases of pre-invasive lesions(2 wedge-shaped lesions). A particularly striking data can be found in this study. In Table 1, When the age was less than the optimal cut-off point (45.5 years), 14 patients (19.44%) were diagnosed as pre-invasive lesions by postoperative pathology, and univariate analysis showed statistical differences. Other studies was found no statistical difference in age in the aggressiveness of ground glass nodules .[25,26]May be stratified analysis of patient age was not performed in these studies.

Study Limitations

Our study has several limitations. 1. This was a single-center retrospective study; 2. 72 cases of pure ground glass nodules were recorded in this study, but the data collected were limited. Therefore, more data should be collected for re-analysis and verification;. 3. These nodules are subjectively selected by clinicians, excluding those pure ground glass nodules that were eliminated by clinicians, so selection bias may exist; 4. None of these patients were followed up. If the follow-up results were included, the study would be more complete.

Conclusions

The maximum diameter of the pure ground glass nodule can be used to assess whether the nodule is invasive, and the optimal cut-off point is 1.08cm. However, CT density of pure ground glass nodules commonly used in clinical practice cannot be used to evaluate whether the nodules are invasive or not.

Declarations

Contributions

(I) Conception and design: Ziyi Wang; (II) Administrative support: Weijiang Huang, Zhimin Liao, Wei Zheng , (III) Provision of study materials or patients: Ziyi Wang; (IV) Collection and assembly of data: Lindan Zuo,Xiongwen Guo ;(V) Data analysis and interpretation: Lindan Zuo; (VI) Manuscript writing: All authors; (VII) Final approval of manuscript: All authors.

Conflict of interests

The authors declare that there are no conflict of interests.

Ethics approval

This study was approved by the Ethics Committee of Xiaogan Hospital Affiliated to Wuhan University of Science and Technology. The research involved 72 patients and their tissues, and informed consent for the use of their clinical images and tissues was obtained from the patient.

References

1.Hansell DM, Bankier AA, MacMahon H, McLoud TC, Müller NL, Remy J. Fleischner Society: glossary of terms for thoracic imaging. Radiology 2008;246(03):697–722.

2.Matsuguma H,Mori K,Nakahara R, et al. Characteristics of subsolid pulmonary nodules showing growth during follow-up with CT scanning. Chest 2013;143(02):436–443.

3.Chang B, Hwang JH, Choi YH, et al. Natural history of pure ground glass opacity lung nodules detected by low-dose CT scan. Chest 2013;143(01):172–178.

4.Silva M,Sverzellati N,Manna C, et al. Long-term surveillance of ground-glass nodules: evidence from the MILD trial. J Thorac Oncol 2012;7(10):1541–1546.

5.Kitami A, Sano F, Hayashi S, Suzuki K, Uematsu S, Kamio Y, et al. Correlation between histological invasiveness and the computed tomography value in pure ground-glass nodules. Surg Today. 2016;46:593-8.

6.Lee GD, Park CH, Park HS, Byun MK, Lee IJ, Kim TH, et al. Lung adenocarcinoma invasiveness risk in pure ground-glass opacity lung nodules smaller than 2 cm. Thorac Cardiovasc Surg. 2019;67:321-8.

7.Heidinger BH, Anderson KR, Nemec U, Costa DB, Gangadharan SP, VanderLaan PA, etal. Lung adenocarcinoma manifesting as pure ground-glass nodules: correlating CT size, volume, density, and roundness with histopathologic invasion and size. J Thorac Oncol. 2017;12:1288-98.

8.Nelson DB, Godoy MCB, Benveniste MF, Shewale JB, Spicer JD, Mitchell KG, et al. Clinicoradiographic predictors of aggressive biology in lung cancer with ground glass components. Ann Thorac Surg. 2018;106:235-41.

9.Sun F, Xi J, Zhan C, Yang X, Wang L, Shi Y, et al. Ground glass opacities: imaging, pathology, and gene mutations. J Thorac Cardiovasc Surg. 2018;156:808-13.

10.Antonoff MB. The search for reliable markers of ground glass opacity prognosis: the truth remains largely unknown. J Thorac Cardiovasc Surg. 2018;156:814-5.

11.Rami-Porta R, Bolejack V, Crowley J, Ball D, Kim J, Lyons G, et al. The IASLC lung cancer staging project: proposals for the revisions of the T descriptors in the forthcoming eighth edition of the TNM classification for lung cancer. J Thorac Oncol. 2015;10:990-1003.

12.Lackey A, Donington JS. Surgical management of lung cancer. Semin Intervent Radiol 2013; 30 (2): 133–40.

13.Oh JY, Kwon SY, Yoon HI et al. Clinical significance of a solitary ground-glass opacity (GGO) lesion of the lung detected by chest CT. Lung Cancer 2007; 55 (1): 67–73.

14.Lee SM, Park CM, Goo JM et al. Transient part-solid nodules detected at screening thin-section CT for lung cancer: Comparison with persistent part-solid nodules. Radiology 2010; 255 (1): 242–51.

15.Lee SM, Park CM, Goo JM, Lee HJ, Wi JY, Kang CH. Invasive pulmonary adenocarcinomas versus preinvasive lesions appearing as ground-glass nodules: Differentiation by using CT features. Radiology 2013; 268 (1): 265–73.

16.Eguchi T, Yoshizawa A, Kawakami S et al. Tumor size and computed tomography attenuation of pulmonary pure ground-glass nodules are useful for predicting pathological invasiveness. PLOS One 2014; 9 (5): e97867.

17.Li M, Wang Y, Chen Y, Zhang Z. Identification of preoperative prediction factors of tumor subtypes for patients with solitary ground-glass opacity pulmonary nodules. J Cardiothorac Surg 2018; 13 (1): 9.

18.Moon Y, Park JK, Lee KY, Ahn S, Shin J. Predictive factors for invasive adenocarcinoma in patients with clinical non-invasive or minimally invasive lung cancer. J Thorac Dis 2018; 10 (11): 6010–9.

19.Li Q, Fan L, Cao ET, Li QC, Gu YF, Liu SY. Quantitative CT analysis of pulmonary pure ground-glass nodule predicts histological invasiveness. Eur J Radiol 2017; 89: 67–71.

20.Zhao W, Xu Y, Yang Z et al. Development and validation of a radiomics nomogram for identifying invasiveness of pulmonary adenocarcinomas appearing as subcentimeter ground-glass opacity nodules. Eur J Radiol 2019; 112: 161–8.

21. Eguchi T, Kadota K, Park BJ, et al. The new IASLC-ATS-ERS lung adenocarcinoma classification: what the surgeon should know. Semin Thorac Cardiovasc Surg 2014;26:210-22.

22.Asamura H. Role of limited sublobar resection for early-stage lung cancer: steady progress. J Clin Oncol 2014;32(23):2403–2404.

23.Nakamura K, Saji H, Nakajima R, Okada M, Asamura H, Shibata T, et al. A phase III randomized trial of lobectomy versus limited resection for small-sized peripheral non-small cell lung cancer (JCOG0802/WJOG4607L). Jpn J Clin Oncol. 2010;40:271–4.

24.Aokage K, Saji H, Suzuki K, Mizutani T, Katayama H, Shibata T, et al. A non-randomized confirmatory trial of segmentectomy for clinical T1N0 lung cancer with dominant ground glass opacity based on thin-section computed tomography (JCOG1211). Gen Thorac Cardiovasc Surg. 2017;65:267–72.

25.Sim HJ, Choi SH, Chae EJ, et al. Surgical management of pulmonary adenocarcinoma presenting as a pure ground glass nodule. Eur J Cardiothorac Surg 2014;46:632-6; discussion 636. 26.Yoshida J, Nagai K, Yokose T, et al. Limited resection trial for pulmonary ground-glass opacity nodules: fifty-case experience. J Thorac Cardiovasc Surg 2005;129:991-6

Figures

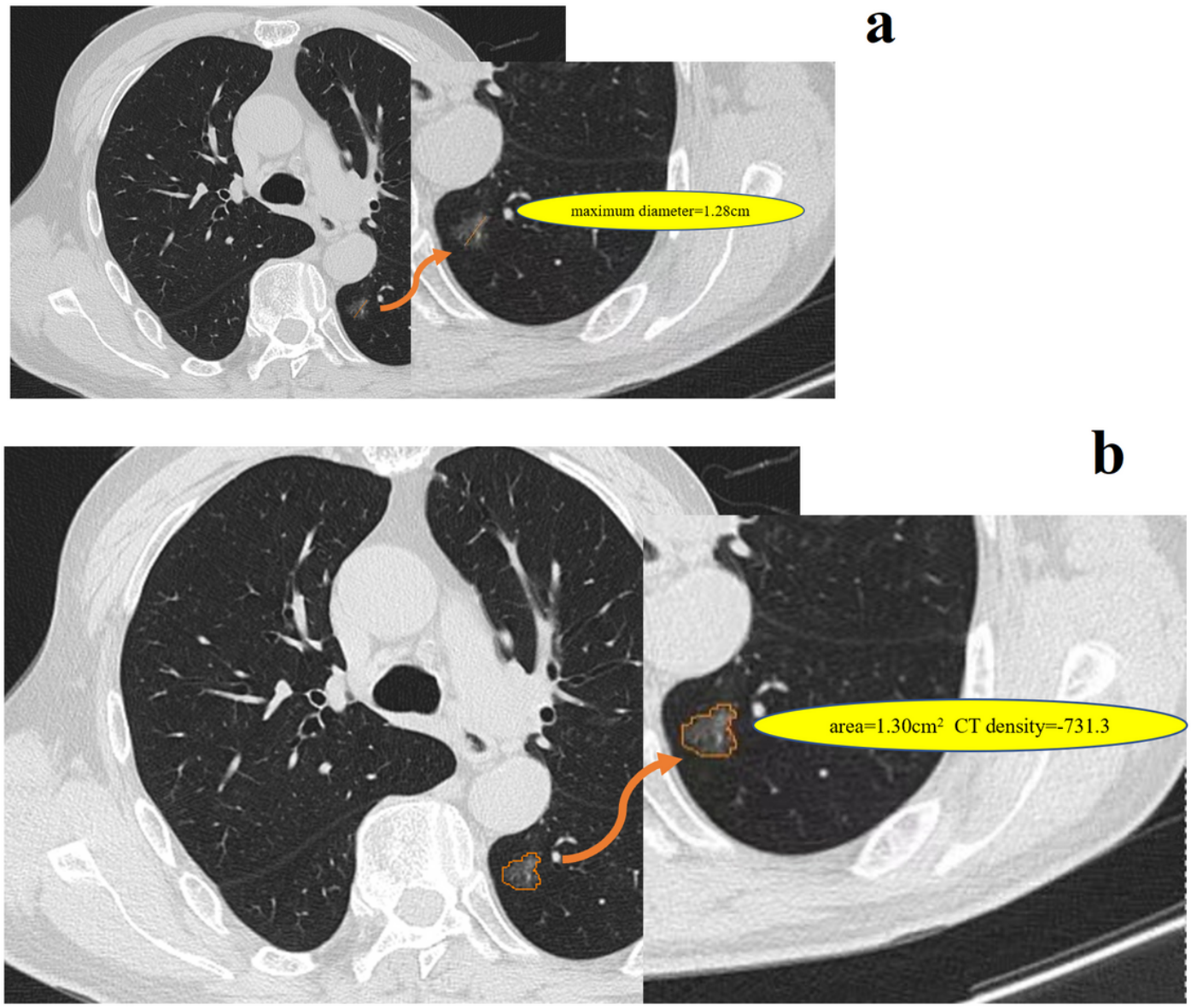

Figure 1

(a)The maximum diameter of pure ground-glass nodule. (b)The area and CT density of pure ground-glass nodule Pure ground-glass nodule diagnosed by chest CT scan. (a) Pure GGO nodule. Maximum diameter 1.28 cm. (b) Pure GGO nodule. Area 1.30cm2 and CT density -731.3HU.

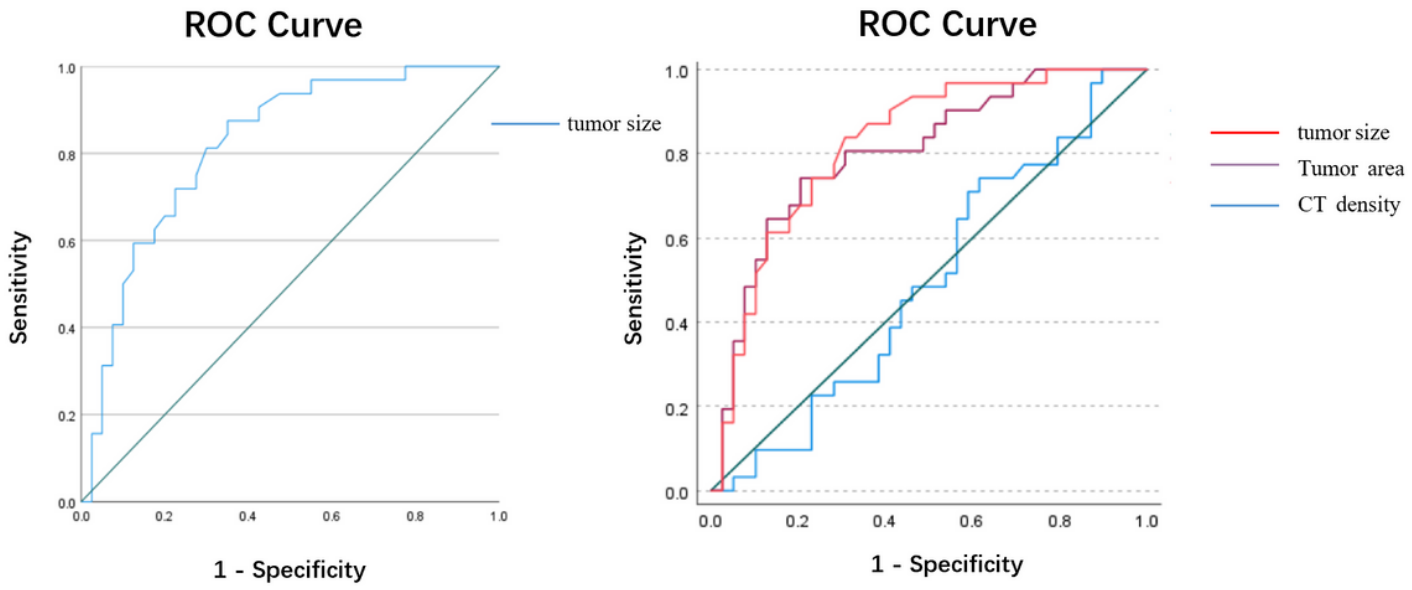

Figure 2

Receiver operating characteristic curve of tumor size in differentiating Invasive lesions from pre-invasion lesion in patients with pGGNs. The area under the curve was 0.823 (95% CI, 0.724-0.921). The optimal cutoff for size was 1.08 cm according to the Youden Index. ROC, Receiver operating characteristic.