Efficacy of the erector spinae plane block in lumbar spinal surgery patients: a systematic review

Yong Qiu
Beijing Hospital, National center of Gerontology
Teng-jiao Zhang
Beijing Hospital
Ling-bing Meng
Beijing Hospital
Zhen Hua (huazhenbj528@163.com)
Beijing hospital https://orcid.org/0000-0003-0854-9981

Research article

Keywords: ESPB, Lumbar spine surgery, Postoperative analgesia, Systematic review

Posted Date: December 16th, 2019

DOI: https://doi.org/10.21203/rs.2.18749/v1

Abstract

Background: Erector spinae palne block (ESPB) as a new trunk fascia block technique was proposed in 2016. Because of its clear analgesic effect and simple operation, it has aroused the interest of many nerve block experts. However, there are few clinical studies on ESPB for lumbar surgery, and its benefits are controversial. The goal of this review paper is to summarize the use of ESPB for lumbar spine surgery in order to better understand and promote this technique.

Methods: Pubmed, EMBASE, Cochrane library, ClinicalTrial.gov databases were searched up to July 30, 2019. According to the inclusion and exclusion criteria established in advance, “lumbar spine surgery” and “ESPB” related MesH terms, free-text words were used. Data on pain scores, analgesic consumptions and adverse effects were reported. All processes follow PRISMA statement guidelines.

Results: A total of 171 participants from 11 publications were identified, including two randomized controlled trials, one retrospective cohort study, four case report, four cases series. Block operation plane from T8 to L4. The main anesthetics used in block are bupivacaine, ropivacaine and lidocaine. There was evidence for reducing postoperative pain scores and analgesic consumptions.

Conclusion: ESPB in lumbar spine surgery have the potential to relieve lumbar postoperative pain and reduce the use of analgesic drugs. Randomized controlled trials of high quality and large samples are needed to further clarify the benefits of ESPB in lumbar surgery patients.

Background

Postoperative pain is often severe in patients undergoing lumbar surgery. Due to postoperative pain, patients are unwilling to get out of bed at an early stage, which affects their recovery[1, 2]. Patient-controlled analgesia or epidural injection analgesia is usually used in clinic. However, patient-controlled analgesia is prone to opioid-related side effects. Epidural injection is associated with infections, hematomas and other adverse events[3, 4]. Furthermore, the analgesic effect of conventional postoperative analgesia is limited. If the postoperative pain of the lumbar spine could not be effectively relieved, it may develop into chronic pain, affecting the quality of life of the patients[5].

Erector spinae plane block as a new trunk fascia block technique was proposed in 2016[6]. Due to its clear analgesic effect and simple process, it has aroused the interest of many nerve block experts. As the diffusion of the drug solution, ESPB can effectively block the posterior root of the spinal nerve and produce part of the paraspinal block effect at the same time[7, 8]. Many scholars have applied ESPB to postoperative analgesia in chest and abdomen. Furthermore, they found that ESPB could reduce peri-operative muscle relaxation and analgesic drug use. Finneran reported that ESPB can provide analgesia for breast surgery[9]. A study reported that ESPB was effective for abdominal analgesia in weight loss surgery[10]. Similarly, one study reported that ESPB relieved postoperative pain in patients with lumbosacral spine surgery, reduced the use of analgesic drugs, and promoted postoperative rehabilitation[11]. Furthermore, a recent study showed that the analgesic effect of ESPB may be better than that of epidural injection[12]. Reducing the use of analgesic drugs in perioperative period is beneficial to accelerate the recovery of patients and reduce the cost of hospitalization.

However, few clinical studies have focused on ESPB in lumbar surgery. What is more, there are differences in the mechanism and effect of block in different parts of erector spinal muscle[13]. Furthermore, some scholars question the practicability of ESPB in lumbar surgery. Tseng believes that postoperative analgesia in patients with lumbar spine surgery using thoracolumbar interfascial plane (TILP) block may better than ESPB[14]. Therefore, it is necessary to systematically summarize the use of ESPB in lumbar spine surgery so as to better understand and promote this technique and benefit patients undergoing lumbar surgery.

Methods

Literature search

Pubmed, EMBASE, Cochrane library, ClinicalTrial.gov databases were searched. MeSH terms and free-text words were used, including “lumbar spine surgery”, “decompression”, “lumbar spinal stenosis”, “spondylolisthesis”, “ESP block”, “erector spinae plane block”. Search time up to July 30, 2019. References to relevant articles or reviews were screened to prevent missed inspection. Our retrieval method was developed together with experienced literature retrieval teachers. All the retrieval results were read independently by the two researchers (QY, ZTJ). According to the established inclusion and exclusion criteria, the title, abstract and full text were strictly evaluated, and the basic information included in the article was extracted. Disagreements would be resolved by discussing or consulting with another author. All processes followed PRISMA statement guidelines.

Inclusion and exclusion criteria:

Inclusion criteria. (1) Study: Case report, case series, retrospective corhort study, and RCTs; (2) Participants: lumbar spine surgery patients; (3) Interventions: erector spinae plane block.

Exclusion criteria. (1) Review; (2) Participants: puncture point infection, abnormal blood coagulation, local anesthetic allergy, severe cardiopulmonary disease.

Data collection:

Type of publication, year of publication, journal name, authorship country of origin, type of block (single shot, continuous, intermittent bolus), anatomic location, patient age, multimodal analgesia use, opioid consumption, sensory and motor changes, reported single shot dosing, additives, opioid related and block related side effects and adverse events, VAS or NRS pain scores, patient satisfaction were collected.

Quality evaluation:

Risk of bias for RCTs (Randomized controlled trials) were assessed by two researchers using a modified Cochrane risk of bias assessment tool. RCTs were evaluated in terms of random sequence generation; allocation concealment; blinding of patients, clinicians, data collectors, outcome assessors, and data analysts; incomplete outcome data; and selective outcome reporting; other biases. Each potential source of bias was graded as "low risk", "unclear risk" or "high risk". Bias risk map and bias risk summary diagram were generated by RevMan 5.3 (The Cochrane Collaboration, 2014).

Results

Search results:

A total of 171 participants from 11 publications were identified, including two randomized controlled trials, one retrospective cohort study, four case report, four cases series[11, 15-23]. The main reasons for the exclusion of the articles were non-lumbar surgery or unrelated to the purpose of the study.Figure 1

Included literature:

Outcome indicators included morphine consumptions, pain scores, adverse reactions and patient satisfaction after lumbar spine surgery. The follow-up period was from 10 hours to 72 hours. Only one article reported that postoperative pain in the lumbar spine was relieved by ESPB and catheterization, and the other 10 articles were treated with bilateral single injection before operation. Block operation plane from T8 to L4. The main anesthetics used in block are bupivacaine, ropivacaine and lidocaine. What is more, almost all of the included studies showed that ESPB could effectively relieve lumbar postoperative pain and reduce the use of analgesic drugs. (Table 1)

At the same time, a total of two RCTs were included, but the heterogeneity of outcome indicators could not be analyzed by meta-analysis. Both RCT found that ESPB significantly reduced lumbar postoperative pain scores and analgesic drug consumptions, and no operation-related adverse events occurred. However, the random blind method of the two studies did not do well. Furthermore, small RCTs may not be able to detect adverse effects of therapeutic procedures. (Figure 2A, 2B)

Discussion

There is an increase in the number of patients with lumbar diseases, and a large number of them need lumbar surgery[3]. As the obvious pain after lumbar surgery, postoperative analgesia is often needed. However, patient-controlled intravenous analgesia and epidural analgesia, which are commonly used in clinic, have their own shortcomings[4, 24]. Side effects such as nausea and vomiting caused by postoperative opioid use result in poor postoperative experience, reduce patient satisfaction, and are not conducive to rapid recovery[25]. In recent years, many researchers have used ESPB for postoperative analgesia and found that the analgesic effect is good[10]. The local anesthetics injected during ESPB spread widely and could produce the effect of paraspinal block, therefore, the block range was wide and could last until a period of time after operation. Furthermore, ESPB can reduce the stimulation of operation, reduce the soft tissue injury caused by pulling muscle during operation, and then effectively reduce the use of perioperative analgesia and anesthetics[14, 26, 27]. However, there are few studies on ESPB for postoperative analgesia of lumbar spinae surgery patients[28]. Therefore, it is necessary to summarize the relevant clinical studies. Eleven studies of ESPB for lumbar surgery were included, and data from 171 patients were extracted and analyzed. Interestingly, all included studies have shown that ESPB can reduce postoperative opioid consumptions and pain scores in patients undergoing lumbar surgery. Furthermore, ESPB could improve patient satisfaction and reduce the side effects caused by opioid use without block-related side effects. ESPB can effectively relieve postoperative pain, reduce opioid consumption and improve patient satisfaction, in line with ERAS (enhanced recovery after surgery).

It has been reported that pain is obvious at 4 hours after lumbar surgery and relieved after 72 hours. What is more, regional block anesthesia can help patients reduce pain and other discomfort[18, 29]. Interestingly, Singh found that when 0.25% 20ml bupivacaine was injected on both sides of the T10 plane, the 6th hour NRS score was low, however the 8th hour NRS score was high after lumbar surgery, which suggested that the ESPB could last until 6 to 8 h after operation[30]. The duration of ESPB block was related to the type and dose of local anesthetics. However, the safe doses of different local anesthetics were different. For example, the unilateral injection volume of ropivacaine was 20 to 40ml, the concentration was 0.25% to 0.5%, and the total safe dose was 150mg. It is recommended that each side of bilateral block should be given 0.375% ropivacaine 20ml in adults[15, 31]. Therefore, the dose or concentration can be increased appropriately to prolong the analgesia time and help the patients to get through the most painful stage after operation.

The puncture plane was from T8 to L4, and the follow-up time was from 10 h to 72 h. However, in different studies, patients have different basic analgesia programs, and some researchers pay attention to the use of rescue painkillers, while some studies focus on the total amount of postoperative analgesia drugs[14, 32]. Furthermore, Different basic analgesia regimens may cause differences in pain scores. As a result, there is great heterogeneity among different studies, and the results can not be quantitatively synthesized and analyzed. At the same time, it is suggested that we should pay more attention to the primary outcome indicators in the design of clinical trials in the future. The recently reported protocol of ESPB for postoperative analgesia of lumbar surgery is worthy of reference[14]. At the same time, it is important to note that little attention has been paid to the effects of ESPB on the use of intraoperative analgesic drugs and muscle relaxants. Only one case report mentioned that erector muscle block could effectively reduce the use of analgesia and muscle relaxant drugs during the perioperative period of spondylolisthesis correction surgery, and appropriate hypotension was beneficial to surgical visual field exposure and operation[33]. Reducing the use of perioperative anesthetics can not only reduce the cost of hospitalization, but also reduce the possible side effects of extensive use of anesthetics. At present, some scholars believe that perioperative use of opioids can affect the immune function of patients, and may be associated with the poor prognosis of tumor patients. At the same time, reducing the use of perioperative opioids may reduce the risk of tumor recurrence[34, 35]. From this point of view, it seems that the effect of ESPB on intraoperative opioid dosage is also worthy of attention. On the other hand, the included studies did not seem to pay particular attention to the effect of ESPB on early out-of-bed activity and postoperative hospital stay in patients with lumbar spine

surgery. Early out of bed activity and early discharge from hospital comply with ERAS, which is also the reason for the promotion of ESPB in patients undergoing lumbar surgery. At the same time, no adverse events related to ESPB were found in all the 11 studies, suggesting that ESPB was safe.

Recently, Turbitt and other experts have proposed that nerve block technology should not be limited to nerve block experts, but should be mastered as a basic technique by general anesthesiologists in order to be more widely used in clinic and benefit patients[35]. However, due to the differences in clinical conditions in different areas, the clinical coverage of regional nerve block is still limited. Therefore, we should better proceed from the clinical practice, so that more anesthesiologists to master simple and practical cost-effective regional block technology. Because of its simple operation and low risk of infection, bleeding and spinal cord injury caused by puncture, ESPB should also be used as a basic operation technique for anesthesiologists. Although ESPB has been widely used in thoracic and abdominal surgery, the use of ESPB in lumbar surgery is still controversial[36]. Some researchers believe that TILP block is better than ESPB in patients undergoing lumbar surgery[13]. However, ESPB has the advantages of simple operation and less complications, and is more in line with the idea advocated by Turbitt and other experts to let general anesthesiologists master nerve block techniques and apply them. We believe that the clinical research quality of ESPB for lumbar surgery should be improved, and the mechanism of erector muscle block for postoperative analgesia and perioperative protection of lumbar spine should be further explored. At the same time, more general anesthesiologists are needed to master ESPB and apply it to patients undergoing lumbar surgery for the benefit of more patients.

Limitation

Although we have strictly formulated the scheme of literature retrieval and data extraction, there are few research reports that can be included. Only 2 RCT articles were included, howerver the outcome could not be analyzed. Furthermore, the sample size of the two articles is small, and the random, blind method and research quality need to be improved. We need more large sample size, high quality clinical trials to explore the benefits of ESPB for lumbar surgery patients.

Conclusions

ESPB is a good choice for postoperative analgesia in patients undergoing lumbar surgery. However, its safety and effectiveness need more evidence. In addition, the perioperative benefits of ESPB for patients undergoing lumbar surgery need to be further explored.

Declarations

Ethics approval and consent to participate

Not applicable.

Consent to publication

Not applicable.

Availability of data and materials

The data used and/or analyzed during the current study are available from the public database GEO or the corresponding author on reasonable request.

Competing interests

The authors declare that they have no competing interests.

Funding

Not applicable

Author contributions

YQ performed the retriveal and was major contributor in writing the manuscript and submitting the manuscript. ZH made substantial contribution to research conception. He also designed the draft of the research process. LBM and TJZ had been involved in revising manuscript critically for important intellectual content. All authors read and approved the final manuscript.

Acknowledgements

We are thankful to Meng-lei Hao for her statistical assistance and suggestions during the submitting process.

Abbreviations

Erector spinae palne block (ESPB); Thoracolumbar interfascial plane (TILP); Randomized controlled trials (RCTs); Enhanced recovery after surgery (ERAS).

References

1. Saleh A, Thirukumaran C, Mesfin A, Molinari RW: **Complications and readmission after lumbar spine surgery in elderly patients: an analysis of 2,320 patients**. *Spine J* 2017, **17**:1106-1112.

2. Lin I, AUID- Oho, Wiles L, Waller R, Goucke R, Nagree Y, Gibberd M, Straker L, AUID- Oho, Maher CG, PPB O: **What does best practice care for musculoskeletal pain look like? Eleven consistent recommendations from high-quality clinical practice guidelines: systematic review**. *Br J Sports Med* 2019 .
3. Naik BI, Nemergut EC, Kazemi A, Fernandez L, Cederholm SK, McMurry TL, Durieux ME: **The Effect of Dexmedetomidine on Postoperative Opioid Consumption and Pain After Major Spine Surgery**. *Anesth Analg* 2016, **122**:1646-1653.
4. Gessler F, Mutlak H, Tizi K, Senft C, Setzer M, Seifert V, Weise L: **Postoperative patient-controlled epidural analgesia in patients with spondylodiscitis and posterior spinal fusion surgery**. *J Neurosurg Spine* 2016, **24**:965-970.
5. Hamilton DL, Manickam B: **Erector spinae plane block for pain relief in rib fractures**. *Br J Anaesth* 2017, **118**:474-475.
6. Forero M, Adhikary SD, Lopez H, Tsui C, Chin KJ: **The Erector Spinae Plane Block: A Novel Analgesic Technique in Thoracic Neuropathic Pain**. *Reg Anesth Pain Med* 2016, **41**:621-627.
7. Elsharkawy H, Pawa A, Mariano ER: **Interfascial Plane Blocks: Back to Basics**. *Reg Anesth Pain Med* 2018, **43**:341-346.
8. Hamilton DL, Manickam BP: **Is the erector spinae plane (ESP) block a sheath block**. *Anaesthesia* 2017, **72**:915-916.
9. Finneran JJ 4th, Gabriel RA, Khatibi B: **Erector Spinae Plane Blocks Provide Analgesia for Breast and Axillary Surgery: A Series of 3 Cases**. *Reg Anesth Pain Med* 2018, **43**:101-102.
10. Chin KJ, Malhas L, Perlas A: **The Erector Spinae Plane Block Provides Visceral Abdominal Analgesia in Bariatric Surgery: A Report of 3 Cases**. *Reg Anesth Pain Med* 2017, **42**:372-376.
11. Melvin JP, Schrot RJ, Chu GM, Chin KJ, 0000-0002-8339-3764 AO: **Low thoracic erector spinae plane block for perioperative analgesia in lumbosacral spine surgery: a case series**. *Can J Anaesth* 2018, **65**:1057-1065.
12. Celik M, Tulgar S, Ahiskalioglu A, AUID- Oho, Alper F: **Is high volume lumbar erector spinae plane block an alternative to transforaminal epidural injection? Evaluation with MRI**. *Reg Anesth Pain Med* 2019 .
13. Tseng V, Xu JL: **Erector Spinae Plane Block For Postoperative Analgesia in Lumbar Spine Surgery: Is There a Better Option**. *J Neurosurg Anesthesiol* 2019 .
14. Canturk M: **Ultrasound-guided bilateral lumbar erector spinae plane block for postoperative analgesia after spondylolisthesis correction surgery**. *J Clin Anesth* 2019, **57**:77-78.
15. De Lara Gonzalez S, Basora MM, Tio M, Martinez-Camacho A, Fuster S, Sala-Blanch X: **L4 erector spinal plane block after lumbar spine arthrodesi: A case-series**. *Rev Esp Anestesiol Reanim* 2019 .
16. Singh S, Chaudhary NK: **Bilateral Ultasound Guided Erector Spinae Plane Block for Postoperative Pain Management in Lumbar Spine Surgery: A Case Series**. *J Neurosurg Anesthesiol* 2019, **31**:354.
17. Almeida CR, AUID- Oho, Oliveira AR, Cunha P: **Continuous Bilateral Erector of Spine Plane Block at T8 for Extensive Lumbar Spine Fusion Surgery: Case Report**. *Pain Pract* 2019, **19**:536-540.
18. Singh S, Choudhary NK, Lalin D, Verma VK: **Bilateral Ultrasound-guided Erector Spinae Plane Block for Postoperative Analgesia in Lumbar Spine Surgery: A Randomized Control Trial**. *J Neurosurg Anesthesiol* 2019 .
19. Ueshima H, Inagaki M, Toyone T, Otake H: **Efficacy of the Erector Spinae Plane Block for Lumbar Spinal Surgery: A Retrospective Study**. *Asian Spine J* 2019, **13**:254-257.
20. Yayik AM, Cesur S, Ozturk F, Ahiskalioglu A, Ay AN, Celik EC, Karaavci NC: **Postoperative Analgesic Efficacy of the Ultrasound-Guided Erector Spinae Plane Block in Patients Undergoing Lumbar Spinal Decompression Surgery: A Randomized Controlled Study**. *World Neurosurg* 2019 .
21. Brandao J, Graca R, Sa M, Cardoso JM, Caramelo S, Correia C: **Lumbar erector spinae plane block: Successful control of acute pain after lumbar spine surgery - A clinical report**. *Rev Esp Anestesiol Reanim* 2019, **66**:167-171.
22. Calandese F, Adduci A: **Erector spinae plane block for acute postoperative pain management after anterior thoracolumbar spine surgery**. *J Clin Anesth* 2019, **52**:55-56.
23. Waldrop R, Cheng J, Devin C, McGirt M, Fehlings M, Berven S: **The Burden of Spinal Disorders in the Elderly**. *Neurosurgery* 2015, **77 Suppl 4**:S46-50.
24. Graffigna G, Barello S: **Patient Health Engagement (PHE) model in enhanced recovery after surgery (ERAS): monitoring patients' engagement and psychological resilience in minimally invasive thoracic surgery**. *J Thorac Dis* 2018, **10**:S517-517S528.
25. De Cassai A, Bonvicini D, Correale C, Sandei L, Tulgar S, Tonetti T: **Erector spinae plane block: a systematic qualitative review**. *Minerva Anestesiol* 2019, **85**:308-319.
26. Gurkan Y, Aksu C, Kus A, Yorukoglu UH: **Erector spinae plane block and thoracic paravertebral block for breast surgery compared to IV-morphine: A randomized controlled trial**. *J Clin Anesth* 2019, **59**:84-88.
27. BCH T, Fonseca A, Munshey F, McFadyen G, Caruso TJ: **The erector spinae plane (ESP) block: A pooled review of 242 cases**. *J Clin Anesth* 2019, **53**:29-34.
28. Bianconi M, Ferraro L, Ricci R, Zanoli G, Antonelli T, Giulia B, Guberti A, Massari L: **The pharmacokinetics and efficacy of ropivacaine continuous wound instillation after spine fusion surgery**. *Anesth Analg* 2004, **98**:166-172, table of contents.
29. Andreae MH, Andreae DA: **Regional anaesthesia to prevent chronic pain after surgery: a Cochrane systematic review and meta-analysis**. *Br J Anaesth* 2013, **111**:711-720.
30. Tulgar S, Yildirim A, Karaoglan A, Ozer Z: **Erector spinae plane block as the main anesthetic method for peri-paravertebral area surgical procedure**. *J Clin Anesth* 2019, **54**:157.
31. Fiorelli S, Leopizzi G, Saltelli G, Andreetti C, Fiorelli A, Peritore V, Rocco M, Massullo D: **Bilateral ultrasound-guided erector spinae plane block for postoperative pain management in surgical repair of pectus excavatum via Ravitch technique**. *J Clin Anesth* 2019, **56**:28-29.

32. Breebaart MB, AUID- Oho, Van Aken D, De Fre O, Sermeus L, Kamerling N, de Jong L, Michielsen J, Roelant E, Saldien V, Versyck B: **A prospective randomized double-blind trial of the efficacy of a bilateral lumbar erector spinae block on the 24h morphine consumption after posterior lumbar inter-body fusion surgery**. *Trials* 2019, **20**:441.
33. Eisenstein TK: **Opioids and the immune system: what is their mechanism of action**. *Br J Pharmacol* 2011, **164**:1826-1828.
34. Cronin-Fenton DP, Heide-Jorgensen U, Ahern TP, Lash TL, Christiansen PM, Ejlertsen B, Sjogren P, Kehlet H, Sorensen HT: **Opioids and breast cancer recurrence: A Danish population-based cohort study**. *Cancer* 2015, **121**:3507-3514.
35. Turbitt LR, Mariano ER, El-Boghdadly K: **Future directions in regional anaesthesia: not just for the cognoscenti**. *Anaesthesia* 2019 .
36. Murouchi T: **Consideration of Block Nomenclature: Erector Spinae Plane Block or Retrolaminar Block**. *Reg Anesth Pain Med* 2017, **42**:124.

Table

Table 1: Qualitative evaluation of the studies that assessed the postoperative analgesia of ESPB on lumbar spine surgery.

Author	Country	Study design	Study size	Surgical operation	ESPB	Outcome	Side effect	Follow-up time	Conclusion
Canturk et al. (2019)	Turkey	Case report	1	Lumbar spinal fusion	L1 vertebra level, both sides with 10ml bupivacaine 0.25% and 10ml prilocaine 1%, single-shot.	Opioid consumption, NRS pain scores.	None	24 hours	ESPB provides a clear surgical field and long-lasting postoperative analgesia.
De et al. (2019)	Spain	Case series	8	Lumbar spinal fusion	L4 vertebra level, both sides with 20ml ropivacaine 0.2%, single-shot.	VAS pain scores, rescue analgesia consumption.	None	48 hours	Lumbar ESP appears to contribute to pain control during the fist 48 hours after lumbar spinal fusion.
Singh et al. (2019)	India	Case series	7	Surgery for PLID or lumbar stenosis	T10 vertebra level, both sides with 20ml bupivacaine 0.25%, single-shot.	NRS score, rescue analgesia.	None	10 hours	The average length of analgesia provided by ESPB was between 6 and 8 hours.
Almeida et al. (2019)	Portugal	Case report	1	L2-S1 spine fusion	Post-operative day 1, T8 vertebra level, both sides with 20ml ropivacaine 0.2%, ESP catheterizations and continuous infusion (5 mL/hour) of ropivacaine 0.2% per side was maintained for 48 hours.	NRS scores	None	48 hours	Bilateral ESP catheterizations at T8 is safe and contribute to significant analgesic improvement.
Singh et al. (2019)	India	RCT	40	Elective lumbar spine surgery	T10 vertebra level, both sides with 20ml bupivacaine 0.5%, single-shot.	Opioid consumption, NRS scores, patient satisfaction.	Two patients in the control group developed severe nausea and vomiting.	24 hours	US-guided ESP block reduces postoperative opioid requirement and improves patient satisfaction.
Ueshima et al. (2019)	Japan	Retrospective study	41	Lumbar spinal surgery	Target vertebral level, both sides with 20mL levobupivacaine0.375%.	NRS scores, analgesia consumption, complications.	None	24 hours	The ESP block provides effective postoperative analgesic effect for 24 hours.
Yayik et al. (2019)	Turkey	RCT	60	Open lumbar decompression	L3 vertebra level, both sides with 20ml bupivacaine 0.25%, single-shot.	VAS scores, opioid consumption, rescue analgesia, opioid-related side effects.	None	24 hours	ESP block can be used in multimodal analgesia practice to reduce opioid consumption and relieve acute postoperative pain.
Brandao et al. (2018)	Portugal	Clinical report	1	Lumbar spine surgery	L4 vertebra level, both sides with 15ml ropivacaine 0.375%, single-shot.	Pain scores, analgesia consumption.	None	48 hours	Performing the block preoperatively dismissed the need for extra intraoperative opioids other than those for intubation and provide a clear surgical field.
Calandese et al. (2018)	Italy	Case report	1	Anterior thoracolumbar spine surgery	T10 vertebra level, a total of 40mL of 0.25% levobupivacaine and 2mL (8mg) of dexamethasone was injected bilaterally.	NRS scores, analgesia consumption.	None	24 hours	ESPB as part of a multimodal analgesia strategy, can provide effective postoperative pain management after anterior thoracolumbar spine surgery.
Cesur et al. (2018)	Turkey	Case series	5	Lumbar surgery	T12 vertebra level, both sides with 20ml local anesthetic solution	NRS scores, analgesia consumption.	None	24 hours	ESPB achieved effective analgesia and

					containing bupivacaine 0.25% and lidocaine 1%, single-shot.				reduced opioid consumption in the single or multilevel lumbar spine surgeries.
Melvin et al. (2018)	USA	Case series	6	Lumbosacral spine surgery	T10 (n=2) and T12 (n=4), which concluded 3 single-injection and 3 continuous ESPB.	NRS scores, analgesia use.	None	72 hours	The ESP block contribute significantly to analgesia and enhance recovery.

ESPB: Erector spinae plane block; ESP: Erector spinae plane; NRS: Numeric rating scales; VAS: Visual analogue scales; PLID: Prolapsed lumbar intervertebral disk; RCT: Random controlled trial.

Figures

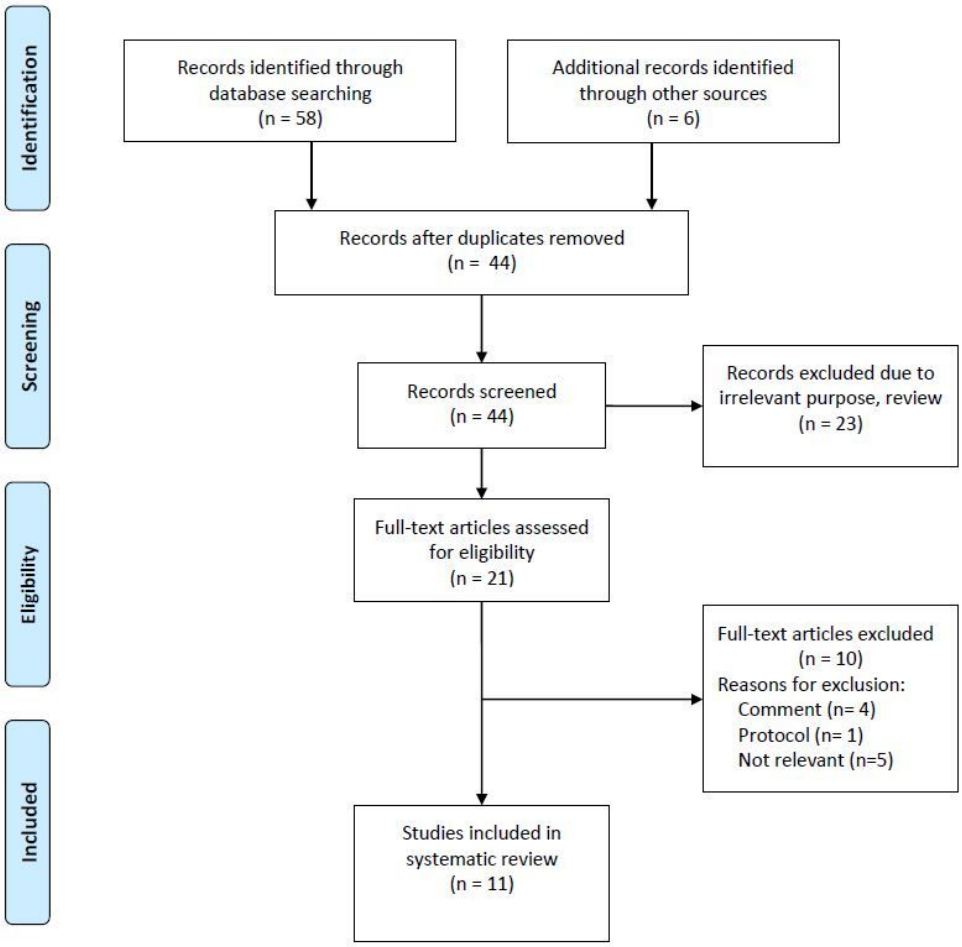

Figure 1

Flow chart showing the identification and selection of the articles for the systematic review.

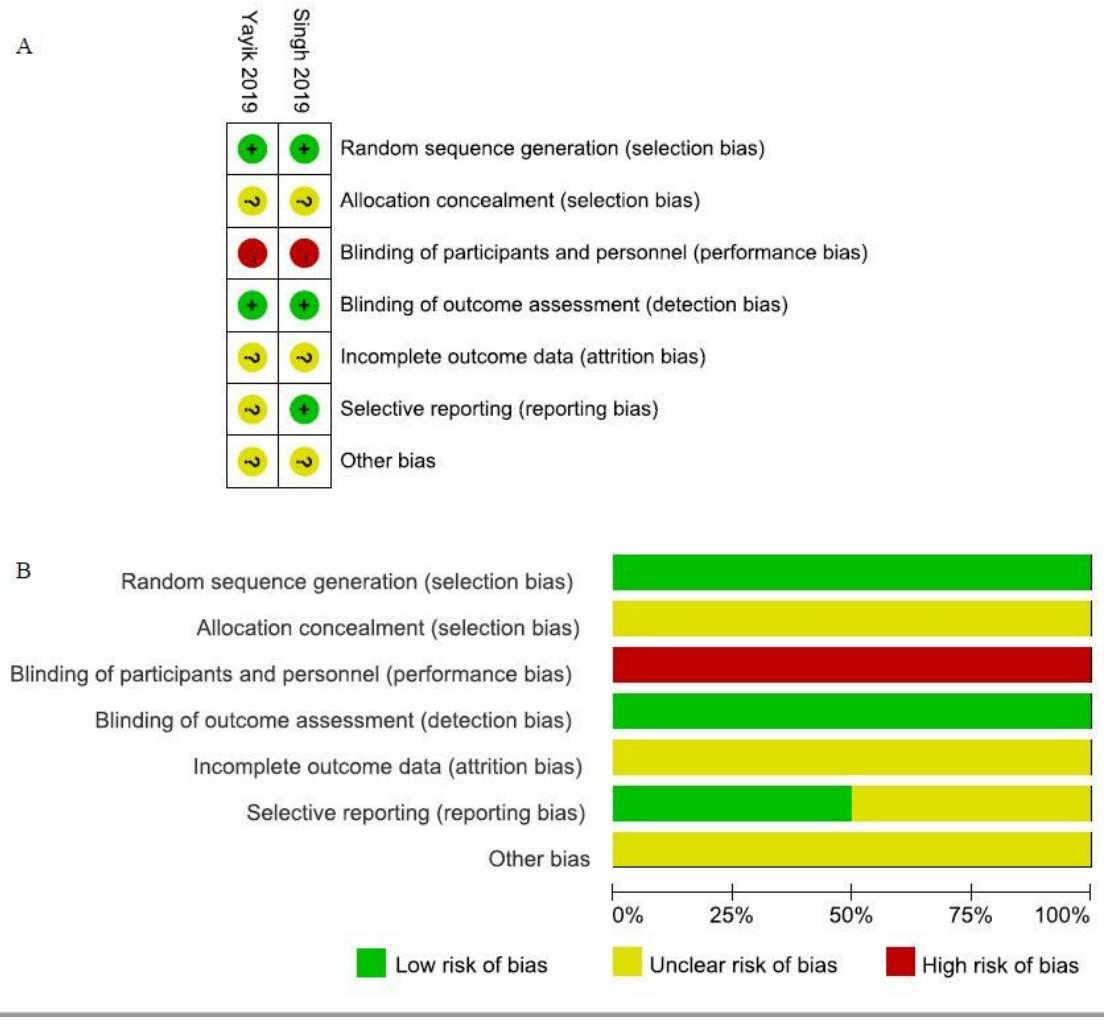

Figure 2

2A: Risk of bias summary: Green circles with “+” sign indicate low risk, yellow circles with “?” sign indicate unclear risk, red circles with “-” sign indicate high risk. 2B: Risk of bias graph: review authors’ judgements about each risk of bias item presented as percentages across all included studies.

Supplementary Files

This is a list of supplementary files associated with this preprint. Click to download.

- PRISMAchecklist.doc