Biceps Tenodesis Combined With Rotator Cuff Repair Increases Functional Status And Elbow Strength In Both Operated And Contralateral Arms

Ali Ihsan KILIC (ali.ihsan.88@gmail.com)
Siirt State Hospital https://orcid.org/0000-0001-7491-6044

Onur HAPA
Dokuz Eylul Universitesi Tip Fakultesi

Ramadan OZMANEVRA
University of Kyrenia: Girne Universitesi

Nihat Demirhan DEMIRKIRAN
Kütahya University of Health Sciences: Kutahya Saglik Bilimleri Universitesi

Onur GURSAN
Dokuz Eylul University Faculty of Medicine: Dokuz Eylul Universitesi Tip Fakultesi

Research article

Keywords: Rotator cuff tear, Biceps, Tenodesis, Supination, Strength, Arthroscopic surgery

Posted Date: October 21st, 2020

DOI: https://doi.org/10.21203/rs.3.rs-94002/v1

Abstract

Purpose: Aim of the present study was to prospectively evaluate the elbow flexion and supination strengths, and the functional outcomes of patients after arthroscopic rotator cuff repair combined with simultaneous biceps tenodesis.

Methods: Nineteen patients who underwent arthroscopic rotator cuff repair and biceps tenodesis with at least 24 months follow-up were included. Patients were evaluated using a visual analogue scale (VAS) for bicipital groove pain, American Shoulder and Elbow Surgeons (ASES), and constant scores(CS), biceps apex distance (BAD), elbow flexion and supination strengths.

Results: VAS for biceps groove measurement averages of postoperative 6th, 12th and 24th month were lower in comparison to pre-operative data and were considered to be statistically significant ($p<0.05$). Constant score, an average of all post-operative measurements and scores were found higher than pre-operative values and was considered to be statistically significant ($p<0,01$). There was a significant difference in the comparison of operated and contralateral forearm supination and elbow flexion muscle strength measurements at postoperative 3rd and 6th-month follow-up ($p<0.01$).

Conclusion: Arthroscopic biceps tenodesis into the anchors of lateral row combined rotator cuff repair provides an increase in strength of elbow flexion and forearm supination, while decreases pain.

Level of Evidence: Level IV

Introduction

Rotator cuff tears are associated with a long head of biceps pathology (LHBT) in %30–69 ofthe cases [1, 2]. Lesions of LHBT can cause pain with the following reasons: associated lesions in labral complex, tendinopathy or tenosynovitis, partial or complete tendon tears, and instability in LHBT like subluxation, dislocation, and pulley effect [3–6].

The preferred treatment is usually tenotomy or tenodesis for relieving pain associated with biceps pathologies [7]. Tenotomy is an easy, time-saving procedure thatreduces pain effectively [8, 9] and preserves the strength and tension of the muscle. Therefore, tenodesis is preferred for younger patients and heavy laborers [10, 11].

Arthroscopic suprapectoral biceps tenodesis has distinct advantages including minimal soft tissue dissection, less scar formation, lack of need of an assistant for soft tissue retraction compared to open subpectoral biceps tenodesis [12]. When tenodesis is performed, many different factors affect tendon repair including tendon quality and strength of the stitch. The most vulnerable part of the suture is the start of the chain, where the suture is passed. For improving strength, Laffoseet al. introduced a new technique named Lasso stitch in 2006 [13], which showed superior biomechanical properties against load to failure compared to compressive rivet and interference screw [14]. Some authors also stated that the Lasso loop technique has less humeral fracture risk theoretically associated with drilling than interference screw [12].

Tenodesis seems to be associated with higher forearm supination and elbow flexion strength compared to tenotomy [15–18]. Little is known regarding elbow strength compared to preoperative levels when two common procedures; biceps tenodesis and rotator cuff repair, are performed simultaneously. Hufeland et al [19] reported that isolated arthroscopic suprapectoral biceps tenodesis using the interference screw increased elbow flexion from 12 months onwards compared to preoperative values, but they did not consider the supination strength.

Although biomechanical properties of Lasso stitch were investigated in some studies, there are limited studies investigating functional outcomes. Uschok et al. [18] investigated functional outcomes of the shoulder and elbow

strength compared to contralateral elbow and stated that there may be loss of elbow flexion strength which is not clinically significant. Elbow supination strength was not investigated in this study [18]. Moorthy et al. aimed to review the literature and suggest if tenotomy or tenodesis is the preferred option in patients who undergo rotator cuff repair. They conclude that there is a lack of higher-level studies to make a decision for a worldwide-accepted algorithm.

The purpose of our study is to prospectively evaluate the elbow flexion and supination strengths, and the functional outcomes of patients after arthroscopic rotator cuff repair combined with simultaneous biceps tenodesis. We hypothesized that rotator cuff repair combined with biceps tenodesis, similar to the technique described by Levy JC [20], would increase both flexion and supination strengths of the elbow compared to preoperative levels at an early period.

Materials And Methods

The present study is a prospective case series of a single surgeon's (O.H.) practice and all data of included patients have been collected prospectively and reviewed retrospectively. We reviewed patients who underwent arthroscopic proximal biceps tenodesis and arthroscopic rotator cuff repair between January 2015 to December 2017. Twenty-two patients with full-thickness rotator cuff tears and biceps tendinosis depending on physical examination, intraoperative and MRI findings, and who did not respond to physical therapy were included and followed.

All patients underwent a preoperative assessment, including comprehensive physical tests specific to rotator cuff lesions (Jobe test, rent sign, Hawkins test, external/internal lag sign, etc.), biceps lesions (Speed test, Yergason test, tenderness, etc.), as well as radiographic examinations using MRI. We evaluated the patients preoperatively in terms of arm dominance, trauma history, bicipital groove tenderness, visual analog scale (VAS) for pain, functional shoulder score (American Shoulder and Elbow Surgeons [ASES] score) and elbow-forearm muscle strength measurements (both operated and contralateral sides).

The rotator cuff tear and LHB lesion were reconfirmed intraoperatively. Patients with full-thickness tears of the supraspinatus (and infraspinatus), and patients with partial subscapularis tears with full-thickness supraspinatus (and infraspinatus) tears were included. A partial tear of the biceps pulley was described as injury or gross partial. The arms of the patients were fully rotated internally and externally to evaluate the stability of the biceps tendon. If the biceps tendon was displaced from the groove, it was defined as subluxation or dislocation. After intraoperative evaluation of LHB tendon; LHB with an inflammation, partial tear of LHB tendon, a partial tear of biceps pulley, LHB with tendon subluxation were included in the study. The study was approved by the institutional local ethical committee (IRB no: 2020/06–39).

Inclusion and exclusion criteria

Patients who had been treated with the arthroscopic double-row repair of rotator cuff tear and biceps tenodesis with a minimum follow-up of 24 months, who fit well with follow up were included study. Exclusion criteria were patients who had massive or irreparable rotator cuff tears, had isolated subscapularis tears, had LHB tendon dislocation, glenohumeral osteoarthritis, acromioclavicular joint osteoarthritis, previous history of upper extremity surgery from the ipsilateral or contralateral side (shoulder/elbow/forearm/wrist surgery), dementia, rheumatoid arthritis, and any inflammatory arthritis.

Evaluation of the patients

All patients were evaluated preoperatively, using the American Shoulder and Elbow Surgeons score (ASES) [21], Constant score (CS) [22], VAS for biceps groove tenderness on digital palpation and biceps apex distance (BAD) [23, 24] for the operated side. Biceps apex distance is the distance from the inner margin of the pectoralis major tendon to the

apex of the biceps [23, 24].Elbow flexion strength at the flexion of 90^0 and supination strengths of the forearm for both operated and contralateral elbows and forearms were measured using a digital dynamometer (Lafayette manual muscle tester, IN, USA, kg) (Fig. 1).

Surgical technique

Surgery was performed under general anesthesia in the lateral decubitus position. After creation of standard posterior and anterior portals, two lasso loops were created passing through the biceps tendon (Fig. 2). Tenotomy was performed and suture strands were kept at the anteriorportal for later tenodesis. The arthroscope was placed to subacromial bursa and conventional double-row repair of supraspinatus tendon was performed. Sutures from the biceps tendon were incorporated into lateral row anchors similar to the technique of Levy JC [20](Fig. 3). No additional coracoacromial ligament complete release or subacromial decompression was performed.

Postoperative rehabilitation

Postoperatively, an abduction sling was applied and patients performed passive exercises, preventing supination of the forearm and external rotation of arm beyond neutral. Active assisted range of motion (ROM) exercises were begun four weeks after the operation. All evaluations were repeated at 3rd, 6th, 12th, and 24th months follow-up postoperatively (Fig. 4).

Statistical analysis

Data analysis was performed using SPSS (Statistical Package or the Social Sciences for Windows, version 22.0 (IBM, SPSS Statistics, New York, USA). Standard deviation and arithmetic mean of repeated measurements of patients prior to surgery and on postoperative 3rd, 6th, 12th, and 24th months were calculated. Repeated Multivariate Tests were used to determine whether or not the differences in repeated measurements were significant. Prior to this test, the homogeneity of variants was assessed by Mauchly's Test of Sphericity, and if it is homogeneous ($p > 0.05$) a parametric Repeated Multivariate Test was used in analysis. In case of determining significant differences in the repeated tests, the Bonferroni pairwise comparison test was implemented to determine the measurements that cause the differences. If variants are not homogeneous, a non-parametric related samples Friedman Test was implemented. Tables of pairwise comparisons were not made. Constant score, ASES, VAS for biceps groove, BAD, elbow flexion, and forearm supination strength scores were analyzed by paired multivariate test. The analysis included independent variables of age (year), duration of pain before surgery (month), tear size (ordinal), the existence of diabetes, sex, and smoking status.

Results

Nineteen patients of 22 were included in this study. Three patients were excluded from the study, one patient at postoperative 12th-month assessment due to traumatic re-rupture of the rotator cuff and two other patients who did not fit well with follow up. The mean age of the patients was 57,4 ± 9,2 (41–73). Fourteen of the patients were female and 5 were male. Rotator cuff tear was detected as small in five, as medium in nine, and as large in five patients (Table 1).

Table 1
Characteristics of patients who underwent surgery

Arthroscopic biceps tenodesis with rotator cuff repair (n)		***P-value***
Gender	5 male, 14 female	n.s
Age (year)	57,4 ± 9,2 (41–73).	n.s
Dominant side (operated)	10 (52.6%)	n.s
Mean preoperative pain duration (month)	11.2 ± 10.4 (3–48)	n.s
Rotator cuff tear size		n.s
Small	*5*	
Medium	*9*	
Large	*5*	
Diabetes mellitus	4 (21.1%)	n.s
Smoking	7 (36.8%)	n.s
n.s non-significant *(P* > 0.05)		

Constant score, an average of all post-operative measurements and scores were found to be higher than pre-operative values and was considered to be statistically significant (p < 0,01). In the pairwise comparisons, although there were no differences between 6th month and 12th-month average scores (p > 0,05), other groups differed in averages (p < 0,01). The average ASES scores of all measurement after the operation was higher than pre-operative measurements. Again, in the pairwise comparisons, all measurement score averages were different from each other (p < 0,01) (Fig. 4) While VAS for biceps groove measurement averages of postoperative 6th, 12th and 24th month were lower in comparison to pre-operative data and were considered statistically significant (p < 0.01). The average scores on 3rd-month were insignificant in comparison to pre-operative data (p > 0.05) (Table 2).

Table 2
Comparison of the mean scores of the scales used to evaluate the functions of patients who underwent arthroscopic biceps tenodesis with rotator cuff tear.

Repeated measure	**Constant score mean (sd.)**	***ASES mean (sd.)**	***VAS (biceps groove) mean (sd.)**	***BAD (cm) mean (sd.)**
Pre-operative	38,2 (12.38)	30,1 (11.32)	7,9 (1,78)	8,9 (1,26)
Postop 3. month	55,7 (15.23)	58,7 (17.91)	4,1 (2,90)	9,3 (1,07)
Postop 6. month	66,0 (19.60)	73,0 (16.92)	1,1 (1,31)	9,4 (1,08)
Postop 12. month	71,5 (16.72)	77,7 (13.91)	0,7 (1,11)	9,5 (1,07)
Postop 24. month	94,4 (4,59)	91,8 (10.21)	0,2 (0,54)	9,5 (1,06)
Repeated Multivariate Tests	F = 142,5, p < 0,001	F = 102,9, p < 0,001	[a] F = 66,9, p < 0,001	F = 1.61, p = 0,226
**ASES: American Shoulder and Elbow Surgeons score, *VAS: Visual Analog Scale, *BAD: Biceps Apex Distance*				

Popeye sign was not observed in any of the patients. Difference in BAD measurements conducted pre-operatively and at 24th month were 0.6 cm. Yet, BAD measurements at 3rd, 6th, 12th and 24th months did not show statistical differences with pre-operative data ($p > 0,05$).

The forearm supination strength of the operated side was significantly higher than preoperative values. Forearm supination strength of the operated side did not differ significantly regardless of whether it was dominant or not (Pillai's Trace $F = 1.31$, $p = 0.313$). In other words, being the dominant arm was not considered to be significant in terms of muscle supination regaining postoperative strength.

Elbow flexion strength on the operated side was significantly higher than the preoperative strength ($p < 0,01$). There was not a significant difference between dominant and non-dominant arm in terms of elbow flexion strength (Pillai's Trace $F = 1.54$, $p = 0.245$).

There was a significant difference in the comparison of operated and contralateral forearm supination and elbow flexion muscle strength measurements at postoperative 3rd and 6th-month follow-up ($p < 0.01$) (Table 3) (Fig. 5).

Table 3
Comparison of mean forearm supination and elbow flexion muscle strength of patients who underwent surgery.

Repeated	**Forearm Supination Strength (kg.)**			**Elbow Flexion Strength (kg.)**		
	mean (sd.)			**mean (sd.)**		
measure	Contralateral side	Operated side [a]	Mean Dif.	Contralateral side	Operated side [a]	Mean Dif.
Preoperative	7,7 (2,88)	4,4 (2,56)	3,4 (2,43)*	10,9 (4,35)	5,9 (3,74)	5,0 (2,73)*
Postop 3. month	8,2 (2,74)*	6,4 (2,68)*	1,7 (2,00)*	12,0 (4,95)	8,6 (4,78)*	3,4 (2,42)*
Postop 6. month	8,9 (2,86)*	7,9 (2,68)*	1,0 (1,56)*	12,6 (5,04)*	10,6 (5,06)*	2,0 (2,30)*
Postop 12. month	10,1 (3,23)*	9,3 (2,80)*	0,7 (1,55)	17,0 (12.25)*	11,9 (5,21)*	5,1 (13.11)
Postop 24. month	10,8 (3,38)*	10,5 (3,35)*	0,3 (0,67)	17,1 (12.21)*	14,3 (5,47)*	2,8 (0,97)
Repeated Multivariate Tests	F = 7,2, = 0,002	;F = 21,2,p < 0,001		F = 6,3,p = 0,004	;F = 23,7,p < 0,001	

* Paired Samples Test is significant at the < 0,05 level (two-tailed).

a Preop vs all other groups significant at the < 0,05 level.

Discussion

This study showed that rotator cuff repair combined with biceps tenodesis increases both supination and elbow flexion strengths while decreases biceps groove pain compared to preoperative values at the early postoperative period. This was the main finding of our study.

Similar findings were reported by Hufeland et al. [19]. Twenty-two patients included in their studywere randomized for tenodesis and tenotomy. They concluded that there was no significant difference in flexion and supination strength

between tenodesis and tenotomy group after 12 months [19]. Unlike our study, they did not perform additional rotator cuff repair and also performed the biceps tenodesis using the interference screw.

The addition of the repair of rotator cuff tear possibly contributed an increase to the strength in our study. The technique for biceps tenodesis was similar to the technique described by Levy JC. However, two simpler lasso loops were created and incorporated into lateral row anchors instead of Krackow technique, and also the tendon was not exteriorized [20]. This might have resulted in an increase of BAD compared to preoperative levels due to some degree of distal migration of the biceps tendon. Nevertheless, it does not seem to be improved at the postoperative 3rd month period and reaches a plateau there after. Mazocca et al.[23] reported higher ASES scores in patients who underwent subpectoral biceps tenodesis without rotator cuff lesion than the patients who had concomitant rotator cuff lesion. Boileau et al. conducted a retrospective study to evaluate the outcomes of arthroscopic biceps tenotomy or tenodesis who underwent surgery due to persistent shoulder pain. The rotator cuff muscles of the patients were irreparable. They conclude that both arthroscopic tenotomy and tenodesis can reduce pain [8].

In a study conducted by Checchia et al., 15 patients with rotator cuff tears and biceps tendon pathology were operated. The authors stated excellent results in 11 patients while reported satisfactory results as 93.4%. They evaluated the patients according to UCLA score and detected Popeye sign only in one patient. The mean follow-up period of the patients was 32.4 months [25]. We use ASES and Constant score instead of UCLA to evaluate the patients. The mean follow-up period of the patients was 24 months in our study.

Another study with 114 participants was conducted by MacDonald et al.[26] revealed good outcomes for both tenotomy and tenodesis groups. We did not compare the outcomes of tenodesis and tenotomy. Tenodesis was performed to all patients included in our study.

Gialanella et al.[27] investigated the short-term effect of biceps surgery on rehabilitation and functional outcomes. They included 93 patients to the study. Twenty-five patients underwent rotator cuff surgery in addition to biceps tendon surgery and 68 of them underwent only cuff repair. They evaluated Constant score, ROM, pain, and UCLA at admission, the end of rehabilitation, and postoperative sixth month. The patients who underwent simultaneous biceps tendon surgery and rotator cuff repair showed poorer functional outcome in the postoperative sixth month [27]. In our study, the elbow flexion and forearm supination values of the operated side were nearly 2-fold of preoperative values at postoperative 6th month.

One of the advantages of the technique we performed is providing a simple and low costing surgery by performing biceps tenodesis and double-row rotator cuff repair simultaneously.

In contrast to our study Yi et al.[24] reported a higher degree of bicipital pain in the arthroscopic suprapectoral biceps tenodesis group compared to open subpectoral group at early period without a difference after 6 months. VAS scores of the arthroscopic group at postoperative 3rd month were similar to the present study (3 ± 1). Preoperative, postoperative ASES, CS scores were higher probably due to the inclusion of only small and medium-sized tears. More patients in the arthroscopy group had an increase of BAD [24].

Shang et al.[28] conducted a meta-analysis to compare tenodesis and tenotomy groups combined with rotator cuff repairs. The results showed no significant differences in terms of ASES scores, elbow flexion strength index, forearm supination index, and range of motion. However, only few randomized controlled studies were included in this meta-analysis[28]. We did not compare tenotomy and tenodesis patients, our study contained only one group of patients who underwent biceps tenodesis. This is one of the limitations of our study.

The disadvantages of LHB tenotomy are a higher risk for Popeye sign, the risk for loss of flexion and supination strength of elbow [29]. It has been shown that tenodesis and tenotomy have resulted in a good or excellent result in 74% and 77% of cases, respectively. Besides, persistent pain related to tenodesis has reported in 24% of cases [30]. In our study, the patients had almost halved pain at 3rd month. Also, we did not notice any popeye deformity at any patient.

Baumgarten et al.[31] evaluated patients with a comparison between patients who underwent primary arthroscopic rotator cuff repair with and without biceps tenodesis. They stated no difference between groups and concluded that arthroscopic biceps tenodesis simultaneous rotator cuff repair is safe and effective[31]. A study in 30 patients, 12 of whom had a rotator cuff tear underwent isolated biceps tenotomy was conducted by Gill et al.[32] showed a significant improvement in function and reduction in pain. Although we performed tenodesis to our patients, we observed a decrease in pain and an increase in both forearm supination and elbow flexion.

In this study, the muscle strength measurements of the patients were compared with those of the contralateral side as a control group. When the measurements from the preoperative period to the postoperative 24th month were compared, it was found that the elbow flexion and forearm supination strength of the operated side reached a level similar to the contralateral side muscle strength from the postoperative 12th month ($p > 0.05$). As an unexpected situation, an increase in muscle strength was observed in the contralateral side in parallel with the increase in muscle strength on the operated side. The difference between the elbow flexion strength in the preoperative period and postoperative 24th-month muscle strength measurements on the contralateral side was 6.2 kg ($p < 0.001$) and the difference in forearm supination strength was 3.1 kg ($P < 0.001$). Among the reasons for this situation are; patients have been exposed to pain for approximately 1 year (mean preoperative pain duration: 11.2 ± 10.4 months) and thus, the development of avoidance of the extremity (decreased quality of life and daily activity level), the patients felt better in terms of psychology and muscle after the operation period. We think that there may be an increase in motivation, strength, and quality of life and daily activation level of patients with strength measurements. However, in this study, patients were not evaluated in terms of these parameters.

Various studies showed the effect of anxiety and depression on the outcomes of rotator cuff repair surgery [33–35]. Lau et al. aimed to evaluate the effect of anxiety or depression on the ASES score [36]. They concluded that stronger feelings of anxiety or depression cause both lower preoperative and postoperative scores. However, it is correlated with better improvement from surgery. A systematic review conducted by Kennedy et al. to determine whether the patients with rotator cuff tear were affected by psychosocial factors [37]. For this purpose, they identified 980 articles. This study stated that psychosocial factors significantly affect the level of disability and preoperative pain [37]. Similarly, Cho et al suggested that the success of the rotator cuff surgery may improve health-related quality of life and psychological status [34].

Limitations of the present study include lack of a control group, short follow-up time, and the limited number of the patients. Control group consisting of rotator cuff repair with biceps tenotomy or consequences of patients with Popeye deformity remains to be clarified and both are the subject of future studies. Our hypothesis was proven as the increase of both supination and elbow flexion strengths were observed at an early follow-up as 3 months.

Conclusions

In conclusion, arthroscopic biceps tenodesis into the anchors of lateral row combined with rotator cuff repair provides an increase in strength of elbow flexion and forearm supination, while a decrease in pain. These improvements not only have been observed on the operated side but also the contralateral side was affected positively at early postoperative period. Although there is no consensus in the literature about performing biceps tenodesis or tenotomy, we suggest tenodesis combined rotator cuff repair.

Abbreviations

ASES: American Shoulder and Elbow Surgeons Score

CS: Constant Score

VAS: Visual Analogue Scale

BAD: Biceps Apex Distance

MRI: Magnetic Resonance Imaging

LHB: Long Head of the Biceps brachii tendon

ROM: Range of Motion

UCLA: University of California - Los Angeles Shoulder Scale

Declarations

Acknowledgments

None

Funding

There is no funding source.

Ethics approval and consent to participate

This study was approved by the Ethics Committee of Dokuz Eylül University (No: 2020/06-39).

Consent for publication

Signed informed consent for publication was obtained from all authors.

Competing interests

The authors declare that they have no competing interests.

Authors' contribution

Conception and design: All authors;

Administrative support: AI Kılıc, O Hapa, R Ozmanevra, ND Demirkiran;

Provision of study materials or patients: AI Kılıc, O Hapa, R Ozmanevra,O Gursan;

Collection and assembly of data: AI Kılıc, O Hapa, O Gursan;

Data analysis and interpretation: AI Kılıc, R Ozmanevra, ND Demirkiran;

Manuscript writing: All authors;

Final approval of manuscript: All authors.

Conflict of interest

The authors declare that they have no conflict of interest.

Funding

We affirm that we have no financial affiliation (including research funding) or involvement with any commercial organization that has a direct financial interest in any matter included in this manuscript.

Ethical approval

Ethics approval for this study was obtained from the Ethics Committee of Dokuz Eylül University, Turkey (No: 2020/06-39). Informed consent was obtained from all participants in accordance with the Declaration of Helsinki.

Informed consent

None

References

1. Kilicoglu O, Koyuncu O, Demirhan M, Esenyel CZ, Atalar AC, Ozsoy S, et al. Time-dependent changes in failure loads of 3 biceps tenodesis techniques: In vivo study in a sheep model. Am J Sports Med. 2005;33:1536–44.
2. Ozalay M, Akpinar S, Karaeminogullari O, Balcik C, Tasci A, Tandogan RN, et al. Mechanical strength of four different biceps tenodesis techniques. Arthrosc - J Arthrosc Relat Surg. 2005;21:992–8.
3. Elser F, Braun S, Dewing CB, Giphart JE, Millett PJ. Anatomy, function, injuries, and treatment of the long head of the biceps brachii tendon. Arthrosc - J Arthrosc Relat Surg. 2011;27:581–92.
4. Khazzam M, George MS, Churchill RS, Kuhn JE. Disorders of the long head of biceps tendon. J Shoulder Elb Surg. 2012;21:136–45.
5. Braun S, Horan MP, Elser F, Millett PJ. Lesions of the biceps pulley. Am J Sports Med. 2011;39:790–5.
6. Hawi N, Liodakis E, Garving C, Habermeyer P, Tauber M. Pulley lesions in rotator cuff tears: prevalence, etiology, and concomitant pathologies. Arch Orthop Trauma Surg. 2017;137:1097–105.
7. Kelly AM, Drakos MC, Fealy S, Taylor SA, O'Brien SJ. Arthroscopic release of the long head of the biceps tendon: Functional outcome and clinical results. Am J Sports Med [Internet]. 2005;33:208–13. Available from: http://journal.ajsm.org/cgi/doi/10.1177/0363546504269555%5Cnhttp://ajs.sagepub.com/content/33/2/208.short
8. Boileau P, Baqué F, Valerio L, Ahrens P, Chuinard C, Trojani C. Isolated arthroscopic biceps tenotomy or tenodesis improves symptoms in patients with massive irreparable rotator cuff tears. J Bone Jt Surg - Ser A. 2007;89:747–57.
9. Szabó I, Boileau P, Walch G. The proximal biceps as a pain generator and results of tenotomy. Sports Med Arthrosc. 2008;16:180–6.
10. Hsu AR, Ghodadra NS, Provencher CMT, Lewis PB, Bach BR. Biceps tenotomy versus tenodesis: A review of clinical outcomes and biomechanical results. J Shoulder Elb Surg. 2011;20:326–32.
11. Wittstein JR, Queen R, Abbey A, Toth A, Moorman CT. Isokinetic strength, endurance, and subjective outcomes after biceps tenotomy versus tenodesis: A postoperative study. Am J Sports Med. 2011;39:857–65.
12. Beletsky A, Cancienne JM, Leroux T, Manderle BJ, Chahla J, Verma NN. Arthroscopic Tenodesis of the Long Head Biceps Tendon Using a Double Lasso-Loop Suture Anchor Configuration. Arthrosc Tech. 2019;8:e1137–43.

13. Lafosse L, Van Raebroeckx A, Brzoska R. A New Technique to Improve Tissue Grip: “The Lasso-Loop Stitch.” Arthrosc - J Arthrosc Relat Surg. 2006;22:1246.e1-1246.e3.
14. Vestermark G, Hartigan D, Piasecki D, Fleischli J, Odum SM, Zheng N, et al. Biceps tenodesis: Biomechanical assessment of 3 arthroscopic suprapectoral techniques. Orthopedics. 2017;40:e1009–16.
15. Lee HJ, Jeong JY, Kim CK, Kim YS. Surgical treatment of lesions of the long head of the biceps brachii tendon with rotator cuff tear: A prospective randomized clinical trial comparing the clinical results of tenotomy and tenodesis. J Shoulder Elb Surg. 2016;25:1107–14.
16. Meraner D, Sternberg C, Vega J, Hahne J, Kleine M, Leuzinger J. Arthroscopic tenodesis versus tenotomy of the long head of biceps tendon in simultaneous rotator cuff repair. Arch Orthop Trauma Surg. 2016;136:101–6.
17. Oh JH, Lee YH, Kim SH, Park JS, Seo HJ, Kim W, et al. Comparison of Treatments for Superior Labrum-Biceps Complex Lesions with Concomitant Rotator Cuff Repair: A Prospective, Randomized, Comparative Analysis of Debridement, Biceps Tenotomy, and Biceps Tenodesis. Arthrosc - J Arthrosc Relat Surg. 2016;32:958–67.
18. Uschok S, Herrmann S, Pauly S, Perka C, Greiner S. Combined arthroscopic tenodesis of the long head of biceps and rotator cuff repair in antero-superior cuff tears. Arch Orthop Trauma Surg. 2016;136:1273–9.
19. Hufeland M, Kolem C, Ziskoven C, Kircher J, Krauspe R, Patzer T. The influence of suprapectoral arthroscopic biceps tenodesis for isolated biceps lesions on elbow flexion force and clinical outcomes. Knee Surgery, Sport Traumatol Arthrosc. 2017;25:3220–8.
20. Levy JC. Simultaneous Rotator Cuff Repair and Arthroscopic Biceps Tenodesis Using Lateral Row Anchor. Arthrosc Tech. 2012;1:e1.
21. Michener LA, McClure PW, Sennett BJ. American Shoulder and Elbow Surgeons Standardized Shoulder Assessment Form, patient self-report section: Reliability, validity, and responsiveness. J Shoulder Elb Surg. 2002;11:587–94.
22. Constant CR, Gerber C, Emery RJH, Søjbjerg JO, Gohlke F, Boileau P. A review of the Constant score: Modifications and guidelines for its use. J Shoulder Elb Surg. 2008;17:355–61.
23. Mazzocca AD, Cote MP, Arciero CL, Romeo AA, Arciero RA. Clinical outcomes after subpectoral biceps tenodesis with an interference screw. Am J Sports Med. 2008. p. 1922–9.
24. Yi Y, Lee JM, Kwon SH, Kim JW. Arthroscopic proximal versus open subpectoral biceps tenodesis with arthroscopic repair of small- or medium-sized rotator cuff tears. Knee Surgery, Sport Traumatol Arthrosc. 2016;24:3772–8.
25. Checchia SL, Doneux PS, Miyazaki AN, Silva LA, Fregoneze M, Ossada A, et al. Biceps tenodesis associated with arthroscopic repair of rotator cuff tears. J Shoulder Elb Surg. 2005;14:138–44.
26. MacDonald P, Verhulst F, McRae S, Old J, Stranges G, Dubberley J, et al. Biceps Tenodesis Versus Tenotomy in the Treatment of Lesions of the Long Head of the Biceps Tendon in Patients Undergoing Arthroscopic Shoulder Surgery: A Prospective Double-Blinded Randomized Controlled Trial. Am J Sports Med. 2020;48:1439–49.
27. Gialanella B, Grossetti F, Mazza M, Danna L, Comini L. Functional recovery after rotator cuffrepair: The role of biceps surgery. J Sport Rehabil. 2018;27:83–92.
28. Shang X, Chen J, Chen S. A meta-analysis comparing tenotomy and tenodesis for treating rotator cuff tears combined with long head of the biceps tendon lesions. PLoS One. 2017;12.
29. van Deurzen DFP, Scholtes VAB, Willigenburg NW, Gurnani N, Verweij LPE, van den Bekerom MPJ, et al. Long head BIceps TEnodesis or tenotomy in arthroscopic rotator cuff repair: BITE study protocol. BMC Musculoskelet Disord. 2016;17.
30. Slenker NR, Lawson K, Ciccotti MG, Dodson CC, Cohen SB. Biceps tenotomy versus tenodesis: Clinical outcomes. Arthrosc - J Arthrosc Relat Surg. 2012;28:576–82.

31. Baumgarten KM, Chang PS, Foley EK. Patient-determined outcomes after arthroscopic rotator cuff repair with and without biceps tenodesis utilizing the PITT technique. J Shoulder Elb Surg. 2019;28:1049–55.
32. Gill TJ, McIrvin E, Mair SD, Hawkins RJ. Results of biceps tenotomy for treatment of pathology of the long head of the biceps brachii. J Shoulder Elb Surg. 2001;10:247–9.
33. Cho CH, Seo HJ, Bae KC, Lee KJ, Hwang I, Warner JJP. The impact of depression and anxiety on self-assessed pain, disability, and quality of life in patients scheduled for rotator cuff repair. J Shoulder Elb Surg. 2013;22:1160–6.
34. Cho CH, Song KS, Hwang I, Warner JJP. Does Rotator Cuff Repair Improve Psychologic Status and Quality of Life in Patients With Rotator Cuff Tear? Clin Orthop Relat Res. 2015;473:3494–500.
35. Thorpe AM, O'Sullivan PB, Mitchell T, Hurworth M, Spencer J, Booth G, et al. Are psychologic factors associated with shoulder scores after rotator cuff surgery? Clin Orthop Relat Res. 2018;476:2062–73.
36. Lau BC, Scribani M, Wittstein J. The Effect of Preexisting and Shoulder-Specific Depression and Anxiety on Patient-Reported Outcomes After Arthroscopic Rotator Cuff Repair. Am J Sports Med. 2019;47:3073–9.
37. Kennedy P, Joshi R, Dhawan A. The Effect of Psychosocial Factors on Outcomes in Patients With Rotator Cuff Tears: A Systematic Review. Arthrosc - J Arthrosc Relat Surg. 2019;35:2698–706.

Figures

Figure 1

Elbow flexion strength at 900 flexion (a, b) and forearm supination strengths (c, d) of both operated and contralateral elbows were measured with the use of a digital dynamometer. (Lafayette manuel muscle tester, IN, USA, kg)

Figure 2

Biceps tendon cut after lasso loops.

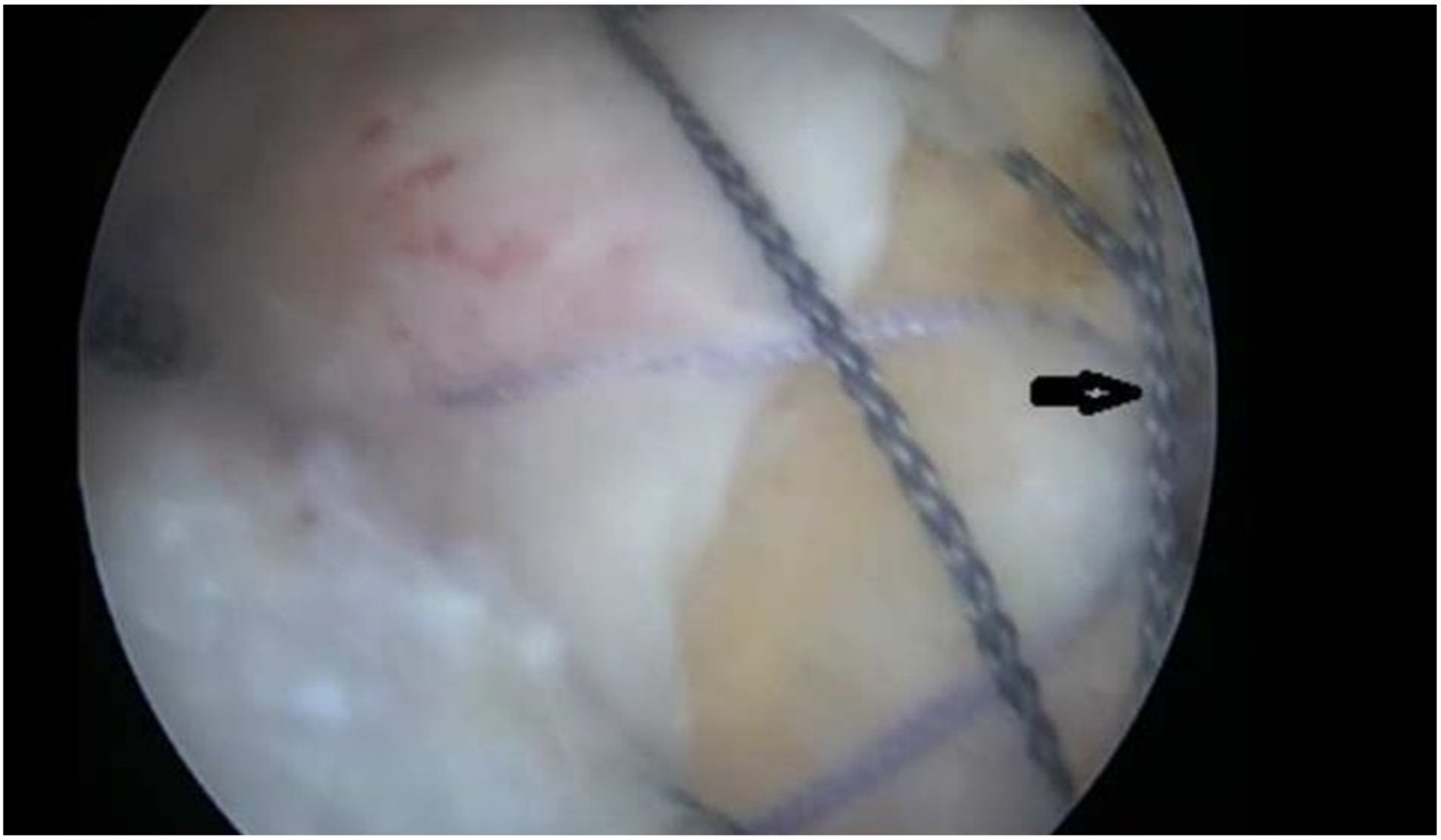

Figure 3

Double row repair of rotator cuff tear. (arrow sutures from the biceps tendon)

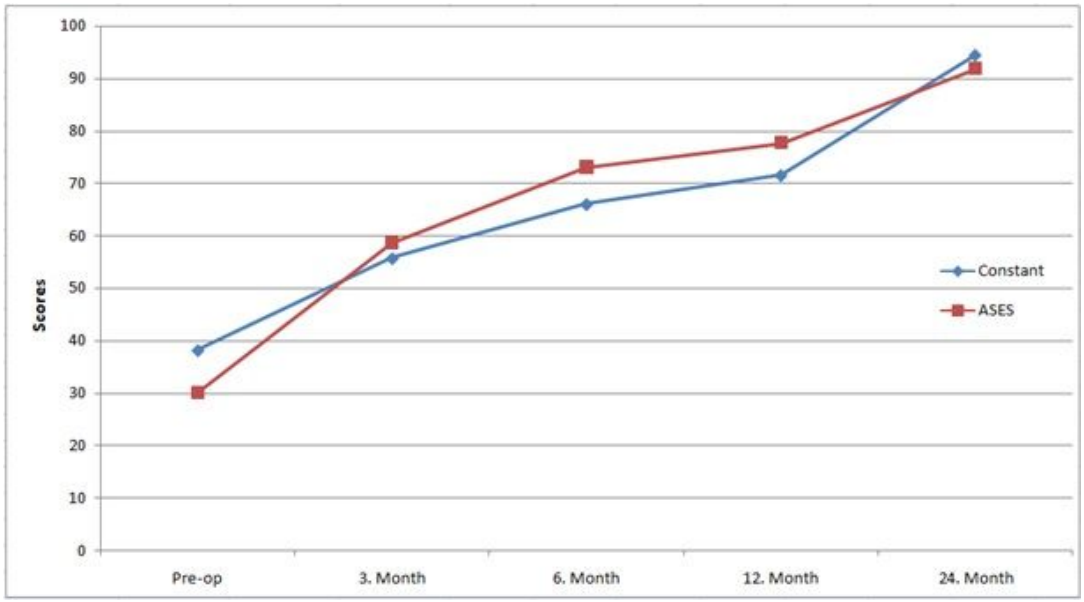

Figure 4

Improvement of the operated side Constant and ASES scores.

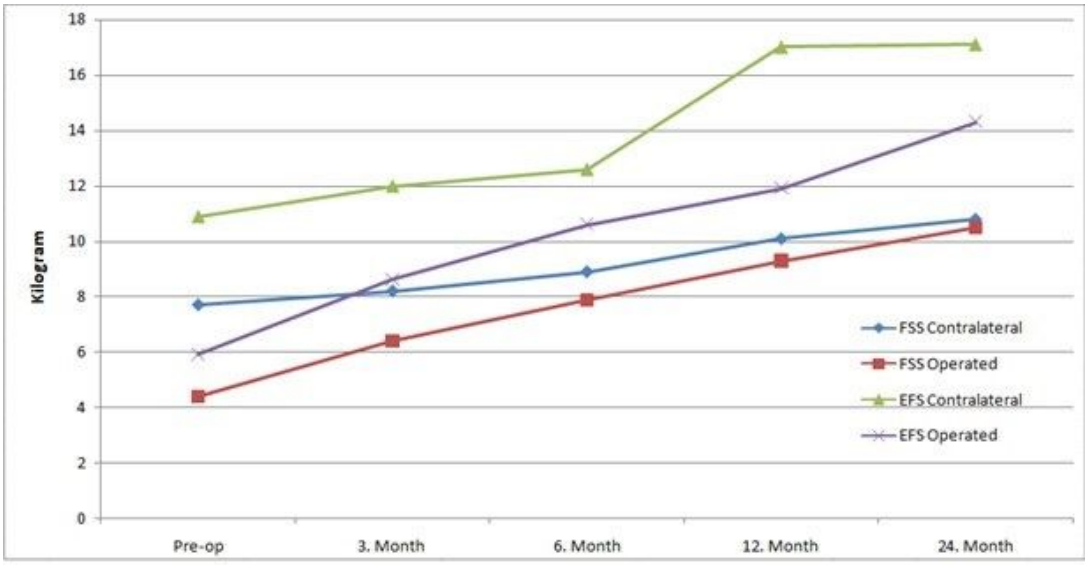

Figure 5

Improvement of the operated and contralateral side elbow flexion and forearm supination strength (kg).