Ascaris lumbricoides causing peritonitis with multiple intestinal perforations: A case report.

Patrick CHARLORIN (charlorin3816@gmail.com)
Saint Damien Hospital/ NPH https://orcid.org/0000-0002-2915-5562

Osnel Louima
Saint Damien Hospital/NPH

Gabriel Steve PIERRE
Saint Damien Hospital/ NPH

Roberto PEIGNE
Saint Damien Hospital

Alexis BOWDER
Program in Global Surgery and Social Change, Harvard Medical School, Boston, USA
https://orcid.org/0000-0002-4927-9378

Maria Grazia Andriani
UOC Pediatric Surgery “Santo Spirito” Hospital Pescara-Italy, Italy

Oleg BODNAR
Department of the Pediatric Surgery and Otolaryngology of the Bukovinian State Medical University, Ukraine

---

Case Report

Keywords: Ascariasis, peritonitis, bowel occlusion, acute abdomen

Posted Date: September 28th, 2021

DOI: https://doi.org/10.21203/rs.3.rs-940439/v1

Abstract

Introduction: Ascaris lumbricoides are still a burden in developing countries especially in Haiti. The lack of hygiene measures leads to an increase in morbidity and mortality due to parasitic infections. They lead to some serious complications, including bowel obstruction and peritonitis.

Case presentation: We present a case of a girl (4 years old) from Haiti. She was admitted to the hospital with abdominal pain and a mass in the right lower quadrant of the abdomen and some worms were palpate at the rectal exam. During the surgical procedure, a large number of alive worms and ileum's perforation holes were revealed. Ileo-ileal anastomosis end to end was performed. After appropriate surgical and post-operative treatment, the girl fully recovered.

Conclusion: In developing countries like Haiti, ascariasis should be kept in mind as a possible etiology of peritonitis in infants.

1. Introduction

Ascaris lumbricoides are some of the most frequent worms to infest the human bowel [1]. Infecting one-quarter of the global population, ascariasis is considered as the leader of helminths infection [2]. The majority of infected cases are found in developing countries (from 8 to 25% people) where access to hygienic practices, good sanitation conditions, and safe drinking water access are still unachieved goals [3]. In African countries like Nigeria, the prevalence has been reported in children to be as high as 88,5% [4].

According to a survey, one in four children aged six to fifteen is carrying some intestinal worms in the Haitian population. In the case of ascariasis particularly when the load of worms is high, surgical complications can take place [5]. Bowel occlusion because of a large number of worms, volvulus, intussusception, pancreatitis, biliary ascariasis, acute appendicitis is the most common indication for surgical treatment of ascariasis complication [4], [6].

From 50 to 65 % ascariasis in developing countries are complicated requiring urgent surgical interventions [7], [8].

Here we present a case of multiple bowel perforations due to ascariasis in a four years old female.

2. Case Presentation

A four years old female, the last born of a family of eight living in a small area, 74 km from our hospital presented to the emergency department of Saint Damien hospital in February 2017. She was complaining of abdominal pain for 2 days before the admission.

On physical examination she was pale and appeared to be malnourished, she had a fever (37.9^{o}C), pulse was regular with a rate of 130 per minute, respiration rate was 44 per minute. A cardiovascular exam

revealed normal S1 and S2 with no murmur. Any neurologic deficit was not found for the central nervous system examination. Abdominal distension and tenderness were demonstrated by abdominal examination. The mass in the right lower quadrant was revealed by abdominal palpation. Minimal peristalsis was heard on auscultation. Some structures remaining of worms were felt at the rectal exam. During the first evaluation, the child passed an episode of liquid stool containing two worms. A Levin tube was placed in the stomach for decompression and bilious secretions draining. Intestinal occlusion by Ascaris lumbricoides was initially suspected and the surgical team was contacted.

Laboratory investigations were done. Hemoglobin level was 10, red blood cell count was 3.7 * 106 per cc, there was an increase of neutrophils 61 %. The creatinine level was 0.8mg per dL and the potassium level was 4.9mEp/L. There was no air image in the plain X-ray study of the abdomen.

The girl was prepared for surgical intervention. We performed correction of fluids and electrolytes imbalance. Ceftriaxone, metronidazole, and analgesics were administered intravenously. Two days after the admission the girl was taken for surgery. The transverse supraumbilical incision was carried out. On laparotomy, the entire peritoneal cavity was filled with bundles of alive worms. Fig.1 (Girl 4 years old. Intraoperative photograph. Alive

roundworms into the abdominal cavity.)

More than Onehundred roundworms were extracted from the abdominal cavity Fig.2 (Bundles of worms that were extracted during the surgical procedure). Further revision showed two perforations holes in the antimesenteric border in the ileum at 20 cm and 25 cm from the ileocecal valve. Fig.3 (Girl 4 years old. Intraoperative photograph. Perforation holes of ileum 20 cm and 25 cm from ileocecal valve). The dimensions of the openings were 5 cm and 3 cm respectively. The intestines were free from Ascaris due to all of them went into the peritoneal cavity through perforation holes. The ileal resection 10 centimeters in length was performed. Followed end-to-end hand sewn ileo-ileal-anastomosis was done. The rest of the bowel was healthy. The abdominal cavity was cleaned with normal saline and a Penrose drain was placed in the right lower quadrant into the pelvis.

The postoperative course was marked by a delay of the intestinal transit. The abdominal function returned during postoperative day seven. The girl had a surgical site infection and anemia. She was discharged on postoperative day 27 and followed as an outpatient.

2. Discussion

Ascaris lumbricoides is one of the most common global infections, largely affecting tropical and subtropical developing countries. Hygiene is a critical component of prevention as Ascariasis results from the fecal-oral transmission which is often a problem for impoverished communities. Improved sanitation and public health measures to achieve safe drinking water can limit infections [9].

Once ingested these parasites transit the enteric mucosa to enter the circulatory system. From there, larvae grow within the lung before being ingested back into the gastrointestinal tract. There they continue to mature and grow, with lengths reaching 15-30cm. If a significant volume of worms builds within the gastrointestinal tract they can cause severe distension of the bowel and symptomatic disease. Patients may present with a myriad of symptoms from abdominal pain, nausea, and vomiting to respiratory difficulty, fever, and hemoptysis if evaluated during lung migration. Laboratory studies may show eosinophilia, but infection is often diagnosed through stool exams for ova and parasites. Various imaging modalities such as x-ray and ultrasound can be used which may show obstructive patterns or even visible worm masses [4].

Pediatric patients infected with Ascaris lumbricoides can develop multiple complications including appendicitis, gastrointestinal bleeding, hepatobiliary disease, intussusception, and bowel obstruction among others. [10]. Surgical intervention is relatively uncommon, with most patients successfully treated conservatively with supportive care and anti-parasitic medications. Reports of operative treatment range from approximately 20–30 % and vary on how extensive surgical treatment is needed [11].

Bowel perforation is a rare complication that needs emergent surgical intervention. This is likely because the worms lack teeth, and the small bowel can undergo significant distension to accommodate the worms. Often perforation is considered secondary to existing bowel pathology creating weaknesses such as typhoid, amebiasis, ulcers, or trauma [1] although in other sources, all point to literature from 1970-80s. Despite this, there are reports of perforation without preexisting disease, possibly due to significant pressure from the worm load causing ischemia. A high index of suspicion and urgent treatment is needed for patients with signs of peritonitis or perforation due to Ascariasis. This surgical treatment includes removal of the worms and often requires resection and anastomosis or ileostomy.

Conclusions

Ascariasis should be borne in mind in the case of abdominal pain and clinical picture of peritonitis in temperate and tropical countries.

Ileum perforation is possible due to pressing directly into the bowel wall, inflammatory reaction, and intestinal wall necrosis.

The choice of surgical intervention depends on the child's condition, the number of ileal perforation holes, and the distance from the ileocecal valve. Ileo-ileal anastomosis end to end can be the method of optimal decision as in our reported case.

Declarations

Acknowledgments:

Thanks to the Francesca Rava Foundation, which contributes to the development of pediatric surgical care in Haiti.

Statement on participant consent: Parents of the enfant consented to participate and publish their child's clinical data and images.

References

1. R. S. Ramareddy, A. Alladi, O. S. Siddapa, V. Deepti, T. Akthar, and B. Mamata, “Surgical complications of Ascaris lumbricoides in children,” *J. Indian Assoc. Pediatr. Surg.*, vol. 17, no. 3, pp. 116–119, 2012, doi: 10.4103/0971-9261.98130.

2. C. M. Mbanga, K. S. Ombaku, K. N. Fai, and V. N. Agbor, “Small bowel obstruction complicating an Ascaris lumbricoides infestation in a 4-year-old male: A case report,” *J. Med. Case Rep.*, vol. 13, no. 1, pp. 1–5, 2019, doi: 10.1186/s13256-019-2103-y.

3. S. R. Ahmad and A. A. Rather, “Worm Obstruction In Children : Has Anything Changed Post Deworming Compaigns. A Tertiary Care Study .,” vol. 18, no. 1, pp. 70–74, 2019, doi: 10.9790/0853-1801137074.

4. A. A. J. Hesse, A. Nouri, H. S. Hassan, and A. A. Hashish, “Parasitic infestations requiring surgical interventions,” *Semin. Pediatr. Surg.*, vol. 21, no. 2, pp. 142–150, 2012, doi: 10.1053/j.sempedsurg.2012.01.009, http://dx.doi.org/10.1053/j.sempedsurg.2012.01.009.

5. E. Uysal and M. Dokur, “The helminths causing surgical or endoscopic abdominal intervention: A review article,” *Iran. J. Parasitol.*, vol. 12, no. 2, pp. 156–168, 2017.

6. A. H. Sarmast, F. Q. Parray, H. I. Showkat, Y. A. Lone, and N. A. Bhat, “Duodenal Perforation with an Unusual Presentation: A Case Report,” *Case Rep. Infect. Dis.*, vol. 2011, pp. 1–3, 2011, doi: 10.1155/2011/512607.

7. C. D. Darlington and G. F. S. Anitha, “Ascaridial volvulus: An uncommon cause of ileal perforation,” *Iran. J. Med. Sci.*, vol. 43, no. 4, pp. 432–435, 2018.

8. S. Gupta, S. Kumar, A. Satapathy, U. Ray, S. Chatterjee, and T. K. Choudhury, “Ascaris lumbricoides: an unusual aetiology of gastric perforation,” *J. Surg. Case Reports*, vol. 2012, no. 11, pp. rjs008–rjs008, 2012, doi: 10.1093/jscr/rjs008.

9. E. C. Strunz, D. G. Addiss, M. E. Stocks, S. Ogden, J. Utzinger, and M. C. Freeman, “Water, Sanitation, Hygiene, and Soil-Transmitted Helminth Infection: A Systematic Review and Meta-Analysis,” *PLoS Med.*, vol. 11, no. 3, 2014, doi: 10.1371/journal.pmed.1001620.

10. A. A. Baba, S. M. Ahmad, and K. A. Sheikh, “Intestinal ascariasis: The commonest cause of bowel obstruction in children at a tertiary care center in Kashmir,” *Pediatr. Surg. Int.*, vol. 25, no. 12, pp. 1099–1102, 2009, doi: 10.1007/s00383-009-2486-8.

11. I. Wani, M. Rather, G. Naikoo, A. Amin, S. Mushtaq, and M. Nazir, “Intestinal ascariasis in children,” *World J. Surg.*, vol. 34, no. 5, pp. 963–968, 2010, doi: 10.1007/s00268-010-0450-3.

Figures

Figure 1

Bundles of Ascaris lumbricoides, at the opening of the abdomen.

Figure 2

Extracted Ascaris lumbricoides from the abdominal cavity and the small intestine.

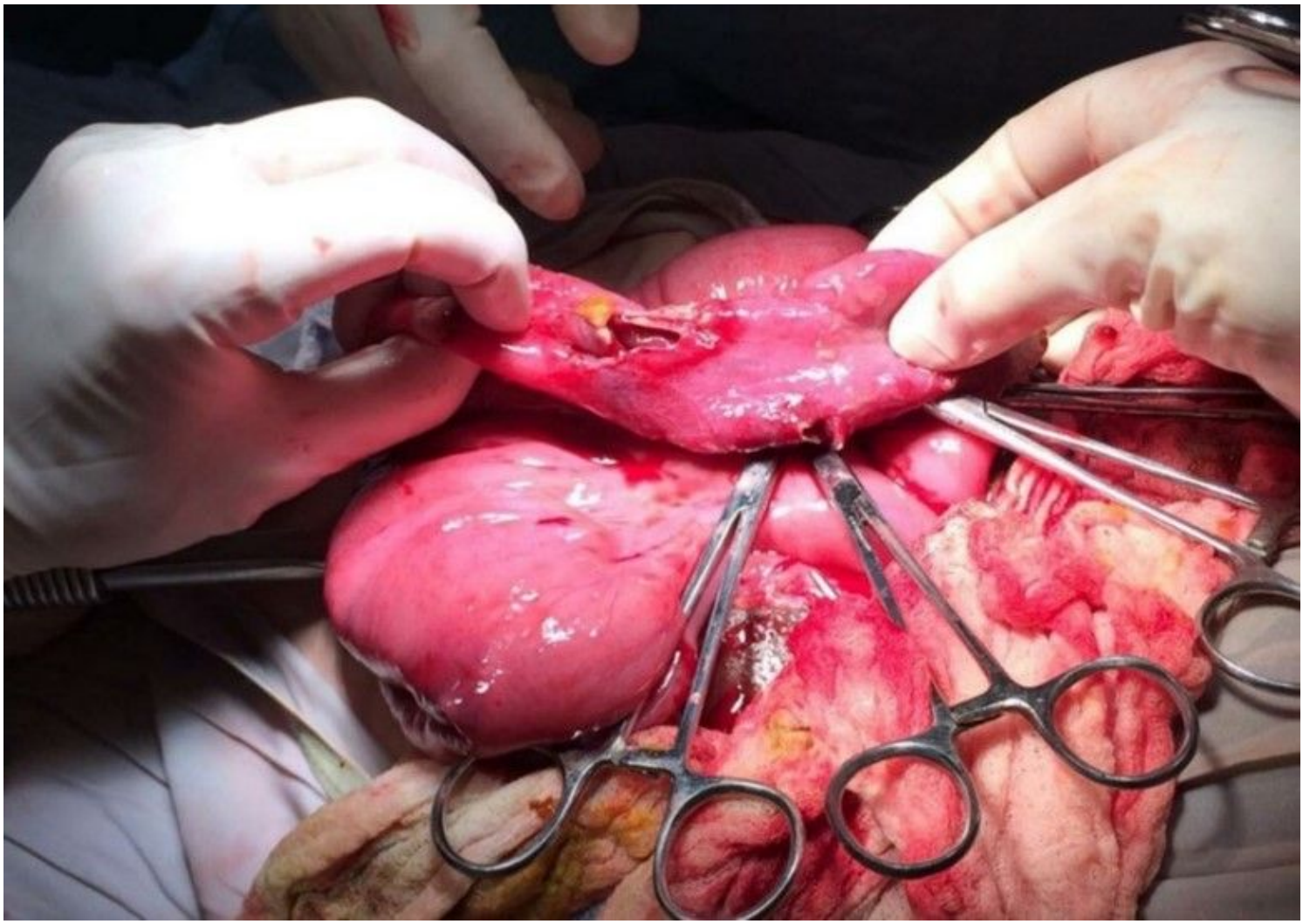

Figure 3

Multiple ileal perforations, found after the abdominal cavity exploration.