Comparing the surgical efficacy of a newly designed endoscopic visualized trephine and a conventional trephine for percutaneous endoscopic lumbar discectomy with foraminoplasty for patients with single-segment lumbar disc herniation: A retrospective case -control study

Shangbo Niu
Southern Medical University Nanfang Hospital
Dehong Yang
Southern Medical University Nanfang Hospital
Jie Li (lijie87919@163.com)
Xuzhou Central Hospital
Wenbo Diao
Xuzhou Central Hospital
Jian Gao
Xuzhou Central Hospital
Yiming Li
Xuzhou Central Hospital

Research article

Keywords: Percutaneous endoscopic lumbar discectomy, lumbar disc herniation, a newly designed endoscopic visualized trephine, foraminoplasty

Posted Date: October 5th, 2021

DOI: https://doi.org/10.21203/rs.3.rs-942316/v1

Abstract

Background

Owing to the remarkable evolution of percutaneous endoscopic lumbar discectomy (PELD), the application of spinal endoscopy is shifting from the treatment of soft disk herniation to complex lumbar spinal stenosis. This study aim to compare the surgical efficacy of a newly designed endoscopic visualized trephine and a conventional trephine for PELD with foraminoplasty for patients with single-segment lumbar disc herniation (LDH).

Methods

A total of 54 patients who were diagnosed with single-segment LDH and received PELD with foraminoplasty at Xuzhou Central Hospital (Xuzhou, China) from January 2016 to June 2020 were included in this case-control study. Data related to the length of incision, amount of intraoperative bleeding, the time required to create the working channel, and intraoperative and postoperative complications were recorded. The Visual Analog Scale (VAS) score was used to assess low back pain and leg pain. Besides, the Oswestry Disability Index (ODI) and Japanese Orthopedic Association (JOA) scores were utilized to evaluate patients' pain intensity and their sitting and standing abilities. The X-ray fluoroscopy was performed to measure the horizontal and angular displacements of lumbar extension-flexion, and to evaluate the stability of lumbar spine.

Results

All the patients successfully underwent surgical procedures, except for two patients with injuries in the spinal nerve root of the responsible segment in the conventional trephine group, who were given nutritional supplements for nerve treatment. Besides, there was no significant difference in incision length and operative blood loss between the modern trephine and the conventional trephine groups. However, the time required to create the channel and the duration of fluoroscopy in the modern trephine group were significantly less than those in the conventional trephine group (34.24 ± 5.38 vs. 44.76 ± 6.37 min, $P < 0.05$). In addition, the VAS, ODI, and JOA scores significantly decreased postoperatively in the two groups. We also found no significant difference in horizontal and angular displacements of lumbar extension-flexion between the two groups pre-operation and at 3- and 12-month post-operation.

Conclusion

In spite of similar surgical efficacy of the two techniques, the newly designed endoscopic visualized trephine outperformed in terms of operation time and duration of fluoroscopy.

Background

Percutaneous endoscopic lumbar discectomy (PELD) was previously proposed for the decompression of the lumbar disc space and removal of nucleus pulposus via a posterolateral approach. PELD also causes less damage to the paravertebral muscle and lower gastrointestinal bleeding, and it is associated with a shorter hospitalization and faster functional recovery postoperatively. To date, PELD has been widely applied to treat lumbar disc herniation (LDH) (1, 2).

The main surgical channel for PELD is the intervertebral foramen, which is the bony structure between pedicles of the adjacent vertebrae, and the nerve root separates the spinal canal from the superior anterior edge of the intervertebral foramen. The so-called "safety triangle" is located in the lower edge of the intervertebral foramen, and it can avoid damage to the nerve (3, 4). However, the osteophyte, vertebral subsidence, and intervertebral disc ossification could make it narrow. When the width of channel is < 7 mm, it is not easy to insert a working cannula and fully guarantee the safety of the nerve. In order to expand the foramen and guarantee the efficacy and safety of the surgery, appropriate resection of the articular process and vertebral lamina is highly essential. Although some innovative techniques were presented to overcome the above-mentioned surgical challenges(5), foraminoplasty has been reported as a low-risk surgical procedure for PELD. There are several minimally invasive endoscopic spine procedures to treat lumbar spinal stenosis (LSS). Due to technical barriers in handling the limited availability of instruments, they have been only utilized by experienced endoscopic surgeons (6). Endoscopic foraminoplasty is a safe and effective surgical method for the treatment of foraminal stenosis.

At present, several surgical tools are commonly used for foraminoplasty, including surgical drills and trephines. However, their accuracy is limited, the level of radiation exposure is still noticeable, and the operation time is relatively long (7). The conventional high-speed drills can even increase the risk of iatrogenic nerve injury or dural sac tear (8). Using a trephine with protective working cannula for foraminoplasty, articular process has shown high levels of safety and efficiency for PELD. The present study aimed to compare the surgical efficacy of a newly designed endoscopic visualized trephine (or can be called modern trephine group) and a conventional trephine (or can be called conventional trephine group) for PELD with foraminoplasty for patients with single-segment lumbar disc herniation (LDH).

Methods

Study design and patients

A total of 54 patients with single-segment LDH who received PELD at Xuzhou Central Hospital (Xuzhou, China) from January 2016 to June 2020 were included in this single-center case-control study. The inclusion criteria were as follows: (1) Patients with single-segment LDH with radicular pain and nerve root pain; (2) A consistency between microstructural changes of the compressed nerve root and clinical symptoms according to the data acquired from imaging examinations; and (3) No incidence of recurrence after undergoing an ineffective conservative treatment for at least 8 weeks.

The exclusion criteria were as follows: (1) Patients with spinal infections, diverse types of cancer, deformity of the spine, or other coexisting diseases, seriously influencing patients' quality of life; (2) Patients with severe osteoporosis; (3) Patients with lumbar instability; (4) Patients who could not tolerate local anesthesia, or were unable to undergo PELD; or (5) Incomplete follow-up data.

The study protocol was approved by the Ethics Committee of the Xuzhou Central Hospital (Approval No. …). All patients signed the written informed consent form before beginning the study.

Surgical procedures

In the prone or lateral position, a C-arm X-ray machine was used to determine the anterior and lateral positions of lumbar vertebrae intraoperatively. The puncture route was marked on the skin surface, and L4/5 and L5/S1 segments were selected to enter the needle at about 10-12 cm beside the midline of the spinous process to be in parallel with the intervertebral space. Routine disinfection, laying sterile towels, local anesthesia (from skin to near the articular process using 1% lidocaine hydrochloride), placing a puncture needle under the guidance of fluoroscopy, adhering to the anterior ventral side of the articular process until reaching the target position, inserting the guidewire, making a skin incision of about 8 mm along the guidewire, inserting the expander step-by-step, creating a working channel with a width of 7.5 mm, as well as isolating the articular process using the newly designed endoscopic visualized trephine (or modern trephine group) were conducted. The articular process was cut using the newly designed endoscopic visualized trephine and the intervertebral foramen was enlarged (Fig. 1a). In the fluoroscopy, under the guidance of C-arm X-ray machine, the articular process was resected step-by-step (Fig. 1b), and endotracheal intubation was undertaken. X-ray images confirmed the true position of the working channel, a spinal endoscope was then inserted, and the width of working channel was adjusted. Then, it was attempted to explore the spinal canal, remove the herniated lumbar intervertebral disc tissue with a clamp, expose the nerve root, and connect ligamentum flavum to posterior longitudinal ligament. The residual nucleus pulposus tissue and fibrous annulus in the intervertebral disc were ablated using a bipolar radiofrequency-based electrode. The nerve root was explored, bleeding was stopped thoroughly, and the working channel was pulled out. Afterwards, primary suture was performed under an antibiotic cover.

Measurements

The Visual Analog Scale (VAS) score was used to assess low back pain and leg pain. Besides, the Oswestry Disability Index (ODI) and Japanese Orthopedic Association (JOA) scores were utilized to evaluate patients' pain intensity and their sitting and standing abilities, and those scores were calculated as described previously (9). The X-ray fluoroscopy was performed to measure the horizontal and angular displacements of lumbar extension-flexion and to evaluate the stability of lumbar spine (10).

Patients' demographic and clinical data, including gender, age, diagnostic method, and surgical data (i.e., incision length, bleeding, time of channel establishment, and timing of fluoroscopy) were collected from the inpatient medical record system of Xuzhou Central Hospital.

The horizontal displacement and angular displacement were recorded from patients' lateral X-ray films. The above-mentioned data were recorded at 3 time-points before surgery, as well as 3 months and 1 year after surgery. Follow-up was accordingly carried out as well.

Statistical analysis

Categorical variables were described as percentage, and continuous variables were expressed as mean ± standard deviation (SD). Patients' demographic and clinical characteristics were compared using the Pearson's chi-squared test for categorical variables, and the Student's t-test for continuous variables. The statistical analysis was carried out using the GraphPad Prism 8 software (GraphPad Software Inc., San Diego, CA, USA). $P<0.05$ was considered statistically significant.

Results

Patients' demographic and clinical data at baseline

This study included 54 cases who were diagnosed with single-segment LDH. They all received standard PELD with foraminoplasty. There were 29 cases (male (17) vs. female (12) patients) in the modern trephine group, with a median age of 45.37±12.98 years old, and their range of age was 22-73 years old; in the conventional trephine group, there were 25 cases (male (16) vs. female (9) patients), with a median age of 41.88±16.85 years old, and their range of age was 17-87 years old.

Postoperative data

All patients successfully underwent the surgical procedures, except for two patients with injuries occurred in the spinal nerve root of the responsible segment in the conventional trephine group, who were given nutritional supplements for nerve treatment, and were fully recovered at 3-month post-operation. No further complications (e.g., nerve injury or vascular and visceral complications) were observed in other patients. The perioperative data of the two groups are shown in Table 1. There was no significant difference in incision length and operative blood loss between the two groups ($P > 0.05$). However, the time required to create the channel and duration of fluoroscopy in the modern trephine group were significantly less than those in the conventional trephine group ($P < 0.05$). The one-stage wound healing was completed in the two groups, and no complications, such as infections or deep venous thrombosis, were detected.

Table 1. Comparison of perioperative data between the modern trephine and the conventional trephine groups.

Item	Modern trephine group	Conventional trephine group	t-value	P-value
Length of incision (cm)	1.310±0.46	1.36±0.48	0.3793	0.7060
The amount of intraoperative bleeding (ml)	40.69±7.40	42.40±5.85	0.9145	0.3647
Time required to create space within the foramen (min)	34.24±5.38	44.76±6.37	6.4550	<0.05
Duration of fluoroscopy (min)	3.207±0.80	9.800±1.233	23.12	<0.05

Follow-up data

All patients were followed up for 12 months. The VAS, ODI, and JOA scores of all the patients are presented in Table 2. It was revealed that the VAS, ODI, and JOA scores significantly decreased postoperatively in the two groups.

Table 2. Comparison of the VAS, ODI, JOA scores between the two groups at different time points.

Scoring system	Time point	Modern trephine group	Conventional trephine group	t-value	P-value
VAS score	Pre-operation	8.93	8.64	1.192	0.2387
	3-month post-operation	2.21	2.52	1.325	0.1910
	1-year post-operation	0.55	0.80	1.308	0.1968
	F-value	878.90	617.20		
	P-value	<0.0001	<0.0001		
ODI score	Pre-operation	42.76	45.00	1.609	0.1137
	3-month post-operation	9.93	9.84	0.184	0.8549
	1-year post-operation	3.17	3.40	0.698	0.4880
	F-value	1422.00	1442.00		
	P-value	<0.0001	<0.0001		
JOA score	Pre-operation	8.586	8.520	0.1811	0.8570
	3-month post-operation	16.07	15.92	0.2785	0.7817
	1-year post-operation	25.59	25.04	0.8751	0.3856
	F-value	438.10	496.10		
	P-value	<0.0001	<0.0001		

Imaging examination

The results of imaging examination are summarized in Table 3. There was no significant difference in horizontal and angular displacements of lumbar extension-flexion between the two groups pre-operation and at 3- and 12-month post-operation (P > 0.05).

Table 3. Comparison of displacements of lumbar extension-flexion between the two groups at different time points.

Item	Time point	Modern trephine group	Conventional trephine group	t-value	P-value
Horizontal displacement	Pre-operation	1.490	1.432	0.7278	0.4700
	3-month post-operation	1.531	1.492	0.5406	0.5911
	1-year post-operation	1.586	1.532	0.7803	0.4387
	F-value	27.77	16.29		
	P value	<0.0001	<0.0001		
Angular displacement	Pre-operation	4.897	4.720	0.4064	0.6861
	3-month post-operation	5.103	4.840	0.6301	0.5314
	1-year post-operation	5.241	5.080	0.3906	0.6977
	F-value	0.89	8.09		
	P-value	0.4899	0.0009		

Discussion

To our knowledge, LSS is a common degenerative disease in the elderly and can be categorized into central stenosis, lateral recess stenosis, and foraminal stenosis. Surgery is indicated for patients with neurogenic claudication and radicular symptoms when conservative treatment has failed. The main purpose of surgical treatment is to decompress the spinal canal and relieve symptoms. Choi et al. evaluated the efficacy of foraminoplasty for herniated disc (HD) and proposed applicable situations for PELD with foraminoplasty. They found that percutaneous endoscopic lumbar foraminoplasty may be effective for small DH, migration, sequestration, recurrent HD, HD in L5-S1 with a high iliac crest, and central HD with a wide lamina angle (11). The current study compared the surgical efficiency of a conventional trephine with the newly designed endoscopic visualized trephine using VAS, ODA, and JOA scores, as well as imaging examination findings. The results showed that there was no significant difference in the surgical efficiency of these two instruments. However, in terms of operation time and duration of fluoroscopy, the newly designed endoscopic visualized trephine outperformed. In this study, only the surgical kits of the two groups were different. Consistent with the results of the current study, Song et al. (2) assessed the primary clinical outcomes of a novel full-endoscopic foraminotomy with a large endoscopic trephine, and compared the effectiveness of this method with other previous techniques for lumbar foraminal stenosis. They found that the full-endoscopic foraminotomy with the large endoscopic trephine is an effective and safe technique for the treatment of degenerative lumbar foraminal stenosis. Chen et al. proposed a periendoscopic visualized trephine system for foraminoplasty in treating LDH with migration and/or foraminal or lateral recess stenosis, and demonstrated that their

method is safe and effective for the treatment, associating with the improved flexibility and decreased radiation exposure (12).

In recent years, several scholars have attempted to apply foraminoplasty. Gu et al. proposed a new technique, namely the Kiss-Hug maneuver, to efficiently and safely decompress foraminal stenosis using the working cannula. This technique could maximize the effectiveness of endoscopic decompression, while ensuring a patient's and a surgeon's safety (13). Liu et al. presented a novel surgical technique based on foraminoplasty that was designed in an attempt to obtain the ideal state. This technique enables surgeons to perform an accurate resection of the superior articular process by easily adjusting the foraminoplasty working tube to the target area (14).

A number of scholars have assessed the significance of how the degree of injury of the facet joint affects clinical outcomes in foraminoplasty. They demonstrated that percutaneous endoscopic transforaminal discectomy (PETD) with foraminoplasty is effective and safe for the treatment of LDH. However, when foraminoplasty destroys the articular surface of the facet joint, the lumbar instability and recurrence rate post-operation might be increased (15). Use of endoscopic technology in spine surgery can offer a minimally invasive, percutaneous approach rather than the wide-open surgical exposure.

The results of the present research showed that all the patients successfully underwent surgical procedures, except for two patients with injuries in the spinal nerve root of the responsible segment in the conventional trephine group, who were given nutritional supplements for nerve treatment. Besides, there was no significant difference in incision length and operative blood loss between the two groups. However, the time required to create the channel and the duration of fluoroscopy in the modern trephine group were significantly less than those in the conventional trephine group. In addition, the VAS, ODI, and JOA scores significantly decreased postoperatively in the two groups. We also found no significant difference in horizontal and angular displacements of lumbar extension-flexion between the two groups pre-operation and at 3- and 12-month post-operation.

The shortcomings of the current research should be pointed out. Firstly, this is a retrospective study, and no randomized grouping was conducted. Thus, the obvious superiority of the newly designed endoscopic visualized trephine may be exaggerated relatively. Besides, the horizontal displacement and angular displacement in the modern trephine group were higher than those in the conventional trephine group. Last but not least, the sample size was small and the lack of randomized grouping might cause bias. Thus, further research is required to eliminate the above-mentioned shortcomings, and to confirm our findings.

Conclusions

This retrospective study indicated that, in spite of similar surgical efficacy of the two techniques, the newly designed endoscopic visualized trephine outperformed in terms of operation time and duration of fluoroscopy.

List Of Abbreviations

Percutaneous Endoscopic Lumbar Discectomy (PELD)

Percutaneous Endoscopic Transforaminal Discectomy (PETD)

Lumbar Disc Herniation (LDH)

Visual Analog Scale (VAS)

Oswestry Disability Index (ODI)

Japanese Orthopedic Association (JOA)

Herniated Disc (HD)

Standard Deviation (SD)

Declarations

Funding information

The Scientific Research Project of Jiangsu Health Commission,Grant/Award Number:H2019023; Xuzhou Science and Technology Project,Grant/Award Number:KC19152

References

1. Kambin P, Sampson S. Posterolateral percutaneous suction-excision of herniated lumbar intervertebral discs. Report of interim results. Clin Orthop Relat Res. 1986(207):37–43.
2. Song QP, Hai B, Zhao WK, Huang X, Liu KX, Zhu B, et al. Full-Endoscopic Foraminotomy with a Novel Large Endoscopic Trephine for Severe Degenerative Lumbar Foraminal Stenosis at L(5) S(1) Level: An Advanced Surgical Technique. Orthop Surg. 2021;13(2):659–68.
3. Kanno H, Aizawa T, Hahimoto K, Itoi E. Minimally invasive discectomy for lumbar disc herniation: current concepts, surgical techniques, and outcomes. Int Orthop. 2019;43(4):917–22.
4. Ju CI. Technical Considerations of the Transforaminal Approach for Lumbar Disk Herniation. World Neurosurg. 2021;145:597–611.
5. Ahn Y. Endoscopic spine discectomy: indications and outcomes. Int Orthop. 2019;43(4):909–16.
6. Zhang J, Liu TF, Shan H, Wan ZY, Wang Z, Viswanath O, et al. Decompression Using Minimally Invasive Surgery for Lumbar Spinal Stenosis Associated with Degenerative Spondylolisthesis: A Review. Pain Ther. 2021.
7. He J, Tang J, Jiang X, Ren H, Cui J, Liang Z, et al. Efficacy and Safety of Foraminoplasty Performed Using an Endoscopic Drill to Treat Axillary Disc Herniation. World Neurosurg. 2020;138:e413-e9.

8. Lee CH, Choi M, Ryu DS, Choi I, Kim CH, Kim HS, et al. Efficacy and Safety of Full-endoscopic Decompression via Interlaminar Approach for Central or Lateral Recess Spinal Stenosis of the Lumbar Spine: A Meta-analysis. Spine (Phila Pa 1976). 2018;43(24):1756–64.
9. Garg A, Pathak H, Churyukanov MV, Uppin RB, Slobodin TM. Low back pain: critical assessment of various scales. Eur Spine J. 2020;29(3):503–18.
10. Dupuis PR, Yong-Hing K, Cassidy JD, Kirkaldy-Willis WH. Radiologic diagnosis of degenerative lumbar spinal instability. Spine (Phila Pa 1976). 1985;10(3):262–76.
11. Choi KC, Shim HK, Park CJ, Lee DC, Park CK. Usefulness of Percutaneous Endoscopic Lumbar Foraminoplasty for Lumbar Disc Herniation. World Neurosurg. 2017;106:484–92.
12. Chen C, Ma X, Zhao D, Yang H, Xu B, Wang Z, et al. Full Endoscopic Lumbar Foraminoplasty with Periendoscopic Visualized Trephine Technique for Lumbar Disc Herniation with Migration and/or Foraminal or Lateral Recess Stenosis. World Neurosurg. 2021;148:e658-e66.
13. Gu S, Hou K, Jian W, Du J, Xiao S, Zhang X. Working Cannula-Based Endoscopic Foraminoplasty: A Technical Note. Biomed Res Int. 2018;2018:4749560.
14. Liu X, Peng Y. A Novel Foraminoplasty Technique for Posterolateral Percutaneous Transforaminal Endoscopic Lumbar Surgery. Oper Neurosurg (Hagerstown). 2020;19(1):E11-e8.
15. Qiao P, Xu T, Zhang W, Fang Z, Ding W, Tian R. Foraminoplasty affects the clinical outcomes of discectomy during percutaneous transforaminal endoscopy: a two-year follow-up retrospective study on 64 patients. Int J Neurosci. 2021;131(1):1–6.

Figures

A

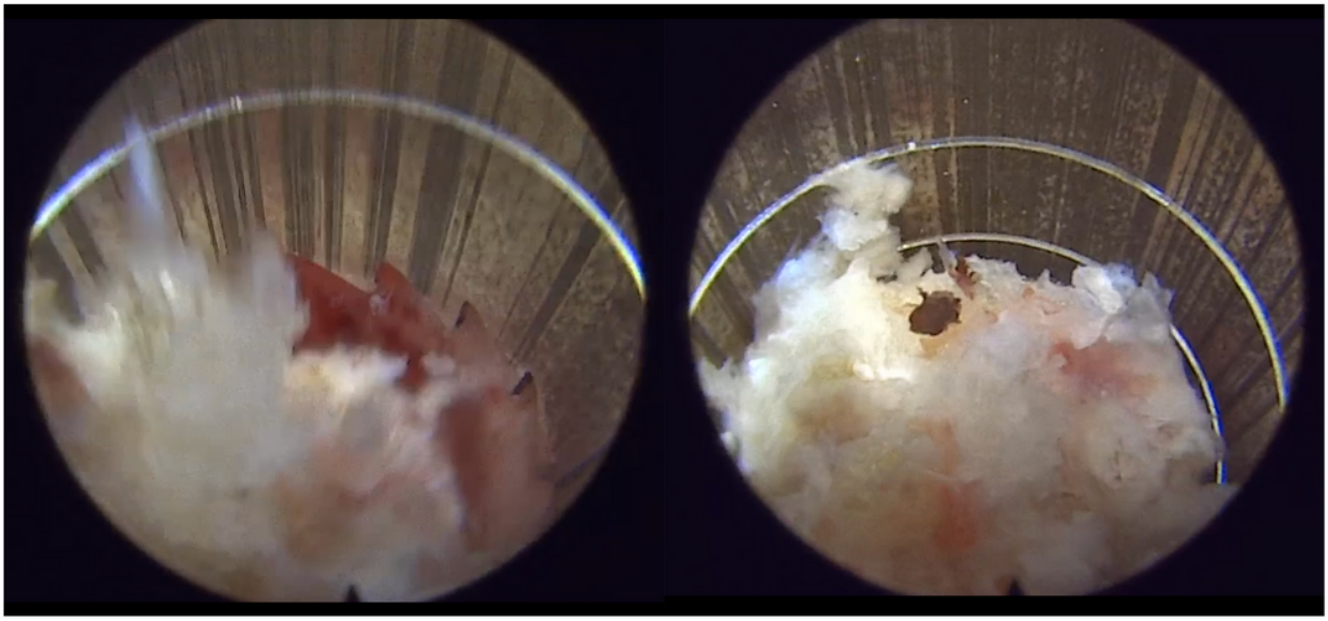

B

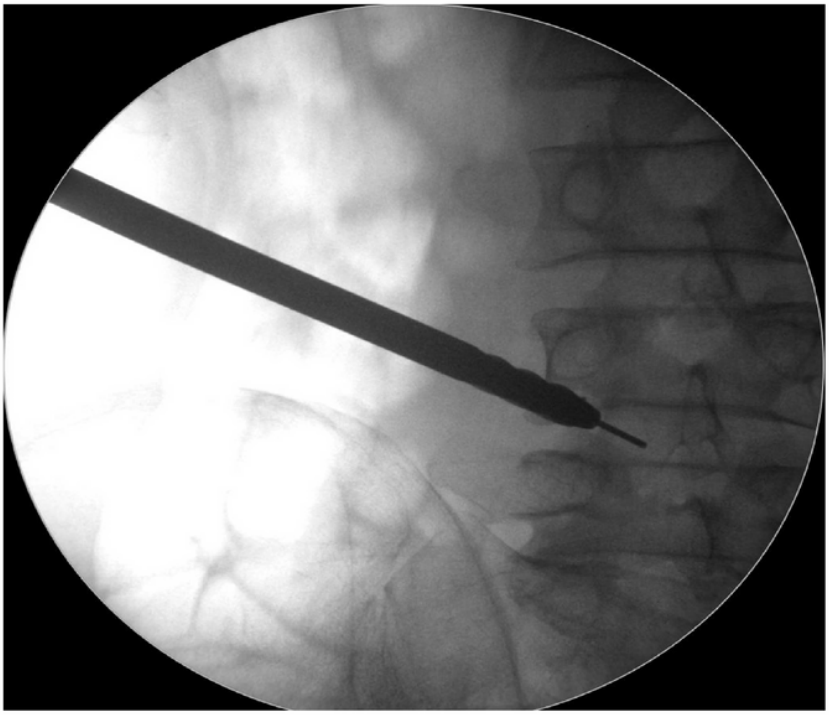

Figure 1

Illustration of PELD procedures. a. A newly designed endoscopic visualized trephine; b. A conventional trephine.

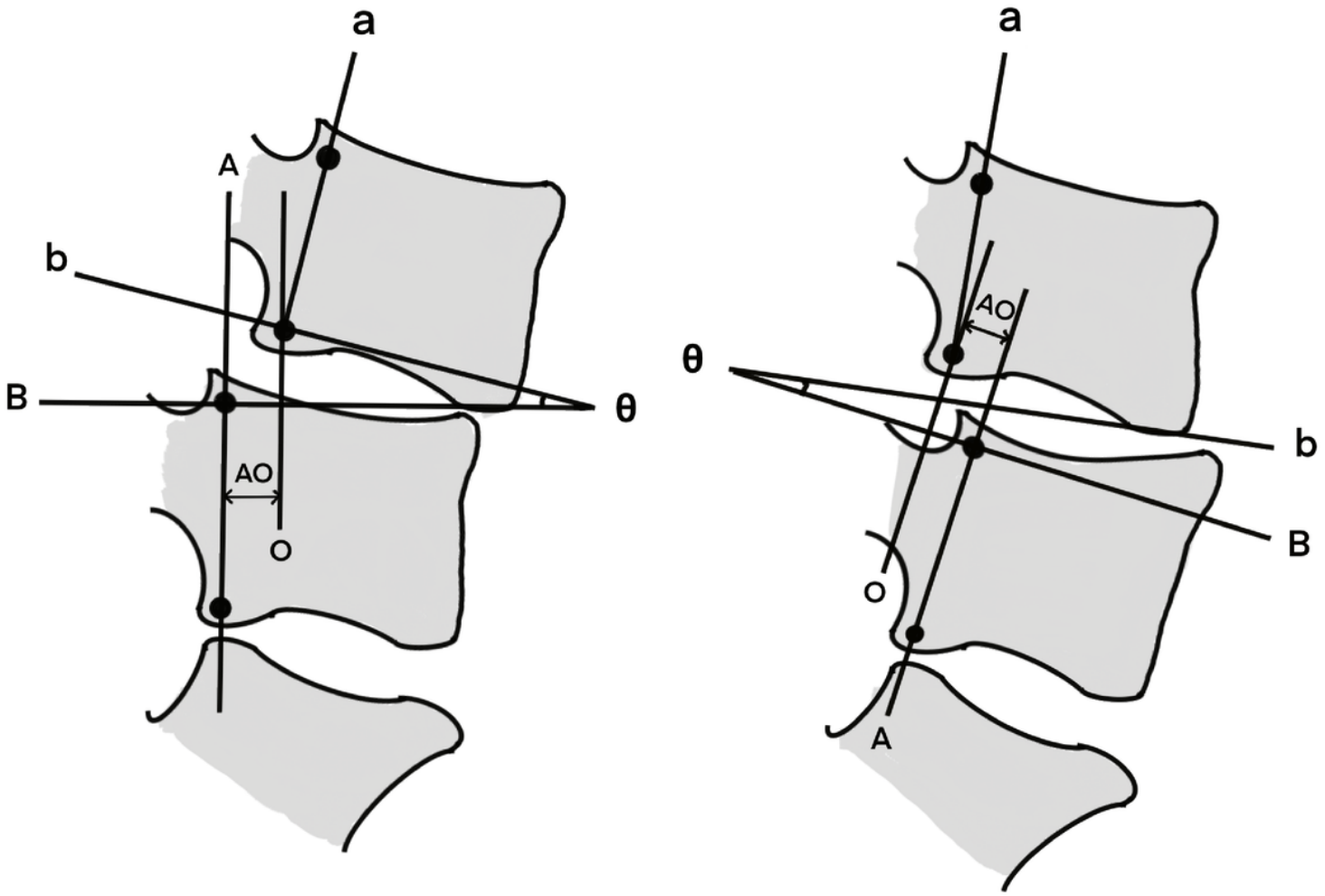

Figure 2

Measurement of horizontal and angular displacements. The image illustrates a lateral extension- and flexion-based X-ray pattern of the lumbar spine, in which the left side is dorsal, and the right side is ventral. 1. A straight line “a” was drew through the highest point and the lowest point of the posterior edge of the upper vertebral body, and then, a straight line “A” was drew using the same method in the lower vertebral body. A straight line “O” in parallel to line “A” was drew. The difference between the lines “A” and “O” was the horizontal displacement. 2. A straight line “b” was drew through the lowest point of the posterior edge of the upper vertebral body that is vertical to “a”. Then, a straight line “B” was drew through the highest point of the posterior edge of the lower vertebral body that was vertical to “A”, the angle between the two lines was named as “θ”, and the angular displacement can be calculated using these data.