The “Needle Re-Entry” Technique for Infrainguinal Arterial Calcified Occlusive Lesions.

Takuya Haraguchi (t.haraguchi@scvc.jp)
Sapporo Heart Center https://orcid.org/0000-0002-2116-2178

Yoshifumi Kashima
Sapporo Heart Center

Tsujimoto Masanaga
Sapporo Heart Center

Tomohiko Watanabe
Sapporo Heart Center

Hidemasa Shitan
Sapporo Heart Center

Takuro Sugie
Sapporo Heart Center

Daisuke Hachinohe
Sapporo Heart Center

Umihiko Kaneko
Sapporo Heart Center

Ken Kobayashi
Sapporo Heart Center

Daitaro Kanno
Sapporo Heart Center

Katsuhiko Sato
Sapporo Heart Center

Tsutomu Fujita
Sapporo Heart Center

Research Article

Keywords: Femoropopliteal artery disease, Endovascular intervention, Chronic total occlusions, Calcified plaque, Peripheral arterial disease, Stent graft, Re-entry.

Posted Date: October 20th, 2021

DOI: https://doi.org/10.21203/rs.3.rs-943788/v1

Version of Record: A version of this preprint was published at CVIR Endovascular on December 1st, 2021. See the published version at https://doi.org/10.1186/s42155-021-00274-y.

Abstract

Background: Vascular calcification is a predictor of poor clinical outcome during and after endovascular intervention. Guidewire crossing techniques and devices have been developed, but chronic total occlusions (CTOs) with severe calcification are still significant challenging lesions in intervention field. We propose a novel guidewire crossing approach combined needle rendezvous with balloon snare technique, named the “needle re-entry” technique, for treatment of complex occlusive lesions.

Main text: A 73-year-old female with severe claudication in her right calf with ankle brachial index of 0.62, and a computed tomography angiogram showed a long occlusion with diffuse calcification in superficial femoral artery. She was referred to our department to have peripheral interventions. Since the calcified vascular wall and nodule of the lesion prevented the successful re-entry with current guidewire crossing matters and devices, the “needle re-entry” was then performed. First, an antegrade 5.0-mm balloon was advanced into a subintimal plane and maintained balloon dilation at 6 atmospheres. Second, an 18-gauge needle was antegradely inserted from distal thigh to the dilated 5.0-mm balloon. After confirming a balloon rupture by the needle penetration, we continued to insert the needle to meet the retrograde guidewire tip. Then, a retrograde 0.014-in. guidewire was carefully advanced into the needle hole, named the “needle rendezvous” technique. After further guidewire advancement to accomplish a guidewire externalization, the needle was removed. Finally, since the guidewire was passing through the 5.0-mm ruptured balloon, the balloon was withdrawn, and the guidewire was captured with the balloon and successfully advanced into the antegrade subintimal space, named the “balloon snare“ technique. After the guidewire was advanced into the antegrade guiding sheath and achieved a guidewire externalization, an endovascular stent graft and an interwoven stent were deployed to cover the lesion. After postballoon dilation, an angiography showed a satisfactory result without complications. No restenosis, reintervention, and limb loss have been observed for one year follow-up period after this technique.

Conclusions: The “needle re-entry” technique is a useful guidewire crossing technique to revascularize femoropopliteal complex CTOs with severe calcification which prevent the achievement of guidewire crossing with the conventional procedures.

Introduction

Vascular calcification are major contributors to interventional revascularization failure in up to 25% for femoropopliteal chronic total occlusions (CTOs) (Scheinert. 2001). Severe calcified burdens negatively affect postprocedural MLA and patency (Fujihara. 2019). Calcification is thought to be a predictor of poor clinical outcome during and after procedure.

Guidewire crossing techniques have been developed, but CTOs, especially with severe calcification, are still challenging lesions in peripheral intervention. Re-entry devices are often used for these lesions (Bausback. 2011) but are not always achievable as expectation. We propose a novel guidewire re-entry approach of combination of needle rendezvous (Haraguchi T. 2021) and balloon snare technique, named

the “needle re-entry (NRE)” technique for complex calcified CTOs with impassable passage by conventional interventional techniques and devices.

Main Text

A 73-year-old female with diabetes mellitus was presented with severe claudication in her right calf. Her right ankle brachial index was 0.62 and a computed tomography angiogram (CTA) showed a long CTO with diffuse calcification in her right superficial femoral artery (SFA). A 7-Fr guiding sheath was percutaneously canulated to establish a crossover fashion from the left common femoral artery. Angiography demonstrated an overview of the lesions as the CTA (Fig. 1a). We intra-arterially injected 5000-IU of unfractionated heparin from the guiding sheath. The antegrade wiring was attempted with several hard guidewires supported with a microcatheter. However, the proximal calcified orifice prevented the guidewire penetration to enter the intraplaque. Therefore, we advanced the 0.035-in. guidewire with a looped wire into the subintimal plane to attempt percutaneous intentional extraluminal recanalization (PIER) technique (Reekers. 1994) (Fig. 1b), but antegrade re-entry failed. The Outback system (Cardinal Health Inc., USA) was used to attempt re-entry, however, its needle could not penetrate the calcified wall of the distal lumen.

Therefore, the antegrade strategy was changed to the retrograde one. We punctured the distal SFA with 20-gauge needle with fluoroscopic guidance and inserted 0.018-in. guidewire with a microcatheter to establish a retrograde fashion (Fig. 1c). The distal calcified cap obstructed the retrograde wiring with the hardest guidewire and looped wire technique (Fig. 1d). Thus, we performed the NRE technique which needle rendezvous technique is combined with balloon snare technique. First, a 5.0-mm balloon was antegradely advanced into the subintimal space and maintained balloon dilatation at 6 atmospheres. The position of retrograde microcatheter below the dilated antegrade balloon was confirmed in ipsilateral view (Fig. 2a), and these devices were overlapped in contralateral view (Fig. 2b). Second, we antegradely inserted an 18-gauge needle from the distal thigh to the dilated 5.0-mm balloon. After a balloon rupture by the needle penetration was confirmed, we continued to insert the needle to pass through the balloon and to meet the retrograde guidewire tip with confirming the correct direction and depth between the tips of the guidewire and the needle in contralateral and ipsilateral views (Fig. 2c). Then, a retrograde 0.014-in. guidewire was carefully manipulated and successfully advanced into the needle hole (Fig. 2d). This technique is named the “needle rendezvous” technique. After further guidewire advancement to accomplish a guidewire externalization, the needle was removed. Finally, since the guidewire was passing through the 5.0-mm balloon, the balloon was withdrawn, and the guidewire was captured with the balloon and successfully advanced into the antegrade subintimal space (Fig. 3a-c). This is the “balloon snare“ technique. After the guidewire was advanced into the antegrade guiding sheath and accomplished a guidewire externalization, we performed the “pave-and-crack” technique (Dias-Neto. 2018) with implanting a 6.0x250-mm stent graft combined with a 6.5x150-mm interwoven stent. After the postballoon dilation with a 7.0-mm noncompliant balloon at highest pressure, an angiography and an intravascular ultrasound finally showed a satisfactory result without complications (Fig. 3d). The

patient's symptom was improved after the procedure, and we have not observed restenosis, reintervention, and limb loss in this patient one year after this technique.

Discussion

This is the first introduction to the NRE technique for guidewire re-entry to recanalize femoropopliteal complex CTOs with severe calcification in this paper, and the process of this technique is shown in the supplementary material (Supplemental movie 1). Several guidewire crossing procedures, such as PIER technique, subintimal arterial flossing with antegrade-retrograde intervention (SAFARI) technique, controlled antegrade and retrograde tracking and dissection (CART), and reverse-CART (Surmely. 2006) improve the technical success of subintimal crossing. Moreover, several re-entry devices have been allowed to use for antegradely crossing the CTOs with a high technical success rate (Bausback. 2011). However, there are still some cases that cannot be solved by the techniques and devices.

Limitations are here. First, the NRE can be achieved in the infrainguinal arteries, but not in the suprainguinal arteries. Second, the NRE cannot be used if an antegrade balloon cannot be advanced into a subintimal plane. Third, if antegrade guidewire does not presents in a subintimal space in the front side of the vessel, our NRE technique will not be applied. While, if antegrade guidewire exists in a subintima in the back side of the vessel, we recommend performing the "poorman's outback (POB)" (Urasawa. 2013). The POB is as follows. An 18-gauge needle is retrogradely inserted from a distal thigh and advanced through a distal lumen to a tip of antegrade wire in an antegrade subintimal plane. After confirming that the needle touches the guidewire tip, we advance the guidewire into the needle hole and remove the needle. Then, the guidewire is controlled to advance into the distal lumen to achieve the re-entry. The representative case treated with POB is in the supplemental material (Supplemental movie 2). Finally, there is a learning curve involved in puncturing through an expanded balloon into a subintimal space to reach a guidewire tip in a distal lumen and in the manipulation of the guidewire to advance into the needle hole.

Conclusions

The NRE technique, which combined the needle rendezvous technique with the balloon snare technique, is a useful re-entry method to revascularize femoropopliteal complex CTOs with severe calcification which prevent the achievement of guidewire crossing. We should perform multi-center study to evaluate the success of recanalization for femoropopliteal occlusions.

Abbreviations

Chronic total occlusion (CTO)

Needle re-entry (NRE)

Computed tomography angiogram (CTA)

Superficial femoral artery (SFA)

Percutaneous intentional extraluminal recanalization (PIER)

Subintimal arterial flossing with antegrade-retrograde intervention (SAFARI)

Controlled antegrade and retrograde tracking and dissection (CART)

Poorman's outback (POB)

Declarations

Ethics approval and consent to participate

Informed consent was achieved. The report followed the declaration of Helsinki of 1964.

Consent for publication

Written informed consent was obtained from the patient for publication of this case report and any accompanying images.

Availability of data and material

The datasets used and/or analyzed during the current study are available from the corresponding author on reasonable request.

Competing interests

The authors declare that they have no competing interests.

Funding

None

Authors' contributions

All authors contributed to the study conception and design. The first draft of the manuscript was written by Takuya Haraguchi and all authors commented on previous versions of the manuscript. All authors read and approved the final manuscript.

Acknowledgements

The authors thank Cassie J. from American Journal Experts (https://www.aje.com), for editing and reviewing this manuscript for English language. Also, we thank for Tanimura T., Itai S., Sawada N., Miyoshi T., as special team member in PAD Center.

References

1. Scheinert D, Laird JR, Schröder M, Steinkamp H, Balzer JO, Biamino G. Excimer laser-assisted recanalization of long, chronic superficial femoral artery occlusions. J Endovasc Ther. 2001;8(2):156-66. doi: 10.1177/152660280100800210.
2. Fujihara M, Kozuki A, Tsubakimoto Y, Takahara M, Shintani Y, Fukunaga M, Iwasaki Y, Nakama T, Yokoi Y. Lumen Gain After Endovascular Therapy in Calcified Superficial Femoral Artery Occlusive Disease Assessed by Intravascular Ultrasound (CODE Study). J Endovasc Ther. 2019;26(3):322-330. doi: 10.1177/1526602819836095.
3. Bausback Y, Botsios S, Flux J, Werner M, Schuster J, Aithal J, Varcoe R, Bräunlich S, Ulrich M, Scheinert D, Schmidt A. Outback catheter for femoropopliteal occlusions: immediate and long-term results. J Endovasc Ther. 2011;18(1):13-21. doi: 10.1583/10-3248.1.
4. Haraguchi T, Tsujimoto M, Kashima Y, Takeuchi T, Tadano Y, Hachinohe D, Kaneko U, Kobayashi K, Kanno D, Sato K, Fujita T. The "Needle bypass" technique: Percutaneous anatomical bypass with needle rendezvous for patients with peripheral arterial disease that have no other surgical options. CVIR Endovasc. 2021 Aug 26;4(1):66. doi: 10.1186/s42155-021-00254-2. PMID: 34436700.
5. Reekers JA, Kromhout JG, Jacobs MJ. Percutaneous intentional extraluminal recanalisation of the femoropopliteal artery. Eur J Vasc Surg. 1994;8(6):723-8. doi: 10.1016/s0950-821x(05)80653-x.
6. Dias-Neto M, Matschuck M, Bausback Y, Banning-Eichenseher U, Steiner S, Branzan D, Staab H, Varcoe RL, Scheinert D, Schmidt A (2018) Endovascular treatment of severely calcified femoropopliteal lesions using the “pave-and-crack” technique: technical description and 12-month results. J Endovasc Ther 25:334–342
7. Surmely JF, Tsuchikane E, Katoh O, Nishida Y, Nakayama M, Nakamura S, Oida A, Hattori E, Suzuki T. New concept for CTO recanalization using controlled antegrade and retrograde subintimal tracking: the CART technique. J Invasive Cardiol. 2006 Jul;18(7):334-8. PMID: 16816442.
8. Urasawa K. (2013) Tokedai style. □□□□□□□EVT□□□□□□ Medical view. pp221-223. Japan.

Figures

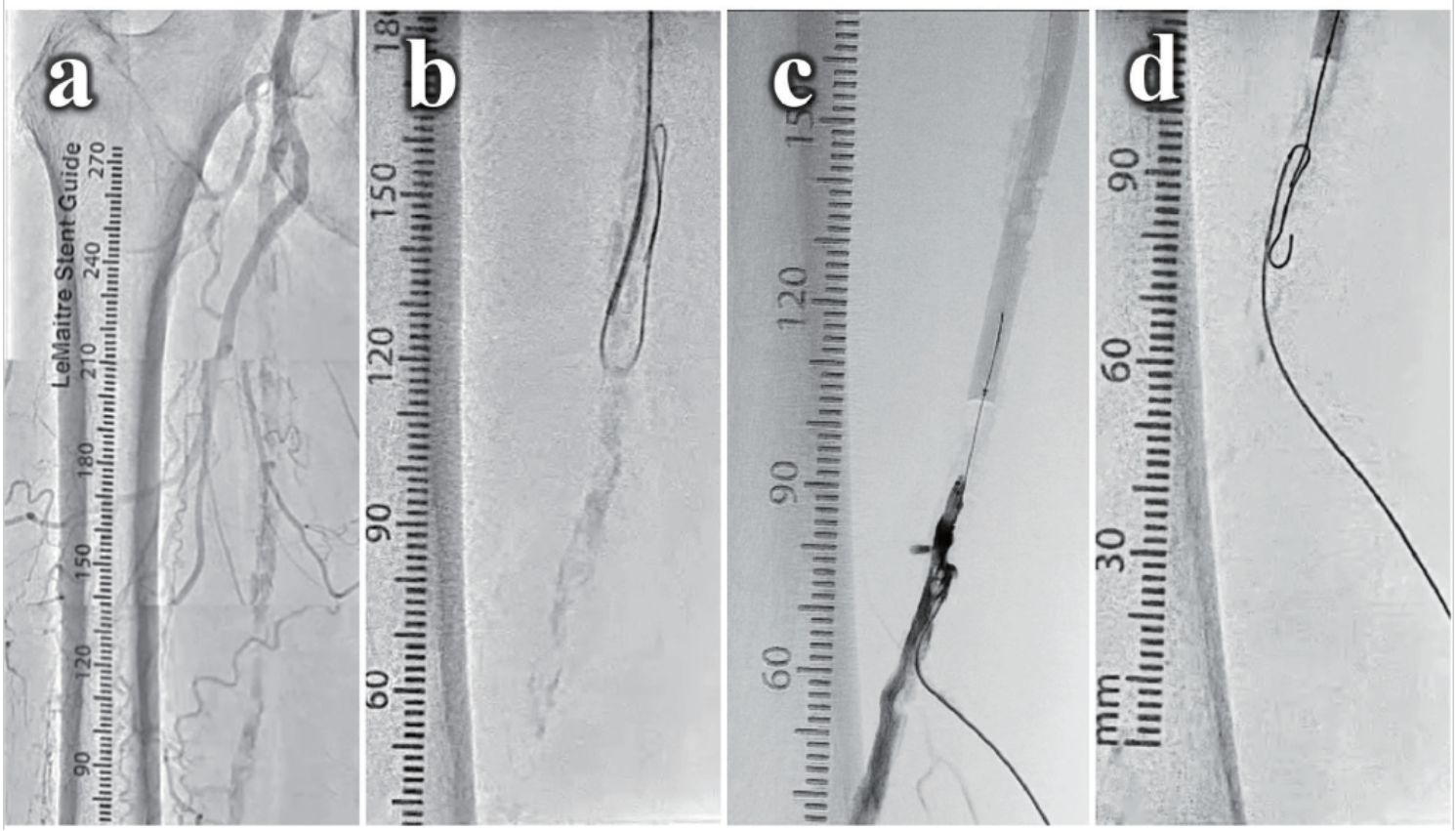

Figure 1

Angiography and the conventional bi-directional approach. a. Control angiography showed the overall lesion (white arrows). b. A 0.035-in. guidewire was antegradely advanced into the subintimal plane to perform percutaneous intentional extraluminal recanalization (PIER) technique, but antegrade re-entry wiring failed. c. The distal SFA was punctured with 20-gauge needle, and 0.018-in. guidewire with a microcatheter was inserted to establish a retrograde fashion, and the distal lumen was revealed by tip injection through the retrograde microcatheter. d. The distal calcified cap obstructed the retrograde wiring with hardest guidewire, and looped wire technique.

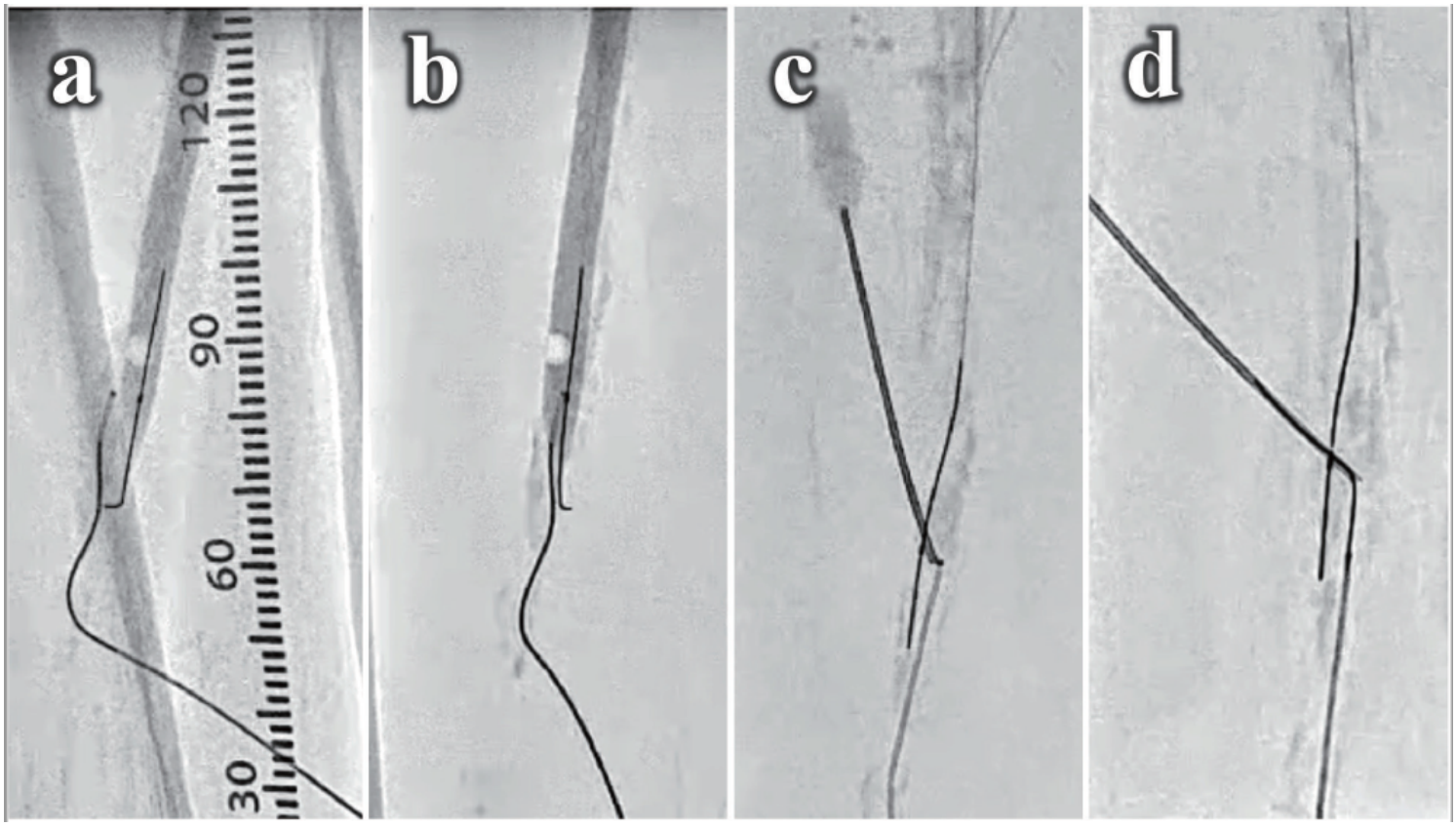

Figure 2

The process of the “needle rendezvous” of the “needle re-entry” technique. a. The retrograde microcatheter in the distal lumen below the dilated antegrade 5.0-mm balloon in the subintimal plane was confirmed in ipsilateral view. b. These devices were overlapped in contralateral view. c. An 18-gauge needle was inserted from the distal thigh to the dilated balloon. After confirming a balloon rupture by the needle penetration, the needle was continued to advance to meet the retrograde guidewire tip. d. A retrograde 0.014-in. guidewire was carefully manipulated and successfully advanced into the needle hole.

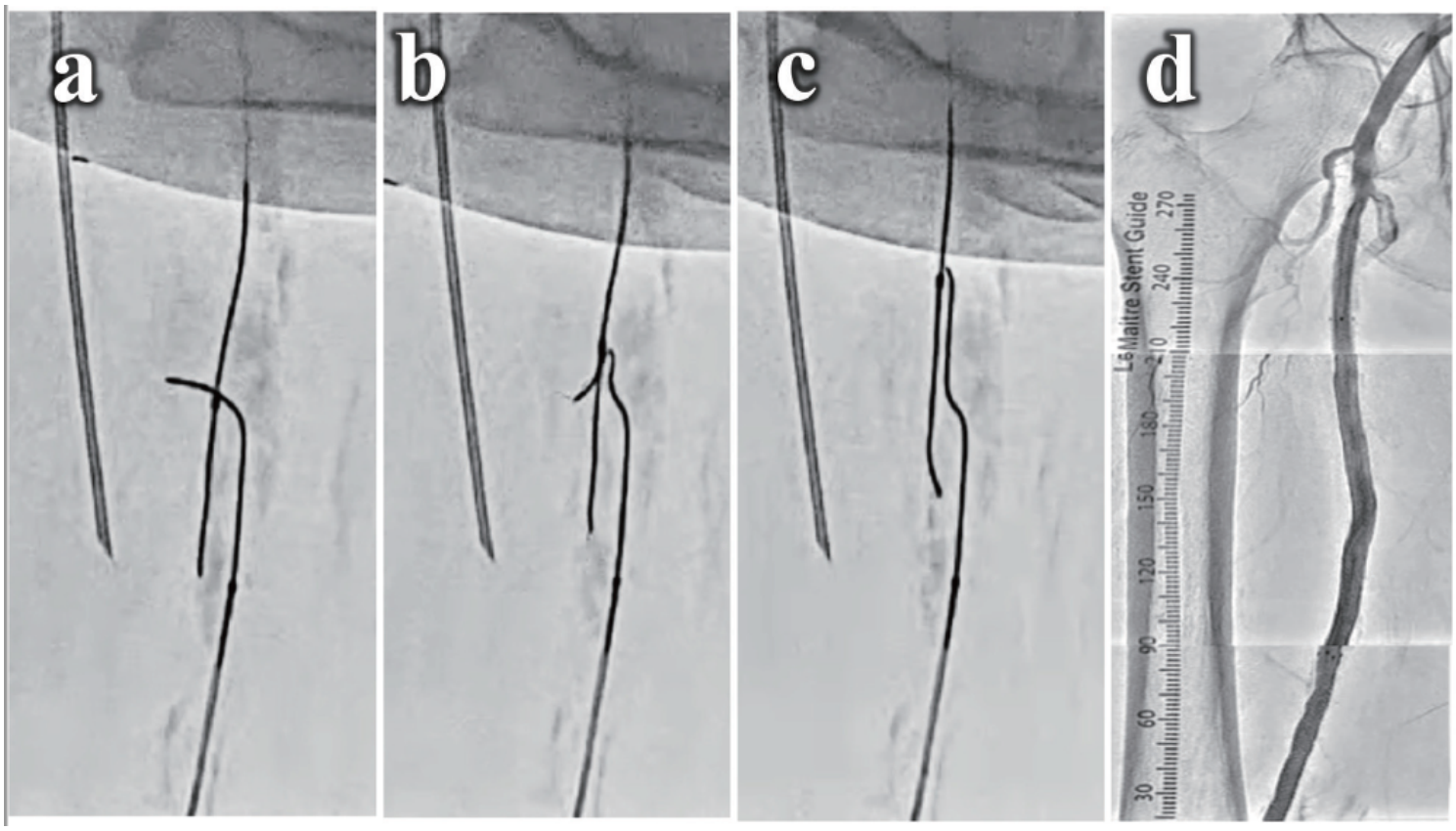

Figure 3

The process of the “balloon snare” of the “needle re-entry” technique. a to c. Since the retrograde guidewire passed into the 5.0-mm balloon, when the balloon was withdrawn, the guidewire was successfully advanced with the balloon into the antegrade subintimal space. d. After the “pave-and-crack” technique was performed, a 6.0x250-mm stent graft combined with a 6.5x150-mm interwoven stent were implanted, final angiography showed a satisfactory result without complications.

Supplementary Files

This is a list of supplementary files associated with this preprint. Click to download.

- Supplementalmovie1.mp4
- Supplementalmovie2.mp4