Neonatal Pneumothoraces With Atypical Location: The Role of Lung Ultrasound

Rebeca Gregorio-Hernández (rebecagh@gmail.com)
Hospital General Universitario Gregorio Marañón: Hospital General Universitario Gregorio Maranon
https://orcid.org/0000-0002-7484-0593

Alba Pérez-Pérez
Hospital General Universitario Gregorio Maranon

Almudena Alonso-Ojembarrena
University of Cadiz: Universidad de Cadiz

María Arriaga-Redondo
Hospital General Universitario Gregorio Marañón: Hospital General Universitario Gregorio Maranon

Cristina Ramos-Navarro
Hospital General Universitario Gregorio Marañón: Hospital General Universitario Gregorio Maranon

Manuel Sánchez-Luna
Hospital General Universitario Gregorio Marañón: Hospital General Universitario Gregorio Maranon

---

Short Report

Keywords: Pneumothorax, lung ultrasound, neonates, ultrasound-guided procedure

Posted Date: October 19th, 2021

DOI: https://doi.org/10.21203/rs.3.rs-949219/v1

Version of Record: A version of this preprint was published at European Journal of Pediatrics on November 29th, 2021. See the published version at https://doi.org/10.1007/s00431-021-04329-z.

Abstract

Neonatal pneumothorax (NP) is a potentially life-threatening condition. Lung ultrasound (LU) has shown higher sensitivity and specificity in diagnosis compared to x-rays, but evidence regarding its usefulness in complex NP is lacking. We report four neonates suffering from cardiac or esophagueal malformations who developed lateral and/or posterior pneumothoraces, in which LU helped, making NP diagnosis and management easier and faster. *In conclusion,* LU is an easy-to-use, fast, simple and accurate tool when evaluating newborns with complex thoracic diseases.

Introduction

Pneumothorax is a life-threatening condition, defined by the presence of air between the two pleural layers. Its prevalence in the neonatal population has been described as 1-6%, increasing with decreasing gestational age (1). Lung ultrasound (LU) has demonstrated higher sensitivity and specificity than conventional x-rays for the diagnosis of pneumothorax in children and neonates(1–4), with GRADE B evidence, according to the latest European Society of Pediatric and Neonatal Intensive Care guidelines regarding point of care ultrasound use (5).

In the critically ill, pneumothoraces are usually located in the anterior area of the thorax. However, in cardiac and thoracic surgery patients or when several drainage procedures are needed, they can be located in non-conventional areas, making assessment and drainage difficult, when based solely on x-rays, even when using lateral views.

We aim to describe several neonatal pneumothoraces (NP) with atypical locations, assessed using LU, in four patients.

Material And Methods

Retrospective review of the LU and x-rays images of four patients with NP with atypical locations (in the lateral or posterior area of the chest, not involving the anterior area) and their management in two tertiary neonatal intensive care units (NICUs) in Spain (Gregorio Marañón University Hospital and Puerta del Mar University Hospital). In both centers LU has been used for more than 5 years to study the respiratory condition of admitted sick neonates. The study period was from January to March 2021 and it was approved by the Gregorio Marañón Hospital Research and Ethics Committee with a waiver of informed consent, and was performed in accordance with the Declaration of Helsinki.

LU was performed by experienced neonatologists as part of the daily care of the patients requiring respiratory support in the NICU, using a Sonosite iViz or a General Electric Vivid IQ ultrasound device, both with linear probe, using lung presets. The focus was positioned at the pleural line, at a depth of 4 cm, no harmonics were used. In every case 6 areas were evaluated: anterior, lateral and posterior in each hemithorax, with the patient in supine position. X-ray images were provided by a pediatric radiologist, who was unaware of the results of the LU.

Results

-Patient 1: Term male newborn with type I esophageal atresia requiring multiple thoracoscopic surgical interventions due to a long-gap atresia. 8 days after the last intervention he suffered a right tension pneumothorax and required a chest drain in the second intercostal space at the midclavicular line. Two days later, he developed acute respiratory distress despite endotracheal intubation and mechanical ventilation. In LU, a hydropneumothorax was observed in the lateral area of right lung despite the previous drainage. The two were related to anastomotic dehiscence. A new ultrasound-guided chest tube was inserted via the seventh intercostal space, obtaining 20 ml of pleural effusion and air, which resolved the respiratory distress.

-Patient 2: Term female newborn, with total anomalous pulmonary venous drainage surgically corrected at 7 days of life (DOL). Due to this surgery, she required bilateral pleuromediastinal drainage for 2 days. At 17 DOL, she was still on mechanical ventilation and was diagnosed with left diaphragmatic paralysis. Plication of the diaphragm was performed, and following surgery, a significant left pneumothorax was diagnosed on posteroanterior (PA) x-rays images, in addition to respiratory worsening. An emergent thoracocentesis was performed via the second intercostal space at the midclavicular line. However, no air was obtained. LU identified normal pattern in the anterior area and located the pneumothorax between anterior and posterior axillary lines, so respiratory support could be optimized (repositioning, volume guarantee increased) and close clinical and ultrasound follow-up was carried out. NP spontaneously resolved without drainage and respiratory situation improved progressively. See table 1.

-Patient 3: Late male preterm infant on mechanical ventilation since birth because of severe pulmonary hypoplasia and congenital hypotonia due to myotonic dystrophy type 1. He needed several drainage procedures because of repeated pneumothoraces in his right lung. At 11 DOL, a pneumothorax between anterior and posterior axillary lines was detected during a control LU, but anterior air and clinical worsening were not observed. Serial LU showed progressive worsening of air leak (lung point moved towards anterior area) along with respiratory deterioration, so finally the thoracic drain was reinserted 15 hours after the first LU, with subsequent resolution of the pneumothorax, according to LU and x-rays images.

- **Patient 4**: Late male preterm infant with type III esophageal atresia corrected on the second DOL. On the eighth DOL, he developed sudden respiratory and hemodynamic deterioration due to a NP in the right hemithorax, despite the previously inserted surgical drainage. It was successfully drained using a new chest tube via the fourth intercostal space. Two days later, the NP could still be seen on x-rays images, so an anterior thoracocentesis was performed with the aim of achieving successful extubation, but the NP was not resolved. LU showed a NP in the posterior and lateral areas of the left thorax, with lateral subcutaneous emphysema (Figure 1). This finding avoided a new pleural drain, and the NP resolved spontaneously, without specific treatment. The chest drain was finally removed after 12 days, because the infant also suffered secondary chylothorax.

Discussion

These cases highlight the importance of evaluating NP using LU in the critically ill neonate in order to plan management, particularly with surgical patients or those with several drainage interventions.

We have reported 4 neonates with complex diagnoses. All had in common prior manipulation of the chest (cardiac/esophageal surgery or previously inserted pleural drainage). LU optimized management in all of them: In patient 1, detailing the amount of pleural effusion and air, and permitting an ultrasound-guided technique. In patients 2 and 4, demonstrating that anterior thoracocentesis is not always the best solution. In patients 2 to 4, it permitted dynamic, close control of evolution in order to decide on the best therapeutic approach.

LU is an easy to use examination, which is quick, cheap, free of ionizing radiation, and can be performed by the same clinician attending the patient (6). Several studies have demonstrated a steep learning curve; shorter than for other uses of point-of-care ultrasound (7).

Classically, chest x-ray has been the gold standard for diagnosis in the sick newborn with respiratory diseases. However, LU has demonstrated a higher sensitivity and specificity in several diseases, and the typical pattern of almost all neonatal lung diseases have already been described (5, 8).

Typical findings of pneumothorax in LU are: A-lines pattern, absence of lung sliding and B-lines, together with lung point identification. The latter has a 100% specificity, and it should be systematically identified in order to confirm the diagnosis (4). Stratosphere sign on M-mode, as a surrogate sign of the absence of pleural sliding, can be identified (9, 10). Experience is needed in order to rule out some ultrasonographic findings which could be misinterpreted (11).

In the critically ill patient, in supine position, the air is usually located in the anterior part of the chest and, as the amount of air increases, the lung point moves towards the patient's back, until its disappearance in massive pneumothoraces(12). However, in our cases, no air was identified in the anterior area, and instead two lung points were seen, limiting the pneumothorax to the lateral/posterior area. We hypothesized that, in the event of worsening, each lung point would move towards anterior and posterior areas respectively, although this assumption has not been analyzed previously, to the best of our knowledge.

This kind of NP with atypical location in the lateral or posterior area of the chest can occur when interventions have previously been performed on the thorax (cardiac surgery, pleural drainage, etc.), leading to pleural adherences that limit the free movement of the air between the two layers. In x-rays, this fact can be difficult to assess, due to the “2-dimensional image” obtained, unless performing an x-ray with lateral views (exposing the child to extra radiation and often risky manipulation). However, this task is very easy to achieve using LU, defining the precise location of the lung point, reducing radiation, and increasing the safety of the procedures performed in newborns, such as emergent thoracocentesis and drainage insertion(6, 13–15).

In addition to studying its location, LU is useful for checking pneumothorax resolution following pleural drainage insertion, and to serially confirm evolution before removal (4): its use has also been related to shortened hospital stays in newborns (15). In our experience, it is a useful instrument for monitoring the patient and anticipating any clinical deterioration.

In conclusion, this study stresses the importance of LU in the management of a neonate with suspected pneumothorax, particularly in complex patients with previous thoracic manipulation, as previously described in some clinical-ultrasound protocols as SAFE (Sonographic Assessment of liFe-threatening Events) algorithm(6).

Long experience of researchers in the use of LU and retrospective analysis are potential limitations of this study; however, we consider that the results are relevant and objective, and create an interesting area for further research.

More studies are needed in order to confirm our findings and hypothesis, so a better understanding of pneumothorax physiopathology in this critical population can be described.

References

1. Fei Q, Lin Y, Yuan TM (2021) Lung Ultrasound, a Better Choice for Neonatal Pneumothorax: A Systematic Review and Meta-analysis, vol 47. Ultrasound in Medicine and Biology. Elsevier Inc., pp 359–369
2. Dahmarde H, Parooie F, Salarzaei M (2019) Accuracy of Ultrasound in Diagnosis of Pneumothorax: A Comparison between Neonates and Adults - A Systematic Review and Meta-Analysis. Can RespirJ 2019:5271982
3. Gao YQ, Qiu RX, Liu J, Zhang L, Ren XL, Qin SJ. Lung ultrasound completely replaced chest X-ray for diagnosing neonatal lung diseases: a 3-year clinical practice report from a neonatal intensive care unit in China. J Matern Neonatal Med. 2020
4. Liu J, Kurepa D, Feletti F, Alonso-Ojembarrena A, Lovrenski J, Copetti R et al. International expert consensus recommendations for neonatal pneumothorax ultrasound diagnosis and ultrasound-guided thoracentesis procedure. J Vis Exp. 2020 Mar 1;2020(157)
5. Singh Y, Tissot C, Fraga MV, Yousef N, Cortes RG, Lopez J et al (2020) International evidence-based guidelines on Point of Care Ultrasound (POCUS) for critically ill neonates and children issued by the POCUS Working Group of the European Society of Paediatric and Neonatal Intensive Care (ESPNIC). Crit Care. Dec 24;24(1):65
6. Raimondi F, Yousef N, Migliaro F, Capasso L, De Luca D (2018) Point-of-care lung ultrasound in neonatology: classification into descriptive and functional applications [published online ahead of print, 2018 Jul 20]. Pediatr Res. Jul 20;1-8
7. Andersen CA, Holden S, Vela J, Rathleff MS, Jensen MB (2019 Jan) Point-of-Care Ultrasound in General Practice: A Systematic Review. Ann Fam Med 17(1)(1):61–69

8. Kurepa D, Zaghloul N, Watkins L, Liu J. Neonatal lung ultrasound exam guidelines. J Perinatol. 2018 Jan 16;38(1):11–22
9. Raimondi F, Rodriguez Fanjul J, Aversa S, Chirico G, Yousef N, De Luca D et al (2016) Lung Ultrasound for Diagnosing Pneumothorax in the Critically Ill Neonate. J Pediatr. Aug 1;175:74-78.e1
10. Avila J, Smith B, Mead T, Jurma D, Dawson M, Mallin M et al (2018) Does the addition of M-mode to B-mode ultrasound increase the accuracy of identification of lung sliding in traumatic pneumothoraces? J Ultrasound Med. Nov 1;37(11):2681–7
11. Skulec R, Parizek T, David M, Matousek V, Cerny V (2021 May) Lung Point Sign in Ultrasound Diagnostics of Pneumothorax: Imitations and Variants. Emerg Med Int 28:2021:1–7
12. Sharma D, Farahbakhsh N (2019 Jan) Role of chest ultrasound in neonatal lung disease: a review of current evidences. J Matern Neonatal Med 17(2):310–316 32(
13. Lichtenstein D, Mezière G, Biderman P, Gepner A (2000 Oct) The lung point: an ultrasound sign specific to pneumothorax. Intensive Care Med 26(10):1434–1440
14. Gray EJ, Cranford JA, Betcher JA, Huang RD, Kessler RA, Theyyunni N et al (2020 Jul) Sonogram of safety: Ultrasound outperforms the fifth intercostal space landmark for tube thoracostomy site selection. J Clin Ultrasound 48(6)(1):303–306
15. Szymońska I, Wentrys Ł, Jagła M, Olszewska M, Wasilewska W, Smykla B et al (2019) Lung ultrasound reduces the number of chest X-rays in newborns with pneumothorax. Dev Period Med XXIII(3):178–183

Tables

Due to technical limitations, table 1 is only available as a download in the Supplemental Files section.

Figures

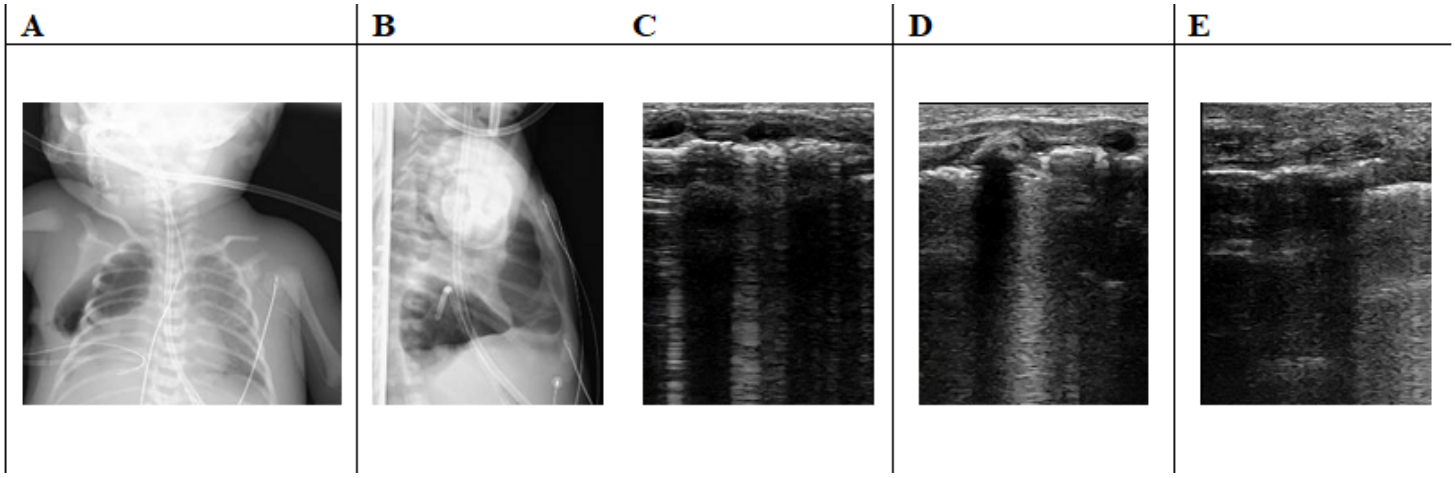

Figure 1

Patient 4. A: PA x-rays, subcutaneous emphysema and pneumothorax. B: Lateral x-rays, pneumothorax in the right posterior area. C, D: LU, right anterior and lateral areas with no pneumothorax. E: Subcutaneous emphysema in the lateral field (we may see pleural line, but not ribs). LU: lung ultrasound, PA: posteroanterior.

Supplementary Files

This is a list of supplementary files associated with this preprint. Click to download.

- Table1.docx