First Case Report of Cholesterol Granuloma of Femur

Shenshen Hao
General Hospital of Pingmeishenma Medical Group https://orcid.org/0000-0002-3818-3258
Shengli Dong
General Hospital of Pingmeishenma Medical Group
Hongke Li
General Hospital of Pingmeishenma Medical Group
Shuaizhi Li
General Hospital of Piengmeishenma Medical Group
Huihui Ren
General Hospital of Pingmeishenma Medical Group
Xiaohui Luo
General Hospital of Pingmeishenma Medical Group
Shuai Liu
General Hospital of Pingmeishenma Medical Group
Honglei Chen
General Hospital of Pingmeishenma Medical Group
Zhifang Zhang
General Hospital of Pingmeishenma Medical Group
Fangshu Zhang (1021770836@qq.com)
The Third People's Hospital of Henan Province

Research article

Keywords: Cholesterol granuloma, Femur, First report, Case report

Posted Date: October 13th, 2021

DOI: https://doi.org/10.21203/rs.3.rs-954012/v1

Abstract

Introduction: Cholesterol granuloma (CG) is a special type of granulation tissue reaction. It is a very rare benign lesion with swelling growth, in which there are a large number of cholesterol crystals and foreign body giant cells. A small amount of literature reports that it occurred in the middle ear or mastoid area. There has been no report of CG of the femur.

Methods: A 74-year-old woman suffered from pain and discomfort in the upper right knee for 10 years, which aggravated for 10 days. He was diagnosed with CG of the right femur in our hospital, and was treated with surgery.

Results: During the operation, a large amount of yellow-brown oily crystal structure was found, and the pathology after the operation was confirmed as CG. The postoperative follow-up was 3 months, and the treatment effect was satisfactory.

Conclusion: CG of the femur is an extremely rare benign lesion, and there is no relevant report. Surgical treatment can remove the diseased tissue and provide effective treatment results.

Introduction

Cholesterol granuloma (CG) was a benign lesion with swelling growth[1]. Multiple parts of the body might appear, and the systemic incidence rate was 1/300,000-1/200,000, of which temporal bone was the most common[2]. According to reports, CG could be formed in various parts of the human body, such as thyroid[3], lung[4], breast[5], mediastinum[6], testis[7], pancreas[8], eyes[9], kidney[10], peritoneum[11], lymph nodes [12], facial bones[13] and temporal bones[14].

CG was rarely reported in the bones of the limbs, and some scholars have reported case reports in the humerus [15] and radius[16]. There has been no report of CG in the femur. We admitted a patient with CG of the femur and treated it with surgery, and followed up for 3 months after the operation. In view of its rarity, we reported on it for the first time to get a preliminary understanding of its pathological characteristics and its occurrence process. We hope that it may provide some reference to scholars who study CG.

Case Presentation And Surgical Technique

A 74-year-old female patient, height 160cm, weight 60kg, admitted to our hospital with the chief complaint of "right knee pain and discomfort for 10 years, and aggravation for 10 days." The patient had no obvious cause to experience right knee pain 10 years ago, slightly restricted activity, no dizziness and headache, no fever and night sweats, no chest tightness and palpitations, no hematuria and urinary pain, no symptoms such as weakness of both lower limbs. First, after a rest, her symptoms persisted. Then, she received symptomatic and conservative treatments such as anti-inflammatory and pain relief, physical therapy, etc. The specifics were unknown, and the symptoms were alleviated. Symptoms

recurred during the period, sometimes light and sometimes severe. Until 10 days ago, her pain symptoms were repeated and significantly worse than before, accompanied by limited mobility. Conservative treatment was still chosen, and the symptoms did not alleviate. The physical examination revealed that the skin of the right knee was intact and not damaged, and there was no redness or swelling. There was no obvious abnormality in the skin temperature. There was tenderness and percussion pain in the right knee. The right knee was accompanied by a slight limitation of movement. There was no obvious abnormality in the right lower limb. There was no edema in the right lower limb, and the peripheral blood supply was normal. X-ray examination revealed that the distal end of the right femur was a multilocular cystic low-density focus with hardened edges (Fig. 1). Computed tomography (CT) examination revealed that there were multiple cystic low-density shadows in the lower part of the right femur, with clear borders, sclerosis margins around, and no obvious abnormalities in adjacent soft tissues (Fig. 2). Magnetic resnane iamge (MRI) examination revealed multiple cystic abnormal signal shadows in the lower right femur and the surrounding soft tissues had no special changes (Fig. 3). The contrast enhanced MRI examination showed that there were multiple cystic abnormal signal shadows in the lower right femur, the contrast enhancement scan of the lesion was not obvious, and the surrounding soft tissues had no special changes (Fig. 4). Laboratory examination results showed that red blood cells were 3.85×10^{12}/L, cholesterol was 5.22mmol/L, prothrombin time was 12.20s, prothrombin time activity ratio was 88.00%, international normalized ratio was 1.14, actived partial thromboplastin time was 24.70s, and thrombin time was 16.20s. These indicators were all within the normal range. She had a history of hypertension for 20 years, took 20mg of "nifedipine sustained-release tablets" orally once a day. The blood pressure was controlled within the normal range. She also had a history of hyperthyroidism for more than 10 years. 3 months ago, she started to took 10mg of "methimazole tablets" orally three times a day, and changed to twice a day with the same dose one and a half months ago. The thyroid function was in the normal range. Therefore, our diagnosis was 1. CG of the right femur, 2. Right knee osteoarthritis, 3. Hypertension, 4. Hyperthyroidism.

The patient underwent surgery after complete preoperative preparation. It was mainly divided into two steps. The first was to take the left iliac bone for intraoperative bone grafting. The second was surgery on the part of the femur where CG lesions occurred. The specific steps of the latter were as follows. A 15cm longitudinal incision was made on the inner side of the distal right thigh. The skin and subcutaneous tissue was cut in turn, and then the medial femoral condyle and the proximal femur were exposed after cutting and separating along the muscle space. The position of the knee joint space was given priority to determine via a syringe needle to protect the joint capsule, and then the medial condyle of the distal femur and the distal third of the femoral shaft were exposed. Gauze soaked in distilled water was placed around the incision to prevent the diseased tissue from contaminating the normal tissue. A window of approximately (2~4)cm×7cm was opened on the medial cortical bone corresponding to the CG lesion with an electric drill and a narrow bone knife, and then the diseased cortical bone was removed. A large number of yellow-brown oily crystal structures could be seen(Fig. 5). The diseased bone ridges scraped off by the drill. The coagulation function of the electric knife was adjusted to spray coagulation mode, that is, the output power was 80 Joule units, and each bone wall was carefully burnt. 80 degrees distilled

water was used to rinse the marrow cavity and bone wall. The above process was alternated three times to achieve the effect of killing diseased cells. Then the surgical area was replaced with a new sterile surgical drape. After the surgeon had changed new sterile gloves, the medullary cavity and bone wall of the femur were treated again with an electric knife and distilled water. The ilium taken in the first step was implanted near the articular surface of the CG lesion to increase the bone mass in the femoral condyle area, and the remaining cavity was filled with high-viscosity bone cement. An anatomical titanium plate was placed on the inner side of the distal femur and fixed with 9 screws. After repeated washing of the incision with normal saline, adequate hemostasis and placement of a drainage tube, the wound was sutured and bandaged under pressure.

The pathological examination of the diseased tissue taken out during the operation showed that new bone was seen under the microscope, cystic degeneration was seen around it, powder-stained no structure was seen in the cyst cavity, and a large number of cholesterol crystals were seen in it (Fig. 6). X-ray examination of the right femur was performed on the first week after the operation, and the results showed that the bone morphology of the distal right femur was satisfactory, and the internal fixation position was satisfactory (Fig. 7). X-ray examination was performed at the third month of postoperative follow-up, and the results showed that the bone quality of the distal right femur was unchanged, the shape was satisfactory, and the internal fixation position was satisfactory (Fig. 8). At this time, the patient's right knee pain symptoms and restricted activity had been significantly improved.

Discussion

CG is a term of histology, which is a special type of granulation tissue reaction. It is the result of the body's cellular response to cholesterol crystal foreign bodies produced by the decomposition of blood and local tissues. CG is often yellowish-brown sludge under naked eye observation. A large number of cholesterol crystals with diamond-shaped fissures could be seen under microscopy. There are foreign body multinucleated giant cells, macrophages, tissue cells and a large number of lymphocytes, fibrin and abundant blood vessels, and there are black particles of hemosiderin in between. Because this blood vessel is easy to rupture, fresh or old bleeding can be seen at the same time. Therefore, CG lesions were characterized by rhomboid or rhombic cholesterol crystals in chronic inflammatory granulation tissue, surrounded by foreign body giant cells, often fresh or old bleeding, accompanied by hemosiderin[17].

Since CG is a very rare disease, the current research reports are mostly case reports. Among them, the most common report of CG was related to petrous apex, so the hypothesis of its pathogenesis was also based on it. There were two main types: the classic obstruction-vacuum hypothesis and the exposed marrow hypothesis[18]. Zheng Wenkui et al. reported a case of CG of the humerus, and tried to give a preliminary description of its possible formation process[15]. Since both the humerus and femur belong to the upper bone in the skeletal structure of the limbs, they have certain similarities in structure and function. Therefore, we guess that the two may also have a certain similarity in the formation process of CG. Therefore, when we try to describe the CG formation process of the femur, refer to his description of the process of the humerus.

Our patient was an elderly woman, so her femoral bone marrow was mainly yellow bone marrow, and the main component of the marrow was fat tissue. On the one hand, the formation of CG could not be separated from the accumulation of cholesterol. The yellow bone marrow in the femur was rich in fat tissue that broken down to produce cholesterol. This undoubtedly provided a prerequisite for the formation of CG. On the other hand, the formation of CG was also closely related to blood, because blood could also provide a sufficient source of cholesterol. Generally speaking, when cholesterol crystals appeared in the femur as a foreign body, the body's immune response was that phagocytes engulfed it. Therefore, under normal circumstances, a small amount of cholesterol crystals were produced and CG was not formed. However, when the rate of production of cholesterol crystals increased and the rate of output exceeded the speed of the body's phagocytosis, this situation would inevitably lead to the accumulation of cholesterol crystals, resulting in a continuous increase in its volume. At this time, the body's response was to unite the phagocytic cells to form a new type of cell, that was, the foreign body giant cell. When an increasing number of these new cells slowly surrounded the cholesterol crystals, their phagocytosis became relatively weak, to some extent. It was worth noting that there was a self-promoting phenomenon in the formation of CG. It was because blood was an important source of cholesterol, but bleeding often occurred in CG. The formation of CG was often accompanied by blood vessel proliferation, and most of these blood vessels were pathological types of blood vessels, which were easy to rupture and bleeding; bleeding leaded to the continuous increase of cholesterol content, while red blood cells continued to degenerate and decompose to produce cholesterol crystals, which stimulated the foreign body, leading to further aggravation of bleeding and inflammation; eventually a hemorrhage-inflammation malignant circulatory system was formed[19]. Theoretically, patients with CG should have higher serum cholesterol levels than normal. However, by consulting the reported cases in the literature, the patient's serum cholesterol was in the normal range, and there was no systemic bleeding factor[20]. Our patient's serum cholesterol was also in the normal range. Therefore, we believed that there was a possibility that the key role in the formation of CG was the ability to produce cholesterol locally in the lesion, and it was not directly related to serum cholesterol content or coagulation disorders.

CG was not only a very rare disease; it was also a disease that was not easily detected because of its milder clinical symptoms and slow progress. Therefore, when CG occurred in the distal femur, the initial symptoms were mainly mild pain, which had similar symptoms to common knee arthritis and was easily misdiagnosed or missed. Our patient had a history of as long as 10 years. Because of the pain in the knee joint, he had been diagnosed with knee arthritis and chosen to use symptomatic analgesia and other treatments. At the same time, because the pain symptoms were not very serious and had not yet reached the level of affecting their lives, she only had received knee arthritis treatment instead of MRI examination. It also suggested that it was difficult to find the CG lesions of the femur in the early stage, and it was easy to be concealed by other diseases of adjacent tissues.

MRI had certain advantages in distinguishing normal tissues from diseased tissues. Therefore, it was a wise choice to perfect the relevant examination of MRI when the disease could not be clearly defined. CG had special performance on MRI images with diagnostic and differential diagnosis value, such as performance on T1 and T2 weighted images-high signal and no enhancement or only slight peripheral

enhancement signal[21]. After we performed MRI and contrast enhanced MRI examinations on the patients, we also got similar results with diagnostic value. Because the CG of the femur developed slowly and was localized in the bone marrow cavity, the bone quality of the femur began to be slightly damaged only after a long period of the disease. Therefore, during X-ray examination, generally only local bone destruction could be found, and there was no special phenomenon other than that. This X-ray appearance was very similar to bone cysts, which needed to be differentiated. However, the transmittance of X-ray film of bone cyst was higher[15]. Generally speaking, pathological examination was the most important examination for diagnosing the CG of the femur, and a large amount of cholesterol crystals could be seen. We treated the disease for the first time via surgery and finally achieved satisfactory results. The reason for choosing surgery was because CG had already caused a certain amount of damage to the structure of the femur. Moreover, after 3 months of follow-up, the patient still maintained satisfactory feedback, indicating that the surgical treatment was correct. Therefore, we believed that for the treatment of CG of the femur, surgery should be the main treatment method when there was bone damage.

In short, we reported this case for two purposes. First, CG was a rare disease, and most of the literature reports were based on case reports. There has been no report on CG of the femur. Second, it was the first time that we had reported on the CG of the femur, so we hoped that our report could provide some references for scholars who were studying CG. Meanwhile, our research also had shortcomings, especially the few references and materials that could be sought, which inevitably leaded to shortcomings in the research results. If there were any deficiencies, scholars were also asked to correct me.

Abbreviations

CG: Cholesterol granuloma; CT: Computed tomography; MRI: Magnetic resnane iamge.

Declarations

Funding

None.

Availability of data and materials

All data and materials during this study are included in this article.

Author’s contributions

SH wrote the first draft of the article. FZ critically reviewed and edited drafts. SD diagnosed the patients. SH and HL treated the patient. SL and SL have made substantial contributions to the conception and designed of the manuscript. HR, XL, HC and ZZ followed up the patients. All authors read and approved the final manuscript.

Ethics approval and consent to participate

Not applicable.

Consent to publish

The patient gave oral consent for publication of this case report.

Competing interests

The authors declare that they have no competing interests.

References

1. Mafee MF, Kumar A, Heffner DK. Epidermoid cyst (cholesteatoma) and cholesterol granuloma of the temporal bone and epidermoid cysts affecting the brain. Neuroimaging Clin N Am. 1994;4:561–78.
2. Liu X, Mei L, Lu S, Cai X. A case of giant cholesterol granuloma of temporal bone and literature review. Chin J Otol. 2021;19:174–6.
3. Noda K, Kodama S, Uemura N, Suzuki M. A rare case of cholesterol granuloma in the thyroid without an abnormality of lipid metabolism. Auris Nasus Larynx. 2010;37:134–6.
4. Wada H, Sakashita T, Shigemori W, Nagao T, Nakano Y. A case of pulmonary cholesterol granuloma: an (18)F-fluorodeoxyglucose positron emission tomography image. Am J Med Sci. 2012;344:414–5.
5. Khan R, Narula V, Jain A, Maheshwari V. Cholesterol granuloma of the breast mimicking malignancy. *BMJ Case Rep.* 2013; 2013.
6. Drury NE, Smith DN, Phillips LM, Trotter SE, Kalkat MS. Cholesterol granuloma of the anterior mediastinum. Thorax. 2017;72:671–2.
7. Unal D, Kilic M, Oner S, Erkinuresin T, Demirbas M, Coban S, Aydos MM. Cholesterol granuloma of the paratesticular tissue: A case report. Can Urol Assoc J. 2015;9:E390–2.
8. Jung CW, Kim BJ, Park SO, Jo AR, Ha JK, Park SK, Kim HS. A case of cholesterol granuloma in pancreas. Korean J Gastroenterol. 2011;58:353–6.
9. Yan J, Cai Y, Liu R, Lin J, Li J. Cholesterol granuloma of the orbit. J Craniofac Surg. 2015;26:e124–6.

10. Thevendran G, Al-Akraa M, Powis S, Davies N. Cholesterol granuloma of the kidney mimicking a tumour. Nephrol Dial Transplant. 2003;18:2449–50.
11. al-Amer AF, Walia HS, Madda JP. Cholesterol granuloma of the peritoneum. Can J Surg. 1990;33:410–3.
12. Sa YJ, Hwang SJ, Sim SB, Lee SH, Moon SW, Park CB. Cholesterol granuloma: a rare benign rib tumor. Ann Thorac Surg. 2013;95:1801–3.
13. Alghulikah A, Musallam N, Sumaily I, Fathaddin A, Aldossary S. Cholesterol Granuloma of the Maxillary Sinus-A Case Report and Literature Review. Allergy Rhinol (Providence). 2021;12:2152656720984785.
14. Sweeney AD, Osetinsky LM, Carlson ML, Valenzuela CV, Frisch CD, Netterville JL, Link MJ, Driscoll CL, Haynes DS. The Natural History and Management of Petrous Apex Cholesterol Granulomas. Otol Neurotol. 2015;36:1714–9.
15. Zheng W, Wang H, Zhang J, Wang C, Jiao J. A case report of cholesterol granuloma of proximal humerus. Chin J Orthop. 2010;30:529–9.
16. Aoki T, Watanabe H, Aoki J, Fukuda T, Shinozaki T, Sano K, Takagishi K. Intraosseous cholesterol granuloma of radius showing a lamellar structure on MR images: a case report. Radiat Med. 2001;19:203–8.
17. Friedmann I, Graham MD. The ultrastructure of cholesterol granuloma of the middle ear: an electron microscope study. J Laryngol Otol. 1979;93:433–42.
18. Jackler RK, Cho M. A new theory to explain the genesis of petrous apex cholesterol granuloma. Otol Neurotol. 2003;24:96–106. discussion 106.
19. Hiraide F, Inouye T, Miyakogawa N. Experimental cholesterol granuloma. Histopathological and histochemical studies. J Laryngol Otol. 1982;96:491–501.
20. Huang Y, Sun G, Zhou S, Zheng H, Li Z, Zhang S. Cholesterol granuloma of the maxillary antrum with extensively bony destruction. J Preclin Med Coll Shandong Univ. 2002;16:209–10.
21. Fu M, Meng C, Song X. Bilateral huge cholesterol granuloma of the temporal bone(A case report and review of literature). Chin J Otorhinolaryngol-skull Base Surg. 2002;8:18–20.

Figures

Figure 1

Preoperative radiographies (panels A and B). Panels A and B correspond to the preoperative anterior and lateral positions, respectively, indicating that the distal end of the right femur was a multilocular cystic low-density focus with hardened edges.

Figure 2

Preoperative CT films (panels A and B). Panels A and B correspond to the preoperative sagittal and horizontal cross-sectional images respectively, indicating that there were multiple cystic low-density shadows in the lower part of the right femur, with clear borders, sclerosis margins around, and no obvious abnormalities in adjacent soft tissues.

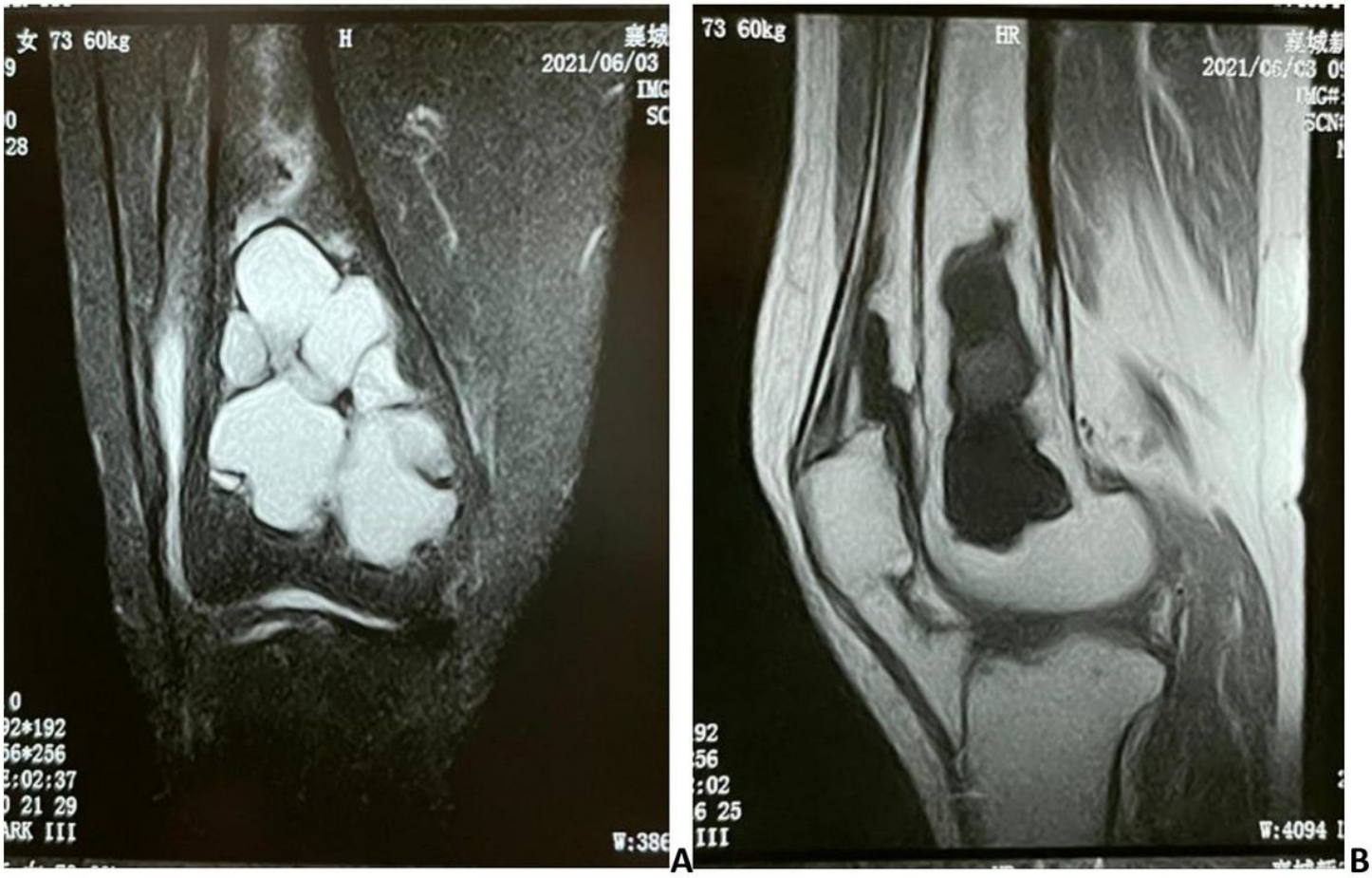

Figure 3

Preoperative MRI films (panels A and B). Panels A and B correspond to the preoperative frontal and sagittal cross-sectional images respectively, indicating that there were multiple cystic abnormal signal shadows in the lower right femur and the surrounding soft tissues had no special changes.

Figure 4

Preoperative contrast enhanced MRI films (panels A, B and C). Panels A, B and C correspond to the preoperative frontal, sagittal and the horizontal cross-sectional images respectively, indicating that there were multiple cystic abnormal signal shadows in the lower right femur, the contrast enhancement scan of the lesion was not obvious, and the surrounding soft tissues had no special changes.

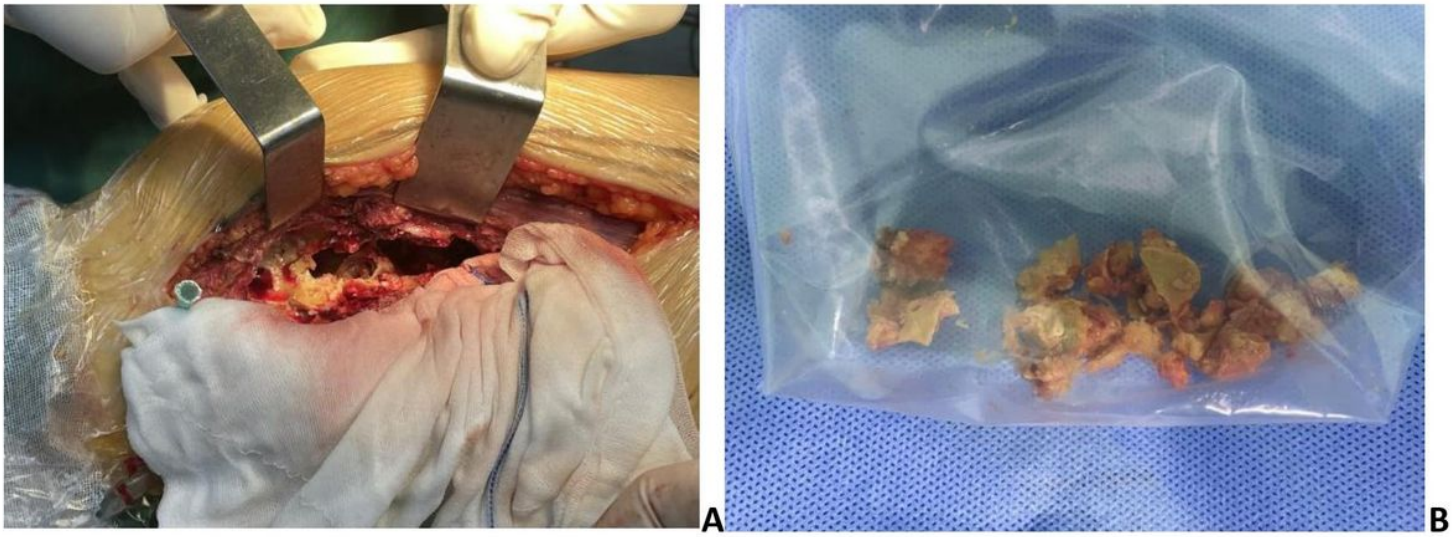

Figure 5

The surgery for removing of CG films (panels A and B). Panel A depicts that after the femur was opened, the bone marrow cavity was filled with CG. Panel B shows a part of CG removed from the right femur.

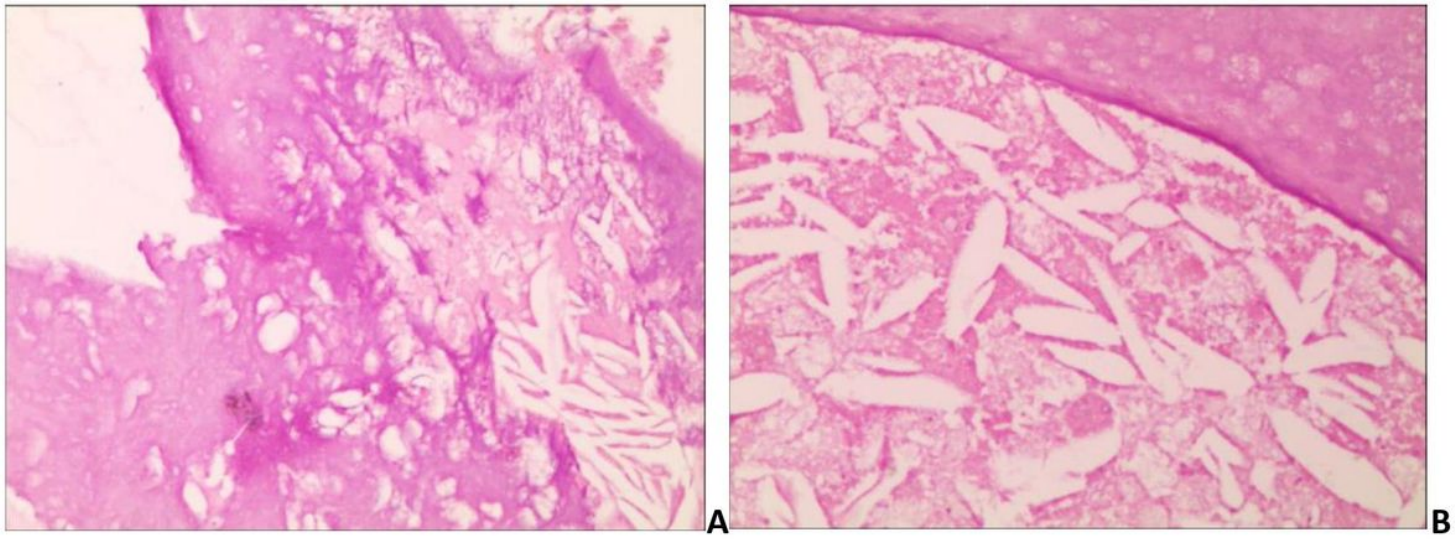

Figure 6

Postoperative pathological examination films(panels A and B). Panels A and B depict that new bone was seen under the microscope, cystic degeneration was seen around it, powder-stained no structure was seen in the cyst cavity, and a large number of cholesterol crystals were seen in it.

Figure 7

Postoperative radiographies(panels A and B). Panels A and B correspond to the first week of the postoperative anterior and lateral positions respectively, showing that the bone morphology of the distal right femur was satisfactory, and the internal fixation position was satisfactory.

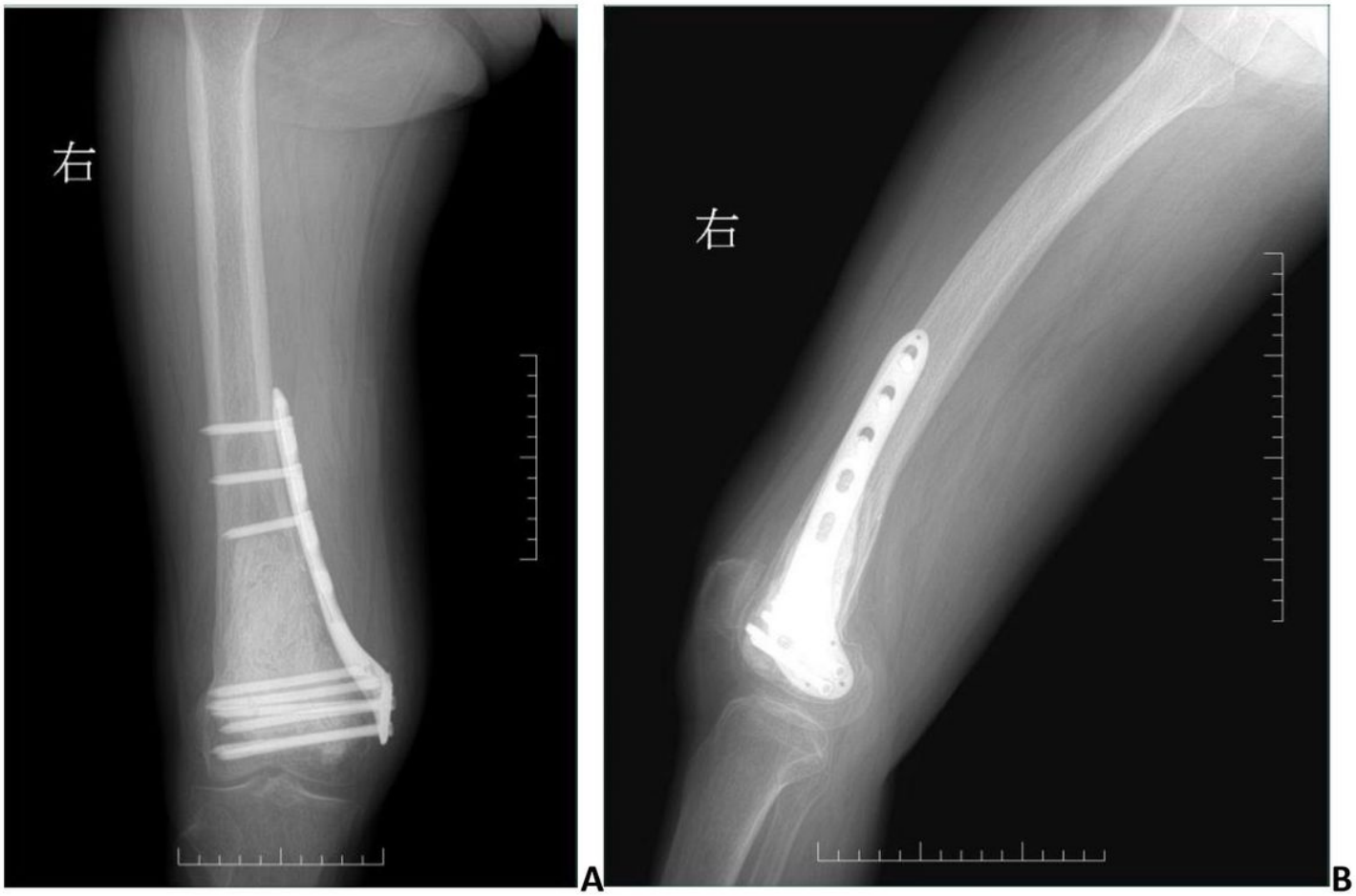

Figure 8

Postoperative radiographies taken on 3 months postoperatively (panels A and B). Panels A and B correspond to the third month of the postoperative anterior and lateral positions respectively, showing that the bone quality of the distal right femur was unchanged, the shape was satisfactory, and the internal fixation position was satisfactory.