Diagnostic Performance of CTA and vessel wall MR imaging in Carotid webs—A Retrospective Study

Hanpei Zheng
Wuhan University Zhongnan Hospital Medical Imaging Centre
Huan Li
Wuhan University Zhongnan Hospital Medical Imaging Centre
Sirui Li
Wuhan University Zhongnan Hospital Medical Imaging Centre
Xiangbo Wu
Wuhan University Zhongnan Hospital
Mei Bin
Wuhan University Zhongnan Hospital
Yinghui Wang
Wuhan University Zhongnan Hospital
Haibo Xu (xuhaibo1120@hotmail.com)
Wuhan University Zhongnan Hospital Medical Imaging Centre https://orcid.org/0000-0002-8451-8979

Research article

Keywords: Carotid web, Vessel Wall MRI, stroke, CTA, Diagnosis

Posted Date: December 13th, 2019

DOI: https://doi.org/10.21203/rs.2.18958/v1

Abstract

Background: There currently is no consensus on the performance of Vessel wall MRI (VW MRI) with carotid webs (CaWs). No clear data exist on compare the performance of each diagnostic features in CaWs.

Purpose: To set a standards about the diagnostic features and compare the performance of each diagnostic features in CaWs.

Materials and methods : All patients (n = 165, median age, 56.9 ± 13.3) who has done both neck CTA and VW MRI in our radiology department, Zhongnan hospital, performed from February 2017 to April 2019 were included. All CTA and VW MRI images were read by two experienced radiologists. Interobserver agreement for the two reader's decision of CTA was checked by using kappa statistics. Sensitivity, specificity, and area under the curve (AUC) of each diagnostic features at CTA and VW MRI were compared.

Results: 10 patients with carotid web was found. The feature "double lumen sign" of CTA and "valve sign" and "contrast stasis" of VW MRI showed good specificity (specificity, 98.6% vs 92.9% vs 93.6%, respectively; P<0.001). The feature "double lumen sign" of VW MRI compared to it of CTA showed higher sensitivity (sensitivity, 80.0% [8 of 10] vs 50.0% [5 of 10], respectively; P<0.001) and better diagnostic performances (area under the curve [AUC], 0.93 [95% CI: 0.68, 0.97] and 0.74 [95% CI: 0.54, 0.94], respectively; P<0.001).

Conclusion: The feature "double lumen sign" and "a line or septum" of CTA and "valve sign" and "contrast stasis" of VW MRI may be a crucial performance of carotid web.

Introduction

The carotid web is an intraluminal shelf-like projection within the lumen of the carotid bifurcation (1). It has been confirmed as a severe risk of recurrent ipsilateral cryptogenic ischemic stroke (2–4). Nevertheless, the prevalence of CaWs is indeterminate, range from 2.5% (5) -37% (6–8). CTA was usually selected as defining imaging modality in series of CaWs as a noninvasive method (1, 7, 8). The diagnostic feature "filling defect" and "a (thin) line or septum" was considered as important evidences to indicate carotid web (2, 5, 9). No clear data exist on compare the performance of each diagnostic features in CaWs.

VW MRI allows good depiction of atherosclerosis plaque, cervical arterial dissection and inflammatory arterial diseases and other cervical Wall disease (10–13). Currently, no consensus on the performance of VW MRI with CaWs had established. A MRI study using 2D FSE sequences and cine FSE sequences, black blood, 5 patients with CaWs diagnosed by 3D contrast-enhanced MR angiography was recorded with its performance (14). It had depicted the feature "protrusion" of the carotid web into the lumen and "a thin septum" dividing the lumen and "contrast stasis" after contrast enhancement. In our studies, a 3.0-T

system (Prisma; Siemens, German) and 64 coil tunnel was used to acquire images using 3D FSE SPACE sequences (black blood). T1 weighted imaging (T1WI), T2 weighted imaging (T2WI) and T1 weighted imaging with fat suppression and contrast enhancement (T1WI-CE) was used to acquire carotid vessel wall imaging. And we summarized and concluded the performance of VW MRI with CaWs into six features based on those patient diagnosed by CTA.

Patients with carotid webs diagnosed by CTA was collected and aimed to summarize their diagnostic features and to compare the diagnostic performance of each diagnostic features. In this studies, we performed this retrospective study to analyze each patient's image, and we hypothesized that each modality has its advantage in different diagnostic features.

Materials And Methods

All patients (n = 165, median age, 56.9 ± 13.3) who has done both neck CTA and VW MRI in our radiology department, Zhongnan hospital, performed from February 2017 to April 2019 were included. This research was approved by the ethics committee, Zhongnan Hospital of Wuhan University, Wuhan University. Those patient with stent-deployed or poor image quality that cannot be judged (n=12) were excluded. All CTA (n = 153, median age, 56.9 ± 13.3) images were read by two experienced radiologists. All carotids were evaluated in standard and oblique projections (thin cuts) in order to get better view of each carotid arteries. Discrepancies were settled by consensus. Each patients diagnosed with CaWs will be recorded with their characteristics based on following diagnostic criterion.

- **Imaging Protocol**
- **CT angiography**

A Siemens Somatom Definition 64 slice CT scanner (Siemens, German) or Philips Ingenuity CT 64 slice CT scanner (Phillips, North America) was use to acquire CTA images. Parameters: tube voltages: 140kv, tube current: 31mAs, thickness 1.5mm, with injection of 1.5ml/kg iopromide contrast material (Bayer Schering Pharma AG).

- **VW MRI**

A 3.0-T system (Prisma; Siemens, German) was used to acquire images using 3D FSE SPACE sequences (black blood) and acquisition parameters are detailed in Table 1. 64-channel head neck coil was used to ensure the good image quality. Each person included three sequences for about thirty minutes scanning. T1 weighted imaging (T1WI), T2 weighted imaging (T2WI) and T1 weighted imaging with fat suppression and contrast enhancement (T1WI-CE) after injection of 0.1 mmol/kg gadolinium-based contrast material (Bayer Schering Pharma AG).

The following parameters were used for T1WI: acquired voxel size, 0.7 × 0.7 × 0.7 mm^3; repetition time /echo time, 600ms/13ms; acquisition time, 9 minutes; direction, anterior to posterior. The following parameters were used for T2WI: acquired voxel size, 0.7 × 0.7 × 0.7 mm^3; repetition time /echo time

1300ms/124ms; acquisition time, 8 minutes; direction, Right to Left. The following parameters were used for T1 weighted imaging: acquired voxel size, 0.7 × 0.7 × 0.7 mm^3; repetition time /echo time, 600ms/13ms; acquisition time, 9 minutes; direction, Anterior to Posterior.

- **Diagnostic criterion**
- **CT angiography**

CaW is an intraluminal shelf-like projection within the lumen of the carotid bifurcation (Figure 1) (6, 8, 9, 15). Recent studies have used CTA as the defining imaging modality in series of CaWs. Three features of diagnostic criteria can be summarize into three points:

(1) "**A filling-defect** ", other description: a shelf-like, a protrusion.

(2) **"A thin line or a septum"**, dividing the lumen in axial.

(3) "**Double-lumen sign"**, similar with dissection.

- **VW MRI**

With 5 patients from the Mari E. Boesen's study, our team summarize six features of CaWs with the following parts (Figure 2):

- **"Thickness": Carotid vessel wall thickness (isointension)**

a. Other description: similar with the description of intimal-medial thickness (IMT) in ultrasound
b. Diagnosis character: Thickening and signal enhancement of the vessel wall, typically only on the side of the carotid web on Proton density-weighted FSE images (14); sometimes similar with the thickness in plaque, but no fat component or hemorrhage below the vessel wall, which means there is no suppression of signal on fat-saturated series or hyperintension in T1WI, that's to say usually isointension compared to normal vessel wall.
c. Differential diagnosis: A typical atherosclerotic plaque contains several components, including a fibrous cap, calcifications, a necrotic lipid core, hemorrhagic areas, and a fibrous component (10). There is suppression of signal on fat-saturated series or intraplaque hemorrhage in carotid plaque usually.

- **"Projection" : derived from posterior wall**

a. Other description: Focal endoluminal protrusions, protruding lesions in the carotid bifurcation; filling defect similar with CTA(14); shelf-like outgrowth; a linear band of tissue extending into the lumen
b. Diagnosis character: Attached to the vessel wall, usually derived from posterior wall, sometimes connect to other side wall. Its MRI signal features: usually isointense without suppression of signal on fat-saturated series or hyperintension beneath the intimal on T1WI; usually isointense or hyperintension on T2WI; it usually has obvious enhancement on T1WI-CE.

c. Differential diagnosis: Unlike the well-delineated CaW with its smooth border, surfaces of atherosclerotic lesions are commonly irregular and atherosclerosis may also involve the distal common carotid and areas distal to the bulb (8-10).

- **“Value sign”: Value-liked constructer**

a) Diagnosis character: The webs derived from two side of lumen with junction in the center.

b) Differential diagnosis：No such image character have been found in other vascular diseases. It may look like vein value or vulnerable intimal flap sometimes.

- **“Double lumen sign”: Double-lumen or multi- lumens**

a) Diagnosis character: A thin line or a septum dividing the lumen in axial, and may have more than two lumens (14);

b) Differential diagnosis：Similar with carotid dissection sometimes, but there is no mural hematoma (16).

- **“Contrast stasis”**

a) Diagnosis character: Residual contrast-enhanced blood accumulation behind the carotid web (14).

b) Differential diagnosis：It need to be distinguish with flow artifacts near the carotid bulb.

- **Reference standard**

CTA was usually selected as defining imaging modality in this study. Each patients’ diagnosis character of each modality were be recorded according to the above-mentioned diagnostic criterion. Discrepant opinions were discussed and settled by consensus. In additions, the degree of stenosis of each patient with CaWs was recorded based on NASCET criteria (mild: 1–29%, low moderate: 30–50%, high-moderate: 50–69%, severe: 70–99%) (13, 14). And any hyperdense focus with relative Hounsfield unit >1,000 was identified as vessel wall calcification.

Statistical Analysis

Interobserver agreement in CTA of detecting carotid webs was checked by using kappa statistics. Two-sided Cohen’s Kappa (κ) coefficient was used to evaluate the inter-rater agreement for the two reader’s diagnostic results.

Sensitivity, specificity, and area under the curve (AUC) of each diagnostic features at CTA and VW MRI were calculated. A $P<0.05$ was considered statistically significant. Statistical analysis was performed using IBM R SPSS R Statistics 22 (IBM R -Armonk, NY, USA).

Results

All patients (n = 165, median age, 56.9 ± 13.3) who has done both neck CTA and VW MRI in our radiology department, Zhongnan hospital, performed from February 2017 to April 2019 were included, except from those patient with stent-deployed or poor image quality that cannot be judged (n = 12) were excluded. All CTA images were read by two experienced radiologists blinded to each other's findings and to clinical information. Inter-rater agreement between two reader was good (κ = 0.85; p < 0.001). In addition, 10 patients with carotid web was found. 3 of them were youth, 2 of them (Male) had acute ischemic stroke and 1 (Female) of them had TIA. Those patients all did not have any obvious cardiovascular risk factors.

65 patients has anterior circulation ischemic stroke in our research, 10 of them has carotid web, showed in the Table 1. Patients with CaWs (n = 10) less frequently presented vascular risk factors compared to ordinary ischemic stroke (n = 55): hyperlipidemia (34.5% (19/55) VS 20.0% (2/10)), diabetes (21.8% (12/55) VS 0% (0/10)), and smoking (25.4% (14/55) VS 10.0% (1/10)). Besides, this two group has same percentages of hypertension (60.0% (33/55) VS 60.0% (6/10)). In addition, patients with CaWs has more frequently presented fibromuscular dysplasia (n = 1, 10%, 1/10) in the carotid arteries: than general population that had published before (0.02%(17, 18)).

Three features of CaWs in CTA and six features of CaWs in VW MRI was settled by consensus. CTA: (1) filling defect (100%, 10/10); (2) a thin line/septum (80%, 8/10); (3) double lumen sign (50%, 5/10), as depicted on Fig. 1. VW MRI:(1) Carotid vessel wall thickness (100%, 10/10); (2) Projection (100%, 10/10); (3) Value sign (60%, 6/10); (4) Double-lumen sign (0%, 8/10); (5) Contrast stasis (30%, 3/10), as depicted on Fig. 2. Each feature of 153 patients' image was been analyzed and recorded.

Sensitivity, specificity, and area under the curve (AUC) of each diagnostic features at CTA and VW MRI were showed in Fig. 3 and Table 2. The feature "projection" of VW MRI compared to "filling defect" of CTA showed better diagnostic performances (area under the curve [AUC], 0.93 [95% CI: 0.89, 0.97] and 0.87 [95% CI: 0.81, 0.94], respectively; P < 0.001). The feature "a line or septum" of CTA compared to VW MRI showed similar diagnostic performances (area under the curve [AUC], 0.86 [95% CI: 0.72, 1.00] and 0.84 [95% CI: 0.69, 0.98], respectively; P < 0.001). The feature "double lumen sign" of VW MRI compared to it of CTA showed higher sensitivity (sensitivity, 80.0% [8 of 10] vs 50.0% [5 of 10], respectively; P < 0.001) and better diagnostic performances (area under the curve [AUC], 0.93 [95% CI: 0.68, 0.97] and 0.74 [95% CI: 0.54, 0.94], respectively; P < 0.001). The feature "double lumen sign" and "a line or septum" of CTA and of "valve sign" and "contrast stasis" of VW MRI showed good specificity (specificity, 98.6% vs 98.6% vs 92.9% vs 93.6%, respectively; P < 0.001).

The feature "double lumen sign" and "a line or septum" of CTA and of "valve sign" and "contrast stasis" of VW MRI may be a crucial performance of carotid web. VW MRI provided superior diagnostic performances of the feature "projection" of VW MRI compared to "filling defect" of CTA in patients with CaWs. VW MRI and CTA were complementary in diagnostic performance of CaWs.

Discussion

Previous studies were usually selected CTA as defining imaging modality in series of CaWs as a noninvasive method (1, 7, 8). Conventional CTA, MRA, and DSA just present luminal narrowing and contrast stasis, but offer limited information about the pathophysiologic characteristic of the vessel wall. Vessel wall MRI (VW MRI) has proved better diagnostic confidence of atherosclerosis plaque, arterial dissection and vasculitis and other vascular disease compared to CTA, DSA and 3D-TOF-MRA (10–13, 19). Currently, no consensus on the performance of Vessel wall MRI (VW MRI) with carotid webs (CaWs) has been established. And No clear data exist on compare the performance of each diagnostic features in CaWs. Our studies has proved that The feature “double lumen sign” and “a line or septum” of CTA and “valve sign” and “contrast stasis” of VW MRI showed good specificity (specificity, 98.6% vs 98.6% vs 92.9% vs 93.6%, respectively; $P < 0.001$). Besides, VW MRI compared to CTA showed better diagnostic performances with the feature “projection” of VW MRI VS “filling defect” of CTA (area under the curve [AUC], 0.93 [95% CI: 0.89, 0.97] and 0.87 [95% CI: 0.81, 0.94], respectively; $P < 0.001$). The feature “double lumen sign” of VW MRI compared to it of CTA showed higher sensitivity (sensitivity, 80.0% [8 of 10] vs 50.0% [5 of 10], respectively; $P < 0.001$) and better diagnostic performances (area under the curve [AUC], 0.93 [95% CI: 0.68, 0.97] and 0.74 [95% CI: 0.54, 0.94], respectively; $P < 0.001$). Besides, they had similar diagnostic performances of “a line or septum” of (area under the curve [AUC], 0.84 [95% CI: 0.69, 0.98] and0.86 [95% CI: 0.72, 1.00], respectively; $P < 0.001$).

2D FSE sequences and cine FSE sequences had recorded carotid web with its performance (14). It had supported the feature “protrusion” and “a thin septum” and “contrast stasis”. But it did not provide quantitative measurements of carotid wall thickness and distensibility and did not make a systematic explanation of its performances on MR due to the small sample size. Our study using 3D FSE SPACE sequences (black blood), 3.0T MR, to acquire the carotid vessel wall imaging, and it can demonstrate the vessel wall in any direction and can summarize the signal on multi-sequences which can provide more evidences to distinguish atherosclerosis and dissection. Feature “Contrast stasis” means residual contrast-enhanced blood accumulation behind the carotid web on T1 weighted imaging with fat suppression and contrast enhancement (T1WI-CE), which can give evidence of for a proposed link between a morphological finding (carotid web) the likelihood of thrombus formation(1). It had proved good specificity (specificity, 93.6%, $P < 0.001$) but with lower sensitivity (sensitivity, 30.0%, $P < 0.001$), which means not all carotid web has contrast stasis or it could not been easily catched. Or, VW MRI may not be the best method to show it. Computational fluid dynamics may could provide good depictions with increased recirculation zones and regional increased wall shear stress metrics that are associated with disturbed flow (20).

CTA has good depiction on anastomotic stenosis of lumen, as our research had proved the feature “filling defect” has a good sensitivity. But it was weak in distinguish the component of a filling defect. VW MRI has great advantage to provide complementary and important information regarding vessel wall composition, wall mechanics, and blood flow(21). Especially, CaWs sometimes has the similar diagnostic performance with atherosclerotic plaques and carotid dissection (5, 22). On the one hand, atherosclerotic

plaques can also mimic a CaW because they typically occur at the carotid bifurcation and has the same feature “ a filling defect” (9). Both may appear as relatively focal endoluminal protrusions, therefore, vessel wall imaging is very important in making an accurate diagnosis. Because the surfaces of atherosclerotic lesions are commonly irregular and there is no fat component or hemorrhage below the intimal-medial, which means there is no suppression of signal on fat-saturated series or hyperintension in T1WI. On the other hand, carotid dissection has the same feature “double lumen sign”, since feature “double lumen sign” shows good specificity during the diagnosis. But VM MRI has a better performance in a double lumen than CTA with higher sensitivity (sensitivity, 80.0% [8 of 10] vs 50.0% [5 of 10], respectively; $P < 0.001$) and better diagnostic performances (area under the curve [AUC], 0.93 [95% CI: 0.68, 0.97] and 0.74 [95% CI: 0.54, 0.94], respectively; $P < 0.001$). And it has advantages in showing mural hematoma which is a crucial performance to the diagnosis of carotid dissection (11, 23).

Conventional digital subtraction angiography (DSA) has been historically used for detection of CaWs since 1973 (24). In the late venous phase of arterial angiography, the demonstration of stagnation in the CaW pocket has been seen as an important evidence. One caveat is that if standard posteroanterior or lateral projections are used, operators may miss the CaW (9). Similar, a careful multi projection analysis (axial, sagittal, and coronal projections) on the CTA is critical. VW MRI allows depiction of a structure in any directions so that can reduce misdiagnosis.

Our study had limitations. First, our study was retrospective; therefore, some patients who underwent one of examination during the last two years were excluded from this analysis. Second, this is no pathological evidences and no long term following-up in mostly patients of our research. Third, our knowledge about the clinical characteristics of disease was limited which may bias the diagnostic performances of each modality because the limited research about Caws on MRI study. Finally, the patients included in our research has a higher proportion of male may cause the prevalence of CaWs underestimated, which few previous studies have showed the possibility of female dominating (5, 6). Since knowledge on dynamic changing of CaW and its origin is limited, a larger scale VM MRI study of it with the addition of newly available quantitative blood flow analysis (25) and computational fluid dynamics (20), may provide more valuable insights into the diagnostic features posed by carotid webs.

Declaration

- **Ethics approval and consent to participate**

Informed consent is acquired.

- **Consent for publication**

Agree.

- **Availability of data and material**

Not applicable.

- **Competing interests**

Not applicable.

- **Funding**

Project supported by the State Key Program for Basic Research of China (Grant No. 2017YFC0108803) and Zhongnan Hospital of Wuhan University (znpy2018125,2017.12-2019.12)

- **Authors' contributions**

Hanpei Zheng, Sirui Li, Haibo Xu contributes to the imaging diagnosis of this case. Xiangbo Wu, Bin Mei and yinghui wang contributes to the collection of clinical data and the clinical therapy. Hanpei Zheng are dedicating to the paper writing.

- **Acknowledgements**

Not applicable

References

1. Choi PM, Singh D, Trivedi A, Qazi E, George D, Wong J, et al. Carotid Webs and Recurrent Ischemic Strokes in the Era of CT Angiography. AJNR American journal of neuroradiology. 2015;36(11):2134-9.
2. Haussen DC, Grossberg JA, Bouslama M, Pradilla G, Belagaje S, Bianchi N, et al. Carotid Web (Intimal Fibromuscular Dysplasia) Has High Stroke Recurrence Risk and Is Amenable to Stenting. Stroke. 2017;48(11):3134-7.
3. Grory BM, Cheng DL, Doberstein C, Jayaraman MV, Yaghi S. Ischemic Stroke and Internal Carotid Artery Web. Stroke. 2019.
4. Martinez-Perez R, Lownie SP, Pandey SK, Boulton MR. Stent Placement for Carotid Web. World neurosurgery. 2017;98:879 e9- e11.
5. Compagne KCJ, van Es A, Berkhemer OA, Borst J, Roos Y, van Oostenbrugge RJ, et al. Prevalence of Carotid Web in Patients with Acute Intracranial Stroke Due to Intracranial Large Vessel Occlusion. Radiology. 2018;286(3):1000-7.
6. Joux J, Chausson N, Jeannin S, Saint-Vil M, Mejdoubi M, Hennequin JL, et al. Carotid-bulb atypical fibromuscular dysplasia in young Afro-Caribbean patients with stroke. Stroke. 2014;45(12):3711-3.
7. Sajedi PI, Gonzalez JN, Cronin CA, Kouo T, Steven A, Zhuo J, et al. Carotid Bulb Webs as a Cause of "Cryptogenic" Ischemic Stroke. AJNR American journal of neuroradiology. 2017;38(7):1399-404.
8. Coutinho JM, Derkatch S, Potvin AR, Tomlinson G, Casaubon LK, Silver FL, et al. Carotid artery web and ischemic stroke: A case-control study. Neurology. 2017;88(1):65-9.

9. Kim SJ, Nogueira RG, Haussen DC. Current Understanding and Gaps in Research of Carotid Webs in Ischemic Strokes: A Review. JAMA Neurol. 2019;76(3):355-61.
10. Oppenheim C, Naggara O, Touze E, Lacour JC, Schmitt E, Bonneville F, et al. High-Resolution MR Imaging of the Cervical Arterial Wall: What the Radiologist Needs to Know. Radiographics. 2009;29(5):1413-U252.
11. Mandell DM, Matouk CC, Farb RI, Krings T, Agid R, terBrugge K, et al. Vessel wall MRI to differentiate between reversible cerebral vasoconstriction syndrome and central nervous system vasculitis: preliminary results. Stroke. 2012;43(3):860-2.
12. Zhang Y, Guallar E, Malhotra S, Astor BC, Polak JF, Qiao Y, et al. Carotid Artery Wall Thickness and Incident Cardiovascular Events: A Comparison between US and MRI in the Multi-Ethnic Study of Atherosclerosis (MESA). Radiology. 2018;289(3):649-57.
13. Park JE, Jung SC, Lee SH, Jeon JY, Lee JY, Kim HS, et al. Comparison of 3D magnetic resonance imaging and digital subtraction angiography for intracranial artery stenosis. Eur Radiol. 2017;27(11):4737-46.
14. Boesen ME, Eswaradass PV, Singh D, Mitha AP, Goyal M, Frayne R, et al. MR imaging of carotid webs. Neuroradiology. 2017;59(4):361-5.
15. Renard D, Hampton J, Keita M, Freitag C. Teaching NeuroImages: Multimodality imaging of carotid web. Neurology. 2018;90(17):e1541.
16. Debette S, Compter A, Labeyrie M-A, Uyttenboogaart M, Metso TM, Majersik JJ, et al. Epidemiology, pathophysiology, diagnosis, and management of intracranial artery dissection. The Lancet Neurology. 2015;14(6):640-54.
17. Slovut DP, Olin JW. Fibromuscular Dysplasia. New England Journal of Medicine. 2004;350(18):1862-71.
18. Schievink WI, Björnsson JJCN. Fibromuscular dysplasia of the internal carotid artery: a clinicopathological study. 1996;15(1):2.
19. Al-Smadi AS, Abdalla RN, Elmokadem AH, Shaibani A, Hurley MC, Potts MB, et al. Diagnostic Accuracy of High-Resolution Black-Blood MRI in the Evaluation of Intracranial Large-Vessel Arterial Occlusions. AJNR American journal of neuroradiology. 2019;40(6):954-9.
20. Compagne KCJ, Dilba K, Postema EJ, van Es A, Emmer BJ, Majoie C, et al. Flow Patterns in Carotid Webs: A Patient-Based Computational Fluid Dynamics Study. AJNR American journal of neuroradiology. 2019;40(4):703-8.
21. Choi YJ, Jung SC, Lee DH. Vessel Wall Imaging of the Intracranial and Cervical Carotid Arteries. J Stroke. 2015;17(3):238-55.
22. Wojcik K, Milburn J, Vidal G, Steven A. Carotid Webs: Radiographic Appearance and Significance. The Ochsner journal. 2018;18(2):115-20.
23. Ben Hassen W, Machet A, Edjlali-Goujon M, Legrand L, Ladoux A, Mellerio C, et al. Imaging of cervical artery dissection. Diagnostic and Interventional Imaging. 2014;95(12):1151-61.

24. Momose KJ, New PF. Non-atheromatous stenosis and occlusion of the internal carotid artery and its main branches. Am J Roentgenol Radium Ther Nucl Med. 1973;118(3):550-66.
25. Schmitter S, Schnell S. 4D Flow MRI. Quantification of Biophysical Parameters in Medical Imaging2018. p. 187-212.

Tables

Due to technical limitations, the tables could not be displayed here. Please see the supplementary files section to access the tables.

Abbreviations

VW MRI= vessel wall MR imaging

CaWs= carotid webs

CTA= Computed tomography angiography

T1WI= T1 weighted imaging

T2WI= T2 weighted imaging

T1WI-CE= T1 weighted imaging with fat suppression and contrast enhancement

DSA=Digital substraction angiography

FSE= fast spin echo

SPACE = sampling perfection with application-optimized contrasts by using different flip angle evolution

TIA = transient ischemic attacks

Figures

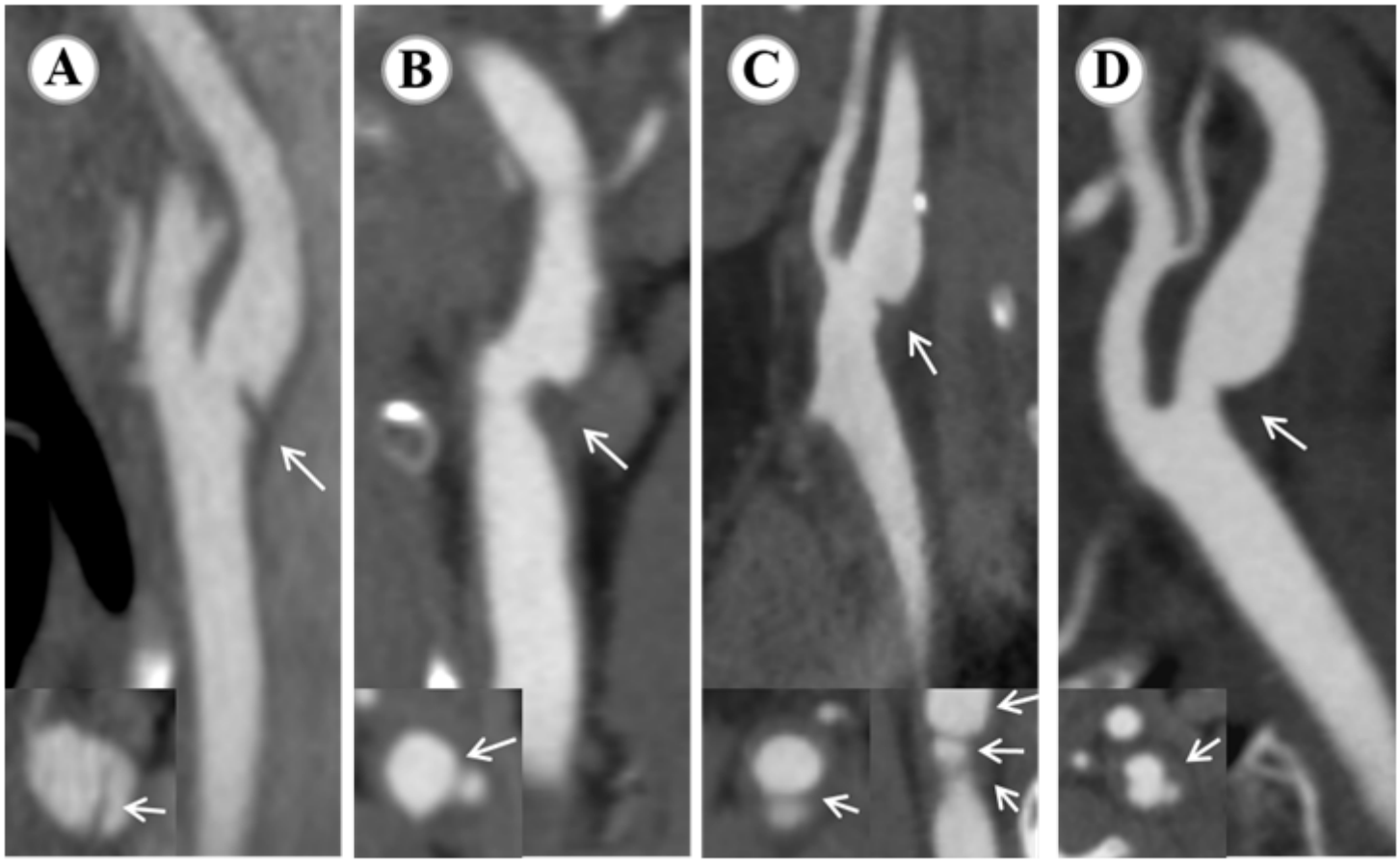

Figure 1

Diagnostic criterion of CTA. Three key points: (1) “A filling-defect”, a shelf-like, a protrusion derived from the posterior wall of carotid bulb. There is no any sign of calcification. (2) “A thin line or a septum”, dividing the lumen in axial, sometimes it cannot easily been seen. (3) “Double-lumen sign”, it may have more than two lumens, as showed in C with a coronal plane, and it cannot always been seen.

Plane	Axial			Sagittal			Key point
Sequence	T1WI	T2WI	T1WI-FS-CE	T1WI	T2WI	T1WI-FS-CE	
Projection derived from posterior wall	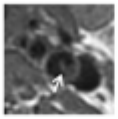	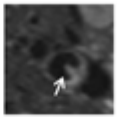	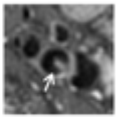	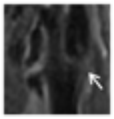			connected to vessel wall (distinguish from artifact)
Vessel wall thickening	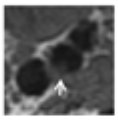	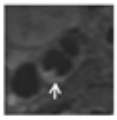				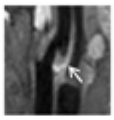	decentered (similar with plaque sometimes) but protrusive
Double-lumen /multi-lumen	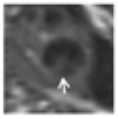		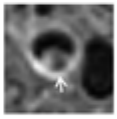	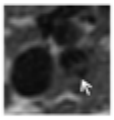		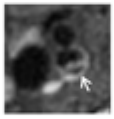	similar with dissection but no mural hematoma
Value-liked constructer	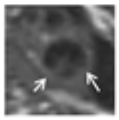						the webs derived from two side of lumen with junction in the center
Contrast stasis	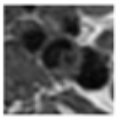	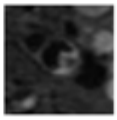	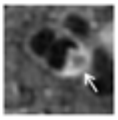	Can not be easily catched in sagittal plane			Residual contrast-enhanced blood accumulation behind the carotid web

Figure 2

Diagnostic criterion of VW MRI. Explanations: We provide two plane of each feature, the image of each plane were selected from a different case.

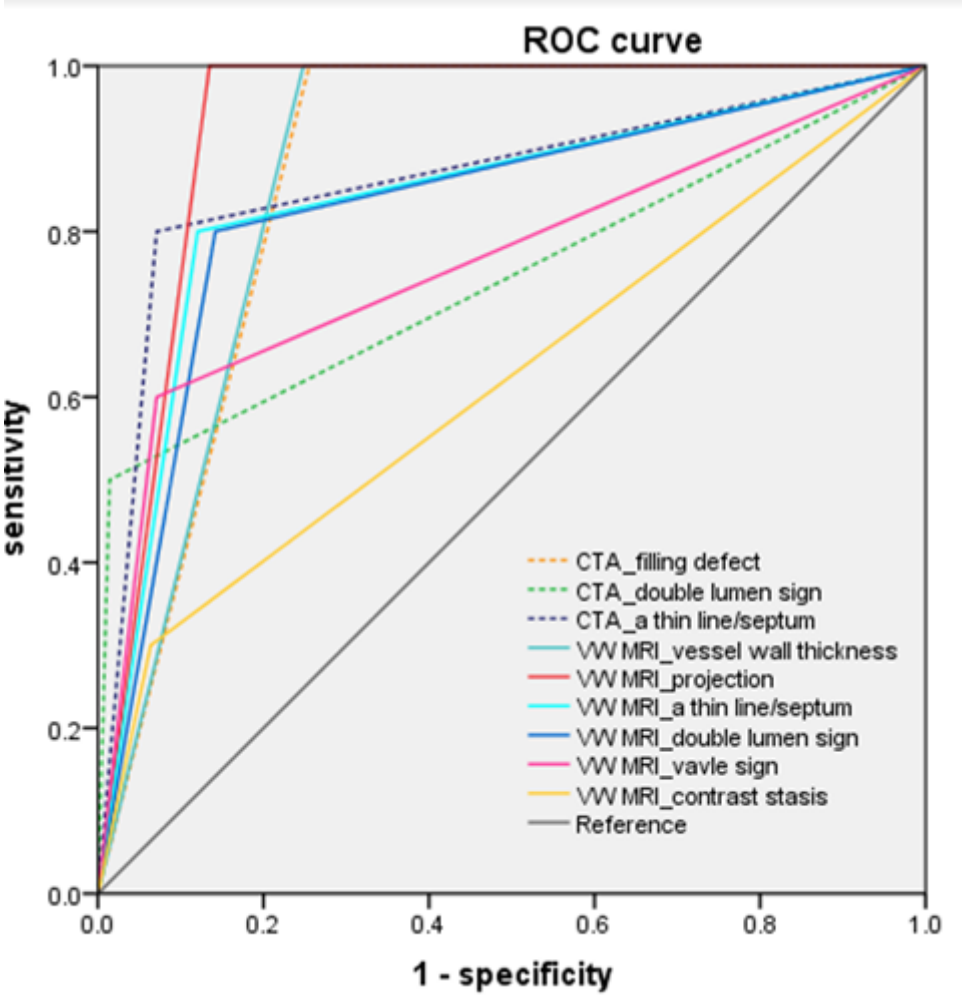

Figure 3

ROC curve of each diagnostic features of VW MRI and CTA. Explanations: Sensitivity, specificity, and area under the curve (AUC) of each diagnostic features at CTA and VW MRI were showed.

Supplementary Files

This is a list of supplementary files associated with this preprint. Click to download.

- Tables.docx