Retrospective Analysis of Risk Factors for Postoperative Perineal Hernia After Endoscopic Abdominoperineal Excision for Rectal Cancer

Tatsuya Manabe (manabe@cc.saga-u.ac.jp)
Saga University
Yusuke Mizuuchi
Kyushu University
Yasuhiro Tsuru
Saga University
Hiroshi Kitagawa
Saga University
Takaaki Fujimoto
Saga University
Yasuo Koga
Saga University
Masafumi Nakamura
Kyushu University
Hirokazu Noshiro
Saga University

Research Article

Keywords: postoperative perineal hernia, endoscopic abdominoperineal excision, rectal cancer

Posted Date: October 13th, 2021

DOI: https://doi.org/10.21203/rs.3.rs-962418/v1

Version of Record: A version of this preprint was published at BMC Surgery on March 8th, 2022. See the published version at https://doi.org/10.1186/s12893-022-01538-7.

Abstract

Background: In contrast to open-surgery abdominoperineal excision (APE) for rectal cancer, postoperative perineal hernia (PPH) is reported to increase after extralevator APE and endoscopic surgery. In this study, therefore, we aimed to determine the risk factors for PPH after endoscopic APE.

Methods: A total 73 patients who underwent endoscopic APE for lower rectal cancer were collected from January 2009 to March 2020, and the risk factors for PPH were analyzed retrospectively.

Results: Nineteen patients (26%) developed PPH after endoscopic APE, and the diagnosis of PPH was made at 9–393 days (median: 183 days) after initial surgery. Logistic regression analysis showed that absence of pelvic peritoneal closure alone increased the incidence of PPH significantly (odds ratio; 13.76, 95% confidence interval; 1.48–1884.84, $p = 0.004$).

Conclusions: Pelvic peritoneal closure should be performed when possible after endoscopic APE to prevent PPH.

Background

Postoperative perineal hernia (PPH) after abdominoperineal excision (APE) of the rectum is a complication caused by herniation of the intra-abdominal organs through the pelvic floor after complete removal of the anorectal sequence. Although most PPHs after APE are asymptomatic or ignorable, some patients have serious symptoms such as discomfort, perineal pain, impaired sensation, urinary dysfunction or intestinal obstruction when perineal bulging is gradually enlarged [4, 5]. Therefore, some patients have disturbed quality of life and others require surgical treatment. In patients with conventional open APE, the incidence of clinically manifest PPH was reported as < 1% [1, 2] and PPH based on barium X-rays was 7% [3]. However, recent technical modifications in APE for rectal cancer are associated with increased incidence of PPH. One such modification is extralevator APE (ELAPE) for lower rectal cancer, which involves wide resection of the levator ani muscles surrounding the rectum through two-phase abdominal and perineal resection to obtain sufficient circumferential resection margins and prevent inadvertent rectal rupture [6]. Despite the improved oncological outcomes, increased perineal complications have been reported after removal of excessive pelvic tissue in ELAPE, compared with conventional APE [7–10]. To prevent PPH, therefore, exact pelvic reconstruction, such as the myocutaneous flap method or use of a biological mesh, has been performed after ELAPE [6, 11, 12]. In contrast, endoscopic surgery is associated with reduced incidence of ventral hernia after colorectal surgery [14], but an increased incidence of PPH after endoscopic APE has been reported [9]; thus, some preventive procedure against PPH is advocated.

In previous studies about conventional open APE, risk factors for PPH after APE included previous hysterectomy, perineal wound infection, perioperative radiotherapy, coccygectomy, excessive length of small bowel mesentery, and larger size of the female pelvis [1, 15–18]. However, most of these reports were from small studies or case reports, and the risk factors for PPH after endoscopic APE for lower

rectal cancer are not well documented. In this study, we aimed to clarify the incidence and risk factors for PPH after endoscopic APE for lower rectal cancer.

Methods

A total of 75 patients with lower rectal cancer underwent endoscopic APE with simple closure of the perineum at Saga University Hospital or the Department of Surgery and Oncology in Kyushu University Hospital between January 2009 and March 2020. Patients who underwent total pelvic exenteration were excluded. PPH was defined as an obvious bulge in the perineum and/or downward displacement of the intestine beyond the line described by computed tomography from the inferior margin of the pubis to the end of the coccyx (Fig. 1). Standard surveillance using computed tomography was routinely carried out every 6 months for at least 5 years after surgery, and irregularly performed to investigate other disease, based on the physician's decision.

The demographics of the patients were obtained from the prospectively maintained comprehensive database and medical records. The tumor stage was classified according to the eighth TNM classification system. Patients with clinical T4, pelvic nodal involvement, and circumferential resection margin < 1 mm by magnetic resonance imaging received preoperative chemoradiotherapy and/or systemic chemotherapy. Postoperative systemic chemotherapy was administered to patients with pathologically positive lymph nodes and/or distant metastases.

Ethics

Informed consent was obtained from all patients. All procedures were conducted in accordance with the ethical standards of the responsible committee on human study and with the Helsinki Declaration and later revision. This retrospective observational study was approved by the Ethics Committee of the Faculty of Medicine at Saga University (2019-09-Jinsoku-03) and Kyushu University (29-292).

Endoscopic APE

All patients were placed in the supine modified Lloyd–Davies position. Laparoscopic surgery was performed using a five-port technique: a supra-umbilical port for the laparoscope, two ports at the right lower quadrant, and two ports placed symmetrically at the left lower quadrant. For robot-assisted APE using the da Vinci Si Surgical System (Intuitive Surgical Inc., Sunnyvale, CA, USA), six ports were placed as described previously [19]. Typically, after ligation of the inferior mesenteric artery, mobilization of the rectum with total mesorectal excision (TME)preserving the autonomic nerves was performed in the pelvis along the presacral space. Posterior dissection in the TME plane stopped at the apex of the coccyx. Next, the lateral ligaments were divided bilaterally and the peritoneal reflection was opened, and the anterior side of the rectum was dissociated to the lower edge of the prostate for men, or along the rectovaginal septum for women. The levator ani muscle was divided transabdominally from the posterior to lateral side to the ischiorectal fossa. When endoscopic transperineal TME was performed, vascular ligation and dissection of the upper rectum were laparoscopically performed and the levator ani muscle was divided

via the perineal approach. Finally, the specimen was extracted through the perineal wound. Closure of the perineum was performed by primary approximation of the skin and subcutaneous tissue. PPC was added for some patients. After specimen removal, the pelvic peritoneum was closed neatly with interrupted 3-0 Vicryl sutures from the anterior to posterior under laparoscopic vision and/or using robotic arms (Fig. 2). The choices of surgical approach, route of the stoma, and PPC depended on the discretion of the treating surgeon.

Statistical analysis

All statistical analyses were performed using JMP version 14 (SAS Institute, Cary, NC, USA). For univariate analysis, continuous variables were compared between the groups by the Mann–Whitney U test, while the chi-squared test and analysis of variance were used for comparison of categorical variables. Multiple logistic regression analysis with Firth correction was performed to identify factors that were independently associated with PPH. $P < 0.05$ was considered to be statistically significant.

Results

Median observation period was 963 days (range 9–2190 days). Of all 73 patients who underwent endoscopic APE for lower rectal cancer, 19 (26%) developed PPH. Three of these 19 patients received hernia repair for the severe symptoms. The cumulative incidence of PPH is shown in Figure 1. The median period of detection of PPH was 183 days (range 9–393 days) after surgery. PPH did not occur in any patient > 2 years after surgery.

Table 1 shows the results of univariate analysis. No patient-related, tumor-related or postoperative factor was associated with PPH. Among the surgical factors, surgical approach, performance of transperineal endoscopic approach, addition of pelvic lymph node dissection, route of the stoma, operating time, blood loss volume and transfusion were not associated with PPH. PPC alone was significantly associated with the incidence of PPH ($p = 0.007$). Multivariate logistic regression analysis with Firth correction that included PPC and postoperative perineal wound dehiscence was performed to identify independent factors associated with occurrence of PPH. PPC was independently associated with the occurrence of PPH (odds ratio = 13.76, 95% confidence interval = 1.48–1884.84; $p = 0.004$) (Table 2).

Table 1
Univariate analysis to evaluate the risk factors for postoperative perineal hernia

		Perineal hernia		
		Presence	Absence	*p* value
		n = 19	n = 54	
Patient-related variables				
Average age (yr)		63.8	66.2	0.472
Sex	Male	11	38	0.325
	Female	8	16	
Average BMI* (kg/m^2)		21.9	21.8	0.991
ASA-PS**	1 / 2 / 3	6 /12 /1	9 /42 /3	0.404
Preoperative therapy	Yes	7	14	0.373
	No	12	40	
NCRT***	Yes	4	5	0.200
	No	15	49	
Systemic chemotherapy	Yes	4	11	0.950
	No	15	43	
Tumor-related variables				
Depth of tumor	T0–2	6	20	0.667
	T3–4	13	34	
Average size of tumor (mm)		84.9	48.2	0.173
pStage	0–2	11	28	0.649
	3–4	8	26	
Surgery-related variables				
Surgical approach	Endoscopic surgery	14	42	0.738
	Robot-assisted surgery	3	5	
	TpTME§	2	7	

*BMI: body mass index, **ASA-PS: American Society of Anesthesiologists physical status, ***NCRT: neoadjuvant chemoradiotherapy, §MVR: multi-visceral resection, §§LPLD: lateral pelvic lymph-node dissection; §§§PPC, pelvic peritoneal closure.

		Perineal hernia		
MVR§	Yes	3	4	0.308
	No	16	50	
LPLD§§	Yes	9	28	0.737
	No	10	26	
Route of stoma	Transperitoneal route#	14	37	0.670
	Retroperitoneal route	5	17	
PPC§§§	Yes	0	11	0.007
	No	19	43	
Average operating time (min)		545.9	596.3	0.256
Average bleeding (g)		292.9	311.4	0.799
Transfusion	Yes	2	8	0.632
	No	17	46	
Postoperative variables				
Perineal wound dehiscence	Yes	4	4	0.120
	No	15	50	
Pelvic abscess	Yes	1	8	0.240
	No	18	46	
Urinary disorder	Yes	3	9	0.929
	No	16	45	
Ileus	Yes	2	7	0.729
	No	17	46	
Average length of postoperative stay (d)		22.2	21.7	0.898
Adjuvant therapy	Yes	7	26	0.392
	No	12	28	

*BMI: body mass index, **ASA-PS: American Society of Anesthesiologists physical status, ***NCRT: neoadjuvant chemoradiotherapy, §MVR: multi-visceral resection, §§LPLD: lateral pelvic lymph-node dissection; §§§PPC, pelvic peritoneal closure.

Table 2
Multiple logistic regression analysis with Firth correction to determine independent risk factors for Postoperative perineal hernia

Parameters	odds ratio (95% confidence interval)	*p* value
PPC*	13.76 (1.48–1884.84)	0.004
Perineal wound dehiscence	4.74 (0.96–29.1)	0.057
*PPC, pelvic peritoneal closure.		

Discussion

This study showed that PPH occurred in 26% of patients with endoscopic APE for rectal cancer within 13 months after surgery and that PPC was available for prevention of PPH. The importance of PPC for preventing perineal complications was advocated by McMullin [2] and Goliger [20] in 1985. In conventional open APE, PPC is a standard procedure when sufficient peritoneal tissue is preserved [21]. Similarly, Yan et al. [24] reported that no PPH was found in 86 cases that underwent endoscopic APE with additional PPC, and that the incidence of PPH was significantly lower in endoscopic APE with than without PPC (0% vs 5.21%, $p = 0.032$). Nevertheless, the pelvic peritoneum is often not closed during endoscopic APE because laparoscopy is necessary for proficient suturing [22, 23]. In contrast to the previous reports about the risk factors for PPH [1, 15–18], this study did not show that PPH had any correlation with female sex, preoperative radiotherapy, or multiple organ resection including coccygectomy. Measurement of the mesenteric length was not accessible under the laparoscopic approach.

Although PPC is a useful technique to prevent PPH, some discussion remains before performing PPC. First, the peritoneum must be removed widely to avoid division of the mesorectum during medial and lateral dissection of the upper rectum from the pelvis under laparoscopy. When it is hard to perform peritoneal closure because of severe tension, addition of a shallow incision on the tense portion of the peritoneum could be helpful to relax it [24]. During suturing of the peritoneum, the stitching intervals should be shortened, because herniation of the intestine through the unexpected defect of the closed peritoneum could occur. Indeed, we did not observe herniation because interrupted stitches were placed at short intervals during peritoneal closure. Next, high proficiency is mandatory in suturing procedures by conventional laparoscopic surgery. Robotic surgery might facilitate such procedures. Finally, PPC could not be performed in some patients with endoscopic APE because of tumor invasion to the pelvic peritoneum, bulky tumor, addition of lateral pelvic lymph-node dissection, and preoperative chemoradiotherapy[25].

Various pelvic reinforcements as alternatives to PPC have been performed after APE: suture of levator ani muscle, bladder peritoneal flaps, hysteropexy, omentoplasty and synthetic mesh. Levator ani muscle suturing [26] can be applied to rectal cancer surgery because of wide excision of the muscle. A randomized trial revealed that omentoplasty did not reduce the incidence of PPH [27]. Several studies

have revealed that Bio-mesh can be effective for reducing PPH [28–30]. Unfortunately, the use of Bio-mesh is limited to western countries. Immobilization of bladder peritoneal flaps in men and the uterus in women might be helpful for preventing PPH, when PPC is impossible [31, 32].

The present study had some limitations: the retrospective design, small study population, and application of the approach for lateral pelvic lymph-node dissection and PPC was decided by surgeons.

Conclusions

The only risk factor for PPH was absence of PPC. Therefore, PPC should be performed after endoscopic APE to prevent PPH, when possible. A further, large prospective study is needed to reduce PPH after endoscopic APE.

Abbreviations

APE: abdominoperineal excision, PPH; postoperative perineal hernia, PPC: pelvic peritoneal closure, ELAPE: extralevator APE. TME: total mesorectal excision

Declarations

Ethics approval and consent to participate

All procedures in this study were conducted in accordance with the ethical standards of the responsible committee on human study and with the Helsinki Declaration and later revision.

Consent for publication

Participants gave their consent for publication.

Availability of data and materials

The demographics of the patients were obtained from the prospectively maintained comprehensive database and the medical records. Informed consent for the use of medical information was obtained from all patients. The study protocol was approved by the Ethics Committee of the Faculty of Medicine at Saga University and Kyushu University.

Competing interests

The authors declare no conflicts of interest in association with the present study.

Funding

There was no funding for this study.

Authors' contributions

TM was the main author of this article and performed the data collection and statistical analyses; YM, YT, HK, TF and YK contributed to the data collection; MN and HN contributed to the data collection and reviewed the manuscript; all authors have read and approved the final manuscript.

Acknowledgements

The authors thank Dr. Atsushi Kawaguchi of the Center for Comprehensive Community Medicine at the Faculty of Medicine of Saga University for his valued assistance in the statistical analyses of this study. We thank Cathel Kerr, BSc, PhD, from Edanz (https://jp.edanz.com/ac) for editing a draft of this manuscript.

References

1. So JB, Palmer MT, ShellitoPostoperative perineal hernia. Dis Colon Rectum. 1997;40:954-7.
2. McMullin ND, Johnson WR, Polglase AL, Hughes ES.Post-proctectomy perineal hernia: case report and discussion. Aust NZJ Surg. 1985;55:69-72.
3. Hullsiek HE. Perineal hernia after abdominoperitoneal resection. Am J Surg. 1956;92:735-738.
4. Ramprasad Rajebhosale, Mohammad Miah, Fraser Currie, Pradeep Thomas. Closed loop obstruction and adhesive intestinal obstruction in perineal hernia. BMJ Case Rep. 2020; doi: 10.1136/bcr-2020-238112.
5. Yasukawa D, Aisu Y, Kimura Y, Takamatsu Y, Kitano T, Hori T. Which Therapeutic Option Is Optimal for Surgery-Related Perineal Hernia After Abdominoperineal Excision in Patients with Advanced Rectal Cancer? A Report of 3 Thought-Provoking Cases. Am J Case Rep. 2018;19:663-668.
6. Holm T, Ljung A, Häggmark T, Jurell G, Lagergren J. Extended abdominoperineal resection with gluteus maximus flap reconstruction of the pelvic floor for rectal cancer. Br J Surg. 2007;94:232-8.
7. West NP, Anderin C, Smith KJ, Holm T, Quirke P. Multicentre experience with extralevator abdominoperineal excision for low rectal cancer. Br J Surg. 2010;97:588-99.
8. Perdawood SK, Lund T. Extralevator versus standard abdominoperineal excision for rectal cancer. Tech Coloproctol. 2015;19:145-52.
9. Sayers AE, Patel RK, Hunter IA. Perineal hernia formation following extralevator abdominoperineal excision. Colorectal Dis. 2015;17:351-5.
10. Han JG, Wang ZJ, Gao ZG, Wei GH, Yang Y, Zhai ZW, Zhao BC, Yi BQ. Perineal Wound Complications After Extralevator Abdominoperineal Excision for Low Rectal Cancer. Dis Colon Rectum. 2019;62:1477-1484.
11. Christensen HK, Nerstrøm P, Tei T, Laurberg S. Perineal repair after extralevator abdominoperineal excision for low rectal cancerDis Colon Rectum. 2011;54:711-7.

12. Musters GD, Klaver CEL, Bosker RJI, Burger JWA, van Duijvendijk P, van Etten B, van Geloven AAW, de Graaf EJR, Hoff C, Leijtens JWA, Rutten HJT, Singh B, Vuylsteke RJCLM, de Wilt JHW, Dijkgraaf MGW, Bemelman WA, Tanis PJ. Biological Mesh Closure of the Pelvic Floor After Extralevator Abdominoperineal Resection for Rectal Cancer: A Multicenter Randomized Controlled Trial (the BIOPEX-study). Ann Surg. 2017;265:1074-1081.
13. van der Pas MH, Haglind E, Cuesta MA, Fürst A, Lacy AM, Hop WC, Bonjer HJ; COlorectal cancer Laparoscopic or Open Resection II (COLOR II) Study Group. Laparoscopic versus open surgery for rectal cancer (COLOR II): short-term outcomes of a randomised, phase 3 trial. Lancet Oncol. 2013;14:210-8.
14. Petersson J, Koedam TW, Bonjer HJ, Andersson J, Angenete E, Bock D, Cuesta MA, Deijen CL, Fürst A, Lacy AM, Rosenberg J, Haglind E; COlorectal cancer Laparoscopic or Open Resection (COLOR) II Study Group. Bowel Obstruction and Ventral Hernia After Laparoscopic Versus Open Surgery for Rectal Cancer in A Randomized Trial (COLOR II). Ann Surg. 2019;269:53-57.
15. Kelly AR. Surgical repair of post-operative perineal hernia. Aust NZJ Surg. 1960;29: 243-5.
16. Cawkwell I., Perineal hernia complicating abdominoperineal resection of the rectum. Br J Surg. 1963;50,:431-3.
17. Frydman GM, Polglase AL. Perineal approach for polypropylene mesh repair of perineal hernia. Aust NZJ Surg. 1989;59:895-7.
18. Cattell RB, Cunningham RM. Postoperative perineal hernia following resection of rectum: report of a case. Surg Clin North Am. 1944;24:679-83.
19. **Sakai** Y (Ed.) **Robotic total mesorectal excision.** Laparoscopic Surgery for Colorectal Cancer. The Netherlands: Springer; 2016.
20. Goliger J. Hernia: perineal.Surgery of the anus, rectum and Colon. 5th London: Balliere Tindall;1985. p. 701-702.
21. Peirce C, Martin S. Management of the perineal defect after abdominoperineal excision. Clin Colon Rectal Surg. 2016;29:160-7.
22. de Campos FG, Habr-Gama A, Araújo SE, Sousa AH Jr, Nahas CR, Lupinacci RM, Nahas SC, Kiss DR, Gama-Rodrigues J.Incidence and management of perineal hernia after laparoscopic proctectomy. Surg Laparosc Endosc Percutan Tech. 2005;15:366-70.
23. Wang YW, Huang LY, Song CL, Zhuo CH, Shi DB, Cai GX, Xu Y, Cai SJ, Li XX. Laparoscopic vs open abdominoperineal resection in the multimodality management of low rectal cancers. World J Gastroenterol. 2015;21:10174-83.
24. Yan X, Su H, Zhang S, Zhou L, Lu J, Yang X, Li J, Xue P, He Z, Wang M, Lu A, Ma J, Zang L, Cai Z, Sun J, Hong H, Zheng M, Feng B.Pelvic peritoneum closure reduces postoperative complications of laparoscopic abdominoperineal resection: 6-year experience in single center. Surg Endosc. 2021;35:406-414.
25. Foster JD, Tou S, Curtis NJ, Smart NJ, Acheson A, Maxwell-Armstrong C, Watts A, Singh B, Francis NK.. Closure of the perineal defect after abdominoperineal excision for rectal adenocarcinoma -

ACPGBI Position Statement. Colorectal Dis. 2018;20 Suppl 5:5-23.

26. Ito E, Yoshida M, Ohdaira H, Kitajima M, Suzuki Y. Case series of in situ pelvic floor reconstruction combining levator ani suture and negative pressure wound therapy for abdominoperineal resection. Ann Med Surg (Lond). 2019;43:64-67.
27. Blok RD, Musters GD, Borstlap WAA, Buskens CJ, Bemelman WA, Tanis PJ; Collaborative Dutch Snapshot Research Group. Snapshot Study on the Value of Omentoplasty in Abdominoperineal Resection with Primary Perineal Closure for Rectal Cancer. Ann Surg Oncol. 2018;25:729-736.
28. Musters GD, Klaver CEL, Bosker RJI, Burger JWA, van Duijvendijk P, van Etten B, van Geloven AAW, de Graaf EJR, Hoff C, Leijtens JWA, Rutten HJT, Singh B, Vuylsteke RJCLM, de Wilt JHW, Dijkgraaf MGW, Bemelman WA, Tanis PJ.Biological Mesh Closure of the Pelvic Floor After Extralevator Abdominoperineal Resection for Rectal Cancer: A Multicenter Randomized Controlled Trial (the BIOPEX-study). Ann Surg. 2017;265:1074-1081.
29. Jensen KK, Rashid L, Pilsgaard B, Møller P, Wille-Jørgensen P. Pelvic floor reconstruction with a biological mesh after extralevator abdominoperineal excision leads to few perineal hernias and acceptable wound complication rates with minor movement limitations: single-centre experience including clinical examination and interview. Colorectal Dis. 2014;16:192-7.
30. Han JG, Wang ZJ, Gao ZG, Wei GH, Yang Y, Zhai ZW, Zhao BC, Yi BQ. Perineal Wound Complications After Extralevator Abdominoperineal Excision for Low Rectal Cancer. Dis Colon Rectum. 2019;62:1477-1484.
31. Yang X, Jin C, Deng X, Wang M, Zhang Y, Wei M, Meng W, Wang Z. Laparoscopic Extralevator Abdominoperineal Excision of the Rectum with Primary Suturing: Short-Term Outcomes from Single-Institution Study. J Laparoendosc Adv Surg Tech A. 2016;26:40-6.
32. Yang T, Wei M, Deng X, Meng W, Wang Z. A Novel Laparoscopic Technique With a Bladder Peritoneum Flap Closure for Pelvic Cavity for Patients With Rigid Pelvic Peritoneum After Neoadjuvant Radiotherapy in Laparoscopic Extralevator Abdominoperineal Excision. Dis Colon Rectum. 2019;62:1136-1140.

Figures

Figure 1.

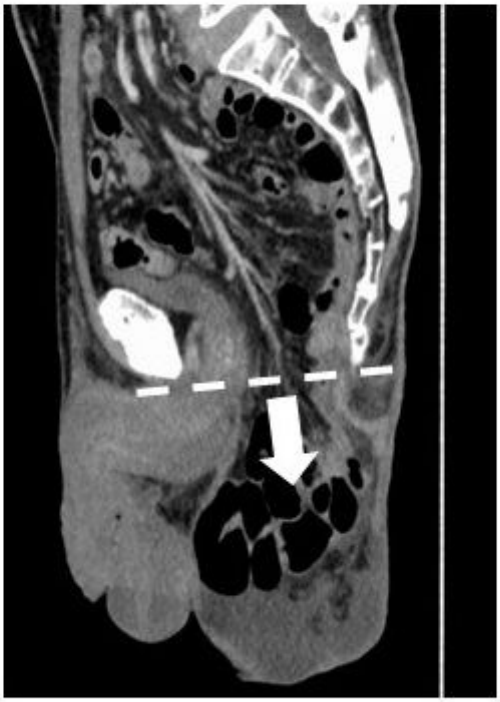

Figure 1

Diagnosis of postoperative perineal hernia by computed tomography is defined as the downward displacement of the intestine beyond the line described by computed tomography from the inferior margin of the pubis to the end of the coccyx.

Figure 2.

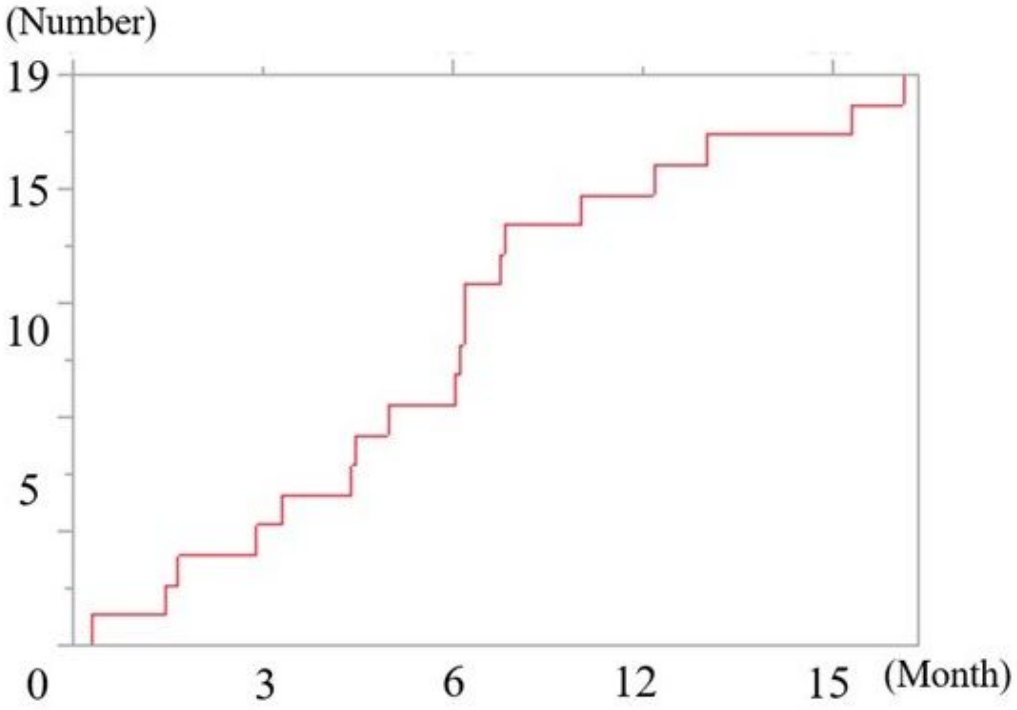

Figure 2

Cumulative number of patients with postoperative perineal hernia after endoscopic abdominoperineal excision.

Figure 3.

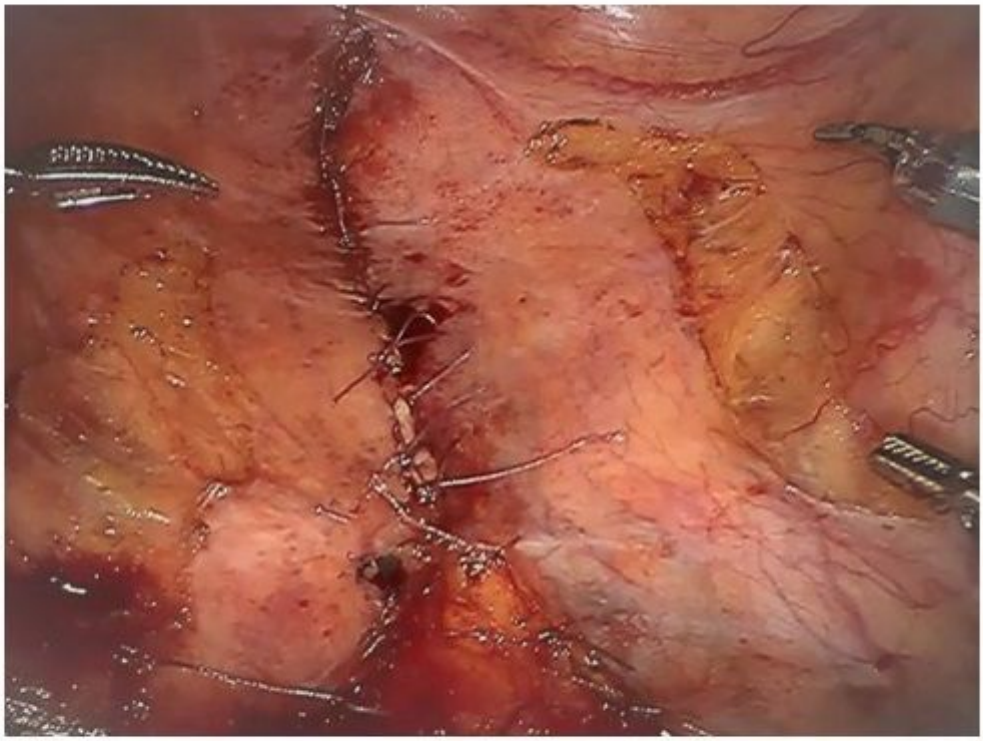

Figure 3

Endoscopic view of pelvic peritoneal closure with shallow incision.