

¹⁸F-Fluorodeoxyglucose Positron Emission Tomography/Computed Tomography imaging for the diagnosis of immune checkpoint inhibitors associated myocarditis

Stéphane Ederhy

Perrine Devos

Bruno Pinna

Elisa Funck-Brentano

Baptiste Abbar

Charlotte Fenioux

Ariel A. Cohen

Javid Moslehi

Marie Bretagne

Yves Allenbach

Dris Kharroubi

Joe-Elie Salem (✉ joeelie.salem@gmail.com)

Sorbonne <https://orcid.org/0000-0002-0331-3307>

Short Report

Keywords: Immune checkpoint inhibitors, myocarditis, FDG-PET

Posted Date: October 13th, 2021

DOI: <https://doi.org/10.21203/rs.3.rs-964963/v1>

License:  This work is licensed under a Creative Commons Attribution 4.0 International License.

[Read Full License](#)

Abstract

Immune-checkpoint inhibitors (ICI) have profoundly improved the prognosis of cancer patients but are associated with life-threatening myocarditis (incidence $\leq 1\%$). The diagnosis of ICI-myocarditis remains challenging necessitating the need for novel diagnostic strategies.

This single center cohort included 61 consecutive patients referred to our cardio-oncology unit for a suspicion of ICI-myocarditis with a positive troponin, between March 2019 and March 2021. In the 31 patients with suspected ICI-myocarditis with available FDG-PET, the median delay between admission and the first available FDG-PET performed was 12 days [interquartile-range:9-30]. Patients received ICI (ICI-monotherapy: 24/31, 77% and ICI-combination therapy: 7/31, 23%), mainly for lung cancer (n=10), melanoma (n=5), and kidney cancer (n=3). FDG-PET was performed using a standardized protocol involving dietary measures prior to PET, including fasting of at least 6h and a fat enriched diet without carbohydrates for 24h. FDG-PET platforms included Biograph-mCT-Flow Siemens (n=9/34, 26%) or Discovery-MI-5-Ring General Electric (n=25/34, 74%) devices and analysed using Singo.via Workstation (Siemens) by a nuclear medicine physician blinded to patients' medical records. Interpretation of FDG-PET was based on the following classification: 1/No FDG uptake, 2/Diffuse FDG uptake, 3/Focal FDG uptake, 4/Focal on diffuse FDG uptake.

An abnormal cardiac fixation on FDG-PET suggestive of myocarditis was observed in only 2/21 (9.5%) patients with otherwise definite ICI-myocarditis (1 diffuse, 1 focal), not different in proportion versus 1/7 (14.3%, 1 focal) patient without ICI-myocarditis ($p > 0.99$). The sensitivity, specificity, positive predictive and negative predictive values (with their 95% confidence-interval) of FDG-PET for ICI-myocarditis was 9.5% (1.2-30.4%), 85.7% (42.1-99.6%), 66% (17.5-95%), 24% (18.5-30.6%), respectively. Only 2/14 (14.2%) FDG-PET were positive despite being performed at a time in which ICI-myocarditis was fully active with troponin levels over ten-times the normal values versus 0/6 (0%, $p > 0.99$) for FDG-PET performed when troponin levels were abnormal but below ten-times the upper limit. Similarly, there was no difference in FDG-PET positivity rate for exams performed within 14 days (1/7, 14.3%; plus 3 inconclusive exams) versus those performed after 14 days (1/14, 7.2%; no inconclusive exams; $p > 0.99$) of hospital admission.

Altogether, our study suggests that FDG-PET has a limited diagnostic value for the diagnosis of ICI-Myocarditis.

Full Text

Immune-checkpoint inhibitors (ICI) have profoundly improved the prognosis of cancer patients but are associated with life-threatening myocarditis (incidence $\leq 1\%$). (1) The diagnosis of ICI-myocarditis remains challenging necessitating the need for novel diagnostic strategies. (2) Bonaca et al. recently proposed a case definition for ICI-myocarditis relying on identification of abnormalities using a combination of clinical symptoms, cardiac biomarkers (troponin), electrocardiogram, cardiac imaging (echocardiography, magnetic resonance imaging (MRI) and ^{18}F -Fluorodeoxyglucose Positron Emission

Tomography/Computed Tomography (FDG-PET)) and endomyocardial biopsy (EMB), the latter being considered as the gold-standard.(2) FDG-PET is commonly used to evaluate patients with suspected inflammatory cardiomyopathies such as sarcoidosis,(3) but its value in ICI-myocarditis is unknown.

This single center cohort (IRB#00011591, APHP-CSE-20-37_JOCARDITE) included 61 consecutive patients referred to our cardio-oncology unit for a suspicion of ICI-myocarditis with a positive troponin, between March 2019 and March 2021. The initial work-up for all patients included electrocardiogram, troponin measurement and echocardiography. Other diagnostic work-up could include cardiac MRI, coronary scanner or angiography, FDG-PET, skeletal muscular biopsy and EMB. In total, by applying modified Bonaca's criteria considering an ICI-myocarditis as definite when criteria for probable were present plus a positive muscular biopsy;(4) 33 patients were considered to have definite ICI-myocarditis and 28 were definitively ruled-out. A total of 34 cardiac FDG-PET (28 interpretable for cardiac fixation) were performed in 31 patients (mean age:66±15.5years; 65% male) including 21 with definite ICI-myocarditis and 10 patients where myocarditis was excluded (**Figure**). Patients were definitively ruled-out when they had an alternative diagnosis (n=3/10 coronary artery disease, n=1/10 capillary-leak syndrome, n=1/10 uncontrolled hypertension and n=1/10 viral myositis) or when investigational work-up including electrocardiogram, muscular and cardiac biopsies and a cardiac MRI were negative (n=4/10 unexplained mild troponin increase). In the 31 patients with suspected ICI-myocarditis with available FDG-PET, the median delay between admission and the first available PET-FDG performed was 12 days [interquartile-range:9-30]. Patients received ICI (ICI-monotherapy: 24/31, 77% and ICI-combination therapy: 7/31, 23%), mainly for lung cancer (n=10), melanoma (n=5), and kidney cancer (n=3). FDG-PET was performed using a standardized protocol involving dietary measures prior to PET, including fasting of at least 6h and a fat enriched diet without carbohydrates for 24h. FDG-PET platforms included Biograph-mCT-Flow Siemens (n=9/34, 26%) or Discovery-MI-5-Ring General Electric (n=25/34, 74%) devices and analysed using Singo.via Workstation (Siemens) by a nuclear medicine physician blinded to patients' medical records. Interpretation of FDG-PET was based on the following classification: 1/No FDG uptake, 2/Diffuse FDG uptake, 3/Focal FDG uptake, 4/Focal on diffuse FDG uptake.

An abnormal cardiac fixation on FDG-PET suggestive of myocarditis was observed in only 2/21 (9.5%) patients with otherwise definite ICI-myocarditis (1 diffuse, 1 focal), not different in proportion versus 1/7 (14.3%, 1 focal) patient without ICI-myocarditis (p>0.99). The sensitivity, specificity, positive predictive and negative predictive values (with their 95% confidence-interval) of FDG-PET for ICI-myocarditis was 9.5% (1.2-30.4%), 85.7% (42.1-99.6%), 66% (17.5-95%), 24% (18.5-30.6%), respectively. The delay between hospital admission and FDG-PET exams as a function of troponin levels and use of immunosuppressants in ICI-myocarditis patients is shown in **Figure**. Interestingly, the 4 FDG-PET performed in 3 ICI-myocarditis patients before start of any immunosuppressant were negative, despite an active disease with abnormal troponin levels (**Figure**). Only 2/14(14.2%) FDG-PET were positive despite being performed at a time in which ICI-myocarditis was fully active with troponin levels over ten-times the normal values versus 0/6(0%,p>0.99) for FDG-PET performed when troponin levels were abnormal but below ten-times the upper limit (**Figure**). Similarly, there was no difference in FDG-PET positivity rate for

exams performed within 14 days (1/7, 14.3%; plus 3 inconclusive exams) versus those performed after 14 days (1/14, 7.2%; no inconclusive exams; $p>0.99$) of hospital admission.

Altogether, our study suggests that FDG-PET has a limited diagnostic value for the diagnosis of ICI-Myocarditis. This finding is particularly relevant when considering that the 95% confidence interval upper bound of FDG-PET sensitivity for ICI-myocarditis is below 30%. Even though this study is the first to assess the value of FDG-PET in ICI-myocarditis, several limitations should be acknowledged. Despite efforts made to decrease metabolic cardiac activity by an appropriate diet, 17.6% of FDG-PET were still inconclusive, particularly when performed early after admission. A total of 47% FDG-PET were realized after 14 days of admission, due to real-life technical issues or patient's condition being unsuitable for FDG-PET. However, the rate of positive exam was not different between exams realized before and after 14 days, as well as those realized while troponin levels were above versus below ten-times the normal upper limit. Notably, in the group of patients with a final diagnosis of ICI-myocarditis, most FDG-PET exams were done while patients were on immunosuppressants, which may have contributed to the low positive rate, but ICI-myocarditis treatment cannot be delayed.(1, 5) Finally, the diagnostic value of other PET tracers, particularly those tagging specifically immune cells is unknown in ICI-myocarditis setting and deserve further evaluation.

Declarations

Competing interests statement:

The authors declare no competing interests.

References

1. Salem J-E, Manouchehri A, Moey M et al. Cardiovascular toxicities associated with immune checkpoint inhibitors: an observational, retrospective, pharmacovigilance study. *The Lancet Oncology* 2018;19:1579–1589.
2. Bonaca MP, Olenchock BA, Salem JE et al. Myocarditis in the Setting of Cancer Therapeutics: Proposed Case Definitions for Emerging Clinical Syndromes in Cardio-Oncology. *Circulation* 2019;140:80–91.
3. Blankstein R, Osborne M, Naya M et al. Cardiac positron emission tomography enhances prognostic assessments of patients with suspected cardiac sarcoidosis. *J Am Coll Cardiol* 2014;63:329–36.
4. Johnson DB, Balko JM, Compton ML et al. Fulminant Myocarditis with Combination Immune Checkpoint Blockade. *N Engl J Med* 2016;375:1749–1755.
5. Zhang L, Zlotoff DA, Awadalla M et al. Major Adverse Cardiovascular Events and the Timing and Dose of Corticosteroids in Immune Checkpoint Inhibitor-Associated Myocarditis. *Circulation* 2020;141:2031–2034.

Figures

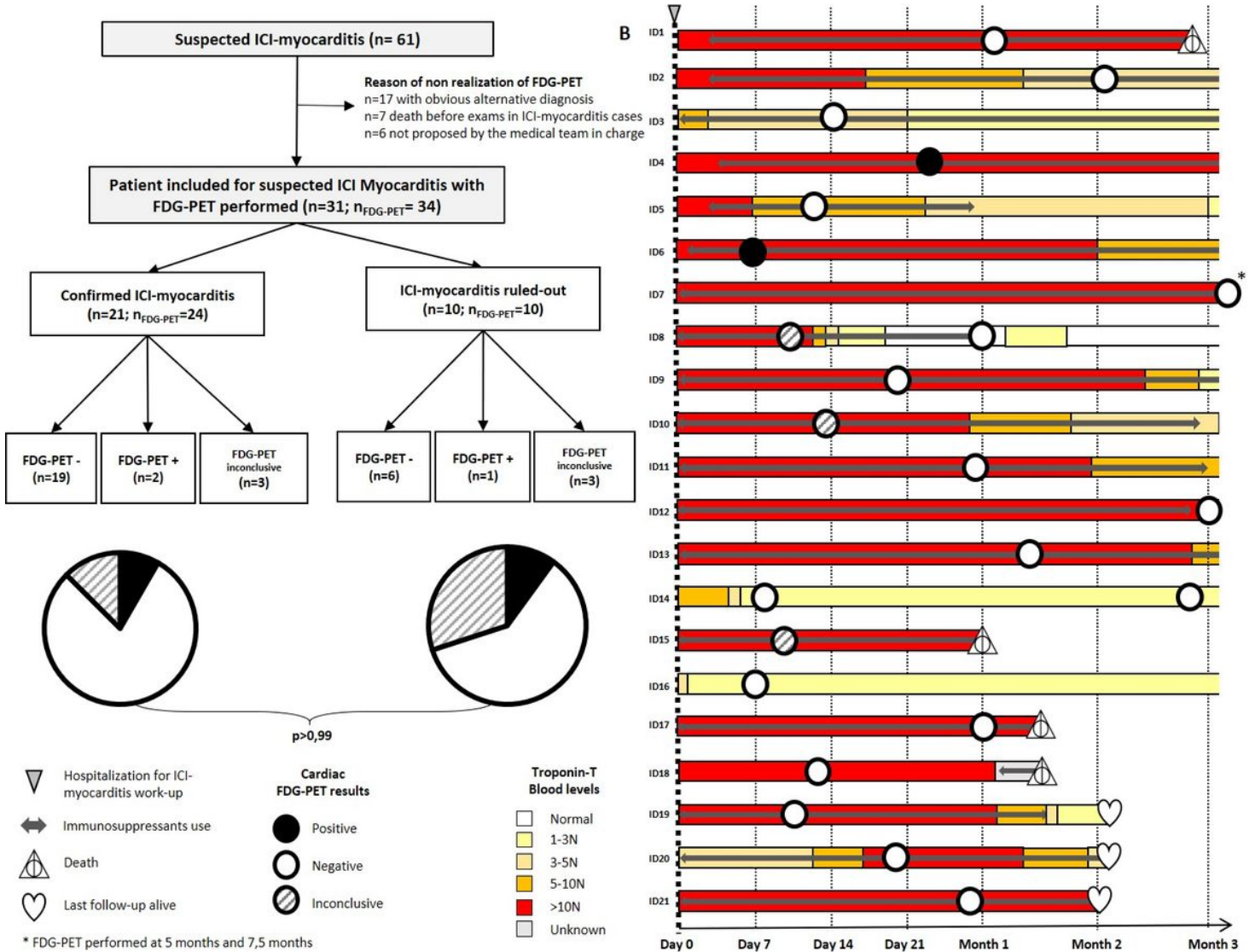


Figure 1

Flow-chart of the patients admitted for suspicion of ICI-myocarditis in our institution as a function of their work-up for 18F-Fluorodeoxyglucose Positron Emission Tomography/Computed Tomography imaging (FDG-PET) (A). Delay between hospital admission and FDG-PET exams as a function of the time course evolution of troponin level and of the immunosuppressive treatments requirements in ICI-myocarditis patients with FDG-PET available (B).