Combined Endoscopic and Exoscopic Resection of Intracranial Epidermoid Cysts

Li Chuzhong
Capital Medical University
Li Zhenye
Capital Medical University
Gui Songbai
Capital Medical University
Zhao Peng
Capital Medical University
Bai Jiwei
Capital Medical University
Cao Lei
Capital Medical University
Cheng Sen
Capital Medical University
Liu Chunhui
Capital Medical University
Zhu Haibo
Capital Medical University
Yazhuo Zhang (zyz2004520@163.com)
Beijing Neurosurgical Institute https://orcid.org/0000-0002-8583-2580

Research Article

Keywords: Intracranial epidermoid cyst, Endoscope, Exoscope, Surgical resection

Posted Date: October 29th, 2021

DOI: https://doi.org/10.21203/rs.3.rs-980980/v1

Abstract

Objective

In the past ten years, a fully endoscopic technique has also been widely used. Exoscope has also been developed for microneurosurgery which offers quality image and convenient manipulation. This article aims at introducing an endoscopic-exoscopic technique for the resection of epidermoid cysts.

Methods

We retrospectively analyzed the patients with intracranial epidermoid cysts who received whole course combined endoscopic and exoscopic resection between 2017 and 2020 at our institution, to explore the benefit of combined endoscopic and exoscopic resection of intracranial epidermoid cysts and evaluated the clinical utility of endoscopic-exoscopic technique.

Results

A total of 17 patients were enrolled in the study. Of all patients, 6 patients (6/17, 35.3%) underwent total resection, 10 patients (10/17, 58.8%) underwent subtotal resection (residual capsule and/or) and 1 patients (1/17, 5.9%) underwent partial resection. Postoperative surgical complications were seen in 3 patients (3/17, 17.6%), including intracranial infection in 2 patients (2/17, 11.8%), and a delayed postoperative hematoma observed in the seventh day after operation for 1 patient (1/17, 5.9%), who was treated in a conservative manner and recovered smoothly from the hemorrhage. The median follow-up time was 33.3 months (range 14.5-54.5 months). During the follow-up period, there was no recurrence of the tumors that received total resection. 2 patients developed residual tumor regrowth but did not show any symptom therefore no further surgery was required.

Conclusions

Endoscopic-exoscopic technique is safe and efficient in the resection of intracranial epidermoid cysts with panoramic views and superior maneuverability. With further development and accumulation of practical experiences, the endoscopic-exoscopic technique can also be applied in the resection of other intracranial tumors.

Introduction

Intracranial epidermoid cysts are congenital, slow-growing and histologically benign tumors, representing about 1% of all intracranial tumors[4, 10, 7].They are commonly known to arise from misplaced stratified squamous epithelium during neural tube formation and separation. Epidermoid tumors generally occur in the cerebellopontine angle (CPA) and parasellar regions. They tend to break through the subarachnoid

space, and extend into multiple compartments and encase surrounding critical neurovascular structures which make radical surgery difficult to perform.

Traditionally, the epidermoid cysts resection was performed with the aid of an operating microscope. Later on, the endoscope has been considered to be a more effective tool to improve tumor resection and decrease the incidence of complications for epidermoid cysts[1, 15, 6, 20, 19]. Endoscopes have been used as an assisting tool to microscope in resection of epidermoid cysts for the past two decades in our institution. Combined microscopic-endoscopic technique was also used for epidermoid cysts resection in other similar institutions [13, 21, 16, 1, 8, 14, 17]. However, when such technique is used, it is technically infeasible to use microscope and endoscope concurrently, because the specifications and the size of the microscope does not allow surgeons to use both microscope and endoscope simultaneously [12]. This has limited the application of microscopic-endoscopic technique in epidermoid cysts resection.

In the past ten years, a fully endoscopic technique has also been widely used[4, 3, 19, 6]. When endoscope was used alone, we found it possible that the neurovascular structures cannot be seen through the endoscope when endoscope passes the neurovascular structures. As a result, in fully endoscopic operations, there was a risk of damage to neurovascular structures that were out of the scope of endoscope.

Exoscope has been developed for microneurosurgery which offers quality image and convenient manipulation[9]. Our institution has performed an observational study with combined endoscopic and exoscopic resection of intracranial epidermoid cysts. This article aims at introducing an endoscopic-exoscopic technique for the resection of epidermoid cysts. We retrospectively analyzed the patients with intracranial epidermoid cysts who underwent combined endoscopic and exoscopic resection, to explore the benefit of combined endoscopic and exoscopic resection of intracranial epidermoid cysts and evaluated the clinical utility of endoscopic-exoscopic technique.

Materials And Methods

Patients

Patients with intracranial epidermoid cysts who received whole course combined endoscopic and exoscopic resection between 2017 and 2020 at our institution were analyzed. The diagnosis of epidermoid cysts was confirmed based on MRI information, intraoperative finding and histopathological analysis. Patients' clinical characteristics including demographic data, symptoms, cyst location and surgical information were reviewed. Cyst volume was calculated by the formula $V= (A \times B \times C/2)$, where A, B, and C represent the maximum diameters of the cyst in each of 3 dimensions[18]. The study protocol was approved by the Ethics Committee of Beijing Tiantan Hospital, and informed consent was obtained from all patients.

Surgical Procedure

Intraoperative neurophysiological monitoring was conducted for safely removing the tumor. After craniotomy, a 90° exoscope (Karl Storz, Tuttlingen, Germany) and a 0°rigid endoscope (Karl Storz, Tuttlingen, Germany) were combinedly used for tumor resection. Both exoscope and endoscope were fixed with pneumatic holding arms (Karl Storz, Tuttlingen, Germany) respectively(Figure 1A). The surgical procedures were conducted as follows: firstly, cerebrospinal fluid was fully released under exoscope. Subsequently, endoscope was introduced for tumor resection. As the keratin contents continues to be evacuated, endoscope needs to get close to or cross cranial nerve and vascular structures to view the tumors hidden around the corner. At the same time, exoscope was used to see what is around the endoscope. The images of endoscope and exoscope can be displayed on the same screen in parallel or separately (Figure 1B). Tumor capsule was removed with bimanual technique by sharp dissection. However, if the tumor capsule adhered closely to critical neurovascular structures, the adhesive part of the tumor capsule was left in place. If the scope of 0°rigid endoscope was limited, a 30°rigid endoscope (Karl Storz, Tuttlingen, Germany) was used for further inspecting and resection. After the tumor was removed, multi-angle endoscopic-assisted irrigation was performed to clear the residual irritant contents.

Surgical Outcome Measurements

Surgical Outcome Measurements
Total resection was defined as complete removal of the tumor capsule during surgery and postoperative MRI showed no remnant tumor. Subtotal resection was defined as incomplete resection of cyst contents (residual cyst content volume ≤10%) and/or residual capsule. Partial resection was defined as residual cyst content volume >10%. After surgery, outpatient review and MRI scan were conducted at 3, 6 months and then annually.

Statistical Analysis

Statistical analysis was performed using the SPSS v21.0 software (IBM Corp, Armonk, NY, USA). The gross total resection rates within different groups were determined by Fisher exact tests. $P<0.05$ was considered statistically significant.

Results

Patient Demographics

A total of 17 patients were enrolled in the study, including 7 males (41.2%) and 10 females (58.8%). The median age at the time of craniotomy was 39 years (range 22-68years).13 patients had de novo tumors without prior treatment, and 4 patients had a recurrence after surgery at another institution. Trigeminal neuralgia was the most common presenting symptom, occurring in 9 patients (9/17, 52.9%). Diplopia occurred in 3 patients (3/17, 17.6%), among which 2 patients presented with abducens nerve palsy (2/17, 11.8%) and one patient acquired palsy of abducens and oculomotor nerves (1/17, 5.9%). 3 patients (3/17,

17.6%) presented with gait ataxia, one with numbness (1/17, 5.9%), one with hearing impairment (1/17, 5.9%).

1 patient (1/17, 5.9%) presented with headache and 1 patient (1/17, 5.9%) presented with hemifacial spasm and hearing impairment.

Preoperative MRI studies were conducted for every case and exhibited variable distributions and volumes of cysts. The distributions of epidermoid cysts included CPA, suprasellar cistern, prepontine cistern, parasellar region, cavernous sinus region and quadrigeminal cistern, specifically: 9 patients had epidermoid cysts in the CPA, suprasellar cistern and prepontine cistern. 3 patients had epidermoid cysts in the CPA and prepontine cistern. 2 patients had epidermis cysts in the CPA, parasellar and cavernous sinus region, suprasellar cistern and prepontine cistern. 1 patient had epidermoid cysts in the CPA, suprasellar cistern, prepontine cistern and quadrigeminal cistern.1 patient had epidermoid cysts in the CPA, parasellar and cavernous sinus region and suprasellar cistern. 1 patient had epidermoid cysts in the parasellar region, suprasellar cistern and prepontine cistern. To summarize, 3 cysts were distributed in 2 areas, 10 cysts were distributed in 3 areas, 2 cysts were distributed in 4 areas and 2 cysts were distributed in 5 areas. Among all patients, 12 of them had epidermoid cysts confined to one side and 5 of them had epidermoid cysts spread into the contralateral side. The median cyst volume was 25.1cm^3(range 4.1–157.7cm^3). The patient characteristics are summarized in Table 1.

Table 1
Characteristics of patients

Characteristic	Value
Age (years)	
Median	39
Range	22-68
Gender	
Male	7
Female	10
Tumor status	
Primary	13
Recurrent	4
Cyst side	
Left	7
Right	5
Both	5
Volume (cm3)	
<25	8
≥25	9

Surgical Approach

Different approaches were used for removing epidermoid cysts according to location of the cysts. 13 patients underwent retrosigmoid approach. 2 patients underwent combination of subtemporal-occipital and retrosigmoid approach. 1 patient underwent frontotemporal approach and 1 patient underwent combination of frontotemporal and retrosigmoid approach.

Extent Of Tumor Resection

Of all patients, 6 patients (6/17, 35.3%) underwent total resection, 10 patients (10/17, 58.8%) underwent subtotal resection (Figure 3) and 1 patients (1/17, 5.9%) underwent partial resection.

To explore the factors affecting resection, we analyzed the relevance between total resection rates and the distributions and volumes of cysts. We found that epidermoid cysts spread into the contralateral side

was significantly associated with nontotal resection(P<0.05) (Table 2). However, cyst volume and number of areas invaded by the cysts were not associated with total resection rates (Table 2).

Table 2
Factors associated with total resection rates

Parameter	Total resection	Nontotal resection	*P* Value
Number of distributions			1.000
≤3	5 (38.5%)	8 (61.5%)	
>3	1 (25.0%)	3 (65.0%)	
Contralateral growth			0.043
No	6 (54.5%)	5 (45.5%)	
Yes	0 (0%)	6 (100%)	
Tumor volume			0.333
<26	5 (45.5%)	6 (54.5%)	
≥ 26 cm3	1 (16.7%)	5 (83.3%)	

Clinical Outcome And Complications

The clinical symptoms are observed postoperatively. Pain caused by trigeminal neuralgia disappeared in all of the 9 patients. 2 of 3 patients who presented with gait ataxia showed significant improvement in their symptoms. Pain relieved in the patient who presented with headache. Hemifacial spasm disappeared for the only patient with the symptom, while the patient's hearing impairment still remained. No improvement of symptoms was found for the 3 patients with diplopia.

Postoperative surgical complications were seen in 3 patients (3/17, 17.6%), including intracranial infection in 2 patients (2/17, 11.8%), and a delayed postoperative hematoma observed in the seventh day after operation for 1 patient (1/17, 5.9%), who was treated in a conservative manner and recovered smoothly from the hemorrhage.

The median follow-up time was 33.3 months (range 14.5-54.5 months). During the follow-up period, there was no recurrence of the tumors that received total resection. 2 patients developed residual tumor regrowth but did not show any symptom therefore no further surgery was required.

Discussion

The advantages and disadvantages of endoscope

It is well known that a complete resection of epidermoid cysts provides a cure for the patients[2] but there are two main difficulties when surgeons perform the resection: (1) the cyst wall is very thin and often extends widely into distant corners and cisterns; (2) the wall of epidermoid cysts often adheres to blood vessels and nerves. Both difficulties can be effectively solved if there is a way to provide surgeons with a direct visualization of the epidermoid cysts. Operating microscope has been used for epidermoid cysts resection in the past, but the straight-line vision of microscope causes blind areas in the deep structures, the surgeon cannot see into the spaces outside of the view of microscopes, which significantly limits the surgeon's ability to perform the total resection of epidermoid cysts. Surgeons need to be able to see into the spaces outside of the view of microscopes during surgery.

Nowadays, it is evident that endoscopes can help find and resect epidermoid cysts in remote areas that are outside of the scopes of the microscopes, which facilitate maximum epidermoid cysts resection. Coupled with high definition camera system, endoscopes offer advantage of higher magnification and wider views. Angled endoscopes permit the surgeon to look around surgical corners, and bimanual operation can be achieved through a fixing device. With the recent development of neuroendoscope, whole course neuroendoscopic resection of epidermoid cysts has become feasible. Fully endoscopic surgery for neuroendoscopic resection of epidermoid cysts could decrease traction on the brain, improve total resection rates, and decrease postoperative complications[18, 3, 19, 11]. However, there is one disadvantage in such fully endoscopic surgery. Moving in and out of either side of operation area may result in a collision between the shaft and the neurovascular structures that endoscope is unable to visualize when looking forward at the tumor. Therefore, exoscope has been introduced in association with the endoscopes in order to overcome this limitation.

The Advantages Of Endoscopic-exoscopic Technique

Exoscope works outside of the body cavity and is therefore more similar to the operating microscope than a traditional endoscope. Because exoscope is lighter than microscope, the combination of endoscope and exoscope renders much more convenience during surgery. In the present study, we described our experience with 17 patients who had removal of intracranial tumors with a combined endoscopic and exoscopic approach. The advantages of endoscopic-exoscopic technique can be described as follows: (1) the exoscope can compensate the defect of endoscope's visual field. (2) because exoscope is lighter than the operating microscope, the combining endoscopic and exoscopic technique provide a higher degree of maneuverability and the exoscope and endoscope can be used concurrently. Considering the lack of stereopsis compared with operating microscope, an initial learning curve period was necessary for neurosurgeons. Based on our study, in spite of the presence of large recurrent epidermoid cysts among all patients and the criteria for the defining total resection was strict, the total resection rates and postoperative surgical complications of our study were compatible with previous studies [21, 5]. Consequently, the endoscopic-exoscopic technique is safe and efficient in the resection of intracranial epidermoid cysts.

Limitations

The findings of this study have to be seen in light of some limitations. Firstly, the small sample size may introduce some selection bias which may compromise the conclusion drawn from the study. A larger sample size is necessary to accurately evaluate the effectiveness of endoscopic-exoscopic technique. Secondly, there is no certainty that the capsule of giant epidermoid cysts was completely removed, which made it challenging to confirm the total removal of the epidermoid cysts. The third limitation concerns the limited follow-up time. Given a longer follow-up period, the study will generate more accurate conclusions in further study.

In conclusion, endoscopic-exoscopic technique is safe and efficient in the resection of intracranial epidermoid cysts with panoramic views and superior maneuverability. With further development and accumulation of practical experiences, the endoscopic-exoscopic technique can also be applied in the resection of other intracranial tumors.

Abbreviations

Cerebellopontine angle, CPA

Declarations

Funding This work was supported by the National Natural Science Foundation of China (82072804).**Conflicts of interest**The authors declare that they have no conflict of interest.

Availability of data and material The research data is available upon a request.

Code availability Not applicable.

Ethics approval The study protocol was approved by the Ethics Committee of Beijing Tiantan Hospital.

Consent to participate Informed consent was obtained from all patients.

Consent for publication This manuscript is approved by all authors for the submission.

Authors' contributions

Li Chuzhong Conceptualization, methodology, formal analysis, writing—original draft, and writing—review and editing.

Li Zhenye Methodology, acquisition of data, formal analysis, writing—original draft, and writing—review and editing.

Gui Songbai Acquisition of data, supervision and formal analysis.

Zhao Peng Acquisition of data.

Bai Jiwei Acquisition of data.

Cao Lei Acquisition of data.

Cheng Sen Acquisition of data.

Liu Chunhui Acquisition of data.

Zhu Haibo Acquisition of data.

Zhang Yazhuo Conceptualization, supervision, and project administration.

References

1. Abolfotoh M, Bi WL, Hong CK, Almefty KK, Boskovitz A, Dunn IF, Al-Mefty O (2015) The combined microscopic-endoscopic technique for radical resection of cerebellopontine angle tumors. Journal of neurosurgery 123:1301-1311. doi:10.3171/2014.10.jns141465
2. Aboud E, Abolfotoh M, Pravdenkova S, Gokoglu A, Gokden M, Al-Mefty O (2015) Giant intracranial epidermoids: is total removal feasible? Journal of neurosurgery 122:743-756. doi:10.3171/2014.11.jns1481
3. Caballero-García J, Morales-Pérez I, Michel-Giol-Álvarez A, Aparicio-García C, López-Sánchez M, Huanca-Amaru J (2020) Endoscopic retrosigmoid keyhole approach in cerebellopontine angle tumors. A surgical cohort. Neurocirugia (Asturias, Spain). doi:10.1016/j.neucir.2020.10.001
4. Cecchini G, Sorenson TJ, Graffeo CS, Vitale G, Di Biase F (2019) Two-Operator Endoscopic Resection of Left Cerebellopontine Angle Epidermoid. World neurosurgery 132:398. doi:10.1016/j.wneu.2019.09.008
5. Farhoud A, Khedr W, Aboul-Enein H (2018) Surgical Resection of Cerebellopontine Epidermoid Cysts: Limitations and Outcome. Journal of neurological surgery Part B, Skull base 79:167-172. doi:10.1055/s-0037-1606220
6. Gopakumar S, Srinivasan VM, Sharma H, Cherian J, Patel AJ (2021) Fully Endoscopic Resection of an Epidermoid Cyst of the Cerebellopontine Angle: Bilateral Resection via a Unilateral Approach. Operative neurosurgery (Hagerstown, Md) 20:E152-e155. doi:10.1093/ons/opaa291
7. Hasegawa M, Nouri M, Nagahisa S, Yoshida K, Adachi K, Inamasu J, Hirose Y, Fujisawa H (2016) Cerebellopontine angle epidermoid cysts: clinical presentations and surgical outcome. Neurosurgical review 39:259-266; discussion 266-257. doi:10.1007/s10143-015-0684-5
8. Li J, Zhong D, Lü D, Huang HY, Du W, Yang J, Wu YT, Xia HJ, Tang WY, Sun XC (2018) [Neuroendoscopy assisted microneurosurgery for posterior cranial fossa lesion]. Zhonghua yi xue za zhi 98:1311-1316. doi:10.3760/cma.j.issn.0376-2491.2018.17.006

9. Mamelak AN, Nobuto T, Berci G (2010) Initial clinical experience with a high-definition exoscope system for microneurosurgery. Neurosurgery 67:476-483. doi:10.1227/01.neu.0000372204.85227.bf
10. Nagasawa D, Yew A, Safaee M, Fong B, Gopen Q, Parsa AT, Yang I (2011) Clinical characteristics and diagnostic imaging of epidermoid tumors. Journal of clinical neuroscience : official journal of the Neurosurgical Society of Australasia 18:1158-1162. doi:10.1016/j.jocn.2011.02.008
11. Peng Y, Yu L, Li Y, Fan J, Qiu M, Qi S (2014) Pure endoscopic removal of epidermoid tumors of the cerebellopontine angle. Child's nervous system : ChNS : official journal of the International Society for Pediatric Neurosurgery 30:1261-1267. doi:10.1007/s00381-014-2357-z
12. Sack J, Steinberg JA, Rennert RC, Hatefi D, Pannell JS, Levy M, Khalessi AA (2018) Initial Experience Using a High-Definition 3-Dimensional Exoscope System for Microneurosurgery. Operative neurosurgery (Hagerstown, Md) 14:395-401. doi:10.1093/ons/opx145
13. Schroeder HW, Oertel J, Gaab MR (2004) Endoscope-assisted microsurgical resection of epidermoid tumors of the cerebellopontine angle. Journal of neurosurgery 101:227-232. doi:10.3171/jns.2004.101.2.0227
14. Singh I, Rohilla S, Kumar P, Krishana G (2018) Combined microsurgical and endoscopic technique for removal of extensive intracranial epidermoids. Surgical neurology international 9:36. doi:10.4103/sni.sni_392_17
15. Takemura Y, Inoue T, Morishita T, Rhoton AL, Jr. (2014) Comparison of microscopic and endoscopic approaches to the cerebellopontine angle. World neurosurgery 82:427-441. doi:10.1016/j.wneu.2013.07.013
16. Tuchman A, Platt A, Winer J, Pham M, Giannotta S, Zada G (2014) Endoscopic-assisted resection of intracranial epidermoid tumors. World neurosurgery 82:450-454. doi:10.1016/j.wneu.2013.03.073
17. Vaz-Guimaraes F, Gardner PA, Fernandez-Miranda JC (2018) Endoscope-Assisted Retrosigmoid Approach for Cerebellopontine Angle Epidermoid Tumor. Journal of neurological surgery Part B, Skull base 79:S409-s410. doi:10.1055/s-0038-1669983
18. Vaz-Guimaraes F, Koutourousiou M, de Almeida JR, Tyler-Kabara EC, Fernandez-Miranda JC, Wang EW, Snyderman CH, Gardner PA (2018) Endoscopic endonasal surgery for epidermoid and dermoid cysts: a 10-year experience. Journal of neurosurgery:1-11. doi:10.3171/2017.7.jns162783
19. Verma B, Dabholkar YG (2020) Role of endoscopy in surgical management of cholesteatoma: A systematic review. Journal of otology 15:166-170. doi:10.1016/j.joto.2020.06.004
20. Vernon V, Naik H, Guha A (2021) Surgical management of cerebellopontine angle epidermoid cysts: an institutional experience of 10 years. British journal of neurosurgery:1-10. doi:10.1080/02688697.2020.1867058
21. Watanabe T, Ito E, Sato T, Ichikawa M, Oda K, Ando H, Matsumoto Y, Sakuma J, Saito K (2011) Combined microsurgical and endoscopic removal of extensive suprasellar and prepontine epidermoid tumors. Neurologia medico-chirurgica 51:684-688. doi:10.2176/nmc.51.684

Figures

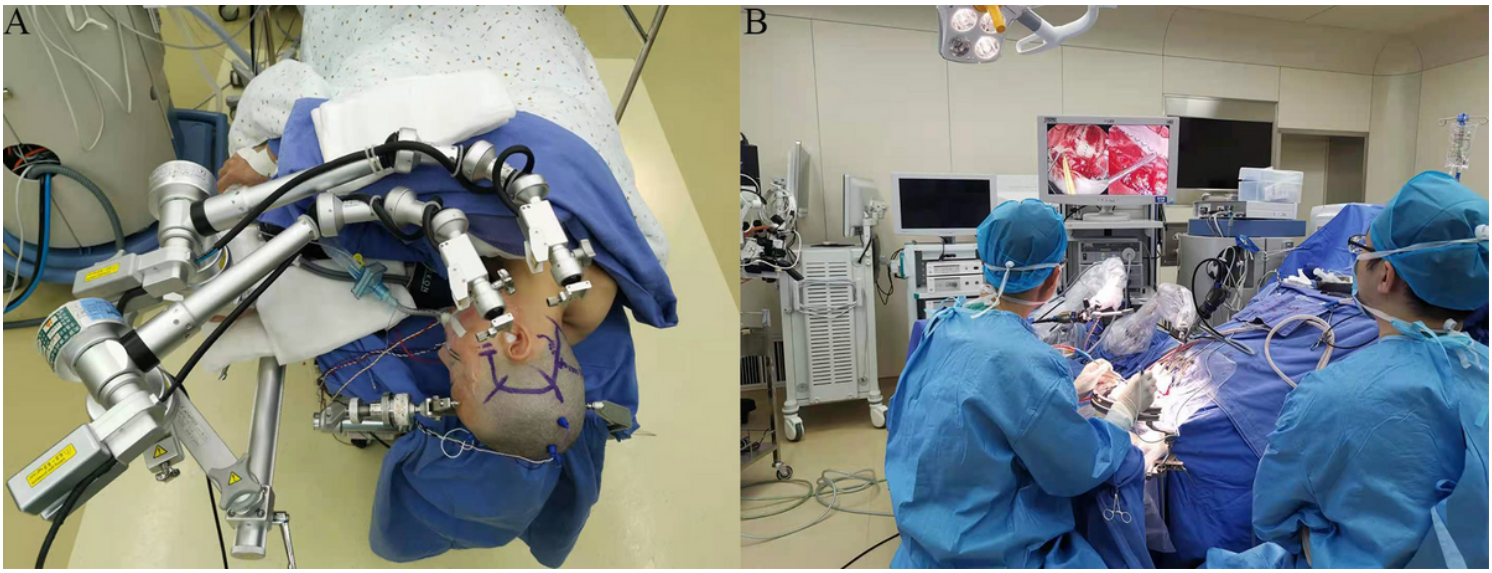

Figure 1

Legend not included with this version

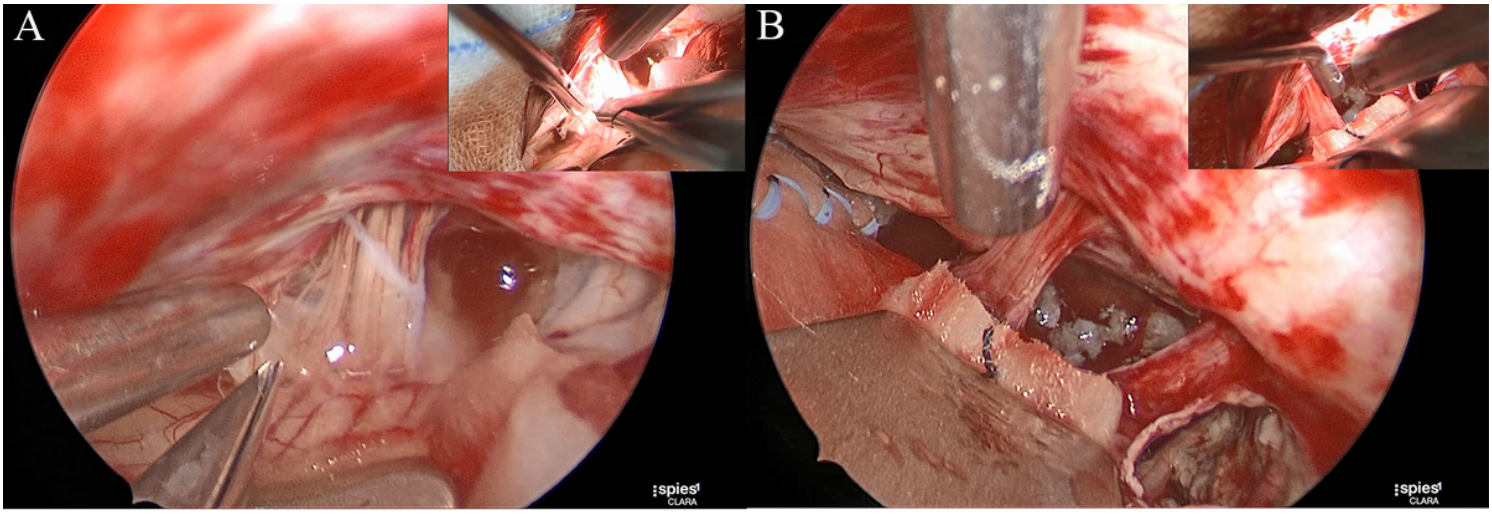

Figure 2

Legend not included with this version

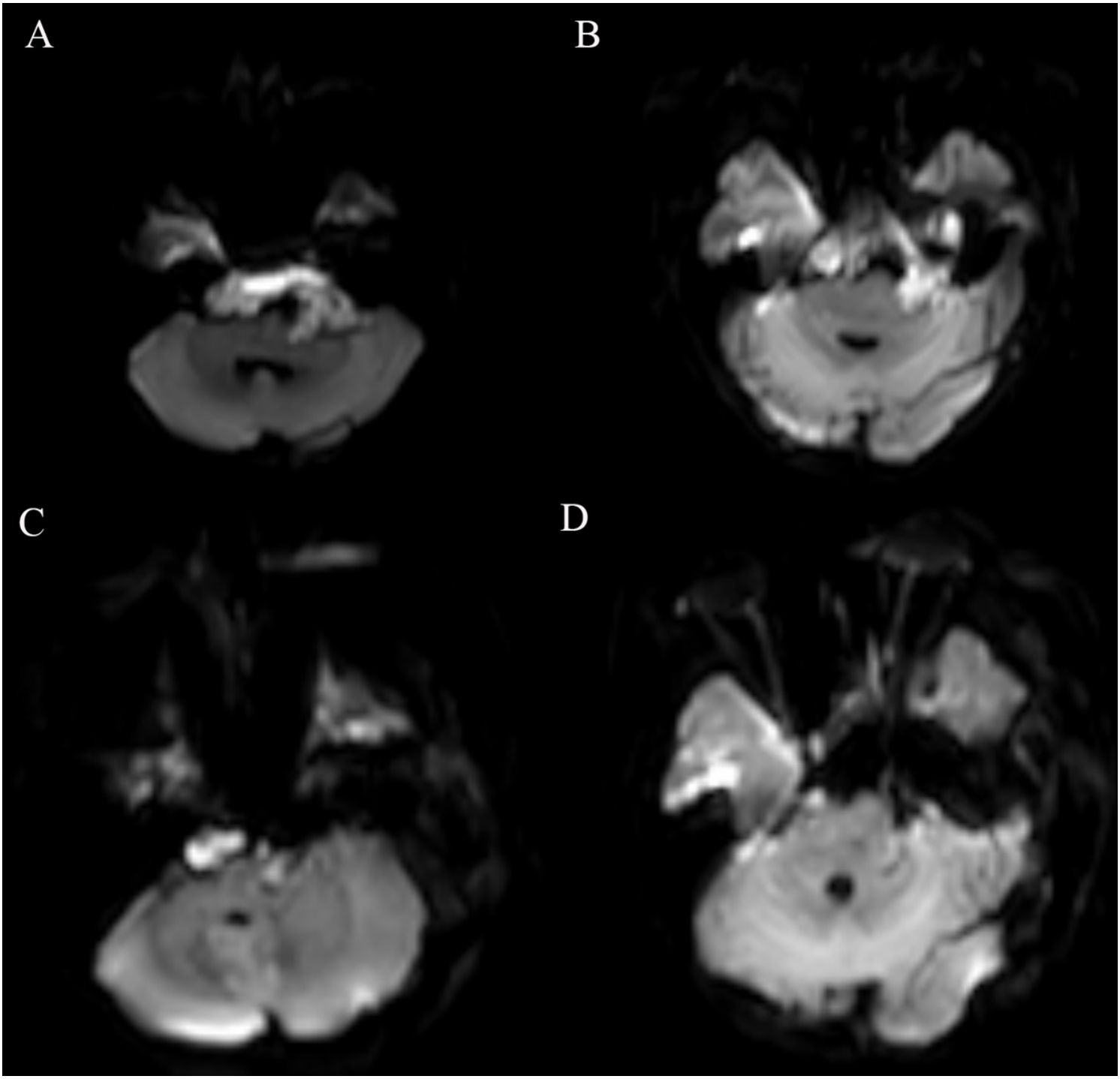

Figure 3

Legend not included with this version