Trans-Scapular Approach Coil Localization for Scapular-Blocked Pulmonary Nodules: A Retrospective Study

Juan Wu
Taizhou Hospital of Zhejiang Province
Min-Ge Zhang
Taizhou Hospital of Zhejiang Province
Jin Chen
Taizhou Hospital of Zhejiang Province
Wen-Bin Ji (jiwenbin2016@163.com)
Taizhou Hospital of Zhejiang Province

Research article

Keywords: computed tomography, scapular, coil, pulmonary nodule

Posted Date: October 30th, 2020

DOI: https://doi.org/10.21203/rs.3.rs-98967/v1

Version of Record: A version of this preprint was published on March 25th, 2021. See the published version at https://doi.org/10.1186/s13019-021-01446-6.

Abstract

Background: Preoperative computed tomography (CT)-guided coil localization (CL) is commonly employed to facilitate the video-assisted thoracoscopic surgery (VATS)-guided diagnostic wedge resection (WR) of pulmonary nodules (PNs). When a scapular-blocked PN (SBPN) will be localized, the trans-scapular CL (TSCL) should be performed. In this study, we investigated the safety, feasibility, and clinical efficacy of preoperative CT-guided TSCL for SBPNs.

Materials and Methods: From January 2014 to September 2020, a total of 152 patients with PNs underwent CT-guided CL prior to VATS-guided WR. Among them, 14 patients had the SBPNs and underwent TSCL procedure.

Results: A total of 14 SBPNs were localized in the 14 patients. The mean diameter of the 14 SBPNs was 7.4 ± 2.4 mm. Technical success rate of puncture of the scapula was 100%. No complications occurred near the scapula. Technical success rate of CL was 92.9%. One coil dropped off when performing the VATS procedure. The mean duration of the TSCL was 14.2 ± 2.7 min. Two patient (14.3%) developed aysmptomatic pneumothorax after TSCL. Technical success rate of VATS-guided WR was 92.9%. The patient who experienced technical failure of TSCL directly underwent lobectomy. The mean VATS procedure duration and blood loss were 90.0 ± 42.4 min and 62.9 ± 37.2 ml, respectively. The final diagnoses of the 14 SBPNs included invasive adenocarcinoma (n = 4), adenocarcinoma in situ (n = 9), and benign (n = 1).

Conclusions: Preoperative CT-guided TSCL can be safely and simply used to facilitate high successful rates of VATS-guided WR of SBPNs.

Background

Pulmonary nodules (PNs) are nowadays commonly detected by chest computed tomography (CT) [1–5]. Although most of the PNs can be regularly followed up by CT according the Fleischner Society or Lung-RADS guidelines [6, 7], many intermediate or high risk PNs should be managed actively. At present, lung biopsy or video-assisted thoracoscopic surgery (VATS)-guided diagnostic wedge resection (WR) have been widely used to diagnose the PNs [8–10]. Although lung biopsy is a mini-invasive procedure which only required local anaesthesia, approximate 10% diagnostic failure is the shortcoming of lung biopsy [11].

Preoperative CT-guided localization is commonly employed to facilitate the VATS-guided diagnostic WR of PNs because it decreases the need for thoracotomy or VATS anatomic resection for the diagnosis of PNs [8, 12]. Localized materials usually include coils, hook-wire, methylene blue, and radio-labeling agents [8]. Among these substances, coil localization (CL) typically released the lowermost rates of complication [8].

Although most of the PNs can be easily found a needle pathway to perform the biopsy or localization, some PNs were blocked by the scapula [13, 14]. Under the common condition, when necessary, the scapula should be punctured when performing the lung interventions for scapula-blocked lung lesions [13, 14]. However, there still lacks the studies regarding of trans-scapular CL (TSCL) for scapular-blocked PNs (SBPNs).

In this study, we aim to investigate the safety, feasibility, and clinical efficacy of preoperative CT-guided TSCL for SBPNs.

Methods

This retrospective, single-center study was approved by our Institutional Review Board. The requirement of written informed consent was waived.

Study design

From January 2014 to September 2020, a total of 152 patients with PNs underwent CT-guided CL prior to VATS-guided WR. Among them, 14 patients (9.2%) had the SBPNs and underwent TSCL procedure.

Inclusion criteria were as follows: (a) a definite SBPN on CT; (b) PNs with the diameter ≤ 3 cm (sub-solid PNs ≤ 30 mm; solid PNs ≤ 15 mm); (c) the PN-pleura distance ≤ 20 mm; and (d) PNs lacking a definite pathological diagnosis.

Exclusion criteria were as follows: (a) a PN diameter < 5 mm; (b) a PN which decreased in size during CT follow-up; and (c) any abnormal coagulation activity, active bleeding, active infection, or limited cardiopulmonary reserve.

Puncture of the scapular

An interventional radiologist with more than 5 years of experience conducting CT-guided interventions performed all procedures using a 64-row CT (GE Healthcare, Milwaukee, WI). Patients were placed in the prone position and were administered local anesthesia.

A preoperative CT scan was used to ensure the needle pathway (Fig. 1a). A 17G needle (DuoSmart, Modena, Italy) was used to puncture the scapula. When the needle contacted the scapula, it was punctured using a drill and the application of steady pressure. Repeat CT scan was performed to observe the location of needle tip and the procedure-related complications (Fig. 1b). When the 17G needle passed across the scapula, the needle tip was pushed near the lung. However, the needle tip did not enter the lung.

Localization procedure

When the 17G needle passed through the scapula, an 18G needle (Precisa, Roma, Italy) was inserted from the 17G needle and was smoothly pushed to the lung to within approximate 10 mm of the PN (Fig. 1c).

Next, a coil (5-cm-length and 0.038-inches-diameter, Cook, Bloomington, IN) was partially placed into the pulmonary parenchyma, after which the needle was smoothly retracted so that the coil tail remained above the visceral pleura (Fig. 1d). Repeat CT scan was performed to observe the location of coil and the procedure-related complications.

VATS procedure

VATS-guided WR was routinely performed within 24 h of localization. The coil tail was used to guide this procedure. When the coil tail was detected under the thoracoscope, the WR was performed with the cutting margin > 20 mm from the coil tail. If the coil tail was invisible, the coil was considered to be completely inserted into the pulmonary parenchyma, then palpation of the coil was performed in order to conduct the WR. When this was still unsuccessful, the lobectomy should be performed.

The resected lesions were sent for a rapid pathological examination. If the pathological diagnosis indicated the results of benign, carcinoma in situ, mini-invasive carcinoma, or metastatic PN, the VATS could finish. Further lobectomy and lymph node dissection should be performed if the PN was diagnosed as invasive carcinoma.

Definitions

SBPN was defined as the PN with the lesion-pleura vertical line striding across the scapula. Technical success of TSCL was defined as that if coil tail could be detected under the thoracoscope. Technical success of WR was defined as that if the PN was found in the resected wedge tissue.

The primary endpoint was technical success of TSCL. The secondary endpoints included localization-related complications, technical success of VATS-guided WR, and final diagnoses of the PNs.

Statistical analysis

All statistical analyses were conducted by SPSS 16.0 (SPSS Inc., Chicago, IL). Continuous variables were presented with mean ± standard deviation. Categorical data were presented as a percentage (number/total).

Results

Patients

The baseline data of the 14 patients were shown in Table 1. There were 7 and 7 males and females, respectively, with a mean age of 57.0 ± 7.8 y. No patient had the malignant history.

Table 1
Baseline data of the 14 patients.

	Values
Patients number	14
Age (y)	57.0 ± 7.8
Gender (male/female)	7/7
Tumor history	0
Smoking history	5

SBPNs

The baseline data of the SBPNs were shown in Table 2. Each patient had 1 SBPN. The mean diameter of the 14 SBPNs was 7.4 ± 2.4 mm. Eight and 6 SBPNs located at right and left upper lobes, respectively.

Table 2
Baseline data of the nodules.

	Values
Nodules number	14
Diameter (mm)	7.4 ± 2.4
Natures of nodules	
Solid	6
Sub-solid	8
Nodule-pleura distance (mm)	5.6 ± 5.1
Side	
Left	6
Right	8

The indications of resection of the SBPNs included: (a) high-risk of lung cancer based on the clinical-radiological features (n = 8) [1, 6, 7]; and (b) PNs with the increase in size or solid components (n = 6).

TSCL procedure

Technical success rate of puncture of the scapula was 100%. No complications occurred near the scapula. Technical success rate of CL was 92.9% (13/14, Table 3). One coil dropped off when performing

the VATS procedure. The mean needle-pleura degree was 80.4 ± 4.5 degrees. The mean duration of the TSCL was 14.2 ± 2.7 min.

Table 3
Details of CT-guided localization.

	Values
Technical success of localization	13 (92.9%)
Duration of CT-guided procedure (min)	14.2 ± 2.7
Needle-pleura degree	80.4 ± 4.5
Complications	
Haematoma near the scapula	0
Pneumothorax	2 (14.3%)
Lung haemorrhage	0
CT: computed tomography.	

Two patient (14.3%) developed aysmptomatic pneumothorax after TSCL, but this did not impact the subsequent VATS procedure.

VATS-guided WR

Technical success rate of VATS-guided WR was 92.9% (13/14, Table 4). The patient who experienced technical failure of TSCL directly underwent lobectomy. Four patients underwent additional lobectomy after WR because the pathological diagnosis indicated the invasive adenocarcinoma result.

Table 4
Details of VATS procedures.

	Values
Technical success of WR	13 (92.9%)
Types of surgery	
WR	9
WR + lobectomy	4
Lobectomy	1
Duration of VATS (min)	90.0 ± 42.4
Blood loss (ml)	62.9 ± 37.2
Final diagnoses	
Invasive adenocarcinoma	4
Adenocarcinoma in situ	9
Benign	1
VATS: video-assisted thoracoscopic surgery; WR: wedge resection.	

The mean VATS procedure duration and blood loss were 90.0 ± 42.4 min and 62.9 ± 37.2 ml, respectively. The final diagnoses of the 14 SBPNs included invasive adenocarcinoma (n = 4), adenocarcinoma in situ (n = 9), and benign (n = 1). The pathological diagnosis of the SBPN in the patient who experienced technical failure WR was adenocarcinoma in situ.

Discussion

The present study showed the feasibility, safety, and clinical efficacy of preoperative CT-guided TSCL for SBPNs. During the CT-guided lung interventions, the needle pathway is sometimes blocked by the bone structures [13, 14]. In most cases, the bone structures should be avoided and the alternative pathway was chosen. However, unlike other lung interventions (biopsy or ablation), CT-guided CL of PNs requires that the coil tail remains on the pleural surface nearest the PN to ensure the technical success of VATS-guided WR [12]. Thus, the shortest needle pathway is essential to the CT-guided CL procedure, even though the optimal pathway is blocked by the bone structures.

In the present study, the scapula was successfully punctured in all patients with a high technical success rate (92.9%) of CT-guided TSCL. These rates were consistent with technical success rates reported previously in studies of CT-guided trans-bone lung ablation or biopsy (91%-100%) [13–15], and in studies of CT-guided CL for PNs (90%-100%) [12, 16–18]. Previous reports regarding percutaneous needle

approaches in the scapular region have reported no incidence of neurovascular injury or significant hemorrhage associated with such procedures [13–15]. In this study, no complication was observed near the scapula.

Some researchers have previously published clinical reports regarding CT-guided CL for sub-fissural or multiple PNs [18–20]. Relative to the previous studies, the CT-guided TSCL technique is much simpler as it only necessitates the puncturing of the scapula. In this report, we found that the 17G needle could be effectively used to puncture the scapula. Following puncture of scapular, an 18G needle was coaxially inserted to facilitate coil placement. This was done both to reduce the risk of pneumothorax.

An asymptomatic pneumothorax rate of 14.3% was observed in the present study, which is comparable to those observed in previous studies of CT-guided coil localization (9%-40%) [16–18], and studies of CT-guided trans-scapular lung interventions (18%-29%) [13–15].

Technical success rate of VATS-guided WR was 92.9% in he present study. Consistent with findings pertaining to the majority of preoperative CT-guided CL for other special PNs (95%-100%) [18–20], preoperative CT-guided TSCL also can achieve high technical success rate of WR when evaluating SBPNs while preserving maximal lung functionality.

There are multiple limitations to the present study. First, this was a retrospective study from a single-center, thus, the selection bias existed. Second, the sample size was small. However, our article focused on the special cases which had the SBPNs. In previous studies which focused on the trans-scapula lung interventions, the sample size was also limited (5–12 patients) [13–15]. Third, no control group was set in this study. When we began to use the preoperative localization for PNs, we always used the CL. Therefore, we had no cases which were localized by other materials. Further randomized controlled trials are needed.

Conclusion

In conclusion, preoperative CT-guided TSCL can be safely and simply used to facilitate high successful rates of VATS-guided WR of SBPNs.

Abbreviations

CT: computed tomography;

CL: coil localization;

PN: pulmonary nodule;

SBPN: scapular-blocked PN;

TSCL: trans-scapular CL;

VATS: video-assisted thoracoscopic surgery;

WR: wedge resection.

Declarations

Ethics approval and consent to participate:

This retrospective study was approved by institutional review board of Taizhou Hospital of Zhejiang Province affiliated to Wenzhou Medical University. The written informed consent was waived due to the retrospective nature. Only the relevant patient provided informed consent for publication of the images in Fig. 1.

Consent for publication:

The relevant patient provided informed consent for publication of the images in Fig. 1.

Availability of data and materials:

The data that support the findings of this study are available from the corresponding author upon reasonable request.

Competing interests:

None.

Funding:

None

Authors' contributions:

WBJ designed this study, MGZ and WBJ performed the CT-guided procedure, JC collected the patients' data; JC and JW analyzed these data; JW wrote and revised this paper; Final manuscript was approved by all authors.

Acknowledgments:

None

References

1. van't Westeinde SC, de Koning HJ, Xu DM, Hoogsteden HC, van Klaveren RJ. How to deal with incidentally detected pulmonary nodules less than 10mm in size on CT in a healthy person. Lung Cancer.2008;60:151-9.

2. Winer-Muram HT. The solitary pulmonary nodule. Radiology. 2006;239:34-49.
3. Xie Y, Zhang J, Xia Y. Semi-supervised adversarial model for benign-malignant lung nodule classification on chest CT. Med Image Anal.2019;57:237-48.
4. Zhang Y, Shen Y, Qiang JW, Ye JD, Zhang J, Zhao RY. HRCT features distinguishing pre-invasive from invasive pulmonary adenocarcinomas appearing as ground-glass nodules. Eur Radiol.2016;26:2921-8.
5. Zhang Y, Qiang JW, Ye JD, Ye XD, Zhang J. High resolution CT in differentiating minimally invasive component in early lung adenocarcinoma. LungCancer.2014;84:236-41.
6. MacMahon H, Naidich DP, Goo JM, Lee KS, Leung ANC, Mayo JR, Mehta AC, et al. Guidelines for Management of Incidental Pulmonary Nodules Detected on CT Images: From the Fleischner Society 2017. Radiology. 2017;284228-43.
7. Godoy MCB, Odisio EGLC, Truong MT, de Groot PM, Shroff GS, Erasmus JJ. Pulmonary Nodule Management in Lung Cancer Screening: A Pictorial Review of Lung-RADS Version 1.0. Radiol Clin North Am. 2018;56:353-63.
8. Park CH, Han K, Hur J, Lee SM, Lee JW, Hwang SH, et al. Comparative Effectiveness and Safety of Preoperative Lung Localization for Pulmonary Nodules: A Systematic Review and Meta-analysis. Chest. 2017;151:316-28.
9. Li Y, Wang T, Fu YF, Shi YB, Wang JY. Computed tomography-guided biopsy for sub-centimetre lung nodules: Technical success and diagnostic accuracy. Clin Respir J. 2020;14:605-10.
10. Fu YF, Li GC, Xu QS, Shi YB, Wang C, Wang T. Computed tomography-guided lung biopsy: a randomized controlled trial of low-dose versus standard-dose protocol. Eur Radiol. 2020;30:1584-92.
11. Liu GS, Wang SQ, Liu HL, Liu Y, Fu YF, Shi YB. Computed Tomography-Guided Biopsy for Small (≤20 mm) Lung Nodules: A Meta-Analysis. J Comput Assist Tomogr. 2020 Sep 23. doi: 10.1097/RCT.0000000000001071. Epub ahead of print. PMID: 32976266.
12. Finley RJ, Mayo JR, Grant K, Clifton JC, English J, Leo J, et al. Preoperative computed tomography-guided microcoil localization of small peripheral pulmonary nodules: a prospective randomized controlled trial. J Thorac Cardiovasc Surg. 2015;149:26-31.
13. Rossi UG, Seitun S, Ferro C. MDCT-guided transthoracic needle aspiration biopsy of the lung using the transscapular approach. Cardiovasc Intervent Radiol. 2011;34:184-7.
14. Rebonato A, Maiettini D, Andolfi M, Fischer MJ, Vannucci J, Metro G, et al. CT-Guided Percutaneous Trans-scapular Lung Biopsy in the Diagnosis of Peripheral Pulmonary Lesion Nodules of the Superior Lobes Using Large Needles. Cardiovasc Intervent Radiol. 2018;41:284-90.
15. Iguchi T, Hiraki T, Ishii H, Gobara H, Fujiwara H, Matsui Y, et al. Transosseous Route for CT Fluoroscopy-Guided Radiofrequency Ablation of Lung Tumors. J Vasc Interv Radiol. 2015;26:1694-8.
16. Fu YF, Zhang M, Wu WB, Wang T. Coil Localization-Guided Video-Assisted Thoracoscopic Surgery for Lung Nodules. J Laparoendosc Adv Surg Tech A.2018;28:292-7.

17. Su TH, Fan YF, Jin L, He W, Hu LB. CT-guided localization of small pulmonary nodules using adjacent microcoil implantation prior to video-assisted thoracoscopic surgical resection. Eur Radiol. 2015;25:2627–33.
18. Xia FF, Shi YB, Wang T, Fu YF. Computed Tomography-Guided Transfissural Coil Localization of Lung Nodules. Thorac Cardiovasc Surg. 2020;68:545-8.
19. Fu YF, Gao YG, Zhang M, Wang T, Shi YB, Huang YY. Computed tomography-guided simultaneous coil localization as a bridge to one-stage surgery for multiple lung nodules: a retrospective study. J Cardiothorac Surg. 2019;14:43.
20. Teng F, Wu AL, Yang S, Lin J, Xian YT, Fu YF. Preoperative computed tomography-guided coil localization for multiple lung nodules. Ther Adv Respir Dis. 2020;14:1753466620909762.

Figures

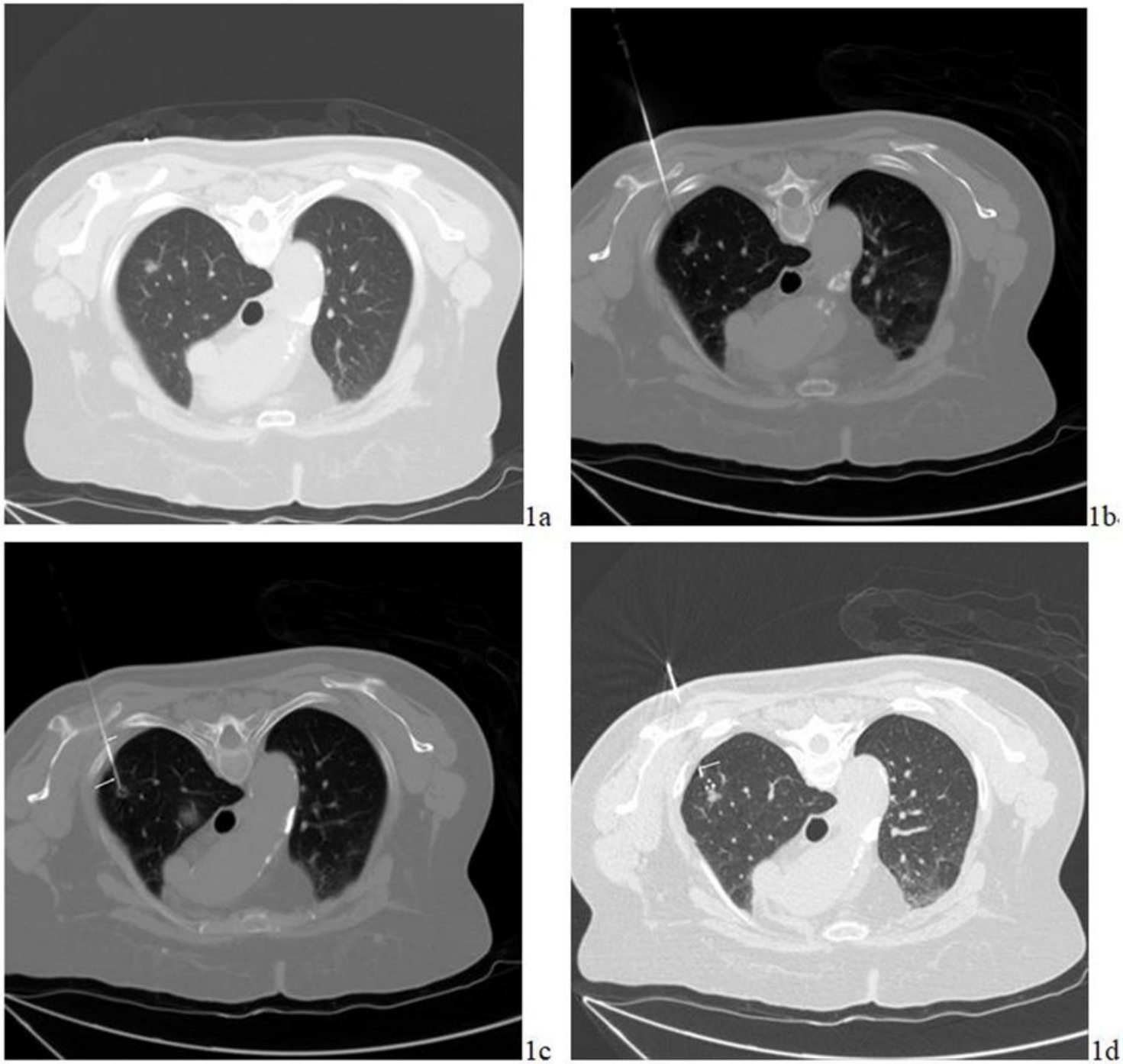

Figure 1

(a) Preoperative CT demonstrated that a SBPN located at the right upper lobe; (b) A 17G needle was used to puncture the scapular; (c) An 18G needle (long arrow) was inserted into the lung for coil localization via the 17G needle (short arrow); (d) The coil tail (arrow) remained above the visceral pleura.