Research Square

Preprints are preliminary reports that have not undergone peer review. They should not be considered conclusive, used to inform clinical practice, or referenced by the media as validated information.

Identification of The Intersegmental Plane By Arterial-Ligation Method During Thoracoscopic Segmentectomy

Heng Zhao
Xi'an Jiaotong University Medical College First Affiliated Hospital
Haiqi He
Xi'an Jiaotong University Medical College First Affiliated Hospital
Lei Ma
Xi'an Jiaotong University Medical College First Affiliated Hospital
Kun Fan
Xi'an Jiaotong University Medical College First Affiliated Hospital
Jinteng Feng
Xi'an Jiaotong University Medical College First Affiliated Hospital
Rui Zhao
Xi'an Jiaotong University Medical College First Affiliated Hospital
Xiaopeng Wen
Xi'an Jiaotong University Medical College First Affiliated Hospital
Jia Zhang
Xi'an Jiaotong University Medical College First Affiliated Hospital
Qifei Wu
Xi'an Jiaotong University Medical College First Affiliated Hospital
Junke Fu
Xi'an Jiaotong University Medical College First Affiliated Hospital
Guangjian Zhang (michael8039@163.com)
Xi'an Jiaotong University Medical College First Affiliated Hospital https://orcid.org/0000-0003-0888-5723

Research article

Keywords: segmentectomy, intersegmental plane, thoracoscopy

Posted Date: November 9th, 2021

DOI: https://doi.org/10.21203/rs.3.rs-994458/v1

License: This work is licensed under a Creative Commons Attribution 4.0 International License.
Read Full License

Abstract

Purpose

The purpose of this study is to explore the feasibility of identifying the intersegmental plane by arterial ligation alone during thoracoscopic anatomical segmentectomy.

Methods

We selected 35 patients with peripheral small lung nodules who underwent thoracoscopic anatomical segmentectomy between May and December 2020. First, the targeted segmental arteries were distinguished and ligated during the operation. Then, bilateral pulmonary ventilation was performed with pure oxygen to fully inflate the entirety pulmonary lobes. After waiting for a while, the intersegmental plane appeared. Finally, the intersegmental plane was observed using thoracoscopy after indocyanine green was injected into the peripheral vein. The intersegmental planes determined by these two methods were compared.

Results

Thirty-four patients underwent segmental resection and one patient finally underwent lobectomy. The intersegmental planes were successfully observed in all patients using the arterial ligation method. The time from contralateral pulmonary ventilation to the appearance of the intersegmental plane was 13.7±3.2 min (6-19 min). The intersegmental planes determined by the arterial ligation method and the fluorescence method were comparable. After the operation, CT examinations showed that the remaining lung segments of all patients were well inflated. The mean duration of closed thoracic drainage was 3.1±0.9 days.

Conclusion

The arterial ligation method can be used to determine the intersegmental plane in anatomical segmentectomy. The method is feasible, reliable, and safe.

Introduction

The thoracoscopic anatomical segmentectomy has become the main treatment method for early non-small cell lung cancer (NSCLC), which can achieve the same efficacy as lobectomy[1–3]. The thoracoscopic anatomic segmentectomy has the advantage of preserving more normal lung tissue and causing less trauma than lobectomy does. However, the determination of the intersegmental plane is one of the difficulties in thoracoscopic anatomic segmentectomy. In determining the intersegmental plane, there are many technical methods reported at home and abroad[4]. But these methods have flaws such

as inaccurate positioning, complex operation and the need for special equipment. In this study, we use the arterial ligation method to determine the intersegmental plane in anatomical segmentectomy, and the results are similar to those of fluorescent staining.

Materials And Methods

We selected 35 patients who underwent thoracoscopic anatomic segmentectomy for NSCLC in our department between May and December in 2020. Among them, 7 were male and 28 were female. The mean age was 56±11 years (33-77). Iodine allergy was eliminated in all patients, and the informed consent was completed before surgery. All patients underwent high resolution thin-layer chest CT examination before the surgery. 3D reconstruction of CT data was performed using Mimics 22.0 software (Materialise, Belgium) to determine the location of the NSCLC and target bronchial, arterial and venous routes. This study was approved by the Ethics Committee of the First Affiliated Hospital of Xi 'an Jiaotong University.

All patients were in lateral decubitus position and were intubated with a double-lumen endotracheal tube during the surgery. For the success of the operation, two incisions were made in patients. One was a 3cm operation hole, located between the 4th or the 5th ribs. The other was a 1cm endoscopic hole, located between the 7th or the 8th ribs. First, the targeted bronchus and segmental arteries were distinguished and ligated during the operation. Then, bilateral pulmonary ventilation was performed with pure oxygen to fully inflate the entirety pulmonary lobes. After that, contralateral single lung ventilation was performed again, and the operation stopped at this point. After waiting for a while, the intersegmental plane appeared. We labeled the pleura by cauterizing it with an electrocoagulation hook. Meanwhile, the time of the appearance of the intersegmental plane was recorded. Finally, 3ml indocyanine Green (ICG) solution was intravenously injected, and we used fluorescent endoscopy to observe the intersegmental plane. We compared the intersegmental plane determined by arterial ligation method with that determined by fluorescence staining method.

The resected lung samples were sent for cryopathologic examination during operation, and lymph node samples were taken from N1 and N2 stations in malignant cases

Results

The intersegmental plane were successfully identified in all patients by the arterial ligation method. When the lungs were fully inflated, the time from the contralateral pulmonary ventilation to the appearance of the intersegmental plane was 13.7±3.2 min (6-19 min). We observed swelling of the target segment and collapse of adjacent segments with well-defined boundaries(Fig. 1a). Next, we administered indocyturine green through a peripheral vein. After 10-15s in the infrared fluorescence mode, we could see that the retained lung segment presented green fluorescence, while the lung tissue of the target segment did not. The intersegmental planes determined by the two methods were consistent(Fig. 1b).

The segments of lung removed in all patients were as follows. Right side: S^1(5 cases), S^2(4 cases), S^2+S^1a(2 cases), S^3(3 cases), S^6(3 cases), S^8(3 cases). Left side: S^{1+2}(2 cases), S^3(1 case), S^{1+2}+S^3(4 cases), S^3b+c(1 case), S^4+S^5(3 cases), S^6(1 case), S^9(1 case), S^{10}(1 case), S^9+S^{10}(1 case). In fact, Segmentectomy was performed in 34 patients. Only 1 patient underwent lobectomy because the resection margin was less than 2cm from the tumor. The pathological results are as follows: 2 cases were benign tumors(6%), 3 cases were Atypical adenomatous hyperplasia(9%), 10 cases were adenocarcinoma in situ(29%), 9 cases were microinvasive adenocarcinoma(26%), and 11 cases were infiltrating adenocarcinoma(31%). The results of postoperative pathological examination were consistent with those of intraoperative frozen biopsy. And lymph nodes in all patients showed no metastasis. All operations were successfully completed and no air leakage was detected during the operation. Postoperative CT showed good remaining lung dilation in all patients, and no serious perioperative complications occurred. The chest drainage tube indwelling time were 3.1±0.9 days (2-5 days).

Discussion

With the wide application of high-resolution thin-slice CT examination, more and more pulmonary nodules have been found, including early NSCLC. Studies confirm that IA stage NSCLC has the similar long-term survival rates of lobectomy and thoracoscopic anatomical segmentectomy [1–3]. Segmental lung resection has the advantages of preserving more normal lung tissue and causing less trauma. Therefore, segmental lung resection is not only a reasonable choice for patients with poor lung functionbut also an effective surgical method for patients with stage IA lung cancer. However, thoracoscopic assisted segmental lung resection presents some technical challenges, among which the determination of the intersegmental plane is one of the most complex operations. On one hand, inaccurate determination of the intersegmental plane may lead to insufficient resection scope, resulting in residual lung tissue of the target segment, inadequate resection margin, and even residual lesions. On the other hand, excessive resection scope may lead to unnecessary resection of normal lung tissue. At the same time, the inaccurate determination of the intersegmental plane can also lead to the injury of the intersegmental vein, air leakage, poor lung inflation, and other problems. Therefore, the determination of intersegmental plane is the key step of anatomic segmental lung resection.

There are several methods used to determine the intersegmental plane[5]. Bronchial occlusion and vascular occlusion are the two main methods. The most commonly used bronchial method is the dilatation and collapse method, which is to cut off the target bronchi and dilate the lung, so that the remaining lung expands and the target lung collapses to determine the intersegmental plane. However, the presence of Kohn holes causes the target lung to expand along with the remaining lung. As a result, this method is inadequate in determining the intersegmental plane accurately. At present, the improved dilatation collapse method is more commonly used. After the target bronchus was cut off, the whole lung was inflated by double-lung ventilation, and then the whole lung was inflated by single-lung ventilation. When the remaining lungs collapsed naturally while the target lung was still inflated, the intersegmental plane could be presented. In addition, we can also reserve a slide node on the target segment bronchiand

ligature the bronchi after the whole lung expands, and wait for the appearance of the dilatation-collapse interface between the target segment and the remaining lungs[6]. Furthermore, the intersegmental plane can also be determined by selective bronchial ventilation through the target segment, such as inserting butterfly needle into the target segment bronchus and ventilating into it[7], and positioning bronchoscope to the target segment bronchus for high-frequency ventilation[8]. All of the above methods are based on the bronchial ventilation. Due to the influence of Kohn hole, the appearance of intersegmental plane is not accurate enough, and the operation of selective bronchial ventilation method is complicated. Still, there are bronchial dye injection methods, such as ICG[9], methylene blue and so on. But the operation is also complex, and the fluorescent dyes need special equipment and are difficult to use. Based on the pulmonary circulation, the pulmonary artery of the target segment is severed in advance, and then ICG is injected via peripheral vein. After a few seconds, the lung tissues outside the target segment show green fluorescence, and the intersegmental plane is clearly visible. However, the duration of the appearance of the intersegmental plane is relatively short. In addition, patients who smoke heavily may have poor visibility in the intersegmental plane after ICG injection[10].

The arterial ligation method is also based on pulmonary circulation. this method was first reported by Iwata in 2013[11]. It is speculated that the principle of intersegmental plane presentation is as follows: when the target segment artery is blocked, pure oxygen is used to dilate the lung. And single lung ventilation is performed again. The oxygen in the lung tissues of the target segment cannot be taken away by the blood in the pulmonary circulation and the tissues continue to expand, and the rest of lungs collapse, resulting in the intersegmental plane (Fig. 1a). Therefore, we hypothesized that simultaneous dissection of the target artery and vein might be more effective[12]. Recently, Fu *et al.*[13] confirmed the feasibility of this method through more cases. This method is in good agreement with the intersegmental plane determined by bronchial occlusion and vascular occlusion. Considering that both the arterial ligation method and ICG method are based on the principle of pulmonary circulation, we compared the intersegmental planes determined by the two methods. And the results showed that the two methods are highly consistent. In the traditional improved dilatation and collapse method, the bronchus, arteries and veins are separated in advance. Therefore, it is reasonable to speculate that the appearance of intersegmental plane in the improved dilatation and collapse method is also due to pulmonary circulation, rather than the principle of bronchial ventilation alone. Of course, this hypothesis needs further testing. The advantages of the arterial ligation method are that it is simpler than the traditional improved dilatation and collapse method, that the intersegmental plane is more durable than the ICG method, and that no special equipment is required.

Admittedly, there are shortcomings in this study. First, only common lung segments were selected in the study with a small number of cases. Secondly, the effectiveness of this method in patients with COPD needs further validation. Finally, as the traditional dilatation and collapse method, the arterial ligation method also requires the intraoperative cooperation of the anesthesiologist.

In conclusion, the arterial ligation method can successfully identify the intersegmental plane, and it results are consistent with the that of the ICG method. And the arterial ligation method is simpler than

other methods. Therefore, it is worth popularizing and applying. The principle of arterial dissection may be that oxygen in alveoli cannot disperse into blood after the pulmonary circulation in target tissues is interrupted, which needs further study to clarify.

References

1. Landreneau, R.J., et al., *Recurrence and survival outcomes after anatomic segmentectomy versus lobectomy for clinical stage I non-small-cell lung cancer: a propensity-matched analysis*. J Clin Oncol, 2014. **32**(23): p. 2449–55.
2. Zhang, L., et al., *Comparison of the oncologic outcomes of anatomic segmentectomy and lobectomy for early-stage non-small cell lung cancer*. Ann Thorac Surg, 2015. **99**(2): p. 728–37.
3. Hwang, Y., et al., *Comparison of thoracoscopic segmentectomy and thoracoscopic lobectomy on the patients with non-small cell lung cancer: a propensity score matching study*. Eur J Cardiothorac Surg, 2015. **48**(2): p. 273–8.
4. Nex, G., et al., *How to identify intersegmental planes in performing sublobar anatomical resections*. J Thorac Dis, 2020. **12**(6): p. 3369–3375.
5. Andolfi, M., et al., *Identification of the intersegmental plane during thoracoscopic segmentectomy: state of the art*. Interact Cardiovasc Thorac Surg, 2020. **30**(3): p. 329–336.
6. Endoh, M., et al., *How to demarcate intersegmental plane with resected-segments inflation method using the slip knot technique in thoracoscopic anatomic segmentectomy*. J Vis Surg, 2017. **3**: p. 100.
7. Kamiyoshihara, M., et al., *Butterfly-needle video-assisted thoracoscopic segmentectomy: a retrospective review and technique in detail*. Innovations (Phila), 2009. **4**(6): p. 326–30.
8. Okada, M., et al., *A novel video-assisted anatomic segmentectomy technique: selective segmental inflation via bronchofiberoptic jet followed by cautery cutting*. J Thorac Cardiovasc Surg, 2007. **133**(3): p. 753–8.
9. Sekine, Y., et al., *A simple and effective technique for identification of intersegmental planes by infrared thoracoscopy after transbronchial injection of indocyanine green*. J Thorac Cardiovasc Surg, 2012. **143**(6): p. 1330–5.
10. Iizuka, S., et al., *Predictors of indocyanine green visualization during fluorescence imaging for segmental plane formation in thoracoscopic anatomical segmentectomy*. J Thorac Dis, 2016. **8**(5): p. 985–91.
11. Iwata, H., et al., *Surgical technique of lung segmental resection with two intersegmental planes*. Interact Cardiovasc Thorac Surg, 2013. **16**(4): p. 423–5.
12. Matsumoto, M., et al., *Division of the intersegmental plane using electrocautery for segmentectomy in clinical stage I non-small cell lung cancer*. J Thorac Dis, 2018. **10**(Suppl 10): p. S1215-s1221.
13. Fu, H.H., et al., *The arterial-ligation-alone method for identifying the intersegmental plane during thoracoscopic anatomic segmentectomy*. J Thorac Dis, 2020. **12**(5): p. 2343–2351.

Figures

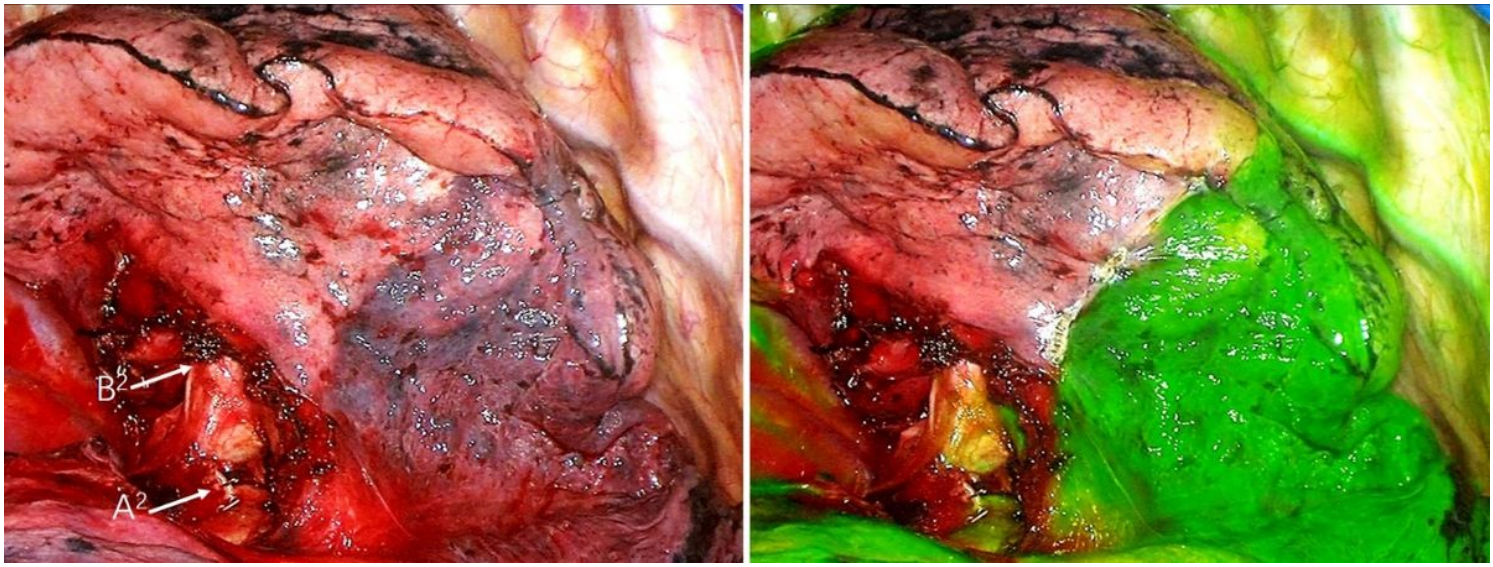

Figure 1

Identifying the intersegmental plane during a right S2 segmentectomy. (Figure 1a is the arterial ligation method. B2 is the posterior bronchus, A2 is the severed posterior artery. Figure 1b is the fluorescence method.)